



Since January 2020 Elsevier has created a COVID-19 resource centre with free information in English and Mandarin on the novel coronavirus COVID-19. The COVID-19 resource centre is hosted on Elsevier Connect, the company's public news and information website.

Elsevier hereby grants permission to make all its COVID-19-related research that is available on the COVID-19 resource centre - including this research content - immediately available in PubMed Central and other publicly funded repositories, such as the WHO COVID database with rights for unrestricted research re-use and analyses in any form or by any means with acknowledgement of the original source. These permissions are granted for free by Elsevier for as long as the COVID-19 resource centre remains active.

patients, whom we wished to isolate from other patients, should they be booked an appointment.

The appointments for booked patients were spread throughout the day and we developed a new COVID-19 period standard operating procedure for use across the Dental Institute. The only treatment we currently provide are dental extraction, and pulpotomy. Both are carried out in closed surgeries using PPE recommended in BAOMS/BAOS guidance¹ by FFP3 mask fit-tested staff. Members of our team are assigned appropriate roles including telephone advice and triage, patient assessment in Acute Dental Care, and operating within the Oral Surgery department.

Now into week 4 of our COVID-19 urgent dental care service, we have received calls from up to 290 patients a day, there are a number of repeat callers who contact us again having failed to secure dental care in their locality as we advised. Whilst many GDP's are taking calls, providing advice and prescriptions where appropriate this is not universally the case. There is a clear need for more Urgent Dental Care Hubs to become operational with immediate effect.

Ethics statement/confirmation of patients' permission

Not applicable.

Conflict of interest

We have no conflicts of interest.

Reference

- Magennis P, Coulthard P. *Guidance PPE for patients with emergency oral and dental problems of unknown COVID status*; 2020 [Accessed online on 20 April 2020] https://www.baoms.org.uk/_userfiles/pages/files/professionals/covid_19/baoms_baos_covid_advice_update_25_march_2020_final.pdf.

O. Obisesan*
O. Akintola
C. Bryant
J. Patel
A. Shah
H. Tagar

Department of Oral Surgery, Kings College Dental Institute, Bessemer Road, London, SE5 9RW, United Kingdom

*Corresponding author.

E-mail address: oobisesan@nhs.net (O. Obisesan)

Perils of intermaxillary fixation screws

Sir,

Intermaxillary fixation (IMF) screws, typically self-tapping, are easy and quick to use, seemingly safe, are compatible with plating systems, reduce buccal and gingival tissue trauma and are used to assist with open reduction and internal fixation (ORIF) of fractured mandibles.¹ However, there is limited literature on complications that may arise with their use.²

Hashemi and Parhiz³ studied 373 screws in 73 patients and found that 6.5% of screws damaged dental roots, of which 13 teeth required further treatment or extraction. Coburn et al⁴ described complications in their 122 patient study including fracture of screws upon insertion and iatrogenic damage to teeth.

Of the complications noted, firstly, we further report the risk of root damage as shown in the panoramic radiograph (OPT) following ORIF (Fig. 1). We have also experienced failure at the IMF screw head-thread junction as in Fig. 2, a complication also reported by Holmes² and Coburn.⁴ Farr⁵ postulated that screw fracture at this junction might be created by the screw being placed partly into root dentine which would then require more force to insert the screw due to greater resistance, whilst this is a view that we share, we also propose that there can be, on occasion, mechanical weaknesses or faults at this junction. This unplanned separation may result in delays due to difficult intraoperative retrieval (if possible without further damage). The complications described have become more pertinent in the present climate, with greater reliance on IMF.

To avoid the problems outlined with IMF screws an alternative, in the form of MatrixWAVE™ MMF System, may be considered. This procedure can be performed under local anaesthetic. As compared to traditional wire fixation of an arch bar, the MatrixWAVE™ MMF System uses a modified arch bar, which is secured with screw fixation. It also uses shorter self-tapping screws compared to IMF screws, because there are more placed across the arch. Lastly, when securing the MatrixWAVE™ MMF System screws, they are not inserted up to the screw head-thread junction, thus allowing more space for wire and elastics to be applied on to these, as well as the cleats on the arch bar, so allowing a more even and accurate distribution of force.

In the current COVID-19 crisis, we are faced with difficult decision making where advice from health care bodies is to avoid 'Aerosol Generating Procedures' (AGP) where possible (such as drilling), along with limited theatre availability and usage. Avoiding AGP may help avoid general anaesthetic/intubation, hospital admission and exposure to

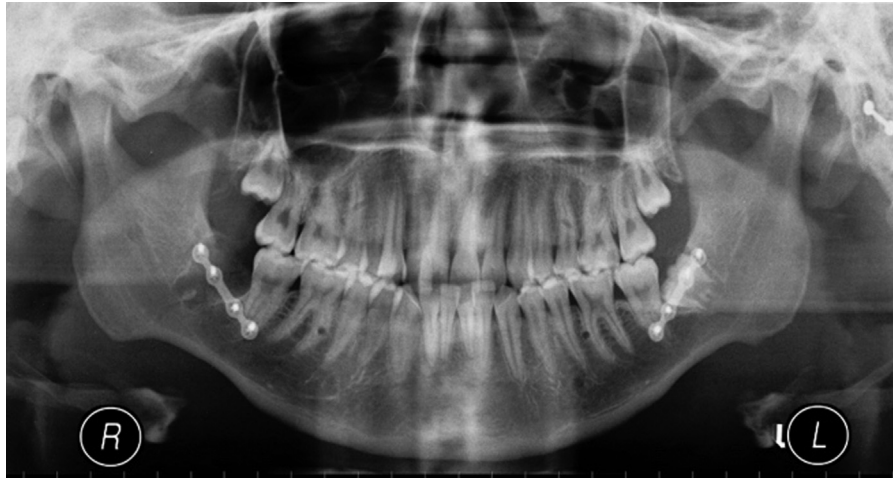

Fig. 1. Panoramic radiograph depicts root dentine involvement of the LR6, LL6, UL5 and UR5.

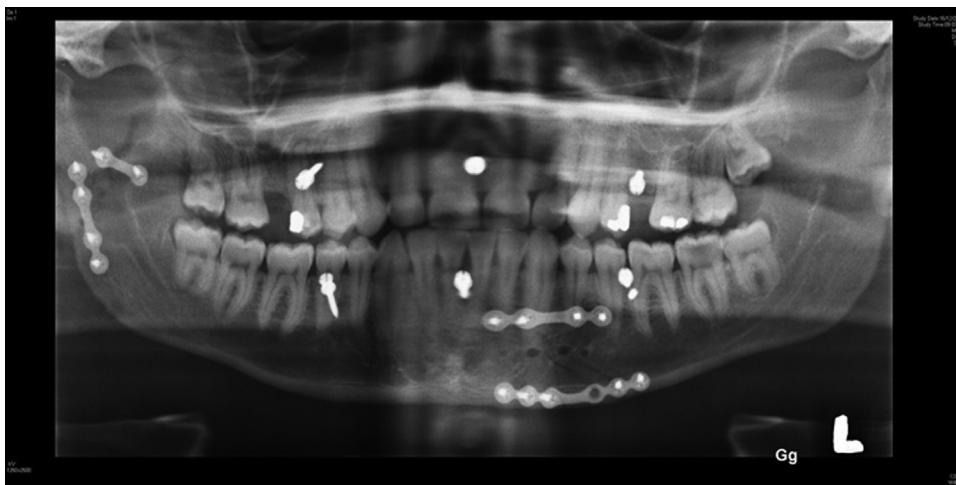


Fig. 2. Panoramic radiograph shows separation of the main screw thread body from the head in between the LL6 and LL5.

potential COVID-19 viral infection, so reduce the stress on an already stretched system. In respect of fractured mandibles, both IMF screws and MatrixWAVE™ MMF System (or similar system), in particular, are proving more useful and a safer alternative for dentate mandibular fractures, at this time, but must be placed carefully.

Conflict of interest

We use Depuy Synthes fixation materials at North Manchester General Hospital.

Funding

No funding sources were used or required.

Ethics statement/confirmation of patient's permission

Ethics approval not required. Patient permission obtained.

Reference

1. Jones DC. The intermaxillary screw: a dedicated bicortical bone screw for temporary intermaxillary fixation. *Br J Oral Maxillofac Surg* 1999;**37**:115–6.
2. Holmes S, Hutchison I. Caution in use of bicortical intermaxillary fixation screws. *Br J Oral Maxillofac Surg* 2000;**38**:574.
3. Hashemi HM, Parhiz A. Complications using intermaxillary fixation screws. *J Oral Maxillofac Surg* 2011;**69**(5):1411–4.
4. Coburn DG, Kennedy DW, Hodder SC. Complications with intermaxillary fixation screws in the management of fractured mandibles. *Br J Oral Maxillofac Surg* 2002;**40**(3):241–3.
5. Farr DR, Whear NM. Intermaxillary Fixation Screws and Tooth Damage. *Br J Oral Maxillofac Surg* 2002;**40**(1):84–5.

A.S. Ali

R.M. Graham*

Oral and Maxillofacial Surgery Department, North
Manchester General Hospital, Delaunays Road, Crumpsall,
Manchester, M8 5RB

*Corresponding author.

E-mail address: richard.graham2@nhs.net (R.M. Graham)

A perspective from a NYC chief oral and maxillofacial surgery resident during the COVID-19 pandemic

Sir,

The World Health Organization (WHO) declared coronavirus disease 2019 (COVID-19) as a pandemic on March 11, 2020. As the outbreak began to take a grip on New York City (NYC), my intern was consulted for a COVID-19 positive patient with an odontogenic infection. We donned our bouffant caps, eyewear, respirators, faceshields, and gowns before walking to the Emergency Department (ED). As we stepped foot into the ED, stretchers overflowed against the walls of the hallways. The background noise was loud from all the COVID-19 patients on rumbling ventilators and beeping monitors. It felt as though we were standing in the middle of a graphic battlefield. Even the smell was different. As we approached our patient, we heard her whimper as she pointed to her lower right tooth. I anaesthetised the area and grabbed my forceps, trying to be careful as the oral cavity contains a high viral load. Thankfully, I extracted the tooth with ease.

I could not imagine what my ED colleagues were feeling as they worked tirelessly around me.

In a matter of days, almost every patient in my hospital had COVID-19. NYC became the epicentre of the pandemic and the situation worsened day-to-day. “Code 99”, “RRT”, and “STAT intubation” constantly blared from the intercom. The lawn filled with white triage tents. Kraft paper blocked the windows facing the overflowing morgue. Oral and Maxillofacial Surgery (OMFS) residents were deployed to General Surgery to help run their teams and even suture lacerations outside the facial region.

Late March, one of our residents tested positive. A few days later, we saw a picture in the news of another OMFS resident from Brooklyn with COVID-19. He was on a stretcher “coughing up blood” despite being young and fit.¹ A week later, we received an e-mail describing a 37-year-old chief OMFS resident from Michigan who had passed away from complications of COVID-19. He left behind a wife and three children.² We were clearly fighting a camouflaged enemy that did not discriminate.

To clear my mind, I took a different route toward home. As I passed by one of the largest, busiest stores in the world, Macy’s at Herald Square, there was barely a person in sight (Fig. 1). The streets of Manhattan had emptied—an unusual display in broad daylight. The scene felt almost post-apocalyptic and yet I felt gratitude for all who remained inside and all essential workers. They helped stop the spread and save lives.

I reached home and went to sleep not knowing what tomorrow would bring.



Fig. 1. An image of Macy’s at Harold Square in New York City taken from my car during COVID-19 stay-at-home order.