



CASE REPORT

Open Access

Compression of common peroneal nerve caused by an extraneural ganglion cyst mimicking intermittent claudication

Raif Ozden^{*}, Vedat Uruc, Aydiner Kalacı and Yunus Dogramacı

Abstract

Peripheral neuropathies caused by ganglion cysts are rare. They seldom cause serious complications especially in the lower extremities. The case was a 51-year-old woman referred by her physician to the vascular surgeon with diagnosis including intermittent (vascular) claudication and deep venous thrombosis. Primarily vascular surgeon performed a doppler ultrasound of the lower extremity and calculation of the ankle-brachial index. There were no abnormal pathological findings. Careful physical examination revealed soft swelling and tenderness around the fibular head and neck. Weakness was observed in foot eversion and dorsiflexion. There was pain and tingling in the distribution of the peroneal nerve. and referring the patient to orthopedic surgeon owing to concern for a potential compressive lesion at the right proximal tibiofibular region. Electromyogram studies and physical examination confirmed a diagnosis of compression neuropathy of common peroneal nerve. Magnetic resonance imaging revealed a fluid-filled, lobulated mass indicating a ganglion cyst. One months after decompression, the patient had no complaint. Fast diagnosis and immediate management are essential to regain best possible recovery.

Keywords: Peroneal nerve, Ganglion cyst, Tibiofibular joint

Introduction

Leg pain, loss of ankle dorsiflexion and sensory loss, neurogenic claudication most commonly produced by degenerative disc disease of the lumbar spine. On the other hand, isolated peroneal nerve compression can mimic lumbar disc disease. Differentiation of symptoms of vascular claudication from symptoms of neurogenic claudication is important. Ganglion cyst is the most frequent tumours of the upper extremity. Despite their high incidence, ganglion cyst rarely result in peripheral nerve compression [1]. Compression neuropathies of the lower extremity are much less common and comprise only a minority of cases have been described [2-9]. The peak incidence has been seen at the fourth decade of life and it is rare in children [2,8]. Neurologic symptoms and pain are typical manifestations. We describe a case with a ganglion cyst as a rare cause of peroneal neuropathy and mimicking intermittent claudication treated surgically.

Case presentation

A 51-year-old female patient presented to her physician with a six-month history of intermittent claudication. She developed aching, cramping, pain and weakness of her right calf. She has radiating pain and hypoesthesia, while motor weakness was less prominent. She was referred to a vascular surgeon. After examination of the case there was nothing that concerns vascular surgery. Tenderness in the area of the right fibular head with gradual development of swelling in the same area was determined. Therefore, case was referred to orthopedic surgeon. A comprehensive physical examination revealed soft tissue swelling in the region around the fibular head and neck. There was slightly weakness in foot eversion and dorsiflexion, especially of the first toe. Inversion was normal. Electromyogram studies of the common peroneal nerve demonstrated significant neuropathic abnormalities. Subsequent magnetic resonance imaging demonstrated a lobulated, multilocular, cystic-appearing mass around the proximal fibular area. It was measured approximately 3 cm × 2 cm × 2 cm (Figure 1). The lesion was located

^{*} Correspondence: raifozden@gmail.com
Department of Orthopaedics and Traumatology, Faculty of Medicine, Mustafa Kemal University, Antakya, Hatay, Turkey

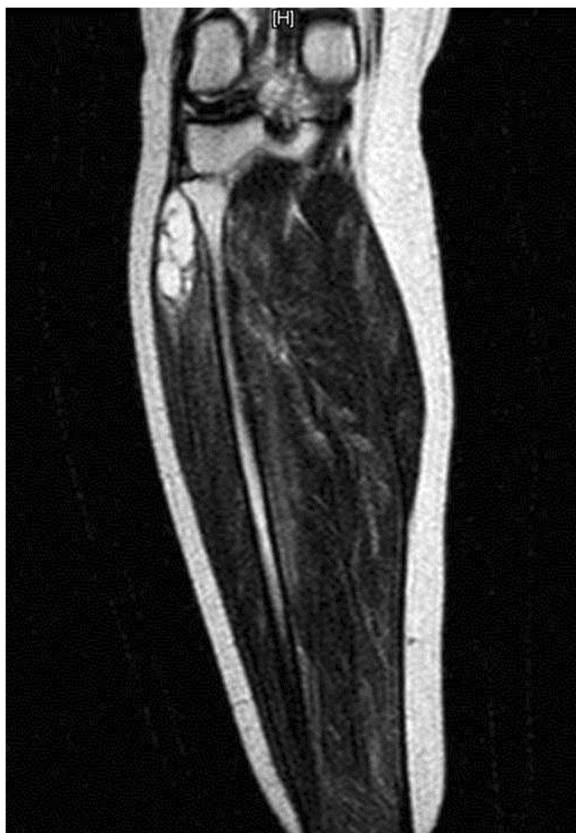


Figure 1 Characteristic magnetic resonance imaging findings of ganglion cyst with high signal intensity on the T2 sequence images.

anterior to the lateral aspect of the fibular neck, with the common peroneal nerve compressed against the posterior aspect of the cyst. It extended along the nerve toward its bifurcation. Using a lateral approach, the common peroneal nerve was recognized and traced to its bifurcation (Figure 2). The mass was followed

down to its stalk and removed completely. The peroneal nerve was recognized as intact. All nerve branches were preserved under loupe magnification. The surgical material was diagnosed as ganglion cyst by histopathological examination. After one month of the surgery, the patient had no complaints of pain and the claudication also recovered completely.

Discussion

Peripheral nerve lesions owing to ganglionic cysts are infrequent findings. The pathogenesis of these cysts has been the subject of controversy. However, evidence has demonstrated that they are of articular origin [10,11]. Ganglionic cysts compressing the peroneal nerve may be extraneural or intraneural [12]. Most of the ganglionic cysts defined in the literature causing peroneal nerve compression were intraneural type. Compression of the peroneal nerve was owing to an extraneural cyst as in our case is a condition rarely encountered and history of knee trauma is a common finding [13,14]. There was knee trauma history in our case. The most frequent symptoms of this condition are weakness in the tibialis anterior, peroneus longus and brevis muscles, and pain radiating to the lateral malleolus [15-17]. Swelling of the proximal tibio-fibular joint are less common. Our case presented with radiating pain and hypoesthesia, while motor weakness was less prominent. The other complaints were swelling and localized pain in the region around the fibular head and neck. The differential diagnosis should include root compression, a nerve compression near the tendinous arch of the peroneal longus muscle, a nerve-sheath tumor, the osteocartilaginous exostosis at the proximal lower leg [18-20] and intermittent claudication as in our case. Plain radiographs have little importance in the diagnosis of ganglion cyst, but may be beneficial in eliminating a bony anomaly or fracture of the proximal part of fibula. Furthermore it may be useful in

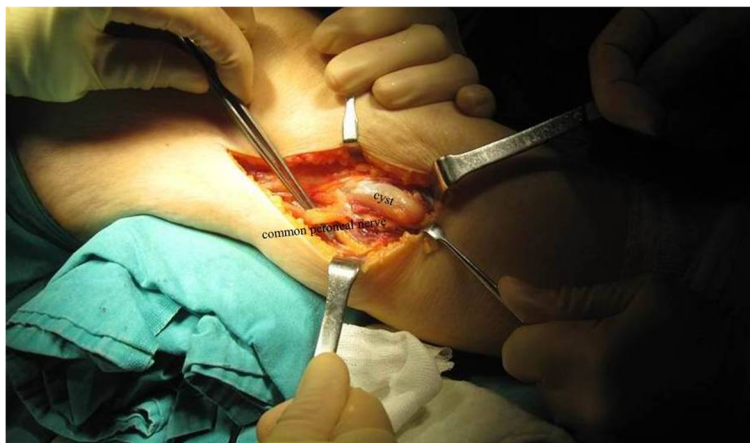


Figure 2 Intraoperative photograph of the lesion as seen associated with the peroneal nerve.

excluding degenerative disc disease of the lumbar spine. Magnetic resonance imaging is more useful in terms of the diagnosis. It may be difficult to differentiate a ganglion cyst from nerve sheath tumors and also solid masses on magnetic resonance imaging. Ultrasonography may be effective in showing the cystic nature of the mass and in differentiating it from solid tumors [21]. Compression of the fibular nerve by an extraneural ganglion is an infrequent and often misleading condition. If the patient has intermittent claudication especially with paresthesia, weakness in foot eversion and dorsiflexion, ganglion cyst should be considered in the differential diagnosis. A combination of magnetic resonance imaging and ultrasonography is helpful for correct diagnosis of the disorder, and it should be treated by microsurgical technique when possible.

Conclusion

When a patient presenting with intermittent claudication, compression neuropathy of the peroneal nerve secondary to a ganglion cyst should be kept in mind in aspect of the differential diagnosis. After a complete history and physical examination, electromyogram and magnetic resonance imaging should be performed in terms of the differential diagnosis of a ganglion cyst. Careful preoperative evaluation, and early surgical excision by microsurgical technique in the management of the ganglion cyst should be recommended.

Consent

Written informed consent was obtained from the patient for publication of this case report and accompanying images.

Competing interests

We declare that we have no competing interests.

Authors' contributions

AK is the chief author who deals the patient clinically, BCG draws SKM attention for this case, RO and VU help AK in every aspect and YD take care of this patient preoperatively. All authors have read and approved the final manuscript.

Authors' information

Corresponding Author: Raif Ozden M.D. Assistant Professor. Mustafa Kemal University Faculty of Medicine, Department of Orthopaedics and Traumatology, Antakya, Hatay, Turkey.

Vedat Uruc M.D. Assistant Professor. Kemal University Faculty of Medicine, Department of Orthopaedics and Traumatology, Antakya, Hatay, Turkey.

Aydiner Kalacı M.D. Associate Professor. Mustafa Kemal University Faculty of Medicine, Department of Orthopaedics and Traumatology, Antakya, Hatay, Turkey.

Yunus Dogramacı M.D. Associate Professor. Mustafa Kemal University Faculty of Medicine, Department of Orthopaedics and Traumatology, Antakya, Hatay, Turkey.

Received: 27 February 2013 Accepted: 17 May 2013
Published: 30 May 2013

References

1. Greer-Bayramoglu RJ, Nimigan AS, Gan BS: Compression neuropathy of the peroneal nerve secondary to a ganglion cyst. *Can J Plast Surg* 2008, **16**:181–183.
2. Johnston JA, Lyne DE: Intraneural ganglion cyst of the peroneal nerve in a four-year-old girl: a case report. *J Pediatr Orthop* 2007, **27**:944–946.
3. Frank DA, Sangimino MJ: Peroneal nerve palsy secondary to ganglion cyst of the proximal tibiofibular joint in a pediatric patient. *Orthopedics* 2008, **31**:86.
4. Robla-Costales J, Socolovsky M, Dubrovsky A, Astorino F, Fernandez-Fernandez J, Ibanez-Plagaro J, Garcia-Cosamalon J: Intraneural cysts of the peroneal nerve in childhood: report of 2 cases and literature review. *Neurocirugia* 2011, **22**:324–331.
5. Luigetti M, Sabatelli M, Montano N, Cianfoni A, Fernandez E, Lo Monaco M: Teaching neuroimages: peroneal intraneural ganglion cyst: a rare cause of drop foot in a child. *Neurology* 2012, **78**:46–47.
6. Spinner RJ, Desy NM, Amrami KK: Sequential tibial and peroneal intraneural ganglia arising from the superior tibiofibular joint. *Skeletal Radiol* 2008, **37**:79–84.
7. Stamatis ED, Manidakis NE, Patouras PP: Intraneural ganglion of the superficial peroneal nerve: a case report. *J Foot Ankle Surg* 2010, **49**:401–404.
8. Waldschmidt U, Slongo T: An unusual cause of paralysis of the peroneal nerve—a case report. *J Pediatr Surg* 2010, **45**:259–261.
9. Yazid Bajuri M, Tan BC, Das S, Hassan S, Subanesh S: Compression neuropathy of the common peroneal nerve secondary to a ganglion cyst. *ClinTer* 2012, **162**:549–552.
10. Spinner RJ, Atkinson JLD, Tiel RL: Peroneal intraneural ganglia. The importance of the articular branch: a unifying theory. *J Neurosurg* 2003, **99**:330–343.
11. Spinner RJ, Amrami KK, Wolanskyj AP, Desy NM, Wang H, Benarroch EE, Skinner JA, Rock MG, Scheithauer BW: Dynamic phases of peroneal and tibial intraneural ganglia: a new dimension added to the unifying articular theory. *J Neurosurg* 2007, **107**:296–307.
12. Ghossain M, Mohasseb G, Dagher F, Ghossain A: Compression of the common peroneal nerve by a synovial cyst. *Neurochirurgie* 1987, **33**:412–413.
13. Rawal A, Ratnam KR, Yin Q, Sinopidis C, Frostick SP: Compression neuropathy of common peroneal nerve caused by an extraneural ganglion: a report of two cases. *Microsurgery* 2004, **24**:63–66.
14. Kili S, Perkins RD: Common peroneal nerve ganglion following trauma. *Injury* 2004, **35**:938–939.
15. Stack RE, Bianco AJ, MacCarthy CS: Compression of the common peroneal nerve by ganglion cysts. *J Bone Joint Surg [Am]* 1965, **47**:773–778.
16. Brooks DM: Nerve compression by simple ganglia: a review of thirteen collected cases. *J Bone Joint Surg [Br]* 1952, **34**:391–400.
17. Barrie HJ, Barrington TW, Colwill JC, Simmons EH: Ganglion migrans of the proximal tibiofibular joint causing lesions in the subcutaneous tissue, muscle, bone or peroneal nerve: report of three cases and review of the literature. *Clin Orthop* 1980, **149**:211–215.
18. Huaux JP, Malghem J, Maldague B, Noel H, Rombouts JJ, Courtois C, Nagant de Deuxchaisnes C: Pathology of the upper peroneotibial joint. History of cysts. Apropos of 4 cases. *Rev Rhum Mal Osteoartic* 1986, **53**:723–726.
19. Sidey JD: Weak ankles. A study of common peroneal entrapment neuropathy. *Br Med J* 1969, **3**:623–626.
20. Rinaldi E: Peroneal paralysis due to exostosis of the fibula. Report of 2 cases. *Ital J OrthopTraumatol* 1983, **9**:259–262.
21. Evans JD, Neumann L, Frostick SP: Compression neuropathy of the common peroneal nerve caused by a ganglion. *Microsurgery* 1994, **15**:193–195.

doi:10.1186/1749-7221-8-5

Cite this article as: Ozden et al.: Compression of common peroneal nerve caused by an extraneural ganglion cyst mimicking intermittent claudication. *Journal of Brachial Plexus and Peripheral Nerve Injury* 2013 **8**:5.