

Comparison of Conventional Ultrasound and Contrast Enhanced Magnetic Resonance (MR) Enterography in Evaluation Patients with Crohn's Disease

Bilal Imsirovic¹, Enver Zerem², Emir Guso¹, Muhamed Djedovic³, Anesa Cengic¹, Rusmir Baljic⁴, Zulejha Merhemic⁵, Alma Efendic⁶

¹Department of Radiology, General Hospital "Prim dr. Abdulah Nakas" Sarajevo, Sarajevo

²Department of Gastroenterology, University Clinical Center Tuzla, Tuzla

³Department of Surgery, Health Center Brcko, Brcko, University of Sarajevo, Sarajevo

⁴Department of Infectious Diseases, Clinical Center, University of Sarajevo, Sarajevo

⁵School of Health Studies, University of Sarajevo, Sarajevo

⁶Department of Radiology, Cantonal Hospital Zenica, Zenica

Corresponding author: Bilal Imsirovic, MD. Department of Radiology, General Hospital "Prim. dr. Abdulah Nakas", Kranjceviceva 12, 71000 Sarajevo, Bosnia and Herzegovina, ORCID ID: <http://www.orcid.org/0000-0002-0941-6593>. Phone: +387 33 285 100; Fax: +387 33 285 370; E-mail: bilal_imsirovic@yahoo.com

doi: 10.5455/aim.2018.26.93-97

ACTA INFORM MED. 2018 JUN; 26(2): 93-97

Received: Feb 07, 2018 • Accepted: Apr 26, 2018

© 2018 Bilal Imsirovic, Enver Zerem, Emir Guso, Muhamed Djedovic, Anesa Cengic, Rusmir Baljic, Zulejha Merhemic, Alma Efendic

This is an Open Access article distributed under the terms of the Creative Commons Attribution Non-Commercial License (<http://creativecommons.org/licenses/by-nc/4.0/>) which permits unrestricted non-commercial use, distribution, and reproduction in any medium, provided the original work is properly cited.

ABSTRACT

Introduction: The small intestine is a challenging organ for clinical and radiological evaluation, and by introducing imaging radiological techniques, not significantly disturbing the comfort and safety of patients, it attempts to obtain adequate diagnosis and valuable information. **Aim:** The research was conducted with the aim of checking the comparability and potential of diagnostic modality of ultrasound and dynamic contrast enhanced MR Enterography (DCE-MR) in patients with Crohn's disease.

Methods: 55 patients were examined prospectively, and ultrasound examination of the abdomen was performed for all patients before the MR enterography. They were subsequently endoscopically examined or treated surgically, which was taken as a reference. Four parameters characterizing the disease itself were analyzed: bowel wall thickening, presence of abscess, fistula and lymphadenopathy.

Results: Comparing the accuracy of the results of ultrasound findings and findings of MR enterography, it was found that there is a significant difference in the results obtained. The study found that the sensitivity for MR enterography for bowel wall thickening was 97.8%, and the specificity was 70%, while the sensitivity for ultrasound for the bowel wall thickening was 51% and the specificity was 100%. In the diagnosis of abscess, there was no significant difference between the results obtained by ultrasound and magnetic resonance imaging (MRI) findings, while in fistula and lymphadenopathy there was a significant difference. **Conclusion:** Conventional ultrasound is a good orientation method in the initial evaluation of patients with Crohn's disease, while contrast enhanced MR enterography provides an excellent assessment for disease activity as well as the complications that accompany it.

Key words: ultrasonography, magnetic resonance imaging, inflammatory bowel disease

1. INTRODUCTION

Crohn's disease is the most common small bowel disease that even still today presents a diagnostic challenge, and every effort to advance the diagnosis of this disease is have scientific and practical significance (1).

Although endoscopic methods are best for diagnosis and monitoring of digestive tube diseases, they are limited in the proximal and distal segments of the small intestine (2).

With the introduction of radiological imaging techniques, goal was to reach an adequate diagnosis and valuable information, without jeopardizing comfort and safety of the patient (3). Ultrasound is widely used diagnostic modality that is due to its availability, simplicity, absence of harmful effects and low cost is the first diagnostic method to be used in the diagnosis of the abdominal diseases (4). The use of ultra-

sound in the diagnosis of diseases of the gastrointestinal tract, even though he has restrictions such as are meteorism, abdominal pain, poor spatial orientation, superposition with intestinal convolutions, inability to display certain segments of intestines, etc, is justified in any case as an orientation method (5).

The use of magnetic resonance imaging in the evaluation of patients with inflammatory bowel disease was conditioned by development of devices that had technical predispositions for performing such examinations (6, 7).

Protocol development for MR enterography made the huge step forward in diagnostic treatment of patients with inflammatory bowel disease (8). Problems such as insufficient intestinal distension and intestinal peristalsis are solved with application oral contrast media and intravenous spasmolytic application (8).

The use of magnetic contrast medium with dynamical post contrast evaluation improved examination quality (9-12).

Initial hypotheses were that conventional ultrasound is a good orientation method in the initial evaluation of patients with Crohn's disease, that contrasting MR enterography provides an excellent assessment of the activity of the disease as well as the complications that accompany it, and that contrast enhanced MR enterography, in comparison with conventional ultrasound, has a significantly higher percentage of success in detecting the activity and complications of Crohn's disease.

The research was conducted to determine the accuracy and applicability of conventional ultrasound in the evaluation of patients with Crohn's disease, to determine the possibilities and potential of contrast enhanced MR enterography in setting diagnosis and assessing the severity and activity of inflammatory bowel disease, comparing the efficiency of conventional ultrasound and contrast MR enterography in diagnostic evaluation of patients with Crohn's disease, and provide guidelines for future diagnostic protocols.

2. PATIENTS AND METHODS

Patients and study design

The study implied a prospective study in which a conventional ultrasound was compared with DCE-MRI enterography in the diagnosis of Crohn's disease and complications that accompany it.

The study included 55 patients who were diagnosed and treated in Zenica Cantonal Hospital during the period from July 2013 to December 2015 due to the suspicion of Crohn's disease.

Research protocol was approved by the ethical committee of the Cantonal Hospital Zenica.

All patients had an ultrasound examination of the abdomen prior to MR enterography. Figure 1 shows ultrasonically verified presence of wall thickening of terminal ileum and enterocutaneous fistula, while Figure 2 showed thickening of the bowel wall with rise in signal intensity after contrast medium was administered (Figure 1 and 2). They were subsequently subjected to endoscopic examinations or were surgically treated and that was set as the reference finding.

The study included patients with clinical and laboratory set suspicion of Crohn's disease, that included patients with previously diagnosed and PH verified Crohn's disease (endoscopically and surgically), and which are in phase of exacerbation (patients with presence of clinical and laboratory indicators of diseases activity).

In consideration came and patients with suspected Crohn's disease where the disease is located on endoscopic accessible places in order to subsequent confirmation of endoscopic imaging findings (colon, terminal ileum, area of ileum and colon junction—the proximal part of the gastrointestinal tract available endoscope).

The study also included patients who were after imaging surgically treated.

The study excluded patients with a contraindication for MRI (electromagnetic implants, metallic foreign bodies, claustrophobia ...), patients with a contraindication for the application of MR contrast agent (renal failure, high values of urea and creatinine, allergy to contrast media ...), patients

to whom there were confirmed changes in the digestive tract segments that were not available for endoscopic confirmation and did not require urgent surgical treatment.

Study implied analysis of ultrasound and DCE-MR enterography for every patient included in the study. Clinical and morphological characteristics were analyzed, such as thickening of the bowel wall (more than 3 mm) presence of fistula and abscess. Analysis included local lymphadenopathy as indirect sign of inflammation.

Methods

Patients qualified to participate in the study on the basis of the above mentioned criteria were ultrasonically examined in the Ultrasound Cabinet, Radiology department, Zenica Cantonal Hospital on PHILIPS EnVisor M2540A Ultrasound System.

Ultrasound examination was performed for all patients before MRI examination order to make it as objective as possible, and to avoid seeking changes seen during MR examination. Each ultrasound examination included a B-mode scan, using a convex 3.5 MHz probe and linear 7 MHz probe.

MRI scanning (SIEMENS Magnet Avanto, 1.5 T, Erlangen, Germany) was performed for all patients in the most optimal time frame compared to ultrasound examination.

Even though there is not a consensus about the universal protocol for contrast enhanced MRI enterography, each examination should consist with fast and ultrafast T1W and T2W sequences in transversal and coronary plane. Dynamic post-contrast evaluation implies use of GE T1W sequences with fat saturation.

After native examination, and intravenous application of contrast medium, dynamic post-contrast recordings on T1 VIBE sequences biplanar (transversal and coronary) were performed.

Before examination the patient drank 1.5L of fluid consisted of 10% mannitol and water in proportion 1:2; at the end they drank 100 mL of dilution every 5 minutes. After that patients were put on the device table where the magnetic coils were applied: 4-channel flex large and 8-channel body matrix a tim coil.

Before start of both native and post-contrast scanning, patients were given intravenous spasmolytic in order to slow down peristalsis and to avoid artefacts of intestinal twitching.

Statistical analysis

Applied methods of descriptive statistical analysis were used to describe distribution of examined variables. Kolmogorov-Smirnov test was used to test normal distribution of quantitative variables. Since these samples are not normally distributed but at the same time they are dependent, in questioning the significance it was used non-parametric Wilcoxon test (Wilcoxon signed rank test).

Statistical analysis was performed using the "R" program.

In order to establish the diagnostic characteristics, respectively the quality of one method in relation to the other, we performed receiver operating characteristic curve (ROC) analysis.

The statistical hypotheses were tested at the level of <math> < 0.05 </math>, that means that the difference between samples was considered significant if $p < 0.05$.

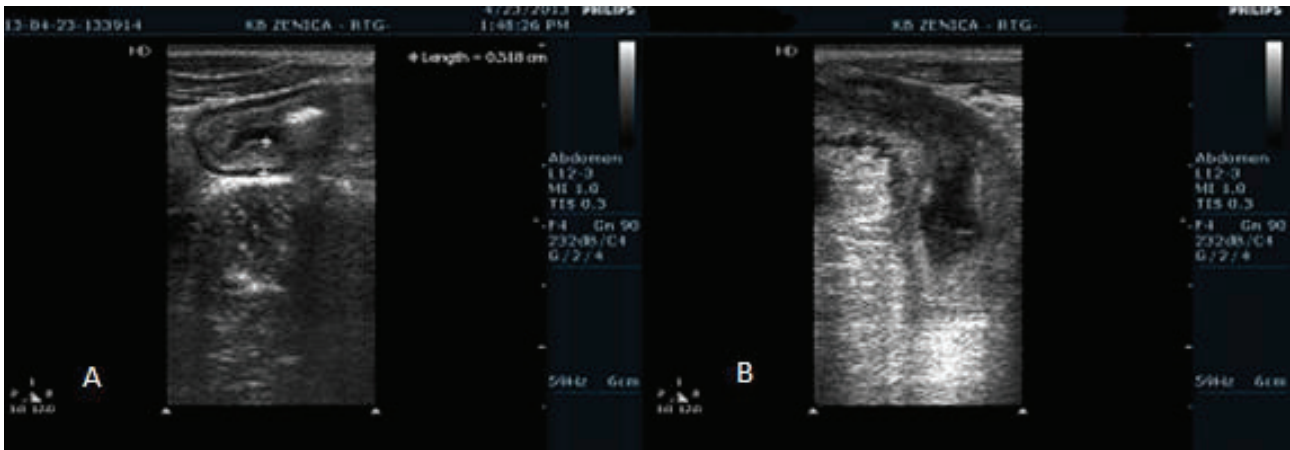


Figure 1. Ultrasonic findings: A) Thickening of the terminal ileum wall, and B) presence of enterocutaneous fistula (Department of radiology, Cantonal Hospital Zenica, 2013).

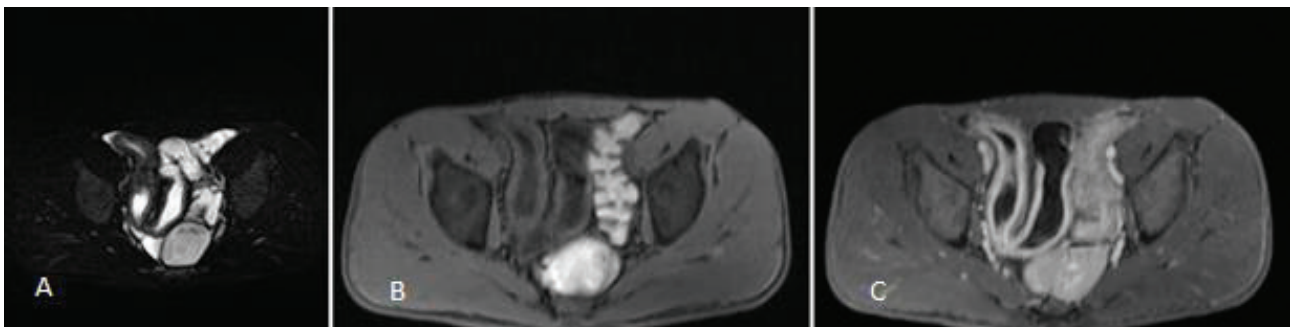


Figure 2. A) T2 blade fs axial multi breathe hold (mbh), B) T1 vibe fs axial mbh, and C) T1 vibe fs axial mbh postcontrast: bowel wall thickening (Department of radiology, Cantonal Hospital Zenica, 2013).

3. RESULTS

Out of 55 checked patients, 10 patients were lacking pathohistological confirmation of the disease presence. Three of them had positive results on MR enterography.

Of the 55 patients examined by ultrasound, thickening of the bowel wall has been found at 23 of them (42%) to who disease was pathohistologically confirmed. In 10 patients (18.2%), ultrasonically, the absence of bowel wall thickening was precisely diagnosed. Thickening is generally related to the affection of the sigmoid colon, and the thickening of the wall of the terminal ileum.

MR enterography described wall thickness in 44 patients who were pathohistologically confirmed (80%) and in 3 (5.45%) patients without pathohistological confirmation. In 7 (12.7%), the absence of pathological wall thickening on the MR enterography was accurately diagnosed.

The bowel wall thickening has been practically verified on all segments of the small and large intestine. Both modalities verified the thickening of the bowel wall in 22 patients (40%), ultrasound showed a thickening of the bowel wall in one patient (1.8%) which had not seen on MR enterography, while MR enterography showed bowel wall thickening in 22 patients (40%) that were not detected on ultrasound.

Using the statistical program "R", it was found that $V = 0$, with $p = 2.727 \times 10^{-6}$ suggesting that ultrasound provides results with a significant difference compared to verified. MRI does not give results with a significant difference compared to verified ones ($V = 7.5$, $p = 0.3173$).

Statistical analysis of the results reveals that there is a significant difference between the ultrasound and MRI ($V = 337.5$, $p = 2,517 \times 10^{-6}$).

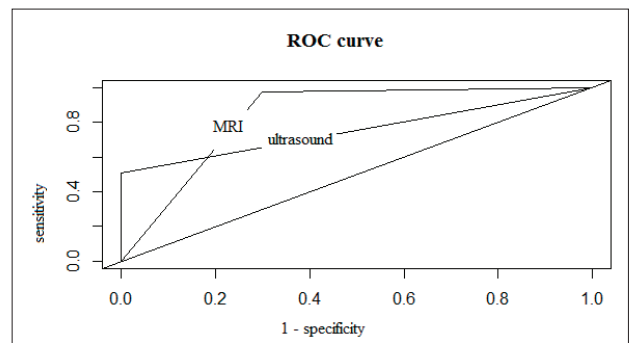


Figure 3. Ultrasound and magnetic resonance imaging (MRI) findings of wall thickening compared to the pathohistological finding.

In addition also were observed ROC curves for ultrasound and MRI, in relation to the pathohistological findings (Figure 3).

Using standard formulas, it is estimated that sensitivity or True Positive Rate for the MRI enterography is TPR = 0.978 and specificity or False Positive Rate equals 0.3 (FPR=0.3).

For ultrasound sensitivity was TPR = 0.51, while the specificity was FPR = 0.

From the above is evident that the sensitivity for MRI enterography due to the bowel wall thickening was 97.8% and specificity 70%, while the sensitivity of ultrasound is 51% and specificity 100%.

For the purpose of comparing the predictive features of one method over the other it was used area under curve (AUC) as a measurement. In most cases, higher AUC values represent better method or better predictive characteristics of the method.

For the determination of the AUC value for ultrasound and MRI, it was obtained for MRI AUC = 0.838 and for ultrasound AUC of a fistula presence.

Lymphadenopathy has been described in ultrasound reports in 13 patients (23.6%). MR enterography has described lymphadenopathy in 29 patients (52.7 %).

Using a statistical program "R" it has been proven that there is a significant difference between the results obtained with ultrasound and MRI findings regarding lymphadenopathy ($V = 180, p = 9,617 \times 10^{-5}$).

4. DISCUSSION

The study confirmed that there is a statistically significant difference between the results obtained by ultrasound examination and MR enterography, which indicates that there is a significant difference between the accuracy of the results of ultrasound findings and the findings of MR enterography.

According to international guidelines, high-resolution ultrasound should be the first diagnostic method in disease assessment and control exams (13, 14). MRI has been increasingly used in the diagnosis making and patients monitoring with inflammatory bowel disease, which is beneficial, and with important features such as are: lack of ionizing radiation, excellent tissue characterization and functional imaging (15).

In comparison with earlier studies where the sensitivity for MR enterography ranges from 83% to 100%, and the specificity between 94% and 100%, while the sensitivity for ultrasound, depending on the studies, ranges from 55% to 94%, and a specificity from 96% to 100%, it was concluded that the obtained results largely correlate with the results of earlier studies, except for the result obtained for specificity in MR enterography, which is somewhat lower than the previous research (16).

By determining the Area under curve (AUC) value for ultrasound and MR enterography, it was additionally confirmed that the predictive properties of MR enterography are better than ultrasound.

In the detection of abscess collections, it was concluded that there was no significant difference between the results obtained with ultrasound and MRI.

In the detection of fistula and lymphadenopathy, it was concluded that there is a significant difference between the results obtained with ultrasound and MRI.

According to Dillman et al. the ultrasound accurately displays the small intestine and mesenteric changes associated with Crohn's disease, and ultrasound findings show a high correlation with MRI findings in this group of patients (17).

Meta-analysis of Donga et al. showed that ultrasound has a high diagnostic accuracy in detecting Crohn's active disease in adults, especially for Crohn's disease of the small intestine (18).

Castiglione et al. concluded that ultrasound and MR enterography are reliable procedures for the diagnosis of Crohn's disease of the small intestine, while MR enterography has being more sensitive for assessment of disease prevalence. Ultrasound can be used as an initial method for patients to be subsequently examined with MR enterography (19).

Ziech et al. concluded that ultrasound and MR enterography have high precision for diagnosing inflammatory

bowel disease in children, but cannot be used to distinguish Crohn's disease from ulcerative colitis (20).

Sato et al. conducted a study whose objective was to compare the ability to detect lesions in Crohn's disease with MR enterography with ileocolonoscopy. It has been concluded that MR enterography can be useful not only for the detection of ulcers but also for the detection of endoscopically verified, milder lesions in Crohn's disease, suggesting the clinical benefit of MR enterography for the detection and monitoring of the disease (21).

Several authors confirmed that the quantitative parameters of conventional MRI sequences, dynamic contrast MRI sequences, and diffusion weighted imaging (DWI) sequences correlate with the histopathology of surgical samples, and that conventional MR enterography can be used to evaluate Crohn's disease activity (22, 23).

From all of the above, it can be concluded that conventional ultrasound is a good orientation method in the initial evaluation of patients with Crohn's disease, and can be used as the initial method for patients to be subsequently examined with MR enterography.

Contrast enhanced MRI enterography provides an excellent assessment for disease activity as well as the complications that accompany it. It has a high sensitivity for changes seen in patients with Crohn's disease, provides detailed morphological and functional informations on small intestinal diseases, and reliable evidence of normality which makes it easier for the diagnosis of early or subtle structural abnormalities, which in the end helps to direct treatment and make decision on further follow up of patients.

- Conflict of interest: None.
- Author Contribution: Each author participated in each step of research and gave final approval for publication.

REFERENCES

1. Kilcoyne A, Kaplan JL, Gee MS. Inflammatory bowel disease imaging: Current practice and future directions. *World J Gastroenterol.* 2016; 22: 917-932.
2. Emami MH, Behbahan IS, Zade HD, Daneshgar H. New interpretation for diagnostic yield of ileoscopy: A prospective study and a brief review. *J Res Med Sci.* 2009; 14: 157-163.
3. Al-Bawardy B, Hansel SL, Fidler JL, Barlow JM, Bruining DH. Endoscopic and radiographic assessment of Crohn's disease. *Gastroenterol Clin North Am* 2017; 46: 493-513.
4. Zerem E. Comment on the article about the evaluation of transabdominal ultrasonography performed by a gastroenterologist in his office: why should not all clinicians use transabdominal ultrasonography on a routine basis? *J Clin Gastroenterol.* 2011; 45: 476-477.
5. Schreyer GA, Menzel C, Friedrich C, Poschenrieder F, Egger L, Dornia C, Schill G, Dendl ML, Schacherer D, Girlich C, Jung ME. Comparison of high-resolution ultrasound and MR-enterography in patients with inflammatory bowel disease. *World J Gastroenterol* 2011; 17: 1018-1025.
6. Rollandi GA, Martinoli C, Conzi R, Cittadini G, Molinari F, Bertolotto M, Talenti A, Curone P. Magnetic resonance imaging of the small intestine and colon in Crohn's disease. *Radiol Med.* 1996; 91: 81-85.
7. Gourtsoyiannis N, Papanikolaou N, Grammatikakis J, Maris T,

- Prassopoulos P. MR enteroclysis protocol optimization: comparison between 3D FLASH with fat saturation after intravenous gadolinium injection and true FISP sequences. *Eur Radiol* 2001; 11: 908-13.
8. Greer ML. How we do it: MR enterography. *Pediatr Radiol* 2016; 46: 818-828.
 9. Ippolito D, Invernizzi F, Galimberti S, Panelli MR, Sironi S. MR enterography with polyethylene glycol as oral contrast medium in the follow-up of patients with Crohn disease: comparison with CT enterography. *Abdom Imaging*. 2010; 35: 563-570.
 10. Siddiki HA, Fidler JL, Fletcher JG, Burton SS, Huprich JE, Hough DM, Johnson CD, Bruining DH, Loftus EV Jr, Sandborn WJ, et al. Prospective comparison of state-of-the-art MR enterography and CT enterography in small-bowel Crohn's disease. *AJR Am J Roentgenol* 2009; 193: 113-121.
 11. Tillack C, Seiderer J, Brand S, Göke B, Reiser MF, Schaefer C, Diepolder H, Ochsenkühn T, Herrmann KA. Correlation of magnetic resonance enteroclysis (MRE) and wireless capsule endoscopy (CE) in the diagnosis of small bowel lesions in Crohn's disease. *Inflamm Bowel Dis*. 2008; 14: 1219-1228.
 12. Costa-Silva L, Brandão AC. MR enterography for the assessment of small bowel diseases. *Magn Reson Imaging Clin N Am* 2013; 21: 365-383.
 13. Travis SP, Stange EF, Lémann M, Oresland T, Chowers Y, Forbes A, D'Haens G, Kitis G, Cortot A, Prantera C, et al. European evidence based consensus on the diagnosis and management of Crohn's disease: current management. *Gut*. 2006; 55 (Suppl 1): 16-35.
 14. Schreyer AG, Ludwig D, Koletzko S, Hoffmann JC, Preiss JC, Zeitz M, Stange E, Herrlinger KR. Updated German S3-guideline regarding the diagnosis of Crohn's disease - implementation of radiological modalities. *ROFO*. 2010; 182: 116-121.
 15. Fidler J. MR imaging of the small bowel. *Radiol Clin North Am*. 2007; 45: 317-331.
 16. Horsthuis K, Bipat S, Bennink RJ, Stoker J. Inflammatory bowel disease diagnosed with US, MR, scintigraphy, and CT: meta-analysis of prospective studies. *Radiology*. 2008; 247: 64-79.
 17. Dillman JR, Smith EA, Sanchez RJ, DiPietro MA, DeMatos-Maillard V, Strouse PJ, Darge K. Pediatric Small Bowel Crohn Disease: Correlation of US and MR Enterography. *Radiographics* 2015; 35: 835-848.
 18. Dong J, Wang H, Zhao J, Zhu W, Zhang L, Gong J, Li Y, Gu L, Li J. Ultrasound as a diagnostic tool in detecting active Crohn's disease: a meta-analysis of prospective studies. *Eur Radiol*. 2014; 24: 26-33.
 19. Castiglione F, Mainenti PP, De Palma GD, Testa A, Bucci L, Pesce G, Camera L, Diaferia M, Rea M, Caporaso N, Salvatore M, Rispo A. Noninvasive diagnosis of small bowel Crohn's disease: direct comparison of bowel sonography and magnetic resonance enterography. *Inflamm Bowel Dis*. 2013; 19: 991-998.
 20. Ziech ML, Hummel TZ, Smets AM, Nievelstein RA, Lavini C, Caan MW, Nederveen AJ, Roelofs JJ, Bipat S, Benninga MA, Kindermann A, Stoker J. Accuracy of abdominal ultrasound and MRI for detection of Crohn disease and ulcerative colitis in children. *Pediatr Radiol*. 2014; 44: 1370-1378.
 21. Sato H, Tamura C, Narimatsu K, Shimizu M, Takajyo T, Yamashita M, Inoue Y, Ozaki H, Furuhashi H, Maruta K, Yasutake Y, Yoshikawa K, Watanabe C, Komoto S, Tomita K, Nagao S, Miura S, Shinmoto H, Hokari R. Magnetic resonance enterocolonography in detecting erosion and redness in intestinal mucosa of patients with Crohn's disease. *J Gastroenterol Hepatol*. 2015; 30: 667-673.
 22. Tielbeek JA, Ziech ML, Li Z, Lavini C, Bipat S, Bemelman WA, Roelofs JJ, Ponsioen CY, Vos FM, Stoker J. Evaluation of conventional, dynamic contrast enhanced and diffusion weighted MRI for quantitative Crohn's disease assessment with histopathology of surgical specimens. *Eur Radiol*. 2014; 24: 619-629.
 23. Imširović B, Zerem E, Efendić A, Mekić Abazović A, Zerem O. Significance of Diffusion Weighted Imaging (DWI) as an improving factor in contrast enhanced MRI enterography in evaluation patients with Crohn's disease. *Med Glas (Zenica)*. 2018; 15(2): (in press).