



## Gastric volvulus presenting as an acute coronary syndrome with long-lasting electrocardiographic changes

Shi-Lin FANG<sup>1</sup>, Ming DENG<sup>2</sup>, Ya-Nan PENG<sup>1</sup>, Chang GAO<sup>1</sup>, Qiu ZHAO<sup>1</sup>, Jing LIU<sup>1\*</sup>,  
Xue-Dong GAN<sup>3,\*</sup>

<sup>1</sup>Department of Gastroenterology, Zhongnan Hospital of Wuhan University; The Hubei Clinical Center & Key Lab of Intestinal & Colorectal Diseases, Wuhan, China

<sup>2</sup>Department of Radiology, Zhongnan Hospital of Wuhan University, Wuhan, China

<sup>3</sup>Department of Cardiology, Zhongnan Hospital of Wuhan University, Wuhan, China

*J Geriatr Cardiol* 2019; 16: 309–312. doi:10.11909/j.issn.1671-5411.2019.03.002

**Keywords:** Acute coronary syndrome; ECG; Gastric volvulus

A sixty-one-year-old male, with a medical history of coronary heart disease and myocardial bridge (not confirmed by cardiac catheterization) in the past three years and a 1-h history of sudden onset nausea, retching, diaphoresis, epigastric discomfort without any chest pain. The electrocardiogram revealed ST elevation myocardial infarction (STEMI) changes (Figure 1A). Urgent cardiac catheterization revealed mild myocardial bridge in the middle of the left anterior descending (LAD) (10% systolic compression) and normal left ventricular function without regional wall motion abnormalities. Three high-sensitivity cardiac troponin I (HSTNT) titers done at 4, 8 and 20 h from the onset of symptoms were HSTNT = 10.5 pg/mL, 10.9 pg/mL, 25.4 pg/mL (less than 26.2) with CK-MB = 3 pg/mL, 18 pg/mL, 13 pg/mL (< 25) and the myoglobin levels were = 34.8 pg/mL, 39.6 pg/mL, 44.5 pg/mL (< 140.1), respectively. Full blood count was mild abnormal, and urine analysis, fecal occult blood, serum electrolytes, D-dimer, renal function tests and liver function tests were normal. Serum amylase was 48 U/L (< 90) and serum lipase was 101 mg/dL (< 70); TSH was 1.5970 μIU/mL (0.35–4.94), free T4 1.01 ng/dL (0.70–1.48) and free T3 2.23 ng/dL (1.71–3.71); fasting blood sugar was 5.46 mmol/L and lipid profile was normal. 2D echocardiogram revealed the following sizes and thickness: left atrium, 21 mm; left ventricle, 34 mm; pulmonary artery, 22 mm; interventricular septal thickness, 9 mm; and left ventricular posterior wall thickness, 9 mm.

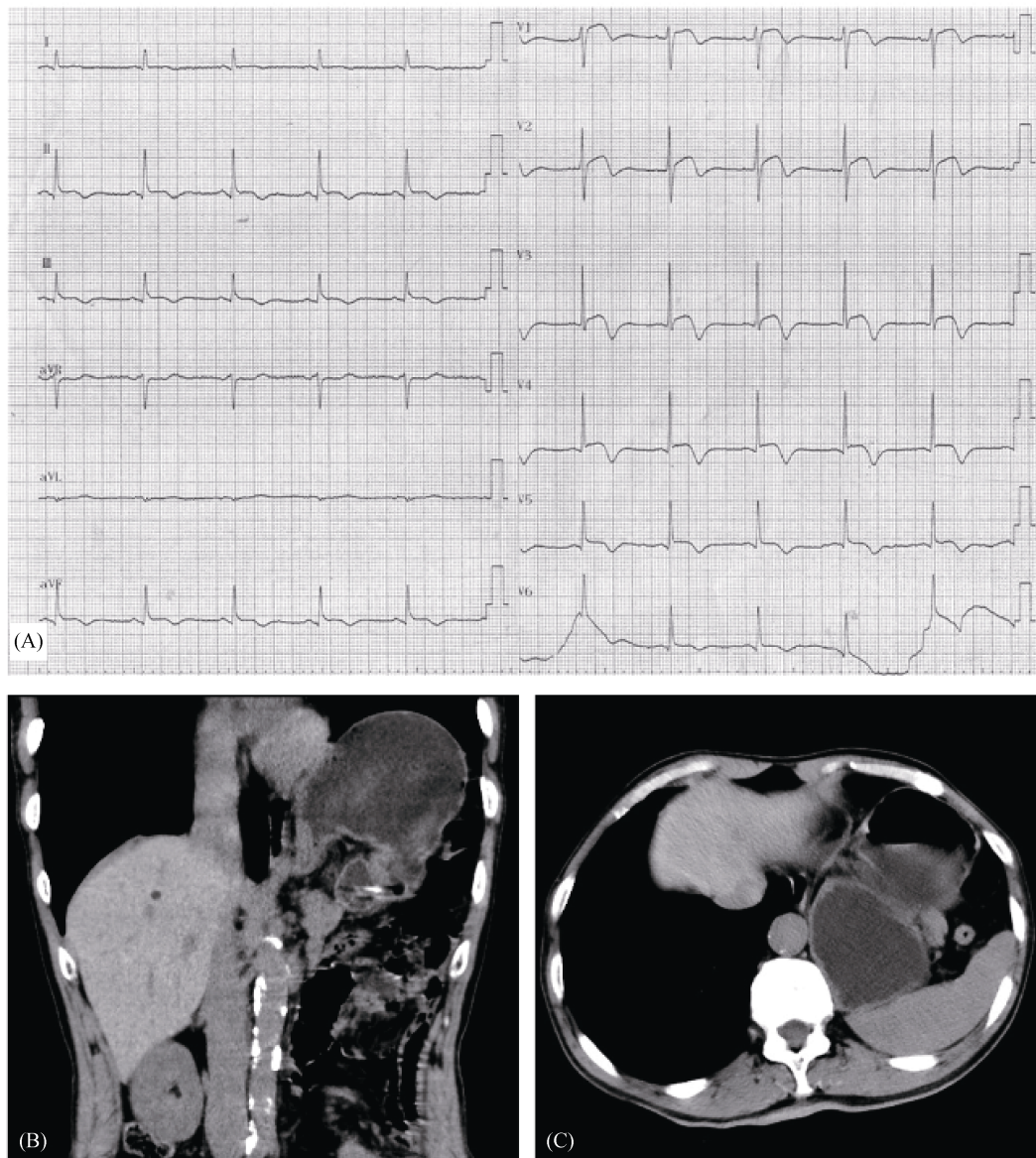
During the first three days of his hospitalization, the patient complained of progressively worsening up-abdominal pain and was sent for a computed tomographic (CT) scan of

the chest and abdomen. The CT scan revealed gastric volvulus with mass effect on the heart, appearing to be twisted along the mesenteroaxial variety, the left diaphragm elevated, and the stomach body was twisted upwards, with an air-fluid level at CT transverse position (Figure 1B & 1C). The patient had subsequently succeeded a conservative approach by endoscopic de-rotation. Within two days, he was discharged home in stable and improved condition.

However, his ECG had not returned to normal. Regardless of the ECG 2-h after cardiac catheterization on the day of admission, we performed ECG in different positions in the standing, supine, and right lateral positions, or the ECG of 1-h before and after endoscopy was not changed much. On the second day after gastroscopy, the chest X-ray showed that the level of the left diaphragm was decreased, but still in the elevated position (Figure 2A). After 22 months of follow-up, the patient complained of intermittent chest tightness, no nausea, chest and abdominal pain and other discomfort. The electrocardiogram prompted the partial lead ST-T segment elevation change (Figure 2C). X-ray angiography of the digestive tract indicated that the gastric volvulus (mesenteroaxial type) changes after the reduction (Figure 2B). The CT scan of the chest revealed remain left elevation of the diaphragm, and gastric wall close to the cardiac apex with mass effect on the heart (Figure 3A & 3B). For the elevation of the diaphragm and the gastric torsion, we consulted the surgical department later. Because the patient has no difficulty in breathing and chest tightness that is difficult to relieve, the surgical restoration of normal anatomic position of the diaphragm and the stomach are not considered at this time. It is recommended to treat it conservatively and observe it dynamically.

\*Correspondence to: dhgxd319@163.com (GAN XD);

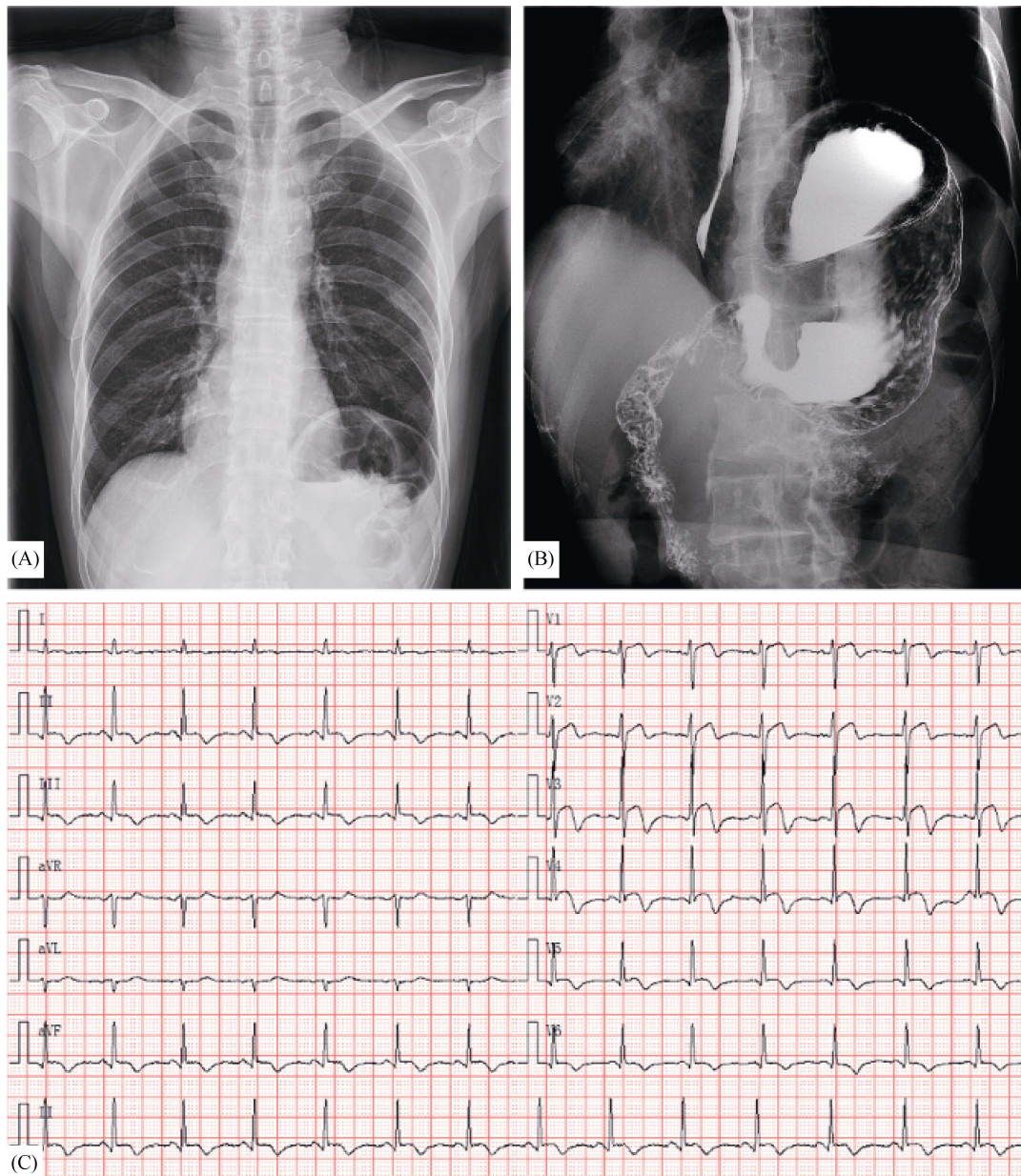
LIU J (liujing\_GI@whu.edu.cn)



**Figure 1.** Emergency ECG at the time of onset (A); computed tomographic axial chest scan showed gastric body manifestations [coronal view (B) and a cross section (C)].

It is generally believed that the stomach is fixed to the cardia and pylorus, as well as the ligaments of large and small curves. Under normal circumstances, the position can be rotated to some extent. However, if it exceeds this level, it causes the displacement of the stomach itself, even the adjacent organs, and the obstacles of the discharge of the stomach contents and a series of physiological changes and clinical symptoms appear, that is, gastric volvulus. There are many causes of gastric volvulus, including overeating, severe vomiting, acute gastric dilatation, gastric ligament relaxation, gastric disease, gastric adjacent organ lesions and so on. According to the direction of twisting, it can be divided into three types: gastric volvulus may exist as an or-

ganoaxial, mesenteroaxial, or a combination of varieties. About 60% of gastric volvulus cases encountered are of the organoaxial variety,<sup>[1]</sup> and our patient belonged to mesenteroaxial type. Typical gastric volvulus is based on the Borchardt triad: sudden onset of chest or epigastric abdominal discomfort, repeated retching, difficulty in placing the stomach tube or inability to insert.<sup>[2]</sup> It seems, however, to have been still pretty rarely in the clinic. Most patients can make an accurate way to diagnose by Upper gastrointestinal barium study,<sup>[3]</sup> CT scan or CT angiography with 3D reconstruction can facilitate the diagnosis.<sup>[3,4]</sup> The reasons for misdiagnosis in this case were that: (1) the patient had a history of heart disease; (2) the episode-upper ab-



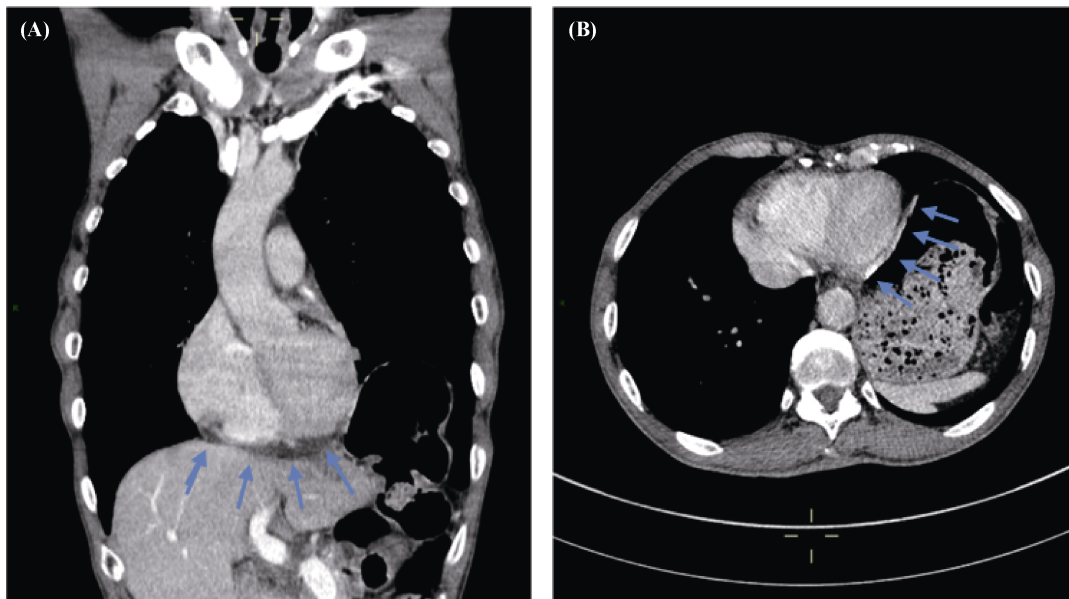
**Figure 2.** Reexamination of diaphragmatic position on chest radiography after endoscopic gastric volvulus repair after admission (A); after 22 months of endoscopic repair, the results of ECG reexamination (B) and X-ray barium meal examination showed (C).

dominal pain, nausea, sweating, and myocardial infarction caused by coronary arterial have some different cause but the same symptoms; and (3) emergency electrocardiogram presented as acute coronary syndrome.

Gastric volvulus itself is rare in clinical practice, and it is even rarer to have changes in ECG. Several possible mechanisms can explain the ECG changes in gastric volvulus, including: (1) change in the position of the heart in the thoracic cavity secondary to gastric volvulus elevated diaphragm; (2) an irritative effect on the pericardial by the twisted stomach; and (3) compression of the coronary arteries by the twisted stomach. In the cases reported in three

literatures,<sup>[5-7]</sup> the patients recorded had esophageal hiatus hernia. No matter whether there was ST segment change in the preoperative ECG, the ECG returned to normal after the surgical torsion repair. In the patient we described here, the ECG had been always abnormal in the ST segment.

ST-T changes can be seen in cardiac hypertrophic cardiomyopathy or myocarditis. 2011 ACCF/AHA guidelines suggest that the thickness of any part of the left ventricular iliac crest is greater than or equal to 15 mm, and there is no other reason to explain the clinical diagnosis of HCM.<sup>[8]</sup> Our patient's 2D echocardiogram revealed normal left ventricular function with normal ejection fraction without any re-



**Figure 3.** Computed tomographic axial chest scan on coronal view (A) and transverse position (B). The twisted gastric wall that was close to the cardiac area with a mass effect on the heart (blue arrows marking the oppressed position).

gional wall motion abnormalities or myocardial hypertrophy. Myocarditis usually has an onset age of 20–50 years old.<sup>[9]</sup> A study showed that 36% of patients had recent history of upper respiratory tract or enteritis.<sup>[10]</sup> ECG changes with regional ST-segment elevation and Q-wave may suggest acute myocardial injury, combined with those patients presenting as normal coronary angiography, myocarditis should be suspected. However, in our patient, the cardiac biomarkers were normal and there was no abnormal echocardiography, and the patient was older, sixty-one-year-old, and he had no pre-infection.

We conclude that when we treat the patients with gastric volvulus, if there are ECG persistent ST changes, patients with chest pain, upper abdominal pain, vomiting, sweating and other symptoms, how to quickly identify acute abdomen & acute coronary syndrome is a question. Timely diagnosis and treatment deserves clinicians' serious consideration.

## References

- 1 Wu MH, Chang YC, Wu CH, *et al.* Acute gastric volvulus: a rare but real surgical emergency. *Am J Emerg Med* 2010; 28: 118.e5–e7.
- 2 Borchardt M. Zur pathologie und Therapie des Magenvolvulus. *Arch Klin Chir* 1904; 74.
- 3 Al-Balas H, Hani MB, Omari HZ. Radiological features of acute gastric volvulus in adult patients. *Clin Imag* 2010; 34: 344–347.
- 4 Larssen KS, Stimec B, Takvam JA, *et al.* Role of imaging in gastric volvulus: stepwise approach in three cases. *Turk J Gastroenterol* 2012; 23: 390–393.
- 5 Sivasankaran S, Kawamura A, Lombardi D, *et al.* Gastric volvulus presenting as an acute coronary syndrome. *Tex Heart Inst J* 2006; 33: 266–268.
- 6 Pichon N. Gastric volvulus with electrocardiographic changes presenting as an acute coronary syndrome. *Intensive Care Med* 2016; 42: 1289–1290.
- 7 Patel JB, Akshintala D, Patel P, *et al.* Intermittent gastric volvulus mimicking acute coronary syndrome. *Am J Med* 2017; 130: e47–e49.
- 8 Gersh BJ, Maron BJ, Bonow RO, *et al.* 2011 ACCF/AHA guideline for the diagnosis and treatment of hypertrophic cardiomyopathy: executive summary: a report of the American College of Cardiology Foundation/American Heart Association Task Force on Practice Guidelines. *Circulation* 2011; 124: 2761–2796.
- 9 Blauwet LA, Cooper LT. *Myocarditis*. *Prog Cardiovasc Dis* 2010; 52: 274–288.
- 10 Caforio AL, Calabrese F, Angelini A, *et al.* A prospective study of biopsy-proven myocarditis: prognostic relevance of clinical and aetiopathogenetic features at diagnosis. *Eur Heart J* 2007; 28: 1326–1333.