

Case Report

Isolated synchondrosis fracture of the atlas presenting as rotatory fixation of the neck: Case report and review of literature

Andrew J. Kobets, Jonathan Nakhla, Arundhati Biswas, Merritt D. Kinon, Reza Yassari, Ira R. Abbott

Leo M. Davidoff Department of Neurological Surgery, Montefiore Medical Center/Albert Einstein College of Medicine, Bronx, New York, USA

E-mail: *Andrew J. Kobets - Akobets@Montefiore.org; Jonathan Nakhla - Jonathan.Nakhla@gmail.com; Arundhati Biswas - Arundhati.Biswas@gmail.com; Merritt D. Kinon - Mkinon@montefiore.org; Reza Yassari - Yassari@montefiore.org; Ira R. Abbott - Rickabbo@Montefiore.org

*Corresponding author

Received: 26 July 16 Accepted: 28 September 16 Published: 26 December 16

Abstract

Background: Exclusive to the pediatric population, cartilaginous fractures of the atlas are singularly rare. Rarer still are those fractures that produce a fixed, rotational deficit of the neck. Here, the authors present the case of a 4-year-old boy with an isolated fracture of the anterior synchondrosis of C1 with a rotational component following a fall, as well as a review of the literature. Management with serial bedside manipulation, which is unique to our report, helped conservatively correct the rotation of the patient's neck, and, coupled with rigid bracing, demonstrated a comprehensive management strategy that resulted in fracture ossification at 3 months.

Case Description: Our patient is a 4-year-old boy who fell from a bunk bed and complained of severe neck pain. The patient was brought to the emergency room and was found to have an isolated anterior fracture of the right frontal synchondrosis of the atlas. After conservative management with a hard collar and cautious manual reductions at the bedside, rotation of our patient's neck spontaneously resolved on day 3. After 3 months of rigid immobilization, the patient remained at neurological baseline and his fracture was healed. Literature review demonstrated age range between 2 and 6 years, with a subset of patients demonstrating rotational components to their fractures. Complete resolution of nearly all patients treated with rigid immobilization after fracture was documented, yet several patients experienced delayed diagnosis.

Conclusions: Knowledge of the radiographic appearance of the C1 ossification centers as well as the normal timeline and sequence of ossification is essential in differentiating a true synchondrosis fracture from normal, nonossified cervical cartilage. With early diagnosis, immobilization, pain control, and muscle relaxants, patients can recover well with conservative management, can successfully ossify fracture sites, and can recover without sequelae.

Key Words: Atlas, C1, fracture, rotational deformity, synchondrosis, trauma

Access this article online**Website:**www.surgicalneurologyint.com**DOI:**

10.4103/2152-7806.196768

Quick Response Code:

This is an open access article distributed under the terms of the Creative Commons Attribution-NonCommercial-ShareAlike 3.0 License, which allows others to remix, tweak, and build upon the work non-commercially, as long as the author is credited and the new creations are licensed under the identical terms.

For reprints contact: reprints@medknow.com

How to cite this article: Kobets AJ, Nakhla J, Biswas A, Kinon MD, Yassari R, Abbott IR. Isolated synchondrosis fracture of the atlas presenting as rotatory fixation of the neck: Case report and review of literature. *Surg Neurol Int* 2016;7:S1092-5.

<http://surgicalneurologyint.com/Isolated-synchondrosis-fracture-of-the-atlas-presenting-as-rotatory-fixation-of-the-neck-Case-report-and-review-of-literature/>

INTRODUCTION

Isolated fractures of the anterior synchondroses of the atlas are rare. Following traumatic axial loading on the atlas, patients often present in a delayed fashion with pain, limited range of motion, and muscle spasm without focal neurological deficits. In addition, a small subset of patients present with fixed, rotatory subluxation of the neck (e.g. “cock robin” position).^[3]

Understanding the normal anatomic development of the atlas and its ossification centers assists in differentiating true fractures from yet unfused synchondroses or unstable fractures. In several case reports, fractures were missed, resulting in delayed diagnosis and worsening symptoms.^[1,3,5,9] This report demonstrates how to prevent these complications and outlines a management strategy to minimize morbidity and optimize fusion rates of these fractures.

CASE PRESENTATION

A 4-year-old male presented with complaints of severe neck pain after jumping from the top bed of a bunk-bed and landing on his head. He experienced no loss of consciousness or neurological deficit but demonstrated a fixed rotation of the neck to the left (e.g. cock-robin appearance). He was placed in a hard cervical collar and a computed tomography (CT) scan of the cervical spine demonstrated asymmetric widening the C1 arch, 4 mm to the right, with a fracture through the right C1 synchondrosis [Figure 1]. Three-dimensional reconstruction demonstrated mild displacement of the C1 vertebra to the left [Figure 2]. The short T1 inversion recovery (STIR) magnetic resonance imaging (MRI) showed an increased signal around C1, reflecting edema in the cartilaginous tear [Figure 3].

The patient was managed conservatively with nonsteroidal anti-inflammatory drugs (NSAIDs) and valium to help reduce the rotation; minor manipulation consisting of manual reduction of the rotation was attempted daily at the bedside. After 3 days of observation and manipulation, he was discharged home after a repeat CT confirmed stability/spontaneous reduction. He was treated in a hard collar for 3 months; at which point the CT showed no fracture or subluxation. At 6-month follow-up, he was pain-free, neurologically intact, and returned to his regular level of activity. Subsequent follow-up imaging showed complete resolution of the synchondrosis fracture.

DISCUSSION

Frequency of pediatric atlas fractures

Pediatric cervical spine injuries account for 1.9–9.5% of all cervical spine injuries and few reports document atlas,

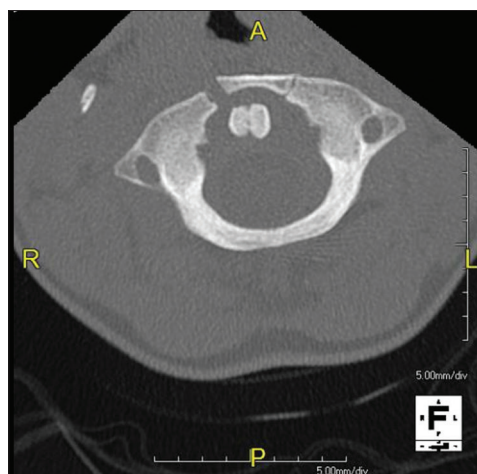


Figure 1: Anterior right synchondrosis fracture with 4 mm displacement. Normal left synchondrosis

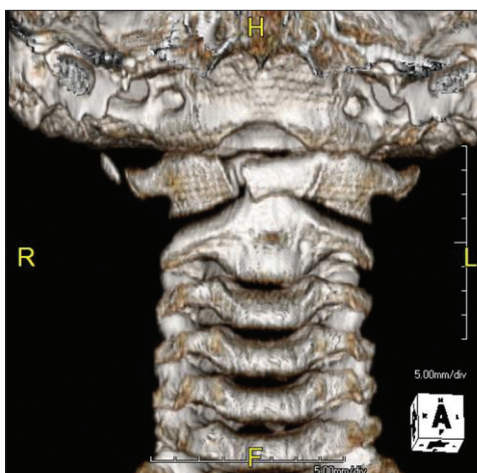


Figure 2: Three-dimensional reconstruction demonstrates a right synchondrosis fracture with inferior rotation of the fracture segment

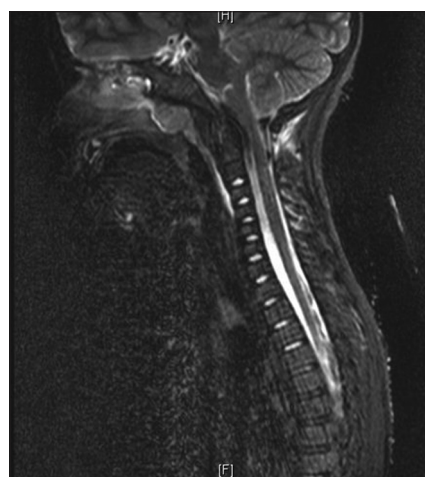


Figure 3: Sagittal T2 STIR MRI demonstrating prevertebral soft tissue hyperintensity anterior to the upper cervical vertebrae

isolated atlas, and synchondrosis fractures in children [Table 1]. These lesions are rare and occur due to the relative increased laxity of ligaments in children, increased neck flexibility, and greater elasticity of their synchondroses.

Ossification of the anterior arch of C1

Although reports of C1 arch ossification *in-utero* have been noted, ossification of the anterior arch of C1 typically begins between 1 and 22 months of age.^[7] Discrete anterior ossification centers first appear between 6 months and 2 years of age and form cartilaginous bridges between the anterior arches by 6 years of age. Based on the radiographic analysis of 841 patients, ossification of both anterior synchondroses begins by median 5.2 years (range: 4–6.3 years) of age, and is completed at 8.5 years (range: 5.5–13 years).^[7] In 129 CT scans of patients up to 18 years of age, the oldest patient with still apparent neurocentral synchondroses was 7 years old. Asymmetry of the degree of ossification was seen in 7.2% of patients; accessory neurocentral synchondroses were also noted along with anterior midline synchondroses (20% of patients). Furthermore, the widths of anterior neurocentral synchondroses decrease with increasing patient age (e.g., with $r^2 = 0.85$ for these two measures).

History of pediatric Jefferson’s fractures

In 1920, Jefferson’s first series of 46 C1 fractures included one child. Marlin and Williams, Galindo and Francis, Richards, and Wirth in the 1980s demonstrated that pediatric C1 fractures involving both the anterior and posterior arches. Later, isolated fractures of the anterior arch of the atlas through the synchondrosis were documented.^[4,5]

Etiology of pediatric C1 fractures

As in this study, several cases of pediatric C1 fractures have been attributed to trauma to the vertex of the

heads.^[1] Reilly described a 6-year-old child who after a fall developed a hinged, left synchondrosis fracture displaced 6 mm anteriorly; it reduced with digital transoral closed reduction.^[8] Realignment of the arch occurred upon follow-up with rigid stabilization. However, transoral reduction may not be necessary.

Imaging studies can miss pediatric C1 fractures

Pediatric C1 synchondrosis fractures may be mistaken for persistent lateral synchondroses.^[1,10] If missed, patients may develop progressive diastases of the anterior arch of C1 and develop increased pain or neurological deterioration. Identifying soft tissue swelling or asymmetry of the atlas relative to the axis is helpful to differentiate true fractures from yet unossified cartilage. Therefore, an MRI in addition to X-rays and CT scans may be needed to better identify subtle findings consistent with ligamentous injury.

Bracing of pediatric C1 fractures

Rigid immobilization for 6 weeks has been used successfully for isolated anterior C1 arch fractures. In Hagino’s report (2006), an isolated anterior arch synchondrosis fracture with atlantoaxial rotatory fixation fused after 5 weeks of in-patient treatment and 2 months of outpatient bracing.^[3]

CONCLUSIONS

This report describes an isolated anterior synchondrosis fracture of the atlas in a 4-year old male. Conservative management consisting of gentle manipulation and bracing resulted in complete ossification. Early diagnosis with X-rays, CT, and MRI, along with immobilization are keys to avoiding further potential neurological sequelae.

Table 1: Characteristics of 11 cases of isolated anterior synchondrosis fractures of C1

Study	Patient Gender/ Age	Delayed Diagnosis?	Fracture Type	Rotational component?	Treatment Type	Treatment Duration	Outcome
AuYoung, 2009 ^[11]	1. F/5, 2.F/30mo.	1. Yes 2. No	1. Anterior Midline 2. Anterior Midline	1. No 2. No	1.Hard Collar 2.Hard Collar	1. 3 months 2. 9 weeks	Complete Resolution
Hagino, 2006 ^[3]	F/4	Yes	Left Neurocentral	No	Halter Traction, Hard Collar	1 month, then 9 weeks	Complete Resolution
Judd, 2000 ^[4]	M/6	No	Left Neurocentral	No	Malibu Collar	2 months	Complete Resolution
Kapoor, 2003 ^[5]	M/21mo.	Yes	Anterior Midline	No	Halter Traction, Hard Collar	3 weeks, then 6 weeks	Complete Resolution
Reilly, 2005 ^[8]	M/6	No	Left Neurocentral	Yes	Halo Vest	unknown	Complete Resolution
Thakar, 2005 ^[9]	M/5	Yes	Right Neurocentral	No	Hard Collar	6 weeks	Complete Resolution
Turk, 2012 ^[10]	F/4	No	Right Neurocentral	No	Hard Collar	unknown	Complete Resolution
Mikawa, 1987 ^[6]	M/4	Yes	Left Neurocentral	Yes	Halter Traction, Hard Collar	3 weeks, then 2 months	Complete Resolution
Bayar, 2002 ^[2]	F/2	Yes	Left Accesory Neurocentral	Yes	Hard Collar	3 months	Complete Resolution
Present Study	M/4	No	Right Neurocentral	Yes	Hard Collar	3 months	Complete Resolution

Financial support and sponsorship

Nil.

Conflicts of interest

There are no conflicts of interest.

REFERENCES

1. AuYong N, Piatt J. Jefferson fractures of the immature spine. Report of 3 cases. *J Neurosurg Pediatr* 2009;3:15-9.
2. Bayar MA, Erdem Y, Ozturk K, Buharali Z. Isolated anterior arch fracture of the atlas: Child case report. *Spine* 2002;27:E47-9.
3. Hagino T, Ochiai S, Tonotsuka H, Tokai M, Senga S, Hamada Y. Fracture of the atlas through a synchondrosis of the anterior arch complicated by atlantoaxial rotatory fixation in a four-year-old child. *J Bone Joint Surg Br* 2006;88:1093-5.
4. Judd DB, Liem LK, Petermann G. Pediatric atlas fracture: A case of fracture through a synchondrosis and review of the literature. *Neurosurgery* 2000;46:991-4.
5. Kapoor V, Watts B, Theruvil B, Boeree NR, Fairhurst J. Delayed displacement of a paediatric atlas fracture through the synchondrosis after minor trauma. *Injury* 2004;35:1308-10.
6. Mikawa Y, Watanabe R, Yamano Y, Ishii K. Fracture through a synchondrosis of the anterior arch of the atlas. *J Bone Joint Surg Br* 1987;69:483.
7. Piatt JH Jr, Grissom LE. Developmental anatomy of the atlas and axis in childhood by computed tomography. *J Neurosurg Pediatr* 2011;8:235-43.
8. Reilly CW, Leung F. Synchondrosis fracture in a pediatric patient. *Can J Surg* 2005;48:158-9.
9. Thakar C, Harish S, Saifuddin A, Allibone J. Displaced fracture through the anterior atlantal synchondrosis. *Skeletal Radiol* 2005;34:547-9.
10. Turk G, Kabakus IM, Akpınar E. Fracture of the Atlas through a Synchondrosis of Anterior Arch. *Case Rep Radiol* 2013;2013:934135.