



Since January 2020 Elsevier has created a COVID-19 resource centre with free information in English and Mandarin on the novel coronavirus COVID-19. The COVID-19 resource centre is hosted on Elsevier Connect, the company's public news and information website.

Elsevier hereby grants permission to make all its COVID-19-related research that is available on the COVID-19 resource centre - including this research content - immediately available in PubMed Central and other publicly funded repositories, such as the WHO COVID database with rights for unrestricted research re-use and analyses in any form or by any means with acknowledgement of the original source. These permissions are granted for free by Elsevier for as long as the COVID-19 resource centre remains active.

REVIEW ARTICLE

From ARDS to pulmonary fibrosis: the next phase of the COVID-19 pandemic?



JACOB E. MICHALSKI, JONATHAN S. KURCHE, and DAVID A. SCHWARTZ

AURORA, COLORADO

While the coronavirus disease 19 (COVID-19) pandemic has transformed the medical and scientific communities since it was first reported in late 2019, we are only beginning to understand the chronic health burdens associated with this disease. Although COVID-19 is a multi-systemic disease, the lungs are the primary source of infection and injury, resulting in pneumonia and, in severe cases, acute respiratory distress syndrome (ARDS). Given that pulmonary fibrosis is a well-recognized sequela of ARDS, many have questioned whether COVID-19 survivors will face long-term pulmonary consequences. This review is aimed at integrating our understanding of the pathophysiologic mechanisms underlying fibroproliferative ARDS with our current knowledge of the pulmonary consequences of COVID-19 disease. (Translational Research 2022; 241:13–24)

INTRODUCTION

The coronavirus disease 19 (COVID-19) pandemic has reshaped numerous aspects of the medical and scientific communities in an unprecedentedly brief period of time. A surge in research has quickly created a greatly expanded understanding of the epidemiologic characteristics and acute clinical manifestations caused by severe acute respiratory syndrome coronavirus 2 (SARS-CoV-2) infection^{1,2}; however, the chronic consequences of this disease are only now beginning to emerge.³⁻⁵ Although COVID-19 is a multi-systemic disease,⁶⁻¹² the lungs are the primary source of infection and injury, resulting in

pneumonia and, in severe cases, acute respiratory distress syndrome (ARDS).

Given that pulmonary fibrosis is a well-recognized sequela of ARDS,¹³⁻¹⁷ since nearly the onset of the pandemic concerns have been raised regarding the possible chronic pulmonary consequences of SARS-CoV-2 infection.¹⁸⁻²¹ While long-term pulmonary complications for ARDS have been dramatically reduced with vastly improved disease management including the advent of lung-protective ventilation strategies,^{13,22} the sheer magnitude of patients affected by COVID-19-related ARDS has only amplified these concerns. There is growing evidence that a substantial portion of COVID-19 survivors continue to have persistent physiologic impairments with accompanying radiologic findings months after recovery,²³⁻³¹ which parallels established outcomes from the severe acute respiratory syndrome (SARS),³² Middle East respiratory syndrome (MERS),³³ and influenza A outbreaks.³⁴ Moreover, for some of the most vulnerable populations to COVID-19, including those with pre-existing lung disease and the elderly, even a small degree of pulmonary effects from COVID-19 could have devastating consequences for quality of life in these populations.

In this review, we discuss ARDS in the setting of COVID-19, and summarize our current understanding

From the Department of Medicine, University of Colorado School of Medicine, Aurora, Colorado; Medicine Service, Pulmonary Section, Rocky Mountain Regional VA Medical Center, Aurora, Colorado; Department of Immunology and Microbiology, University of Colorado School of Medicine, Aurora, Colorado.

Submitted for Publication August 2, 2021; revision submitted September 12, 2021; Accepted for Publication September 14, 2021.

Reprint requests: David A. Schwartz, MD, University of Colorado School of Medicine, 12631 East 17th Avenue, B178, Aurora, CO 80045. e-mail: david.schwartz@ucdenver.edu.

1931-5244/\$ - see front matter

© 2021 The Authors. Published by Elsevier Inc. This is an open access article under the CC BY-NC-ND license

(<http://creativecommons.org/licenses/by-nc-nd/4.0/>)

<https://doi.org/10.1016/j.trsl.2021.09.001>

of pulmonary fibrosis resultant from ARDS. Furthermore, we discuss the mechanisms driving the fibrotic phase of ARDS in the context of our understanding of progressive fibrosing lung diseases such as idiopathic pulmonary fibrosis (IPF). Finally, we examine the emerging evidence of chronic pulmonary consequences of severe COVID-19 and speculate on the management of post-ARDS COVID-19 patients.

ARDS AND COVID-19

While clinical definitions of ARDS have evolved over time since its initial description in the 1960s,³⁵ the 2012 Berlin criteria center the definition of ARDS as new or worsening respiratory failure with hypoxemia and alveolar infiltrates in the setting of critical illness and the absence of heart failure as a sole cause.³⁶ At the microscopic level this correlates with the histologic pattern referred to as diffuse alveolar damage (DAD) which comprises a constellation of findings including alveolar edema, hyaline membrane formation, and inflammatory infiltrates in the acute phase.³⁷⁻³⁹ ARDS is the most frequent complication of severe COVID-19 disease and is highly prevalent among fatal cases. A substantial proportion of individuals hospitalized for COVID-19 progress to ARDS, up to 40% in some cohorts, and development of ARDS remains one of the highest predictors of mortality in COVID-19.^{2,40,41} ARDS caused by COVID-19 as compared to non-COVID-19 etiologies has been demonstrated to share similar features, including respiratory mechanics.⁴²⁻⁴⁴ The estimated number of COVID-19 cases surpassing 180 million worldwide by mid-year 2021 and the proportion of most severe COVID-19 cases of approximately 5%, this will equate to millions of survivors of ARDS due to SARS-CoV-2.

The mortality of ARDS has been reduced by the introduction of standardized management, including conservative fluid management⁴⁵ and lung-protective ventilation,²² though there remains a subset of ARDS survivors who experience persistent pulmonary and extra-pulmonary consequences for years after recovery.⁴⁶⁻⁴⁹ Identified risk factors for increased severity of these long-term consequences include increasing age, the severity of the acute illness, duration of mechanical ventilation, and pulmonary-specific causes of ARDS.⁴⁵

Substantial concern for long-term pulmonary sequelae of SARS-CoV-2 infection has emerged from our previous experience with coronaviruses, namely the 2003 SARS and 2012 MERS outbreaks. The frequency of ARDS among SARS patients was comparable to the rate seen among cohorts of hospitalized patients with COVID-19.^{32,50,51} At 6-month follow-up

after hospitalization for SARS infection, the frequency of pulmonary function deficits and radiologic abnormalities, including evidence of fibrosis like parenchymal banding and traction bronchiectasis, directly correlated with initial disease severity. Furthermore, subsets of SARS survivors followed for up to 2 years had persistent changes in pulmonary function.⁵⁰ Similar observations have been seen in MERS patients in which increased age and critical illness are correlated with increased restrictive lung deficits and radiologic abnormalities indicative of fibrosis.³³ Survivors of the pandemic 2009 H1N1 strain of the influenza A virus also experienced significant rates of post-ARDS fibrosis which persisted through at least 6 months after hospitalization.³⁴ While these data offer insight into the incidence of pulmonary sequela in viral ARDS survivors, they are limited in their exploration of the natural history of these findings including whether they remained persistent beyond the follow-up timeframe. However, taken together these data outline the consequences from other viral causes of ARDS and underline the importance for understanding ARDS-induced pulmonary fibrosis in the era of COVID-19.

PATHOGENESIS OF ARDS-INDUCED FIBROSIS

ARDS has been recognized as a clinical entity since its first description over 50 years ago, and our understanding of ARDS pathogenesis has continuously changed and remains an actively evolving area of investigation.⁵²⁻⁵⁴ Traditionally, ARDS has been thought of as a series of sequential pathobiologic phases which are believed to encompass the scope of the response of the distal airspace to an injurious insult. The exudative phase of ARDS is the initial response to acute lung injury causing disruption of the alveolar epithelial-endothelial barrier in which edematous flooding of the alveolar and interstitial compartments occurs. Secondly, the proliferative phase ensues in an attempt to repair injury through re-establishment of the alveolar barrier with clearance of exudative fluid. While there have been remarkable advances in revealing the complex mechanisms underlying these initial phases of ARDS, the third, fibrotic phase has continued to remain poorly understood.¹³

The degree of fibroproliferation in ARDS has been intimately linked with poor prognosis, including increased mortality and ventilator dependence.¹³ Still, it remains unclear why most patients with ARDS are able to recover from the initially inflammatory process while a subset undergoes an excessive fibrotic response that can persist radiographically for months to years after ultimate recovery and is correlated with loss of quality of life and pulmonary dysfunction.⁴⁹

As our understanding of the drivers of excessive fibroproliferation in severe ARDS continues to advance, our overall understanding of the underpinnings of lung fibrosis has exponentially grown, particularly in the context of progressive fibrosing diseases like idiopathic pulmonary fibrosis (IPF).⁵⁵⁻⁵⁹ Furthermore, decades of research have demonstrated that while there are undoubtedly differences between subtypes of pulmonary fibrosis, such as that seen following ARDS and in chronic diseases like IPF, the foundational mechanisms of pulmonary fibrosis are often shared. In fact, the most commonly used animal models of pulmonary fibrosis, including the bleomycin model, utilize acute lung injuries in a similar manner to which we conceptualize fibroproliferative disease in ARDS. Thus, while IPF and fibroproliferative ARDS are distinct entities, the underlying pathobiology of these diseases almost certainly share similarities. Here we discuss the overall pathophysiologic mechanisms linked to pulmonary fibrosis and their potential implications in ARDS-associated fibrosis, and more specifically that caused by SARS-CoV-2 lower respiratory tract infection.

Epithelial injury. The most widely accepted hypothesis for pulmonary fibrosis pathogenesis begins with epithelial cell injury which subsequently triggers a fibroproliferative cascade.^{56,57-59} The alveolar epithelium is comprised of 2 distinct cells: Type I and type II alveolar epithelial cells (AECs).⁶⁰ Type I AECs form the vast majority of the surface area of the alveolus, forming the air-blood interface with the underlying interstitium and capillary system. Type II AECs are considered the stem cell of the distal lung and are responsible for surfactant production and re-epithelization of the bronchoalveolar epithelium after injury.⁶¹

In ARDS, the initial insulting injury results in loss of epithelial barrier function through destruction of the relatively fragile alveolar-endothelial interface. In extra-pulmonary causes of ARDS, this epithelial injury is likely caused by inflammation and oxygen toxicity that can induce alveolar cell death, loss of negatively-charged glycocalyx, and accumulation of protein-rich alveolar edema.⁶² In pulmonary-specific causes of ARDS, like lower respiratory tract infections by viruses and bacteria, pathogens can have multiple effects on alveolar epithelial cells leading to both direct and indirect cytotoxicity. In the case of SARS-CoV-2, the virus itself has been shown to have the highest infectivity in type II alveolar cells due to their specific expression of the ACE2 receptor,⁶³⁻⁶⁵ which follows a decreasing expression gradient down the respiratory tract from nasopharynx to alveoli. This direct viral-mediated cell death of the stem cell population impairs bronchoalveolar epithelial repair, surfactant production, and almost certainly drives progression of severe COVID-

19 towards ARDS pathology. Furthermore crosstalk between the alveolar epithelium and other lung cells including fibroblasts and the endothelium, such as increased expression of tissue factor,⁶⁶ certainly drives COVID-19-associated ARDS severity.

Depletion of the alveolar stem cell population and activation of aberrant repair processes has long been speculated to lead to pulmonary fibrosis in diseases such as IPF.^{67,68} In animal models, modulating type II AEC intracellular stresses by inducing aberrant mucin expression,⁶⁹ increasing endoplasmic reticulum stress,⁷⁰ and inducing local tissue hypoxia^{71,72} exacerbate the fibrotic response likely through impairment of the normal repair process. Directed type II AEC cell death through both programmed and non-programmed means also increases experimental fibrosis.^{73,74} This shared origin of epithelial injury between COVID-19-related ARDS and diseases such as IPF likely represents a unifying aspect of pulmonary fibrosis. Given the relatively high infectivity of the SARS-CoV-2 virus towards type II AECs, this may also explain why others have described COVID-19-related ARDS as distinct from other types of ARDS, given its apparent severity. Furthermore, given the connection between the degree of epithelial injury and subsequent fibrosis, these associations could be indicative of a more severe manifestation of post-ARDS fibrosis than that seen in other virally-mediated etiologies.

Although pulmonary fibrosis pathobiology has been focused on interactions within the alveolus, there is a growing understanding of the role of the distal airway epithelium.^{55,75,76} The distal airway is known to be essential to alveolar repair after severe injury and it is hypothesized that dysregulation of this repair pathway may be related to distal airspace remodeling, including bronchiolization and honeycombing, seen in pulmonary fibrosis.^{55,77} Even though ARDS has also been thought of as a disease of the alveolar-capillary interface, SARS-CoV-2 is capable of infecting both alveolar and airway epithelial cells,^{63,64} and the pro-inflammatory signature produced by distal airway infection has been linked to COVID-19 disease severity and ARDS.⁷⁸ Given that intra-airway inflammatory signatures are known to induce pulmonary fibrosis, it remains to be seen whether infection of the distal airway epithelium correlates with post-inflammatory fibrosis.

Endothelial injury. In addition to epithelial injury, disruption of the endothelium lining the air-blood barrier is recognized as a provoking insult that can initiate ARDS pathogenesis.^{79,80} The subsequent pulmonary edema has been demonstrated to be involved in initiating repair pathways that may become altered and pushing the lung towards excessive fibroproliferation.⁸¹ Given the substantial effects that SARS-CoV-2 infection has on the endothelium including pulmonary

capillaries, including complement deposition and microthrombosis,⁸² vascular damage is likely even more severe in ARDS due to COVID-19 compared to other causes.^{83,84}

Vascular changes are also obvious within chronic fibrosing lung diseases like IPF.^{85,86} Microvascular leak and increased endothelial permeability are observed within IPF lungs and have been linked to pulmonary fibrosis pathogenesis. Alveolar edema is typically resolved after lung injury, but persistent vascular leak is hypothesized to exacerbate the pro-fibrotic environment within the distal lung and has been demonstrated to increase fibrosis in animal models.⁸⁷ Persistence of fluid within the airspace also distorts the architecture of the alveolus imparting mechanical forces which impair a return to homeostasis.

It is reasonable to extrapolate that severe ARDS in which fluid remains persistent in the alveolus for extended periods of time, likely well past the acute phase of illness, can further exacerbate the fibroproliferative cascade in an accelerated manner compared to what is observed in slowly progressive lung diseases.

Cellular senescence. Accelerated aging and cellular senescence have long been implicated in pulmonary fibrosis, and a variety of mechanisms have been associated including both genetic and environmental factors.^{88,89} In human tissue,^{88,90-92} animal models,^{88,92} and in vitro cultures,⁹³ markers of cellular senescence are increased in pulmonary fibrosis, and this increase is conserved across multiple cell types including epithelial cells and fibroblasts.^{94,95} Additionally, genetic variants in at least 5 telomere related genes which functionally shorten telomere length have been associated with increased risk of IPF.⁹⁶⁻¹⁰³ Even without these telomere-shortening mutations, IPF patients have telomeres that are shorter than age-matched controls.¹⁰³ Telomere shortening is intimately linked to activation of cellular senescence, and it has been speculated that this premature activation of cellular senescence in IPF tissue may impair normal regenerative processes and drive fibroproliferation. A recent study examining COVID-19 patients at 4-month follow-up after hospitalization found that age-adjusted telomere length was independently associated with the presence of fibrotic-appearing radiographic abnormalities.¹⁰⁴ Recent studies have also highlighted the persistence of transitional epithelial cell types within the IPF lung and in pulmonary fibrosis animal models that express typical features of cellular senescence.¹⁰⁵⁻¹⁰⁷ Interestingly, these transitional cell types are also enriched within COVID-19-injured lungs and may contribute to the overall senescent and fibrotic phenotype.¹⁰⁸ This is further evidence that the pathogenesis of pulmonary fibrosis associated with chronic diseases like IPF and acute illness like COVID-19-induced ARDS share overlapping features.

Mechanical injury. The mechanical forces applied to the alveolus are intrinsic to proper lung function and distortion of these forces via overdistention of alveolar spaces can lead to barotrauma and furthering of lung injury. Our understanding of ventilator-induced lung injury (VILI), particularly from ventilating the lungs at inappropriately high volumes, is inherently tied to our understanding of ARDS, as low volume ventilation strategies reduce mortality and have become the mainstay of management.^{109,110}

Post-ARDS fibrosis also has an association with ventilator use and VILI. Increased pulmonary deficits and radiologic findings after ARDS have been strongly correlated with duration of mechanical ventilation.⁴⁸ Additionally, dramatic reduction in post-ARDS pulmonary effects has been demonstrated with the near universal adoption of lung protective ventilation strategies.²² This suggests that ARDS-induced fibrosis can be exacerbated through application of excessive mechanical forces to the alveolus. Early reports on COVID-19-associated lung injury was atypical of classical ARDS with COVID-19 patients having markedly higher lung compliances than other ARDS patients.¹¹¹⁻¹¹³ However, as many have since reinforced, ARDS itself is a heterogenous syndrome with multiple subtypes that can be grouped in many ways whether it be due to etiology, physiologic changes, or immunologic responses.^{42-44,114-117} Several groups have associated lower lung compliance with higher mortality,^{43,44,118} and it remains possible that early increase in lung stiffness drives further fibrotic lung remodeling. Given this widespread uncertainty around management of COVID-19-related ARDS in the early stages of the pandemic, less rigorous use of lung-protective ventilation may be contributing to worsened fibroproliferation.

There is compelling evidence that mechanical distortion of alveolar spaces is involved in IPF pathogenesis as well.^{119,120} Alveolar decruitment and collapse induration have been implicated in animal models of pulmonary fibrosis and observed in IPF lungs. Interestingly collapse induration has been observed in patients with COVID-19 and is hypothesized to represent one of the initiating steps in the subsequent fibroproliferative response.¹²¹⁻¹²³ Mechanical stretching of alveolar spaces has also been demonstrated to directly activate pro-fibrotic signaling cascades and induced programmed cell death in type II AECs and may account for the peripheral distribution of fibrosis in IPF.¹²⁴⁻¹²⁶ Hypoxia resultant from the mechanical distortion and collapse of alveolar spaces further compounds this injury and exacerbates pro-fibrotic responses.^{127,128} Thus, mechanical injury is inherent to ARDS and pulmonary fibrosis and may link these 2 processes whereby worsening mechanical distortion of the pulmonary architecture seen in ARDS exacerbates these positive feedback loops towards furthering fibrotic remodeling.

Extracellular matrix biology. The ultimate outcome of the fibrotic cascade is the deposition of extracellular matrix (ECM) which stiffens and distorts the pulmonary architecture resulting in restrictive lung deficits. While the ECM was traditionally thought of as an inert substance that represented the end product of fibroblast activation, it is now understood that interactions between ECM and its surrounding cells have a complex interplay in pulmonary fibrosis pathogenesis.¹²⁹⁻¹³³ In particular, increases in lung stiffness have been shown to direct cellular activation, differentiation, and migration to further exacerbate the pro-fibrotic environment.¹³⁴⁻¹³⁷ In severe cases of ARDS in which the proliferative phase is more exaggerated, decreased compliance of the parenchymal tissue may further activate the fibrotic response leading to the dramatic fibrosis that occurs in a subset of patients.

Interactions between cell adhesion molecules and underlying ECM has also been a productive area of investigation in IPF biology. Integrins, which bind the basal surface of cells to the ECM, have been sought as possible therapeutic targets for their known secondary function in activating latent transforming growth factor- β bound within the ECM.¹³⁸⁻¹⁴⁰ The SARS-CoV-2 virus is able to bind integrins via a conserved motif near its receptor binding domain. Although the functional consequence of viral particles binding to membrane-bound integrins is not entirely clear, it has been demonstrated to increase viral entry into cells.¹⁴¹⁻¹⁴⁴ One integrin in particular, $\alpha v\beta 6$, appears to have relatively high affinity for the SARS-CoV-2 virus and has been directly implicated in IPF pathogenesis, again suggesting a link between these seemingly distinct processes.¹⁴⁴

Genetic susceptibility. Understanding of pulmonary fibrosis pathogenesis has been substantially enhanced with the advent of population-based genome-wide association studies which have identified genetic risk variants that account for a significant portion of the total risk of IPF and other fibrotic lung disease.¹⁴⁵⁻¹⁴⁷ A gain-of-function variant in the promoter of the *MUC5B* gene, which encodes 1 of the 2 major gel-forming mucins expressed in the airway and the primary mucin expressed in the distal lung, is the strongest risk factor for IPF.¹⁴⁸⁻¹⁵⁴ Increased expression of *MUC5B* has been directly implicated in driving fibroproliferation in mouse models of fibrosis and remains an active topic of IPF-related research. This same gain-of-function *MUC5B* promoter variant has been associated with increased risk of development of ARDS in individuals age >50 years, likely suggesting shared mechanisms between these distinct disease processes.¹⁵⁵

A recent study examined genetic risk variants for IPF and their relationship to COVID-19 severity.¹⁵⁶ When the *MUC5B* risk variant was excluded, the remaining combined genetic risk factors were

significantly associated with increased risk of severe COVID-19. However, when the *MUC5B* risk variant was analyzed separately, it was found to have a decreased association with severe COVID-19 in those with established disease. Interestingly these results parallel findings in IPF^{157,158} in which the *MUC5B* variant is associated with a paradoxical survival benefit for individuals with IPF. The complex biology underlying these findings remains under investigation though it suggests that genetics almost certainly have a role in understanding both COVID-19 severity and post-COVID-19 fibrosis (Fig 1).

IMPLICATIONS FOR CHRONIC MANAGEMENT OF COVID-19

Prospective data on the chronic pulmonary consequences of COVID-19 are just beginning to emerge from up to 1 year after the start of the pandemic. In a series of patients who had recovered from severe COVID-19 were followed for a year after hospitalization, nearly 25% had persistent radiographic abnormalities with features characteristic of fibrosis including septal thickening, reticular opacities, and traction bronchiectasis.²⁵ Perhaps most significantly, while these radiologic changes correlated with illness severity, these findings were in patients that were not ventilated and therefore likely on the less severe end of the acute lung injury spectrum. In other cohorts that have included critically-ill patients requiring mechanical ventilation, the proportion of individuals with radiologic findings indicative of fibrotic changes as well as functional abnormalities was substantially higher with increasing disease severity, reaching up to 50%–66% of patients at 4 months.²⁶ As described previously, SARS and MERS survivors had similarly persistent function and radiologic abnormalities at follow-up.^{32,33,50} The preliminary data for COVID-19 suggests that functional and radiologic impairment is at least equivalent to if not more prevalent than in SARS and MERS cohorts at similar follow-up time points, possibly due to the fact that severely ill COVID-19 patients infected early in the pandemic were older and more medical comorbid than seen in previous pandemics.^{159,160} Given the far greater clinical impact of COVID-19 compared to previous pandemics, the global health care system will inevitably be challenged by patients with long-term pulmonary and extra-pulmonary COVID-19 complications.

Apart from persistent radiologic changes and deficits in pulmonary testing which persist for months to years after the inciting ARDS incident, functional and health-related quality of life impairments are highly

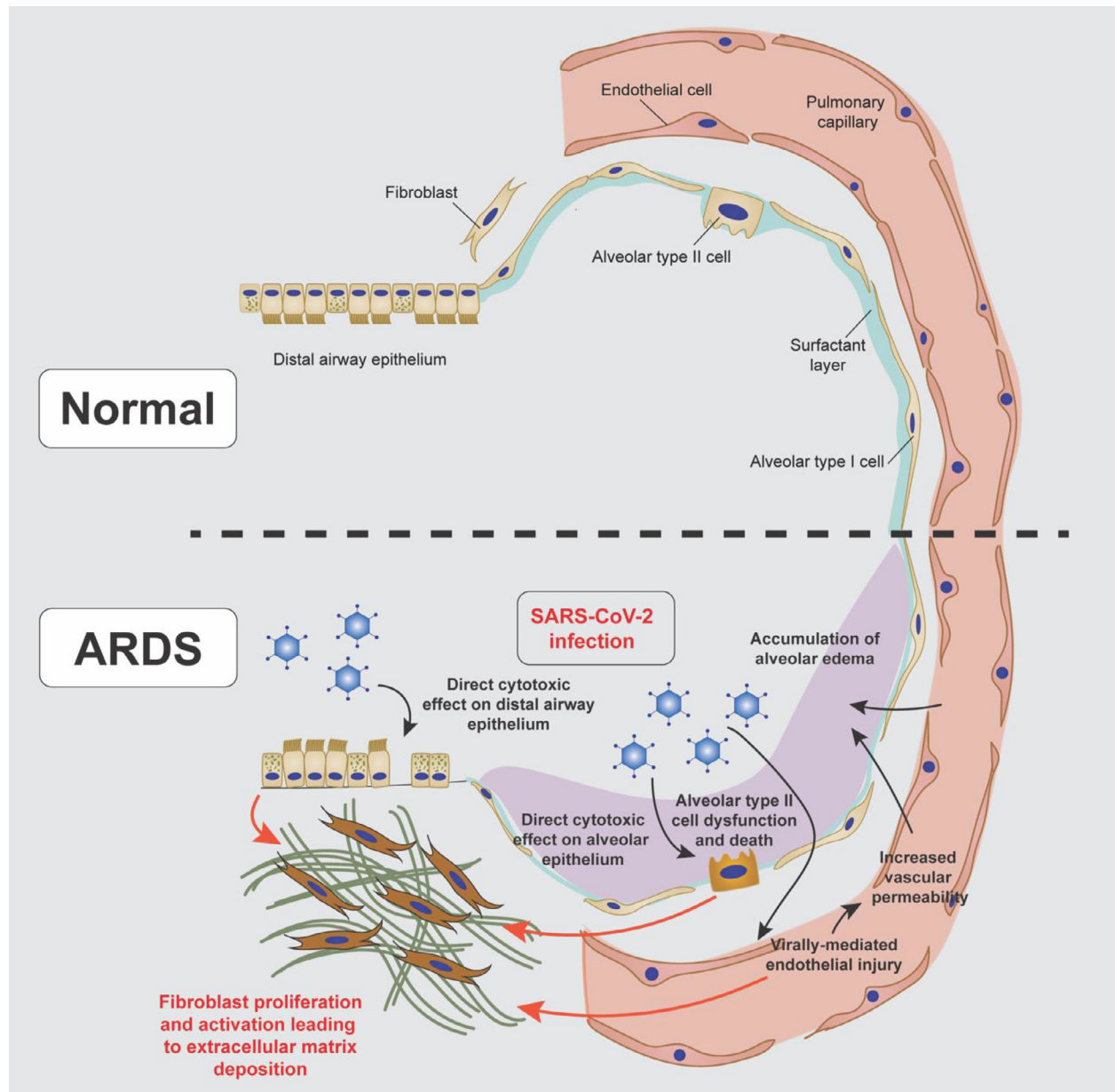


Fig 1. Mechanisms of fibroproliferation in COVID-19-induced ARDS: SARS-CoV-2 infection can lead to acute respiratory distress syndrome (ARDS) during which severe fibroproliferation can occur. The mechanisms by which eventually lead to the deposition of extra-cellular matrix by fibroblasts include direct cytotoxicity to the epithelium and endothelium.

prevalent amongst ARDS survivors. Up to two-thirds of individuals recovering from severe COVID-19 report persistent pulmonary symptoms, most commonly dyspnea, several months after their acute illness and have dramatically reduced functional capacity as measured by the 6-minute walk test.²⁵⁻³⁰ These data parallel our existing knowledge of impairments caused by ARDS survivors from other coronaviruses.³² A substantial body of evidence has now accumulated directly linking the severity of subjective impairments post-

COVID-19 with objective radiographic and physiologic pulmonary changes⁴⁹; suggesting ARDS-induced fibrosis could be a major contributor to pulmonary morbidity in years to come. Additionally, it is not entirely clear how established risk factors for increased COVID-19 severity, including premorbid smoking¹⁶¹ and obesity,^{162,163} interplay with the risk for potential lasting post-COVID pulmonary consequences.

Our best understanding of long-term pulmonary outcome from viral-induced ARDS are extrapolated from

the SARS, MERS, and H1N1 pandemics. These different viral etiologies of ARDS likely overlap; however, the patient populations affected and studied in these 2 pandemics were drastically different than seen in COVID-19: SARS in 2013 largely affected relatively healthy health care workers, and H1N1 in 2009 most dramatically affected younger individuals. The highest risk groups for severe COVID-19 included groups relatively underrepresented in these previous long-term follow-up ARDS studies, including the very elderly and patients with severe medical co-morbidities including established chronic lung disease.^{164,165} Functional impairments that may appear minor in relatively healthier cohorts could have devastating consequences in these groups that will be likely have the highest degree of post-ARDS fibrotic burden. The treatment of these patients, including interval pulmonary function testing, need for supplemental oxygen, benefit from pulmonary rehabilitation, and susceptibility to exacerbations remain unknown.

It remains unclear whether COVID-19-related ARDS will result in progressive and irreversible lung fibrosis, like IPF, where recovery is not possible. Autopsy studies in individuals who succumbed to COVID-19 and explanted lung from severe COVID-19 cases revealed lungs with classic features of progressive fibrotic disease including traction bronchiectasis, interstitial fibrosis, bronchial metaplasia, and radiographic and microscopic honeycombing.^{108,166,167} More recent literature demonstrates a dramatic increase in the number of fibroblasts and collagen deposition in fatal COVID-19 cases.¹⁶⁸ Case reports described histopathologic evidence of DAD (the pathologic manifestation of ARDS) within these fatal cases, but there is yet no evidence to suggest that individuals who entirely recover from COVID-19 related ARDS will experience progressive fibrosis. Rather, as was previously seen with SARS and H1N1, ARDS-induced fibrotic changes appear to stabilize after initial recovery and may resolve over subsequent years. Nevertheless, the trajectory of post-COVID-19 ARDS fibrosis is still uncertain, and many patients may require considerable clinical attention to rehabilitate.

As a final point, there has been much discussion about the possible role for anti-fibrotic medications in preventing or treating the potential for ARDS-induced fibrosis, and currently there are multiple trials underway to investigate these therapies. Nintedanib¹⁶⁹ and pirfenidone¹⁷⁰ are currently the only pharmaceutical agents approved for treatment of IPF and have been shown to slow decline in lung function. Given the likelihood that post-ARDS fibrosis will be relatively stable with slow resolution over months to years after initial COVID-19 disease, it seems reasonable that these

agents may expedite recovery in those most severe cases. Both agents, however, have a significant side-effect burden, including severe nausea, weight loss, diarrhea, sun sensitivity, and liver failure. In regard to preventing the initiating fibroproliferative cascade in ARDS, it is important to account for the fact that fibrosis is tightly linked to the repair process and many of the pathways that are implicated as “pro-fibrotic” are necessary for physiologic lung maintenance. Therefore, when targeting these pathways there is a necessary balance between allowing lung repair while dampening the maladaptive processes that drive fibrosis.

CONCLUSIONS

It is apparent that further studies are necessary to better understand the natural history of post-COVID-19 lung disease. As an increasing amount of radiologic evidence begins to emerge, it is important to emphasize that presence of true fibrosis cannot be established solely from “fibrosis-like” imaging. Findings in post-COVID-19 survivors of reticular abnormalities, traction bronchiectasis, and honeycomb cyst are consistent with established radiographic patterns of fibrosis, like that seen in IPF, however the natural history of the lesions remains unclear. Other findings seen in these data sets such as persistent ground-glass opacities, nodules, and consolidation are not traditionally seen in IPF and complicate the full interpretation of these findings. Furthermore, while some long-term data has emerged in the forms of imaging and pulmonary function, no histopathology of so-called long-haul COVID-19 survivors has been studied to help clarify these radiographic abnormalities.

Beyond the conserved mechanisms underlying pulmonary fibrosis discussed here, there is an expanding understanding of the interplay between innate and adaptive immunologic processes in IPF. These mechanisms which may contribute to the fibrotic response in COVID-19 are well-reviewed elsewhere.¹⁷¹⁻¹⁷⁴

Fibrosis is best understood as a part of the spectrum of adaptive repair and attempts to intervene on this process in the setting of post-COVID-19 syndromes could subvert normal repair. At this time, there is no role for anti-fibrotics in the treatment of acute or chronic COVID-19 pulmonary disease. A recent cohort study described steroid treatment for patients experiencing chronic respiratory symptoms of COVID-19; patients reported improved symptoms following therapy. Importantly, this was not a rigorous study and it is unclear due to lack of a placebo group whether these patients would have failed to improve without steroids.¹⁷⁵ Clearly further studies exploring means of improving quality of life in COVID-19 survivors are paramount.

Ultimately, the best treatment for COVID-19 is prophylactic vaccination. Studies continue to investigate the progression of and interventions for the pulmonary consequences of COVID-19 illness, and given the pace of the pandemic to date there will likely be many opportunities for further exploration in the future.

ACKNOWLEDGMENTS

Conflicts of Interest: All authors have read the journal's policy on disclosure of potential conflicts of interest and report the following: David A. Schwartz reports personal fees from Eleven P15, Inc. (a company with the mission of early detection and early intervention of IPF), outside the submitted work; In addition, David A. Schwartz has patents 14/813,559, 62/624500 pending, and a patent 8,673,565 issued.

David A. Schwartz reports grants from NIH-NHLBI (UG3/UH3-HL151865), DoD Focused Program Project (W81XWH-17-1-0597), NIH-NHLBI (R01-HL149836), VAMC Merit Review (IO1BX005295), NIH-NHLBI (P01-HL0928701), NIH-NHLBI (UH2/3-HL123442), and NIH-NHLBI (X01-HL134585), during the conduct of the study. All authors have read the journal's authorship agreement, and the manuscript has been reviewed by and approved by all named authors.

REFERENCES

- Guan W-J, Ni Z-Y, Hu Y, et al. Clinical characteristics of coronavirus disease 2019 in China. *N Engl J Med* 2020;382:1708–20.
- Wang D, Hu B, Hu C, et al. Clinical characteristics of 138 hospitalized patients with 2019 novel coronavirus–infected pneumonia in Wuhan, China. *JAMA* 2020;323:1061–9.
- Del Rio C, Collins LF, Malani P. Long-term health consequences of COVID-19. *JAMA* 2020;324:1723–4.
- Huang C, Huang L, Wang Y, et al. 6-month consequences of COVID-19 in patients discharged from hospital: a cohort study. *Lancet* 2021;397:220–32.
- Nalbandian A, Sehgal K, Gupta A, et al. Post-acute COVID-19 syndrome. *Nat Med* 2021;27:601–15.
- Gupta A, Madhavan MV, Sehgal K, et al. Extrapulmonary manifestations of COVID-19. *Nat Med* 2020;26:1017–32.
- Redd WD, Zhou JC, Hathorn KE, et al. Prevalence and characteristics of gastrointestinal symptoms in patients with severe acute respiratory syndrome coronavirus 2 infection in the united states: a multicenter cohort study. *Gastroenterol* 2020;159:765–7, e762.
- Clerkin KJ, Fried JA, Raikhelkar J, et al. COVID-19 and cardiovascular disease. *Circulation* 2020;141:1648–55.
- Goyal P, Choi JJ, Pinheiro LC, et al. Clinical characteristics of Covid-19 in New York city. *N Engl J Med* 2020;382:2372–4.
- Terpos E, Ntanasis-Stathopoulos I, Elalamy I, et al. Hematological findings and complications of COVID-19. *Am J Hematol* 2020;95:834–47.
- Ackermann M, Verleden SE, Kuehnel M, et al. Pulmonary vascular endothelialitis, thrombosis, and angiogenesis in covid-19. *N Engl J Med* 2020;383:120–8.
- Mao L, Jin H, Wang M, et al. Neurologic manifestations of hospitalized patients with coronavirus disease 2019 in Wuhan, China. *JAMA Neurol* 2020;77:683–90.
- Burnham EL, Janssen WJ, Riches DWH, Moss M, Downey GP. The fibroproliferative response in acute respiratory distress syndrome: mechanisms and clinical significance. *Eur Respir J* 2014;43:276–85.
- Santos Dos, C C. Advances in mechanisms of repair and remodelling in acute lung injury. *Intensive Care Med* 2008;34:619–30.
- Zapol WM, Trelstad RL, Coffey JW, Tsai I, Salvador RA. Pulmonary fibrosis in severe acute respiratory failure. *Am Rev Respir Dis* 1979;119:547–54.
- Cabrera-Benitez NE, Laffey JG, Parotto M, et al. Mechanical ventilation-associated lung fibrosis in acute respiratory distress syndrome: a significant contributor to poor outcome. *Anesthesiology* 2014;121:189–98.
- Marshall R, Bellingan G, Laurent G. The acute respiratory distress syndrome: fibrosis in the fast lane. *Thorax* 1998;53:815–7.
- Spagnolo P, Balestro E, Aliberti S, et al. Pulmonary fibrosis secondary to COVID-19: a call to arms? *Lancet Respir Med* 2020;8:750–2.
- George PM, Wells AU, Jenkins RG. Pulmonary fibrosis and COVID-19: the potential role for antifibrotic therapy. *Lancet Respir Med* 2020;8:807–15.
- McDonald LT. Healing after COVID-19: are survivors at risk for pulmonary fibrosis? *Am J Physiol Lung Cell Mol Physiol* 2021;320:L257–65.
- Jenkins G. Demystifying pulmonary fibrosis. *Am J Physiol Lung Cell Mol Physiol* 2020;319:L554–9.
- Eisner MD, Thompson T, Hudson LD, et al. Efficacy of low tidal volume ventilation in patients with different clinical risk factors for acute lung injury and the acute respiratory distress syndrome. *Am J Respir Crit Care Med* 2001;164:231–6.
- Han X, Fan Y, Alwalid O, et al. Six-month follow-up chest CT findings after severe COVID-19 pneumonia. *Radiology* 2021;299:E177–86.
- Mo X, Jian W, Su Z, et al. Abnormal pulmonary function in COVID-19 patients at time of hospital discharge. *Eur Respir J* 2020;55:2001217.
- Wu X, Liu X, Zhou Y, et al. 3-month, 6-month, 9-month, and 12-month respiratory outcomes in patients following COVID-19-related hospitalisation: a prospective study. *Lancet Respir Med* 2021;9:747–54.
- Guler SA, Ebner L, Aubry-Beigelman C, et al. Pulmonary function and radiological features 4 months after COVID-19: first results from the national prospective observational Swiss COVID-19 lung study. *Eur Respir J* 2021;57:2003690.
- Chopra V, Flanders SA, O'Malley M, Malani AN, Prescott HC. Sixty-day outcomes among patients hospitalized with COVID-19. *Ann Intern Med* 2021;174:576–8.
- Bellan M, Soddu D, Balbo PE, et al. Respiratory and psychophysical sequelae among patients with COVID-19 four months after hospital discharge. *JAMA Netw Open* 2021;4:e2036142-e2036142.
- Carfi A, Bernabei R, Landi F, Group, f. t. G. A. C.-P.-A. C. S. Persistent symptoms in patients after acute COVID-19. *JAMA* 2020;324:603–5.
- Logue JK, Franko NM, McCulloch DJ, et al. Sequelae in adults at 6 months after COVID-19 infection. *JAMA Netw Open* 2021;4:e210830.
- Zhao Y-M, Shang Y-M, Song W-B, et al. Follow-up study of the pulmonary function and related physiological

- characteristics of COVID-19 survivors three months after recovery. *EClinicalMedicine* 2020;25:100463.
32. Antonio GE, Wong KT, Hui DS, et al. Thin-section CT in patients with severe acute respiratory syndrome following hospital discharge: preliminary experience. *Radiology* 2003;228:810–5.
 33. Das KM, Lee EY, Singh R, et al. Follow-up chest radiographic findings in patients with MERS-CoV after recovery. *Indian J Radiol Imaging* 2017;27:342.
 34. Mineo G, Ciccarese F, Modolon C, Landini M, Valentino M, Zompatori M. Post-ARDS pulmonary fibrosis in patients with H1N1 pneumonia: role of follow-up CT. *Radiol Med* 2012;117:185–200.
 35. Ashbaugh D, Bigelow DB, Petty T, Levine B. Acute respiratory distress in adults. *Lancet* 1967;290:319–23.
 36. Ferguson ND, Fan E, Camporota L, et al. The Berlin definition of ARDS: an expanded rationale, justification, and supplementary material. *Intensive Care Med* 2012;38:1573–82.
 37. Katzenstein A, Bloor CM, Leibow AA. Diffuse alveolar damage—the role of oxygen, shock, and related factors. A review. *Am J Pathol* 1976;85:209.
 38. Thille AW, Esteban A, Fernández-Segoviano P, et al. Comparison of the Berlin definition for acute respiratory distress syndrome with autopsy. *Am J Respir Crit Care Med* 2013;187:761–7.
 39. Thille AW, Esteban A, Fernández-Segoviano P, et al. Chronology of histological lesions in acute respiratory distress syndrome with diffuse alveolar damage: a prospective cohort study of clinical autopsies. *Lancet Respir Med* 2013;1:395–401.
 40. Verity R, Okell LC, Dorigatti I, et al. Estimates of the severity of coronavirus disease 2019: a model-based analysis. *Lancet Infect Dis* 2020;20:669–77.
 41. Wu Z, McGoogan JM. Characteristics of and important lessons from the coronavirus disease 2019 (COVID-19) outbreak in China: summary of a report of 72 314 cases from the chinese center for disease control and prevention. *JAMA* 2020;323:1239–42.
 42. Haudebourg AF, Perier F, Tuffet S, et al. Respiratory mechanics of COVID-19- versus non-COVID-19-associated acute respiratory distress syndrome. *Am J Respir Crit Care Med* 2020;202:287–90.
 43. Grasselli G, Tonetti T, Protti A, et al. Pathophysiology of COVID-19-associated acute respiratory distress syndrome: a multicentre prospective observational study. *Lancet Respir Med* 2020;8:1201–8.
 44. Vandenbunder B, Ehrmann S, Piagnerelli M, et al. Static compliance of the respiratory system in COVID-19 related ARDS: an international multicenter study. *Crit Care* 2021;25:52.
 45. National Heart, L., & Network, B. I. A. R. D. S. C. T. Comparison of two fluid-management strategies in acute lung injury. *N Engl J Med* 2006;354:2564–75.
 46. Herridge MS, Tansey CM, Matté A, et al. Functional disability 5 years after acute respiratory distress syndrome. *N Engl J Med* 2011;364:1293–304.
 47. Masclans JR, Roca O, Muñoz X, et al. Quality of life, pulmonary function, and tomographic scan abnormalities after ARDS. *Chest* 2011;139:1340–6.
 48. Nöbauer-Huhmann I-M, Eibenberger K, Schaefer-Prokop C, et al. Changes in lung parenchyma after acute respiratory distress syndrome (ARDS): assessment with high-resolution computed tomography. *Eur Radiol* 2001;11:2436–43.
 49. Burnham EL, Hyzy RC, Paine R 3rd, et al. Chest CT features are associated with poorer quality of life in acute lung injury survivors. *Critl Care Med* 2013;41:445–56.
 50. Ngai JC, Ko FW, Ng SS, To K-W, Tong M, Hui DS. The long-term impact of severe acute respiratory syndrome on pulmonary function, exercise capacity and health status. *Respirology* 2010;15:543–50.
 51. Hui D, Joynt G, Wong K, et al. Impact of severe acute respiratory syndrome (SARS) on pulmonary function, functional capacity and quality of life in a cohort of survivors. *Thorax* 2005;60:401–9.
 52. Matthay MA, Zemans RL, Zimmerman GA, et al. Acute respiratory distress syndrome. *Nat Rev Dis Primers* 2019;5:18.
 53. Meyer NJ, Gattinoni L, Calfee CS. Acute respiratory distress syndrome. *Lancet* 2021;S0140-6736(0121)00439-00436.
 54. Thompson BT, Chambers RC, Liu KD. Acute respiratory distress syndrome. *N Engl J Med* 2017;377:562–72.
 55. Lederer DJ, Martinez FJ. Idiopathic pulmonary fibrosis. *N Engl J Med* 2018;378:1811–23.
 56. Wijsenbeek M, Cottin V. Spectrum of fibrotic lung diseases. *N Engl J Med* 2020;383:958–68.
 57. Richeldi L, Collard HR, Jones MG. Idiopathic pulmonary fibrosis. *Lancet* 2017;389:1941–52.
 58. Evans CM, Fingerlin TE, Schwarz MI, et al. Idiopathic pulmonary fibrosis: a genetic disease that involves mucociliary dysfunction of the peripheral airways. *Physiol Rev* 2016;96:1567–91.
 59. Steele MP, Schwartz DA. Molecular mechanisms in progressive idiopathic pulmonary fibrosis. *Annu Rev Med* 2013;64:265–76.
 60. Basil MC, Katzen J, Engler AE, et al. The cellular and physiological basis for lung repair and regeneration: past, present, and future. *Cell Stem Cell* 2020;26:482–502.
 61. Barkauskas CE, Cronic MJ, Rackley CR, et al. Type 2 alveolar cells are stem cells in adult lung. *J Clinical Invest* 2013;123:3025–36.
 62. Reilly JP, Calfee CS, Christie JD. Acute respiratory distress syndrome phenotypes. *Semin Respir Critical Care Med* 2019;40:19–30.
 63. Zou X, Chen K, Zou J, Han P, Hao J, Han Z. Single-cell RNA-seq data analysis on the receptor ACE2 expression reveals the potential risk of different human organs vulnerable to 2019-nCoV infection. *Front Med* 2020;14:185–92.
 64. Hamming I, Timens W, Bulthuis M, Lely A, Navis G, van Gooor H. Tissue distribution of ACE2 protein, the functional receptor for SARS coronavirus. A first step in understanding SARS pathogenesis. *J Pathol* 2004;203:631–7.
 65. Sungnak W, Huang N, Bécavin C, et al. SARS-CoV-2 entry factors are highly expressed in nasal epithelial cells together with innate immune genes. *Nat Med* 2020;26:681–7.
 66. Subramanian S, Borczuk A, Salvatore S, et al. Tissue factor upregulation is associated with SARS-CoV-2 in the lungs of COVID-19 patients. *J Thromb Haemost* 2021;19:2268–74.
 67. Sisson TH, Mendez M, Choi K, et al. Targeted injury of type II alveolar epithelial cells induces pulmonary fibrosis. *Am J Respir Crit Care Med* 2010;181:254–63.
 68. Barbas-Filho J, Ferreira M, Sesso A, Kairalla R, Carvalho C, Capelozzi V. Evidence of type II pneumocyte apoptosis in the pathogenesis of idiopathic pulmonary fibrosis (IPF)/usual interstitial pneumonia (UIP). *J Clin Pathol* 2001;54:132–8.
 69. Hancock LA, Hennessy CE, Solomon GM, et al. Muc5b overexpression causes mucociliary dysfunction and enhances lung fibrosis in mice. *Nat Commun* 2018;9:5363.
 70. Lawson WE, Cheng DS, Degryse AL, et al. Endoplasmic reticulum stress enhances fibrotic remodeling in the lungs. *Proc Natl Acad of Sci* 2011;108:10562–7.

71. Xi Y, Kim T, Brumwell AN, et al. Local lung hypoxia determines epithelial fate decisions during alveolar regeneration. *Nat Cell Biol* 2017;19:904–14.
72. Burman A, Kropski JA, Calvi CL, et al. Localized hypoxia links ER stress to lung fibrosis through induction of C/EBP homologous protein. *JCI Insight* 2018;3:e99543.
73. Minagawa S, Yoshida M, Araya J, Hara H, Imai H, Kuwano K. Regulated necrosis in pulmonary disease. A focus on necroptosis and ferroptosis. *Am J Respir Cell Mol Biol* 2020;62:554–62.
74. Lee JM, Yoshida M, Kim MS, et al. Involvement of alveolar epithelial cell necroptosis in idiopathic pulmonary fibrosis pathogenesis. *Am J Respir Cell Mol Biol* 2018;59:215–24.
75. Verleden SE, Tanabe N, McDonough JE, et al. Small airways pathology in idiopathic pulmonary fibrosis: a retrospective cohort study. *Lancet Respir Med* 2020;8:573–84.
76. Stancil IT, Michalski JE, Davis-Hall D, et al. Pulmonary fibrosis distal airway epithelia are dynamically and structurally dysfunctional. *Nat Commun* 2021;12:4566.
77. Vaughan AE, Brumwell AN, Xi Y, et al. Lineage-negative progenitors mobilize to regenerate lung epithelium after major injury. *Nature* 2015;517:621–5.
78. Chua RL, Lukassen S, Trump S, et al. COVID-19 severity correlates with airway epithelium-immune cell interactions identified by single-cell analysis. *Nat Biotechnol* 2020;38:970–9.
79. Vassiliou AG, Kotanidou A, Dimopoulou I, Orfanos SE. Endothelial damage in acute respiratory distress syndrome. *Int J Mol Sci* 2020;21:8793.
80. Millar FR, Summers C, Griffiths MJ, Toshner MR, Proudfoot AG. The pulmonary endothelium in acute respiratory distress syndrome: insights and therapeutic opportunities. *Thorax* 2016;71:462–73.
81. Olman MA, White KE, Ware LB, et al. Pulmonary edema fluid from patients with early lung injury stimulates fibroblast proliferation through IL-1 β -induced IL-6 expression. *J Immunol* 2004;172:2668–77.
82. Magro C, Mulvey JJ, Berlin D, et al. Complement associated microvascular injury and thrombosis in the pathogenesis of severe COVID-19 infection: a report of five cases. *Transl Res* 2020;220:1–13.
83. Huertas A, Montani D, Savale L, et al. Endothelial cell dysfunction: a major player in SARS-CoV-2 infection (COVID-19)? *Eur Respir J* 2020;56:2001634.
84. Varga Z, Flammer AJ, Steiger P, et al. Endothelial cell infection and endotheliitis in COVID-19. *Lancet* 2020;395:1417–8.
85. Probst CK, Montesi SB, Medoff BD, Shea BS, Knipe RS. Vascular permeability in the fibrotic lung. *Eur Respir J* 2020;56:1900100.
86. Montesi SB, Rao R, Liang LL, et al. Gadofosveset-enhanced lung magnetic resonance imaging to detect ongoing vascular leak in pulmonary fibrosis. *Eur Respir J* 2018;51:1800171.
87. Cao Z, Lis R, Ginsberg M, et al. Targeting of the pulmonary capillary vascular niche promotes lung alveolar repair and ameliorates fibrosis. *Nat Med* 2016;22:154–62.
88. Schafer MJ, White TA, Iijima K, et al. Cellular senescence mediates fibrotic pulmonary disease. *Nat Commun* 2017;8:14532.
89. Venosa A. Senescence in pulmonary fibrosis: between aging and exposure. *Front Med* 2020;7:606462.
90. Okuda R, Aoshiba K, Matsushima H, Ogura T, Okudela K, Ohashi K. Cellular senescence and senescence-associated secretory phenotype: comparison of idiopathic pulmonary fibrosis, connective tissue disease-associated interstitial lung disease, and chronic obstructive pulmonary disease. *J Thorac Dis* 2019;11:857–64.
91. Lee JS, La J, Aziz S, et al. Molecular markers of telomere dysfunction and senescence are common findings in the usual interstitial pneumonia pattern of lung fibrosis. *Histopathology* 2021;79:67–76.
92. Yao C, Guan X, Carraro G, et al. Senescence of alveolar type 2 cells drives progressive pulmonary fibrosis. *Am J Respir Crit Care Med* 2021;203:707–17.
93. Aoshiba K, Tsuji T, Nagai A. Bleomycin induces cellular senescence in alveolar epithelial cells. *Eur Respir J* 2003;22:436–43.
94. Waters DW, Blokland KEC, Pathinayake PS, et al. Fibroblast senescence in the pathology of idiopathic pulmonary fibrosis. *Am J Physiol Lung Cell Mol Physiol* 2018;315:L162–72.
95. Lin Y, Xu Z. Fibroblast senescence in idiopathic pulmonary fibrosis. *Front Cell Dev Biol* 2020;8:593283.
96. Tsakiri KD, Cronkhite JT, Kuan PJ, et al. Adult-onset pulmonary fibrosis caused by mutations in telomerase. *Proc Natl Acad Sci* 2007;104:7552–7.
97. Armanios MY, Chen JJ-L, Cogan JD, et al. Telomerase mutations in families with idiopathic pulmonary fibrosis. *N Engl J Med* 2007;356:1317–26.
98. Alder JK, Chen JJ-L, Lancaster L, et al. Short telomeres are a risk factor for idiopathic pulmonary fibrosis. *Proc Natl Acad Sci* 2008;105:13051–6.
99. Mushiroda T, Wattanapokayakit S, Takahashi A, et al. A genome-wide association study identifies an association of a common variant in TERT with susceptibility to idiopathic pulmonary fibrosis. *J Med Genet* 2008;45:654–6.
100. Allen RJ, Guillen-Guio B, Oldham JM, et al. Genome-wide association study of susceptibility to idiopathic pulmonary fibrosis. *Am J Respir Crit Care Med* 2020;201:564–74.
101. Moore C, Blumhagen RZ, Yang IV, et al. Resequencing study confirms that host defense and cell senescence gene variants contribute to the risk of idiopathic pulmonary fibrosis. *Am J Respir Crit Care Med* 2019;200:199–208.
102. Fingerlin TE, Murphy E, Zhang W, et al. Genome-wide association study identifies multiple susceptibility loci for pulmonary fibrosis. *Nat Genet* 2013;45:613–20.
103. Cronkhite JT, Xing C, Raghu G, et al. Telomere shortening in familial and sporadic pulmonary fibrosis. *Am J Respir Crit Care Med* 2008;178:729–37.
104. McGroder CF, Zhang D, Choudhury MA, et al. Pulmonary fibrosis 4 months after COVID-19 is associated with severity of illness and blood leucocyte telomere length. *Thorax* 2021:thoraxjnl-2021-217031.
105. Habermann AC, Gutierrez AJ, Bui LT, et al. Single-cell RNA sequencing reveals profibrotic roles of distinct epithelial and mesenchymal lineages in pulmonary fibrosis. *Sci Adv* 2020;6:eaba1972-eaba1972.
106. Adams TS, Schupp JC, Poli S, et al. Single-cell RNA-seq reveals ectopic and aberrant lung-resident cell populations in idiopathic pulmonary fibrosis. *Sci Adv* 2020;6:eaba1983-eaba1983.
107. Strunz M, Simon LM, Ansari M, et al. Alveolar regeneration through a Krt8+ transitional stem cell state that persists in human lung fibrosis. *Nat Commun* 2020;11:3559.
108. Bharat A, Querrey M, Markov NS, et al. Lung transplantation for patients with severe COVID-19. *Sci Transl Med* 2020;12:eabe4282.
109. Ricard JD, Dreyfuss D, Saumon G. Ventilator-induced lung injury. *Eur Respir J* 2003;22(suppl 42):2s–9s.
110. Slutsky AS, Ranieri VM. Ventilator-induced lung injury. *N Engl J Med* 2013;369:2126–36.
111. Gattinoni L, Coppola S, Cressoni M, Busana M, Rossi S, Chiu-mello D. COVID-19 does not lead to a "typical" acute

- respiratory distress syndrome. *Am J Respir Crit Care Med* 2020;201:1299–300.
112. Gattinoni L, Chiumello D, Caironi P, et al. COVID-19 pneumonia: different respiratory treatments for different phenotypes? *Intensive Care Med* 2020;46:1099–102.
 113. Marini JJ, Gattinoni L. Management of COVID-19 respiratory distress. *JAMA* 2020;323:2329.
 114. Bos LDJ. COVID-19-related acute respiratory distress syndrome: not so atypical. *Am J Respir Crit Care Med* 2020;202:622–4.
 115. Maley JH, Winkler T, Hardin CC. Heterogeneity of acute respiratory distress syndrome in COVID-19: "typical" or not? *Am J Respir Crit Care Med* 2020;202:618–9.
 116. Prescott HC, Calfee CS, Thompson BT, Angus DC, Liu VX. Toward smarter lumping and smarter splitting: rethinking strategies for sepsis and acute respiratory distress syndrome clinical trial design. *Am J Respir Crit Care Med* 2016;194:147–55.
 117. Hariri L, Hardin CC. Covid-19, angiogenesis, and ARDS endotypes. *N Engl J Med* 2020;383:182–3.
 118. Panwar R, Madotto F, Laffey JG, van Haren FMP. compliance phenotypes in early acute respiratory distress syndrome before the COVID-19 pandemic. *Am J Respir Crit Care Med* 2020;202:1244–52.
 119. Wu H, Yu Y, Huang H, et al. Progressive pulmonary fibrosis is caused by elevated mechanical tension on alveolar stem cells. *Cell* 2020;180:107–21, e117.
 120. Pelosi P, Rocco PR. Effects of mechanical ventilation on the extracellular matrix. *Intensive Care Med* 2008;34:631–9.
 121. Lutz D, Gazdhar A, Lopez-Rodriguez E, Ruppert C, et al. Alveolar derecruitment and collapse induration as crucial mechanisms in lung injury and fibrosis. *Am J Respir Cell Mol Biol* 2015;52:232–43.
 122. Burkhardt A. Alveolitis and collapse in the pathogenesis of pulmonary fibrosis. *Am Rec Respir Dis* 1989;140:513–24.
 123. Albert RK, Smith B, Perlman CE, Schwartz DA. Is progression of pulmonary fibrosis due to ventilation-induced lung injury? *Am J Respir Crit Care Med* 2019;200:140–51.
 124. Cagino LM, Hensley MK, Fortier SM, Dickson RP. Mechanical stretch: an important and understudied feature of acute and chronic lung injury. *Am J Respir Crit Care Med* 2020;201:992–4.
 125. Tschumperlin DJ, Ligresti G, Hilscher MB, Shah VH. Mechanosensing and fibrosis. *J Clin Invest* 2018;128:74–84.
 126. Hammerschmidt S, Kuhn H, Grasenack T, Gessner C, Wirtz H. Apoptosis and necrosis induced by cyclic mechanical stretching in alveolar type II cells. *Am J Respir Cell Mol Biol* 2004;30:396–402.
 127. Senavirathna LK, Huang C, Yang X, et al. Hypoxia induces pulmonary fibroblast proliferation through NFAT signaling. *Sci Rep* 2018;8:2709.
 128. Aquino-Gálvez A, González-Ávila G, Jiménez-Sánchez LL, et al. Dysregulated expression of hypoxia-inducible factors augments myofibroblasts differentiation in idiopathic pulmonary fibrosis. *Respir Res* 2019;20:130.
 129. Herrera J, Henke CA, Bitterman PB. Extracellular matrix as a driver of progressive fibrosis. *J Clin Invest* 2018;128:45–53.
 130. Upagupta C, Shimbori C, Alsilmi R, Kolb M. Matrix abnormalities in pulmonary fibrosis. *Eur Respir Rev* 2018;27:180033.
 131. Herrera J, Forster C, Pengo T, et al. Registration of the extracellular matrix components constituting the fibroblastic focus in idiopathic pulmonary fibrosis. *JCI Insight* 2019;4:e125185.
 132. Bitterman P. Fibroblast-matrix cross-talk in idiopathic pulmonary fibrosis: cross-links at the crossroads. *Am J Respir Cell Mol Biol* 2018;58:547–8.
 133. Philp CJ, Siebecke I, Clements D, et al. Extracellular matrix cross-linking enhances fibroblast growth and protects against matrix proteolysis in lung fibrosis. *Am J Respir Cell Mol Biol* 2018;58:594–603.
 134. Liu F, Lagares D, Choi KM, et al. Mechanosignaling through YAP and TAZ drives fibroblast activation and fibrosis. *Am J Physiol Lung Cell Mol Physiol* 2015;308:L344–57.
 135. Berhan A, Harris T, Jaffar J, et al. Cellular microenvironment stiffness regulates eicosanoid production and signaling pathways. *Am J Respir Cell Mol Biol* 2020;63:819–30.
 136. Marinković A, Liu F, Tschumperlin DJ. Matrices of physiologic stiffness potently inactivate idiopathic pulmonary fibrosis fibroblasts. *Am J Respir Cell Mol Biol* 2013;48:422–30.
 137. Freeberg MAT, Perelas A, Rebman JK, Phipps RP, Thatcher TH, Sime PJ. Mechanical feed-forward loops contribute to idiopathic pulmonary fibrosis. *Am J Pathol* 2021;191:18–25.
 138. Sheppard D. The role of integrins in pulmonary fibrosis. *Eur Respir Rev* 2008;17:157–62.
 139. Horan GS, Wood S, Ona V, et al. Partial inhibition of integrin alpha(v)beta6 prevents pulmonary fibrosis without exacerbating inflammation. *Am J Respir Crit Care Med* 2008;177:56–65.
 140. John AE, Graves RH, Pun KT, et al. Translational pharmacology of an inhaled small molecule $\alpha v \beta 6$ integrin inhibitor for idiopathic pulmonary fibrosis. *Nat Commun* 2020;11:4659, -4659.
 141. Sigris CJ, Bridge A, Le Mercier P. A potential role for integrins in host cell entry by SARS-CoV-2. *Antiviral Res* 2020;177:104759-104759.
 142. Makowski L, Olson-Sidford W, J WW. Biological and clinical consequences of integrin binding via a rogue RGD motif in the SARS CoV-2 spike protein. *Viruses* 2021;13:146.
 143. Yan S, Sun H, Bu X, Wan G. New strategy for COVID-19: an evolutionary role for RGD motif in SARS-CoV-2 and potential inhibitors for virus infection. *Front Pharmacol* 2020;11.
 144. Luan J, Lu Y, Gao S, Zhang L. A potential inhibitory role for integrin in the receptor targeting of SARS-CoV-2. *J Infect* 2020;81:318–56.
 145. Kropski JA, Blackwell TS, Loyd JE. The genetic basis of idiopathic pulmonary fibrosis. *Eur Respir J* 2015;45:1717–27.
 146. Kaur A, Mathai SK, Schwartz DA. Genetics in idiopathic pulmonary fibrosis pathogenesis, prognosis, and treatment. *Front Med* 2017;4:154, -154.
 147. Michalski JE, Schwartz DA. Genetic risk factors for idiopathic pulmonary fibrosis: insights into immunopathogenesis. *J Inflamm Res* 2020;13:1305–18.
 148. Seibold MA, Wise AL, Speer MC, et al. A common MUC5B promoter polymorphism and pulmonary fibrosis. *N Engl J Med* 2011;364:1503–12.
 149. Zhang Y, Noth I, Garcia JG, Kaminski N. A variant in the promoter of MUC5B and idiopathic pulmonary fibrosis. *N Engl J Med* 2011;364:1576.
 150. Stock CJ, Sato H, Fonseca C, et al. Mucin 5B promoter polymorphism is associated with idiopathic pulmonary fibrosis but not with development of lung fibrosis in systemic sclerosis or sarcoidosis. *Thorax* 2013;68:436–41.
 151. Borie R, Crestani B, Dieude P, et al. The MUC5B variant is associated with idiopathic pulmonary fibrosis but not with systemic sclerosis interstitial lung disease in the European Caucasian population. *PLoS One* 2013;8:e70621.
 152. Peljto AL, Selman M, Kim DS, et al. The MUC5B promoter polymorphism is associated with idiopathic pulmonary fibrosis in a Mexican cohort but is rare among Asian ancestries. *Chest* 2015;147:460–4.

153. Yang IV, Fingerlin TE, Evans CM, Schwarz MI, Schwartz DA. MUC5B and idiopathic pulmonary fibrosis. *Ann Am Thorac Soc* 2015;12(Suppl 2):S193–9.
154. Horimasu Y, Ohshimo S, Bonella F, et al. MUC 5 B promoter polymorphism in Japanese patients with idiopathic pulmonary fibrosis. *Respirology* 2015;20:439–44.
155. Rogers AJ, Solus JF, Hunninghake GM, et al. MUC5B promoter polymorphism and development of acute respiratory distress syndrome. *Am J Respir Crit Care Med* 2018;198:1342–5.
156. Fadista J, Kraven LM, Karjalainen J, et al. Shared genetic etiology between idiopathic pulmonary fibrosis and COVID-19 severity. *EBioMedicine* 2021;65:103277.
157. Peljto AL, Zhang Y, Fingerlin TE, et al. Association between the MUC5B promoter polymorphism and survival in patients with idiopathic pulmonary fibrosis. *JAMA* 2013;309:2232–9.
158. Biondini D, Balestro E, Rigobello C, et al. MUC5B genotype affects survival of patients with idiopathic pulmonary fibrosis (IPF) on antifibrotic treatment. *Eur Respir J* 2019;54(suppl 63):PA1352.
159. Lu L, Zhong W, Bian Z, et al. A comparison of mortality-related risk factors of COVID-19, SARS, and MERS: a systematic review and meta-analysis. *J Infect* 2020;81:e18–25.
160. Zhu Z, Lian X, Su X, Wu W, Marraro GA, Zeng Y. From SARS and MERS to COVID-19: a brief summary and comparison of severe acute respiratory infections caused by three highly pathogenic human coronaviruses. *Respir Res* 2020;21:224.
161. Lowe KE, Zein J, Hatipoglu U, Attaway A. Association of smoking and cumulative pack-year exposure with COVID-19 outcomes in the Cleveland Clinic COVID-19 registry. *JAMA Intern Med* 2021;181:709–11.
162. Lighter J, Phillips M, Hochman S, et al. Obesity in patients younger than 60 years is a risk factor for COVID-19 hospital admission. *Clin Infect Dis* 2020;71:896–7.
163. Tartof SY, Qian L, Hong V, et al. Obesity and mortality among patients diagnosed with COVID-19: results from an integrated health care organization. *Ann Intern Med* 2020;173:773–81.
164. Wu C, Chen X, Cai Y, et al. Risk factors associated with acute respiratory distress syndrome and death in patients with coronavirus disease 2019 pneumonia in Wuhan, China. *JAMA Intern Med* 2020;180:934–43.
165. Zhou F, Yu T, Du R, et al. Clinical course and risk factors for mortality of adult inpatients with COVID-19 in Wuhan, China: a retrospective cohort study. *Lancet* 2020;395:1054–62.
166. Schwensen HF, Borreschmidt LK, Storgaard M, Redsted S, Christensen S, Madsen LB. Fatal pulmonary fibrosis: a post-COVID-19 autopsy case. *J Clin Pathol* 2021;74:400–2.
167. Grillo F, Barisione E, Ball L, Mastracci L, Fiocca R. Lung fibrosis: an undervalued finding in COVID-19 pathological series. *Lancet Infect Dis* 2021;21:e72.
168. Rendeiro AF, Ravichandran H, Bram Y, et al. The spatial landscape of lung pathology during COVID-19 progression. *Nature* 2021;593:564–9.
169. Richeldi L, Bois Du, R M, Raghu G, et al. Efficacy and safety of nintedanib in idiopathic pulmonary fibrosis. *N Engl J Med* 2014;370:2071–82.
170. King, E T, Bradford WZ, Castro-Bernardini S, et al. A phase 3 trial of pirfenidone in patients with idiopathic pulmonary fibrosis. *N Engl J Med* 2014;370:2083–92.
171. Budinger G, Misharin AV, Ridge KM, Singer BD, Wunderink RG. Distinctive features of severe SARS-CoV-2 pneumonia. *J Clin Invest* 2021;131:e149412.
172. Schultze JL, Aschenbrenner AC. COVID-19 and the human innate immune system. *Cell* 2021;184:1671–92.
173. Sette A, Crotty S. Adaptive immunity to SARS-CoV-2 and COVID-19. *Cell* 2021;184:861–80.
174. Merad M, Martin JC. Pathological inflammation in patients with COVID-19: a key role for monocytes and macrophages. *Nat Rev Immunol* 2020;20:355–62.
175. Myall KJ, Mukherjee B, Castanheira AM, et al. Persistent post-COVID-19 interstitial lung disease. An observational study of corticosteroid treatment. *Ann Am Thorac Soc* 2021;18:799–806.