

Dacryology Update

Nasal endoscopy in the management of congenital nasolacrimal duct obstruction



Yasser H. Al-Faky, MD, FRCS*

Abstract

Probing is a reliable surgical intervention for the management of congenital nasolacrimal duct obstruction (CNLDO). However, it is a blind procedure that carries the risk of false passage formation. Moreover, its success rate is variable, with unexplained causes of failure. Recent literature suggests the use of nasal endoscopic-assisted probing to minimize nasal mucosal trauma, decreases the chance of creating a false passage and provides the optimum management option of different congenital variants of nasolacrimal duct obstruction. Nasal endoscopic-assisted probing has more or less consistent success rates varied between 85% and 98% compared with probing success rates, which vary between 55% and 95% despite having almost the same age range.

Keywords: Nasal, Endoscope, Probing, Congenital, Nasolacrimal duct, Obstruction

© 2013 Saudi Ophthalmological Society, King Saud University. Production and hosting by Elsevier B.V. All rights reserved.
<http://dx.doi.org/10.1016/j.sjopt.2013.11.002>

Introduction

Congenital anomalies of the lacrimal excretory system are mainly confined to the lower end of the nasolacrimal duct (NLD), namely, congenital nasolacrimal duct obstruction (CNLDO), which causes a relatively common clinical problem affecting up to 20% of newborns.^{1–6} The classic imperforate membrane at the level of Hasner's valve is the most common congenital variant encountered during surgery, known as *simple CNLDO*. Nevertheless, other types of obstruction, known as *complex CNLDO*, may be encountered during surgical intervention, which makes the procedure challenging and carries a higher risk of failure.^{7–10} Although probing is a very reliable primary surgical management of CNLDO, it is a blind procedure that depends mainly on the anatomical background and the surgeon's fingertip feelings during the advancement of the probe through the lacrimal drainage system (LDS). The unexplained variable success rates, the difficulty in probe advance-

ment due to anatomical variations, and the false passage formation have encouraged many surgeons to perform probing under direct visualization using a nasal endoscope.

In the last two decades, the nasal endoscope has remarkably advanced, making it easy to use. Hence, it became the standard technique in many otolaryngology surgeries.¹¹ A relatively increasing number of studies have been published in recent years, which highlight the value of using a nasal endoscope during a probing procedure.^{10,12,13} Although their data are encouraging, the extra steps and instruments needed for endoscopy, the need for an otolaryngologist specializing in endoscopic sinus surgery, or the learning curve in mastering the use of a nasal endoscope might be limitations and leave the question, "Is it worthy to perform nasal endoscopic-assisted probing?"

The aim of this review was to shed light on the possible advantages of using a nasal endoscope during a probing procedure in the management of CNLDO.

Received 27 October 2013; received in revised form 29 October 2013; accepted 4 November 2013; available online 13 November 2013.

Department of Ophthalmology, College of Medicine, King Saud University, Riyadh, Saudi Arabia

* Address: Department of Ophthalmology, College of Medicine, King Saud University, PO Box 245, Riyadh 11411, Saudi Arabia. Tel.: +966 01 477 57 23; fax: +966 01 477 57 24.

e-mail address: alfaky@gmail.com



Peer review under responsibility of Saudi Ophthalmological Society, King Saud University



Production and hosting by Elsevier

Access this article online:
www.saudiophthaljournal.com
www.sciencedirect.com

Anatomical variants of CNLDO and false passage

The NLD is typically a single passage connecting the lacrimal sac superiorly to the nasal cavity inferiorly through an orifice into the inferior meatus. This orifice is thought to have a valve like action known as Hasner's valve.¹ The simple and frequently encountered congenital NLD anomaly is the imperforate Hasner's valve.^{1,2} However, the NLD course may have anatomical variations from the sac duct junction up to its opening in the inferior meatus and this can contribute to false passage creation during the probing procedure.¹⁴ In addition, the NLD may extend down the submucosa for several millimeters or even up to the floor of the nose without opening; hence, the probe goes down to the nasal floor without mucosal perforation into the nasal cavity, a condition commonly referred to as "buried probe".^{1,15} The duct may also end blindly in the medial wall of the maxillary sinus.¹ The inferior turbinate may share the anomalous NLD opening either through the blockage of the duct by the impacted anterior end of the turbinate or through the duct itself, which ends blindly in the anterior end of the turbinate.^{1,7} Moreover, the most severe form of anomaly, which is almost the complete absence of the NLD because of the failure of the osseous nasolacrimal canal to develop, can be rarely seen with cleft palate anomalies.^{1,7,16} Another anomaly is the dacryoceles, which causes distension and ballooning of the lower end of the NLD. The clinical presentation of dacryoceles varies from small nasal mass up to complete nasal obstruction caused by the huge distension of the dacryoceles.¹⁷ It is worthy to note that the anomalous segmental canalization of the LDS during embryogenesis can be reflected at a different level and degree of obstruction. Hence, the upper part of the NLD, the common canaliculus, the canaliculi, and the puncta can be affected.^{1,7}

Probing is a blind procedure with variable success rates

The surgical management of CNLDO has not changed significantly since Petrus Camper described probing in the 18th century, which is basically overcoming the obstruction with a probe advanced through the LDS.¹⁸ The anatomical background is extremely helpful to guide the direction during the advancement of the probe through the LDS; however, it is totally a blind procedure that carries the risk of a false passage. In addition, different variants of complex CNLDO can also challenge the smooth passage of the probe, with a higher incidence of complication and an increasing risk of failure.^{19,20}

In majority of published data, the success rate of probing showed great variability between 55% and 95%.^{8–10,21–29} This could be influenced by the study design, inclusion and exclusion criteria, age-group, and outcome measurement parameters. The effect of age as a risk factor for probing failure has been considered as the main aim of much of these reports but remains debatable.^{22–26,28,29} Some studies have looked at the characteristics of NLD obstruction and correlated the probing outcomes to the site and severity of the obstruction. These reports have claimed that the complexity of the obstruction was the main risk for probing failure in older age-groups.^{10,22,23,26} It is worthy to note that the high rate of the spontaneous resolution of simple CNLDO could provide a natural selection process as the children grow older,

in whom the complex problems became relatively more common.^{6,30}

As probing is performed blindly, it may be easy to appreciate the location and severity of obstruction at the surgeon's fingertip during probe advancement. This might be applicable through a typical anomalous LDS, wherein the obstruction is at the level of the inferior meatus. In other variants of CNLDO, it may be difficult to accurately identify the track of the probe, the site of obstruction, and the mucosal exit without direct visualization. The surgeon might lose probing control, and a false passage is likely. The current method used to confirm that the probe is in the nasal cavity without direct visualization is a "metal-on-metal touch," in which another probe or clamp is passed blindly toward the inferior meatus to touch the already advanced probe tip in the nasal cavity. Despite considering the metal-on-metal touch technique as the golden standard clue of the successful passage of the probe by many ophthalmologists, the adjunctive use of a nasal endoscope in some reports revealed a high incidence of a false passage as the metal to metal touch technique can be positive even in a false passage and hence not sacrosanct.^{7,12,13}

Technique of nasal endoscopic-assisted probing

For the past 20 years, the development of both rigid and flexible nasal endoscope enabled us to visualize the nasal cavity, including the inferior meatus and the distal end of the NLD.³¹ Direct visualization allowed a better understanding of the nature of NLD obstruction, which can help in the detection of NLD anatomical variants and prevent a false passage.

The nasal endoscopic-assisted probing is carried out under general anesthesia. Topical decongestant nasal drops (xylometazoline hydrochloride, 0.025%) are usually instilled in the nasal cavity either before the child enters the operating room or immediately after the induction of anesthesia. Under general anesthesia, a nasal pack (neurosurgical pledgets) soaked in 0.025% xylometazoline hydrochloride or 1:100,000 epinephrine is precisely inserted under the inferior turbinate and between the inferior turbinate and the nasal septum for 5–10 min and then removed. This improves visualization through the widening of the nasal cavity as it constricts the vascular nasal mucosa. After the removal of the nasal pack, the nose is aspirated, and a careful examination of the nasal cavity is performed to identify any preexisting nasal pathology that might interfere with probing, such as an impacted inferior turbinate.³²

A 2.7 mm 30° rigid endoscope is used as the small caliber suits the pediatric nasal cavity and the angled view provides a better visualization of the NLD opening under the inferior turbinate. It is advisable to use a thin arm board placed next to the patient's head to enable the surgeon to rest his elbow comfortably on the arm board during endoscopic evaluation. The endoscope is held by the surgeon's left hand, and other instruments throughout the procedure are manipulated with the right hand (for a right-handed surgeon, and vice versa for a left-handed surgeon), but the endoscope and instruments should never cross during surgery. The monitor is connected to a video camera facing the surgeon, behind the patient's head. After the white balance is adjusted and an antifog solution is applied, the endoscope is introduced into the nasal cavity. During the pass of the endoscope, the structures of the nasal cavity, the appearance of the nasal mucosa, and the infe-

rior turbinate are examined. The endoscope is passed along the floor of the nasal cavity while examining the inferior meatus where the NLD drains. The NLD drains into the nasal cavity via the valve of Hasner, which can be identified as a small dimple in the mucosa of the lateral wall of the inferior meatus.^{31,33}

Management of different variants of CNLDO under direct visualization

While examining the inferior meatus, a diluted fluorescein dye is injected through LDS via a cannula introduced through the upper canaliculus as far as the lacrimal sac. The flow of fluorescein dye from the sac to the nasal cavity, if any, is observed. If the flow of dye is free without any resistance (Fig. 1), no further action is taken, and spontaneous resolution is awaited as the LDS is clearly anatomically patent and the symptoms are due to a "functional blockage" or the atony of the lacrimal sac if the sac distended during dye injection, which can be felt by palpation.⁷ If the dye does not flow into the nose, the following actions are considered:^{7,34}

1. If the inferior turbinate is impacted or the inferior meatus is shallow, the infraction of the inferior turbinate is performed, followed by dye reinjection (Fig. 2A and B). If the dye flows freely into the nose, the infraction is considered curative, which could be due to mucosal stretching caused by infraction which opens the mucosal exit of the duct. If the dye has to be forcibly injected to flow into the nose, it is considered as NLD stenosis. If the dye does not flow, which is usually associated with the ballooning of the nasal mucosa, the NLD is considered obstructed. In NLD stenosis or obstruction, probing is performed. As the probe is passed through the canaliculus into the sac and onward into the duct, any stenotic or obstructed area has to be noticed and located.
2. As the probe enters the inferior meatus (Fig. 3), the following conditions are endoscopically observed:
 - a. If the probe tip protruded through a thin obstructing membrane or stenotic valve, the opening is widened by moving the probe from side to side. This can be augmented by a sickle knife cut on the probe to increase the size of the opening.

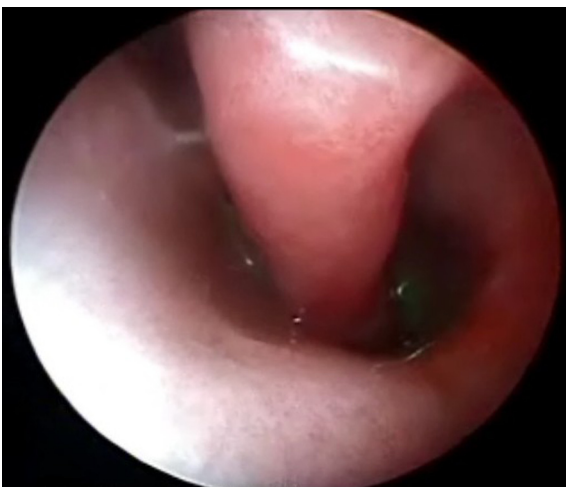

Figure 1. Nasal endoscopic view shows free flow of fluorescein under the inferior turbinate.

- b. If the probe failed to perforate the nasal mucosa because of a clearly thick membrane or stretchable valve, a sickle knife is used to perforate the mucosa over the probe's tip.
 - c. If the probe went through a submucosal plane down to the nasal floor without the perforation of the mucosa into the nasal cavity or went medially perforating the inferior turbinate mucosa, an anatomical variant of CNLDO or a false passage is expected. The probe can be redirected toward the apex of the inferior meatus, using the suction tip to prevent the probe from sliding laterally or medially by supporting it.
3. If bony NLD obstruction is felt or observed, the probing cannot perforate the obstruction, dacryocystorhinostomy (DCR) is warranted and endoscopic DCR is performed under the same anesthesia.^{7,34}

Advantages of nasal endoscopic-assisted probing

Current studies have used fewer endoscopic-assisted probing procedures compared with conventional probing. However, the published data highlighted some advantages that hopefully encourage researchers to conduct more studies with a larger number of patients.

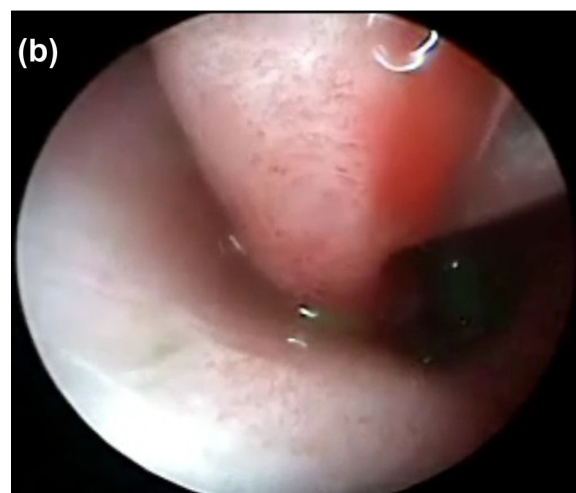
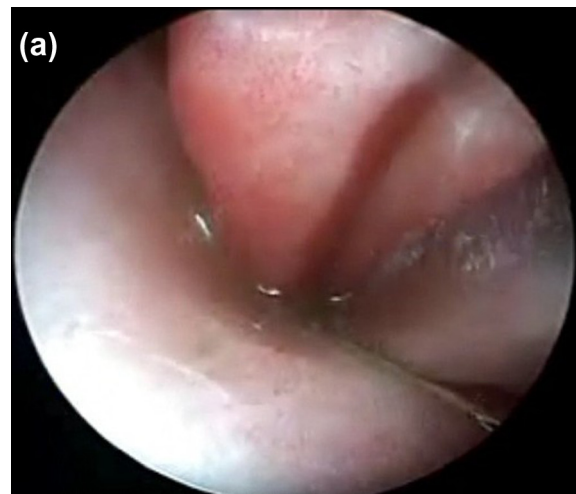

Figure 2. (A) Nasal endoscopic view of inferior turbinate infraction. (B) Note the free flow of fluorescein after infraction of the inferior turbinate.

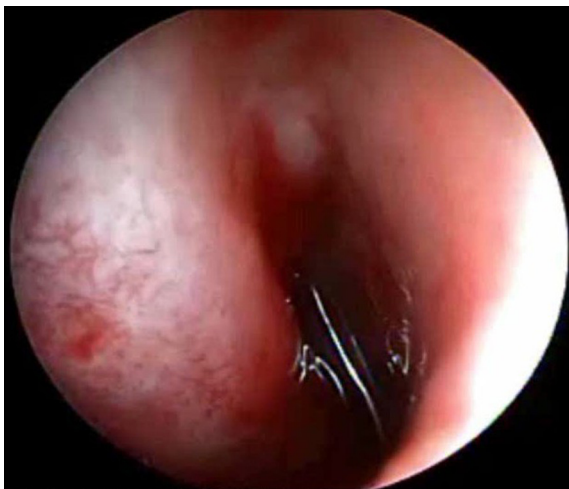


Figure 3. Nasal endoscopic view shows the normal passage of the probe under the inferior turbinate.

A major drawback of many probing reports is the vague definition of probing failure. It remains unclear whether failure is due to technical difficulties or anatomical variants, which have a direct impact on the management outcome.¹⁵ Hence, an important and well-recognized advantage of nasal endoscopic-assisted probing is the direct visualization of the advanced probe through the mucosal exit. Direct visualization highlights the nature and variant of CNLDO and provides the optimum management option, such as using the sickle knife to perforate or increase the size of the mucosal opening.³⁵ Direct visualization has also increased the understanding of CNLDO, which makes our knowledge of failures clearer. Elmosry et al. reported different situations that might be faced during probing because of the different types of obstructions, which could not be delineated properly without direct visualization with the endoscope. They also described the management of the different types of obstruction that definitely needed a nasal endoscopy.³⁶ Wallace et al. highlighted that the use of a nasal endoscope had helped them to look at the site of obstruction and to evaluate the success rates accordingly. They reported 100% (58/58) success rates for lower-end NLD obstruction, 100% (13/13) success rate for punctal stenosis, 0% (0/7) success rate for canalicular and upper NLD obstruction, and 55.6% (5/9) success rate for functional epiphora.³⁴ As probing was successful in all cases of lower-end NLD anomaly, whether atresia or stenosis, despite having seven cases of submucosal probe passage, the endoscope aided in guiding the probe into the correct anatomical pathway. Similarly, all cases of punctal stenosis that were managed under direct visualization were successful.³⁴ Kouri et al. pointed at multiple anatomical anomalies within the LDS that could be attributed to the success of probing. They also highlighted the associated nasal anomalies with CNLDO in 23% of cases that could not be detected and treated without the use of a nasal endoscope and contributed to the overall success by 17.31%. In their series, multiple LDS anatomical anomalies and nasal abnormalities were quite common in older children, which can be attributed to the decline in the success rate of probing with age.³² MacEwen et al. reported 92% success rate with initial probing in classic lower-end CNLDO, even in older children. They concluded that endoscopic-assisted probing improved the understand-

ing of outflow obstruction in young children.⁷ Choi et al. determined the submucosal and bony obstruction variants of CNLDO, with the aid of a nasal endoscope, which were managed accordingly with successful outcomes.³⁷

Unlike blind probing, the use of endoscope reduces nasal mucosal trauma and decreases the chance of creating a false passage.³⁶ Although metal-on-metal feeling is accepted by most ophthalmologists to ensure the entrance of the probe to the nasal cavity, it may overlook a false passage even with an experienced surgeon. Unless guided with direct visualization, the probe passage into the natural mucosal exit at the inferior meatus cannot be guaranteed, and the chance of a false passage is not low. This is even more important for the trainee. Sener and Onerci addressed the value of endoscopic-guided probing during residency training program as they compared probing performed by an experienced pediatric ophthalmologist with probing performed by residents under his supervision. The residents made five false passages of 11 probings, two of which they were not aware, whereas the experienced surgeon performed two false passages of 11 probings, one of which he was not aware.¹² Cakmak et al. also compared probing versus endoscopic-guided probing as a primary intervention for CNLDO. Nasal endoscopy had enabled them to identify a false passage at the upper end of the inferior meatus in two cases. The probing was redirected under direct visualization until the distal end of the nasolacrimal canal was correctly bypassed.¹³ MacEwen et al. reported a false passage in 15% of their series and concluded that the endoscopic-guided relocation of the probe is necessary to prevent a false passage to achieve a high degree of success.⁷ Cibis and Jazbi suggested that a high incidence of false passages during probing might be missed without the use of a nasal endoscope.³⁸ Mullner et al. concluded that a false passage is more likely to occur with the proximal variant of CNLDO because the surgeon may lose the orientation of the probe within soft tissues.³⁹

As probing has variable success rates between 55% and 95%, some researchers have been encouraged to evaluate probing with the aid of a nasal endoscope.^{8-10,21-29} Cakmak et al. compared probing versus endoscopic-guided probing by observation as a primary intervention for CNLDO. They reported 86.5% (32 of 37 eyes) probing success rate (aged from 12 to 60 months) and 94.4% (34 of 36 eyes) endoscopic-assisted probing success rate (aged from 12 to 72 months).¹³ Orhan et al. also compared probing in 22 eyes (age range, 7–14 months) and endoscopic-guided probing in 18 eyes (age range, 7–13 months) with CNLDO. They reported 91% success rate with probing and 94% success rate with an endoscopic-guided probing.⁴⁰ Hakim et al. prospectively studied 169 eyes of 130 children aged 4–48 months with CNLDO who underwent primary treatment with an endoscopic-assisted probing. They reported 97% success rate.⁴¹ Elmosry et al. performed endoscopic-assisted probing in 36 eyes in 26 patients aged from 12 months to 4 years: 30 eyes as a primary intervention and 6 eyes as the second or third intervention. They achieved a 94.5% success rate.³⁶ Wallace et al. used endoscopic-assisted probing in 87 eyes of 67 patients aged 12–91 months as a primary intervention. They reported an 89% success rate and recommended the use of endoscope during probing to facilitate the diagnosis and management of the anomaly at this site under direct visualization.³⁴ Kouri et al. evaluated 52 eyes of 40 patients with CNLDO

aged 12–126 months using endoscopic-assisted probing as a primary intervention. They reported an 84.6% overall success rate.³² MacEwen et al. used endoscopic-assisted probing in 52 eyes of 40 children with CNLDO aged 12–91 months. They reported an 85% overall success rate.⁷ Theodoropoulou et al. reported the use of endoscopic-assisted probing in 50 eyes of 38 children with CNLDO aged 17–109 months. They reported a 98% success rate.⁴² The small series of Sasaki et al. reported a 92.3% success rate in the endoscopic-assisted probing in 13 eyes of 10 children aged 14–74 months.⁴³ In view of that, nasal endoscopic-assisted probing has more consistent success rate (varied between 85% and 98%) compared with probing despite having almost the same age range.

Limitations of nasal endoscopic-assisted probing

The endoscopic-assisted probing requires more instrumentation, which increases the cost of the procedure. Nonetheless, a portable, compact, and less costly nasal endoscope (Fig. 4) is readily available and suitable for such a simple procedure compared with the high-tech nasal endoscope (Fig. 5) used in endoscopic sinus surgery. Another limitation is the need of the otolaryngologist to be around during surgery, or it mandates learning curve mastering of the use of a nasal endoscope by the ophthalmologist. However, the collaborative teamwork of an ophthalmologist and an otolaryngologist might be advantageous to carry out additional rhinology treatments, if required, under the same anesthesia. Moreover, mastering the use of a nasal endoscope is recommended for a dacryologist, providing the opportunity for endoscopic lacrimal surgery and teaching purposes. It is important for a surgeon to realize that 60% of the lacrimal passage courses through the nose and not knowing 60% anatomy while treating those diseases cannot be ethically accepted. Hence for anyone who practises dacryology, nasal endoscopy is a mandatory armamentarium. Personally, I found it a very useful office tool in the preoperative and post-operative evaluation of adult patients with LDS dysfunction.

It is worthy to mention that the aforementioned limitations have been admitted by some researchers who concluded that nasal endoscopic-assisted probing may be excessive as



Figure 4. A portable compacted nasal endoscope which is suitable for endoscopic assisted probing.

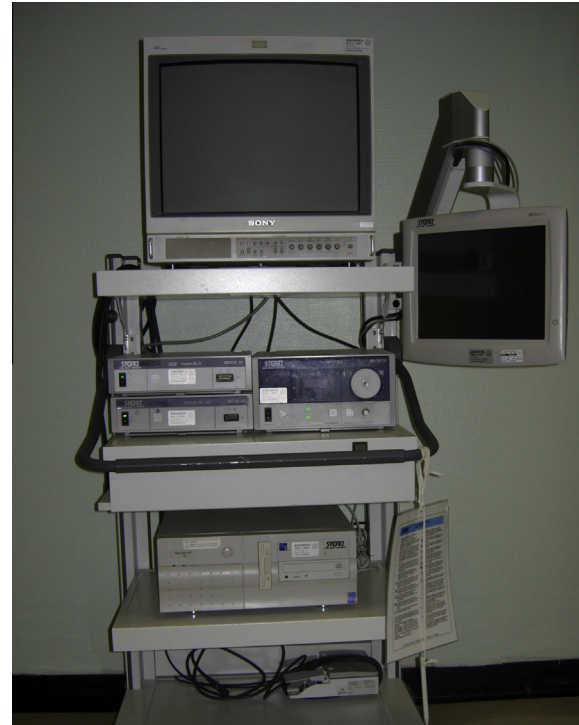

Figure 5. A High-Tec nasal endoscope which is used in endoscopic sinus surgery.

a primary procedure in most cases of CNLDO, although it may be helpful in failed cases.^{13,40}

In summary, the use of endoscopic-assisted probing can be justified as more consistent cure rate is likely to be achieved, the chance of creating a false passages is minimal, the optimum management option for different variants of CNLDO is provided, the knowledge of CNLDO failures is clearer, and the residency teaching potential is better. In the meantime, prospective randomized comparative studies on a large number of patients are needed to enable eventual meta-analysis for a sound conclusion.

Conflict of interest

The authors declared that there is no conflict of interest.

References

1. Nesi FA, Lishman RD, Levine MR. *Ophthalmic plastic and reconstructive surgery*. 2nd ed. *Congenital lacrimal disorders*, 34. Mosby-Year Book, Inc.; 1998, p. 649–660.
2. MacEwen CJ, Young JD. Epiphora during the first year of life. *Eye* 1991;5:596–600.
3. Ffookes OO. Dacryocystitis in infancy. *Br J Ophthalmol* 1962;46:422–34.
4. Cassady JV. Dacryocystitis of infancy. *Am J Ophthalmol* 1948;31:773–80.
5. Noda S, Hayasaka S, Tomoichi S. Congenital nasolacrimal duct obstruction in Japanese infants: its incidence and treatment with massage. *J Pediatr Ophthalmol Strabismus* 1991;28:20–2.
6. Paul TO, Shepherd R. Congenital nasolacrimal duct obstruction: natural history and the timing of optimal intervention. *J Pediatr Ophthalmol Strabismus* 1994;31:362–7.
7. MacEwen CJ, Young JD, Barras CW, Ram B, et al. Value of nasal endoscopy and probing in the diagnosis and management of children with congenital epiphora. *Br.J Ophthalmol* 2001;85:314–8.

8. Honavar S, Prakash V, Rao G. Outcome of probing for congenital nasolacrimal duct obstruction in older children. *Am J Ophthalmol* 2000;**130**:42–8.
9. Kashkouli MB, Kassaei A, Tabatabaee Z. Initial nasolacrimal duct probing in children under age 5: cure rate and factors affecting success. *J AAPOS* 2002;**6**:360–3.
10. Kashkouli MB, Beigi B, Parvaresh MM, Kassaei A, et al. Late and very late initial probing for congenital nasolacrimal duct obstruction: what is the cause of failure? *Br J Ophthalmol* 2003;**87**:1151–3.
11. Rudmik L, Smith TL. Olfactory improvement after endoscopic sinus surgery. *Curr Opin Otolaryngol Head Neck Surg* 2012;**20**(1):29–32.
12. Sener EC, Onerci M. Reappraisal of probing of the congenital obstruction of the nasolacrimal system: is nasal endoscopy essential? *Int J Pediatr Otorhinolaryngol* 2001;**58**:65–8.
13. Cakmak SS, Yildirim M, Sakalar YB, Keklikci U, et al. Is it necessary to accompany probing with endoscopy in cases of congenital nasolacrimal canal obstruction? *Int J Pediatr Otorhinolaryngol* 2010;**74**(9):1013–5.
14. Boger WP. Congenital nasolacrimal duct obstruction. In: Albert DM, Jakobiec FA, editors. *Principles and practice of ophthalmology, clinical practice*. Philadelphia: WB Saunders; 1994, p. 2812–2826.
15. Mirecki R. Cause of failure in probing the naso-lacrimal duct in infants and children and ways of avoiding them. *J Paediatr Ophthalmol* 1968;**5**:171–5.
16. Yuen SJ, Oley C, Sullivan TJ. Lacrimal outflow dysgenesis. *Ophthalmology* 2004;**111**(9):1782–90.
17. Shashy RG, Durairaj VD, Holmes JM, Hohberger GG, et al. Congenital dacryocystocele associated with intranasal cysts: diagnosis and management. *Laryngoscope* 2003;**113**(1):37–40.
18. Nouhuys CE. The lacrimal surgery of Petrus Camper and his contemporaries. *Documenta Ophthalmologica* 1988;**68**(1–2):125–33.
19. Wobig JL. Lacrimal probing complications. *Ophthalmic Plast Reconstr Surg* 1985;**1**:75–6.
20. Milder B. Complications in lacrimal surgery. In: Waltman SR, Krupin T, editors. *Complications in ophthalmic surgery*. New York: JB Lippincott; 1980, p. 233–251.
21. Katowitz JA, Welsh MG. Timing of initial probing and irrigation in congenital nasolacrimal duct obstruction. *Ophthalmology* 1987;**94**:698–705.
22. Mannor GE, Rose GE, Frimpong-Ansah K, Ezra E. Factors affecting the success of nasolacrimal duct probing for congenital nasolacrimal duct obstruction. *Am J Ophthalmol* 1999;**127**(5):616–7.
23. Maheshwari R. Success rate and cause of failure for late probing for congenital nasolacrimal duct obstruction. *J Pediatr Ophthalmol Strabismus* 2008;**45**(3):168–71.
24. Pediatric Eye Disease Investigator Group. Primary treatment of nasolacrimal duct obstruction with probing in children younger than 4 Years. *Ophthalmology* 2008;**115**(3):577–584.
25. Robb RM. Success rates of nasolacrimal duct probing at time intervals after 1 year of age. *Ophthalmology* 1998;**105**(7):1307–10.
26. Al-Faky YH, Al-Sobaie N, Mousa A, Al-Odan H, et al. Evaluation of treatment modalities and prognostic factors in children with congenital nasolacrimal duct obstruction. *J AAPOS* 2012;**16**(1):53–7.
27. Casady DR, Meyer DR, Simon JW, Stasior GO, et al. Stepwise treatment paradigm for congenital nasolacrimal duct obstruction. *Ophthalm Plast Reconstr Surg* 2006;**22**(4):243–7.
28. Kushner BJ. The management of nasolacrimal duct obstruction in children between 18 months and 4 years old. *J AAPOS* 1998;**2**:57–60.
29. Zilelioğlu G, Hoşal BM. The results of late probing in congenital nasolacrimal duct obstruction. *Orbit* 2007;**26**(1):1–3.
30. Petersen RA, Robb RM. The natural course of congenital obstruction of the nasolacrimal duct. *J Pediatr Ophthalmol Strabismus* 1978;**15**:246–50.
31. Kennedy DW, Zinreich SJ, Rosenbaum AE, Johns ME. Functional endoscopic sinus surgery. Theory and diagnostic evaluation. *Arch Otolaryngol* 1985;**111**(9):576–82.
32. Kouri AS, Tsakanikos M, Linardos E, Nikolaidou G, et al. Results of endoscopic assisted probing for congenital nasolacrimal duct obstruction in older children. *Int J Pediatr Otorhinolaryngol* 2008;**72**:891–6.
33. Bolger WE, Kennedy DW. Nasal endoscopy in the outpatient clinic. *Otolaryngol Clin North Am* 1992;**25**(4):791–802.
34. Wallace EJ, Cox A, White P, MacEwen CJ. Endoscopic assisted probing for congenital nasolacrimal duct obstruction. *Eye* 2006;**20**:998–1003.
35. Ingels K, Kestelyn P, Meire F, et al. The endoscopic approach for congenital naso-lacrimal duct obstruction. *Clin Otolaryngol* 1997;**22**:96–9.
36. Elmorsy S, Shabana YK, Fayek HM. Endoscopic assisted probing for symptomatic congenital nasolacrimal duct obstruction after one year of age. *Rhinology* 2010;**47**:100–3.
37. Choi WC, Kim KS, Park TK, Chung CS. Intranasal endoscopic diagnosis and treatment in congenital nasolacrimal duct obstruction. *Ophthalmic Surg Lasers* 2002;**33**:288–92.
38. Cibis GW, Jazbi BU. Nasolacrimal duct probing in infants. *Ophthalmology* 1970;**86**:1488–91.
39. Mullner K, Bodner E, Mannor GE. Endoscopy of the lacrimal system. *Br J Ophthalmol* 1999;**83**:949–52.
40. Orhan M, Cal P, Onerci M, Irkec M. Conventional or endoscopic probing for congenital nasolacrimal duct obstruction. *Eur J Ophthalmol* 2001;**11**:215–7.
41. Hakim OM, Mandour W, Elbaz E. Nasal endoscopic visualization and management of the leading causes of probing failure. *J Pediatr Ophthalmol Strabismus* 2010;**47**(4):214–9.
42. Theodoropoulou S, Sutherland MS, Haddow K, Blaikie A. Success rates of endoscopic-assisted probing for congenital nasolacrimal duct obstruction in children. *J Laryngol Otol* 2013;**127**(8):794–8.
43. Sasaki H, Takano T, Murakami A. Direct endoscopic probing for congenital lacrimal duct obstruction. *Clin Exp Ophthalmol* 2013. <http://dx.doi.org/10.1111/ceo.1210> Epub ahead of print.