

Case Report

Timelined multimodal recording of EEG and driving performance using a driving simulator system during a focal impaired awareness seizure

Tomoaki Ban ^{a,b}, Yohei Ishishita ^a, Masayuki Tetsuka ^a, Taku Uchiyama ^a, Keisuke Ohtani ^a, Kensuke Kawai ^{a,*}^a Department of Neurosurgery, Jichi Medical University, 3311-1 Yakushiji, Shimotsuke, Tochigi 329-0498, Japan^b Equos Research Co., Ltd., 1-18-13 Sotokanda, Chiyoda-ku, Tokyo 101-0021, Japan

ARTICLE INFO

Article history:

Received 5 November 2019

Received in revised form 28 December 2019

Accepted 31 December 2019

Available online 7 January 2020

Keywords:

Driving simulator

Epilepsy

Focal impaired awareness seizure

ABSTRACT

An epileptic seizure during the course of driving can result in a serious car accident. However, basic data on how epileptic seizures actually affect driving performance is significantly lacking. To understand the relationship, it is crucial to conduct not only behavioral but also electroencephalogram (EEG) analysis during epileptic seizures. Therefore, we developed a mobile driving simulator which makes it possible to record driving-related parameters time-lined with video-EEG. We report a case in which behavioral and EEG changes were successfully recorded during ictal periods of focal impaired awareness seizure in a patient engaged with the system. With the current lack of objective data describing how seizures impair driving performance, such an accumulation of information could improve personalized medical management, influence legal adjudication and assist in the development of driving support systems for people with epilepsy.

© 2020 The Authors. Published by Elsevier Inc. This is an open access article under the CC BY-NC-ND license (<http://creativecommons.org/licenses/by-nc-nd/4.0/>).

1. Introduction

Drivers with epilepsy are generally regarded as having a higher risk of motor vehicle accidents (MVAs) [1,2]. The assumption is often made that seizures with impaired awareness and/or sensorimotor function during driving results in the high probability of dangerous operation and subsequent risk for crash of the vehicle. On the other hand, some previous studies have shown that the incidence of MVAs caused by seizures was not higher than that of MVAs from other causes [3–5]. Sheth et al. reported that only 0.2% of fatal MVAs in the U.S. during 1995–97 were associated with ES [6]. Clarifying the relationship between seizures in patients that occur during driving and MVAs is crucial for determining permission to drive, and a major concern for people with epilepsy. However, there are only a few reports that have analyzed the details of how each type of ES impacts the driver's ability to operate an automobile [7].

Video-electroencephalography (video-EEG) monitoring can simultaneously record both EEG signal changes and the behavioral symptoms of a seizure with a very high temporal resolution. Hence, the use of driving simulator systems during video-EEG monitoring is one of the most valuable approaches to revealing precisely when driving performance is impaired during a seizure. Despite this, few studies incorporating this technique exist [8]. We report a case in which we successfully

recorded driving-related parameters timed with video-EEG during interictal and ictal periods.

2. Case presentation

The patient was a 32-year-old right-handed woman with drug-resistant epilepsy. Although the patient had a driving history before her first seizure, she had not driven since starting epilepsy treatment.

At 19 years of age, she had her first focal impaired awareness seizure. Her habitual seizures started with repetitive eye blinking for a few seconds followed by behavioral arrest and turning of her head to the right, but without tonic movements in her legs. Magnetic resonance imaging indicated no lesions in her brain. EEG readings registered frequent spike-and-waves in the middle and posterior temporal regions on the left side of the brain. Long-term video-EEG failed to localize the seizure onset zone. Chronic intracranial-EEG monitoring with subdural grids identified the seizure onset simultaneously from the extensive areas of the basal and lateral cortices of her left temporal lobe. Although focal resection was considered, electrical cortical stimulation performed for functional brain mapping revealed that the epileptogenic zone was located in the area that was eloquent for language function. Therefore, extensive multiple subpial transections on the left temporal lobe were performed. However, the seizures relapsed one month postoperatively. The patient underwent another video-EEG monitoring session 6 months after surgery. During this period, we assessed her driving performance using EEG and a driving simulator system.

* Corresponding author at: 3311-1 Yakushiji, Shimotsuke, Tochigi 329-0498, Japan.
E-mail address: kenkawai-tyk@jichi.ac.jp (K. Kawai).

3. Results

We used a racing game (Gran Turismo 6; Sony Computer Entertainment, Japan) operated by a pedal controller and steering wheel (T500 RS; Thrustmaster, United States) to assess driving performance while simultaneously recording EEG signals and a video feed (Fig. 1A). The patient's driving posture was continuously recorded with two video cameras attached to the ceiling and in front of the patient (Fig. 1B and C). We extracted three parameters from the racing game to assess driving performance: throttle position, brake press, and steering angle. Furthermore, an

additional parameter, G-force related to the deceleration and acceleration of the vehicle itself, was extracted. The purpose of adding the latter parameter was to evaluate effect of a collision of the vehicle as a result of driving failure.

First, we monitored the timeline of her behavior and the changes in EEG signal during the ictal period (Fig. 1). At 11 s after starting the driving task, she began to exhibit repetitive eye blinking. Her driving performance did not appear to be impaired at this time (Fig. 1B). In addition, there was no change in the EEG apart from motion artifacts (pink background in Fig. 1D). At 24 s, the onset of her habitual seizure was

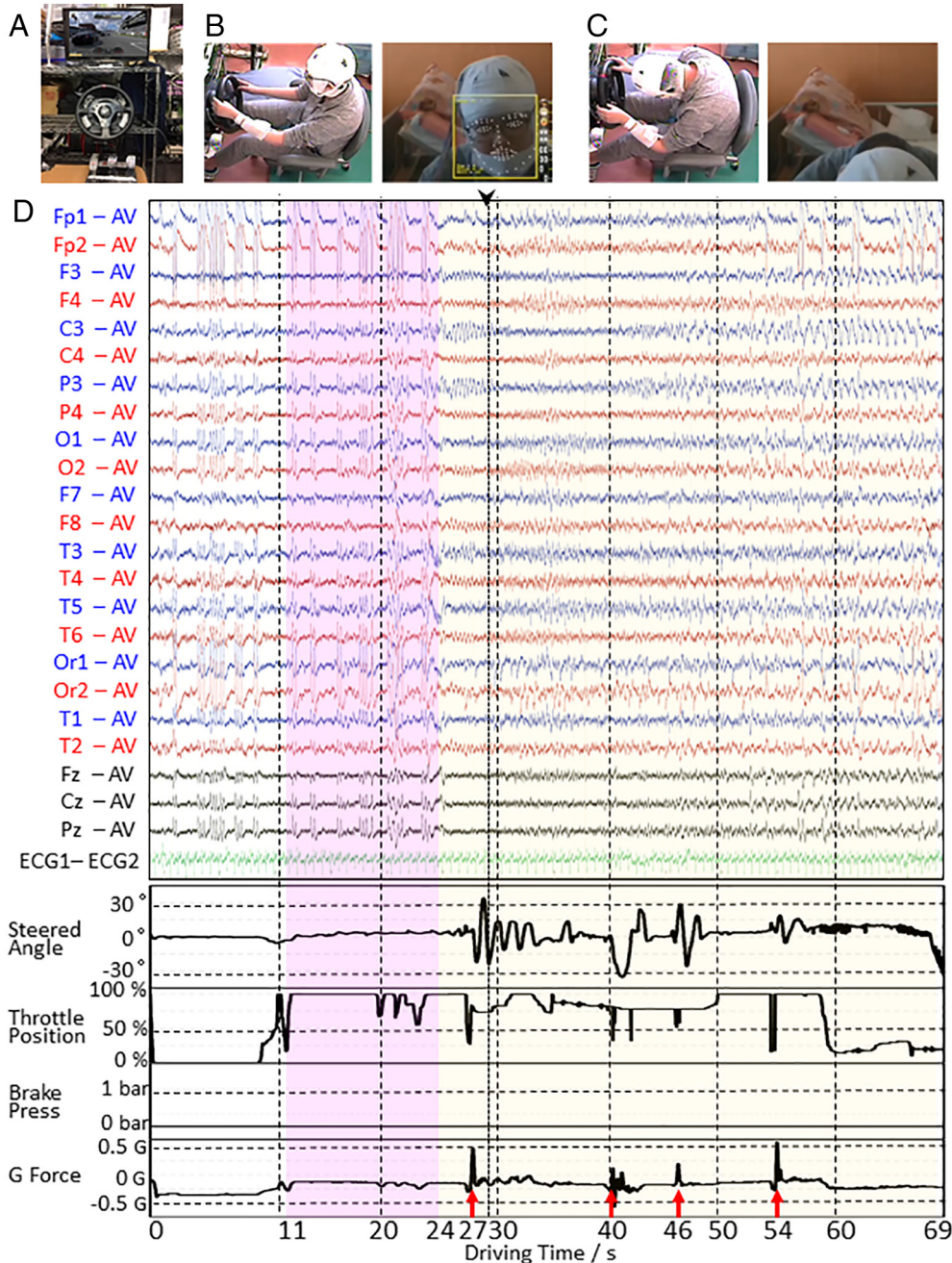


Fig. 1. Timelined multimodal data of EEG signals and driving performance during the ictal period. The driving simulator system used in this study is shown in A. As shown in B and C, driving posture was continuously recorded with two video cameras attached to the ceiling (left) and in front of the patient (right). The timed data of EEG signals and four parameters during the driving task is shown in D. The parameters for displaying EEG waveform, sensitivity, time constant, and high cut filter, were set at 10 μ V, 0.1 s, and 15 Hz, respectively. Although the patient started repetitive eye blinking 11 s after beginning the driving task, her driving performance was not outwardly impaired (B). Furthermore, there was no change in the EEG signal except for motion artifacts seen within the pink background in D. At 24 s, the EEG started with rhythmic low-voltage, fast activity at T3, then continued until seizure termination at 69 s (yellow background in D). At 29 s, epileptiform activity propagated to the contralateral temporal lobe (arrow at top of the graph in D). Her driving posture was lost until 59 s (C). Four crashes to the wall around the driving course occurred at 27 s, 40 s, 46 s, and 54 s, respectively (red arrows in D).

observed on EEG beginning with rhythmic low-voltage theta activity at T3 (yellow background in Fig. 1D). Her neck started to flex forward at 26 s, and only 1 s after that the first collision into the wall of the driving course was there a sudden elevation in the G-force (first red arrow in Fig. 1D). At 29 s, epileptic discharge propagated to the contralateral temporal lobe, after which the right side of her vehicle continuously rubbed against the wall due to complete loss of driving ability with her loss of axial posture (Fig. 1C). The second, third, and fourth collisions were recorded at 40 s, 46 s, and 54 s, respectively. Although epileptiform discharges remained on the EEG recording, the throttle position decreased to about 20% and her driving posture gradually recovered at

59 s. EEG was normalized again at 69 s. In total, her seizure was recorded on EEG for 45 s.

Next, we compared her driving performance during the ictal and interictal periods, focusing on changes to the throttle position and steering angle (Fig. 2). Although there were no tonic movements in her legs, the throttle position was at almost 100% throughout the ictal period (yellow line in upper graph of Fig. 2B). In contrast, the throttle was controlled at around 40% during the interictal period (yellow line in upper graph in Fig. 2C). Remarkably, the throttle position moved immediately to 100% when the patient started to exhibit eye blinking, despite no electroencephalographical change being detected up to that

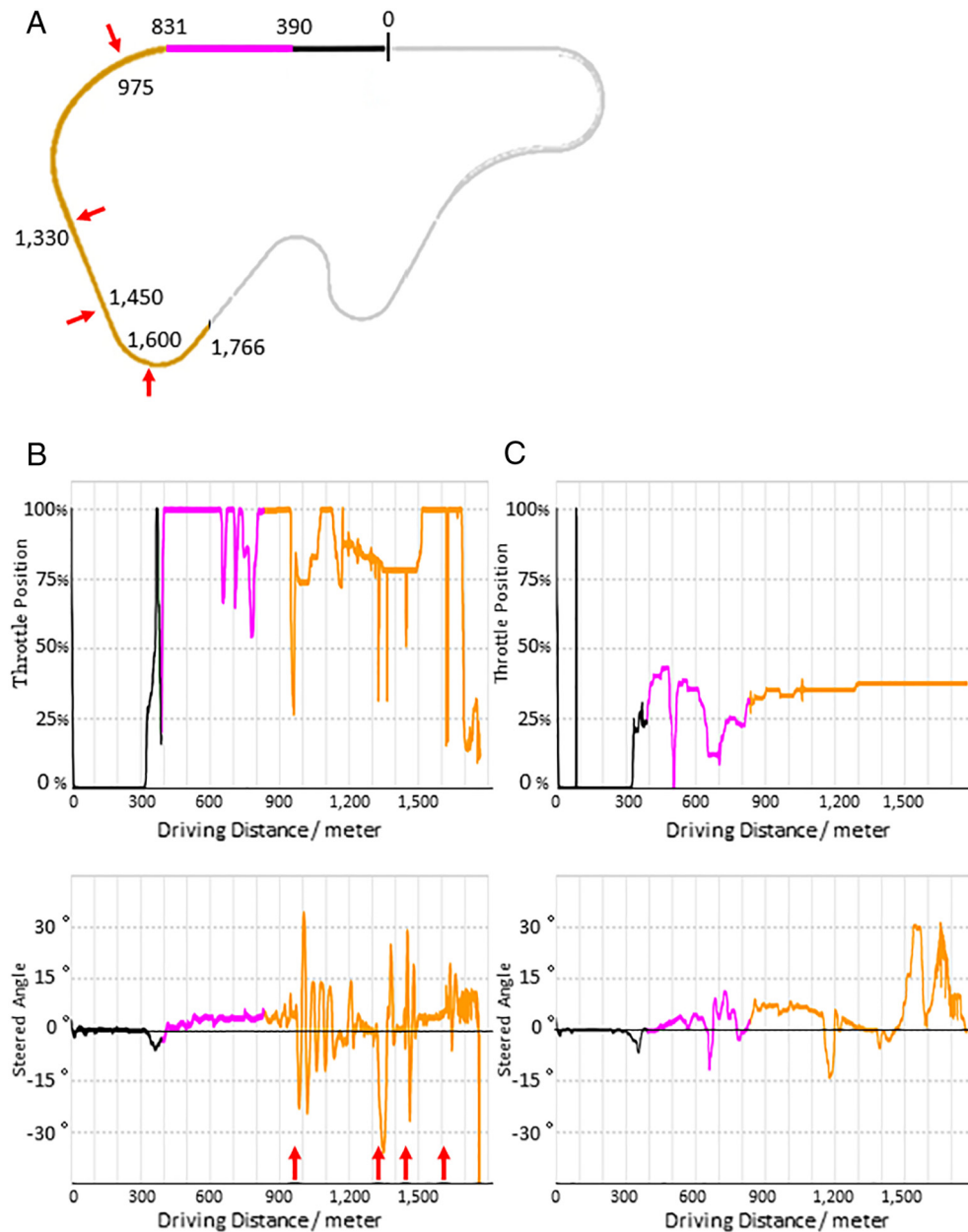


Fig. 2. Comparison of driving performance between ictal and interictal periods. The driving course used in this study is shown in A. The driving operation during the interictal period (0 to 390 m), eye blinking without EEG change (390 to 831 m), and the ictal period with obvious EEG change (831 to 1766 m) are shown in black, pink, and yellow lines, respectively. The driving distance during the ictal period was 935 m, and there were four collision events indicated by the red arrows. Changes to throttle position and steering angle during the ictal and interictal periods are shown in B and C, respectively. Although the throttle position was at almost 100% throughout the ictal period (yellow line in upper graph of B), it was controlled at around 40% during the interictal period (yellow line in upper graph of C). Remarkably, it moved immediately to 100% after the patient started eye blinking, despite no EEG change being detected up to that point (pink line in upper graph of B). With regard to 'steering angle', the steering wheel was properly handled throughout the driving course during the interictal period (lower graph in C). On the other hand, steering control was lost during the ictal period, during which time the steering wheel was swung left and right during each of the four collisions (red arrows in lower graph of B).

point (pink line in upper graph of Fig. 2B). With regard to steering angle, the steering wheel was properly handled throughout the driving course during the interictal period (lower graph in Fig. 2C). On the other hand, steering control was completely lost during the ictal period, during which time the steering wheel was swung left and right during each of the four collision events (red arrows in lower graph of Fig. 2B). Braking operation was not invoked in the racing game environment during either ictal or interictal period. The times taken to drive through the section were 89.5 s and 68.5 s for the ictal and interictal periods, respectively.

4. Discussion

Our multimodal recording demonstrated that the impaired driving performance and resultant crashes were directly caused by focal impaired awareness seizures confirmed by video-EEG. Our recording also revealed the association between impairment of driving-related parameters and development of a seizure that occurred on a moment-to-moment basis. Interestingly, a change in driving-related parameters was detected before the seizure onset was evident on the EEG. To the best of our knowledge, there has been no detailed study in which both EEG and driving-related parameters were simultaneously recorded and directly compared during a focal seizure. This case illustrates how focal impaired awareness seizures can result in unintended acceleration and loss of braking and steering ability followed by high-speed car crashes. Accumulation of such objective data is essential to understand how each type of seizure affects driving performance [8].

Yang et al. reported impairment of virtual driving in 22 seizures from 13 patients participating in driving simulations during video-EEG monitoring [9]. In that study, they proposed the feasibility of evaluating risk of car crash in association with the degree of impairment of awareness. In a subsequent review article in 2014, the same group of authors emphasized again the importance of driving simulator systems adapted for use in epilepsy monitoring units to obtain both ictal and interictal data in patients for objective evidence relating to driving [8]. Recently, Cohen et al. demonstrated the association between generalized epileptiform discharges and driving impairment using a driving simulator [7]. However, this study did not report the effect of the clinical seizure itself. The barriers are presumably threefold: First, driving simulator systems like those used for motor vehicle accident rehabilitation cost a considerable amount of money, in excess of \$100,000 United States dollars [10]. Second, it is difficult to achieve timelined recording of video-EEG and driving-related parameters, as the video-EEG and driving simulator systems are stand-alone devices. Finally, the chance of capturing spontaneous seizures during the driving simulation is unlikely and dependent on the amount of time the patient can cooperate for the study.

To obtain sufficient data on different types of seizures, a large number of patients is required, most likely combined into a registry of data from multiple facilities. For this purpose, a low-cost mobile system is desirable. Our mobile driving simulator system for use with video-EEG monitoring was assembled from a commercially available video game console and video capture unit. It costs as little as \$1800 United States dollars, yet it is able to realize timelined multimodal recording of video-EEG and driving-related parameters. A system like ours can be easily incorporated into epilepsy monitoring units all over the world, allowing a large amount of patient data to be accumulated. Such

collected information would be invaluable for not only aptitude standardization for drivers with epilepsy, but also development of driving support systems for people with epilepsy. Furthermore, since individual evaluation is preferable to standardized criteria such as seizure-free periods [11], evaluating each patient through the use of such systems would be essential in determining individual driver's aptitude.

Acknowledgments

We are grateful to the patients and their families who participated in this study at the Jichi Medical University Hospital. This study was partially supported by the General Insurance Association of Japan and Japan Society for the Promotion of Science.

Declaration of competing interest

Tomoaki Ban is supported by grant from the Japan Society for the Promotion of Science KAKENHI (19K20733) and is an employee of Equos Research Co., Ltd. Kensuke Kawai was supported by grant from the General Insurance Association of Japan (General Research). The other author doesn't have any potential conflict of interest to disclose.

Appendix A. Supplementary data

Supplementary data to this article can be found online at <https://doi.org/10.1016/j.ebr.2020.100356>.

References

- [1] Gastaut H, Zifkin BG. The risk of automobile accidents with seizures occurring while driving: relation to seizure type. *Neurology* 1987;37(19):1613–6.
- [2] Sundelin HEK, Chang Z, Larsson H, Lichtenstein P, Almqvist C, Tomson T, et al. Epilepsy, antiepileptic drugs, and serious transport accidents: a nationwide cohort study. *Neurology* 2018;90(13):e1111–8.
- [3] Taylor J, Chadwick D, Johnson T. Risk of accidents in drivers with epilepsy. *J Neurol Neurosurg Psychiatry* 1996;60(6):621–7.
- [4] Dratzkowski Joseph F, Robert SFisher, Joseph ISirven, Bart MDemaerschalk, Uber-Zak Lori, Hentz Joseph G, et al. Seizure related motor vehicle crashes in Arizona before and after reducing the driving restriction from 12 to 3 months. *Mayo Clinic Proc* 2003;78(7):819–25.
- [5] Ban Tomoaki, Kawai Kensuke, Nambu Kyojiro, Iseki Hiroshi, Masamune Ken. Estimating the risk of fatal traffic accidents posed by drivers with epilepsy in Japan. *Epilepsy & Seizure* 2018;10(1):1–10.
- [6] Sheth SG, Krauss G, Krumholz A, Li G. Mortality in epilepsy: driving fatalities vs other causes of death in patients with epilepsy. *Neurology* 2004;63(6):1002–7.
- [7] Cohen E, Antwi P, Banz BC, Vincent P, Saha R, Arencibia CA, et al. Realistic driving simulation during generalized epileptiform discharges to identify electroencephalographic features related to motor vehicle safety: feasibility and pilot study. *Epilepsia* 2019;0:1–10.
- [8] Chen WC, Chen EY, Gebre RZ, Johnson MR, Li N, Vitkovskiy P, et al. Epilepsy and driving: potential impact of transient impaired consciousness. *Epilepsy Behav* 2014;30:50–7.
- [9] Yang L, Morland TB, Schmits K, Rawson E, Narasimhan P, Motelow J, et al. A prospective study of loss of consciousness in epilepsy using virtual reality driving simulation and other video games. *Epilepsy Behav* 2010;18(3):238–46.
- [10] Association for Technical Aids. Welfare Equipment Developer Information. http://www.techno-aids.or.jp/kaiatsu/j_40.shtml, Accessed date: 4 November 2019. (In Japanese).
- [11] Ma BB, Bloch J, Krumholz A, Hopp JL, Foreman PJ, Soderstrom CA, et al. Regulating drivers with epilepsy in Maryland: results of the application of a United States consensus guideline. *Epilepsia* 2017;58(8):1389–97.