

Percutaneous ultrasound-guided ulnar nerve release technique compared to open technique: A cadaveric study

Jad Mansour^{1,*}, Joe Ghanimeh², Abdelhamid Gheris¹, Berenice Moutinot¹, Remy Coulomb¹, Pascal Kouyoumdjian¹, and Olivier Mares¹

¹ Centre Hospitalier Universitaire Nîmes-Caremeau, place du professeur Robert-Debré, 30029 Nîmes, France

² Department of Orthopedic Surgery, Lebanese American University-Rizk Hospital, Lebanese American University, School of Medicine, Beirut, Lebanon

Received 20 July 2022, Accepted 8 September 2022, Published online 26 September 2022

Abstract – Objectives: To evaluate the outcomes of a novel percutaneous ultrasound-guided technique for release of ulnar nerve entrapment at the elbow when compared to standard open release **Methods:** One single surgeon performed an ultrasound-guided percutaneous release of the cubital tunnel on a group of five cadaveric elbows and open release on five others. All procedures were timed, and incision lengths were recorded. Meticulous anatomic dissection was then performed to assess the complete release of the carpal tunnel and iatrogenic injuries. **Results:** No significant difference was found between the two groups in terms of complete release and iatrogenic injury, whereas Operative time was significantly shorter for the US-guided technique. Incomplete releases of the nerve were found only during the first two trials in each group, while the third, fourth, and fifth trials showed a complete ulnar nerve release in both series, highlighting a fast learning curve for both techniques. All of this through a significantly smaller incision in the US-guided technique. **Conclusions:** This study highlights the similar effects of these two techniques in terms of complete release of the ulnar nerve, with no clear superiority of one over the other in terms of morbidity rate. Both have a fast learning curve for an ultrasound-trained surgeon, with the US-guided technique being a less traumatic and quicker alternative procedure.

Key words: Ultrasound-guided ulnar nerve release – Cubital tunnel, Ulnar nerve release, Cadaveric.

Introduction

Cubital tunnel syndrome (CuTS) is the second most common compression neuropathy affecting the upper extremity [1]. The symptoms of CuTS are usually paresthesia in the fourth and fifth fingers increasing during elbow flexion with associated elbow pain. In severe cases, motor deficits and intrinsic muscle atrophy of the hand can appear [2].

Treatment modalities for CuTS include non-operative interventions as the first line of treatment. If non-operative treatment fails, multiple surgical techniques exist, ranging from open surgical decompression [3] (with or without nerve transposition) [4] to endoscopic [5] to minimally invasive release [6].

Optimal surgical treatment of ulnar nerve entrapment at the elbow is still controversial as none of the techniques mentioned above has demonstrated clear long-term superiority over the others [7–9].

A novel percutaneous US-guided technique for the release of ulnar nerve entrapment at the elbow was described by

Poujade et al. in 2014 [10]. This technique aims at releasing the different anatomic structures compressing the nerve while minimizing damage to the surrounding structures. Few subsequent papers revisited US-guided CuTS release, but no comparative study with the regular open approach is present in known literature [11–13].

Therefore, the primary aim of this study is to compare the ultrasound-guided release of the ulnar nerve (URUN) to the standard open release on 10 cadaveric elbows in terms of efficacy and complication rates. The secondary aims are to compare the operative time, learning curve, and incision length for these two techniques.

Materials and methods

Study design

This study was conducted at the Laboratory of Experimental Anatomy of the Faculty of Medicine of Montpellier-Nîmes, France. After approval by the ethical review committee of our institution, five fresh frozen cadavers were available, amounting

*Corresponding author: jad.mansour09@gmail.com

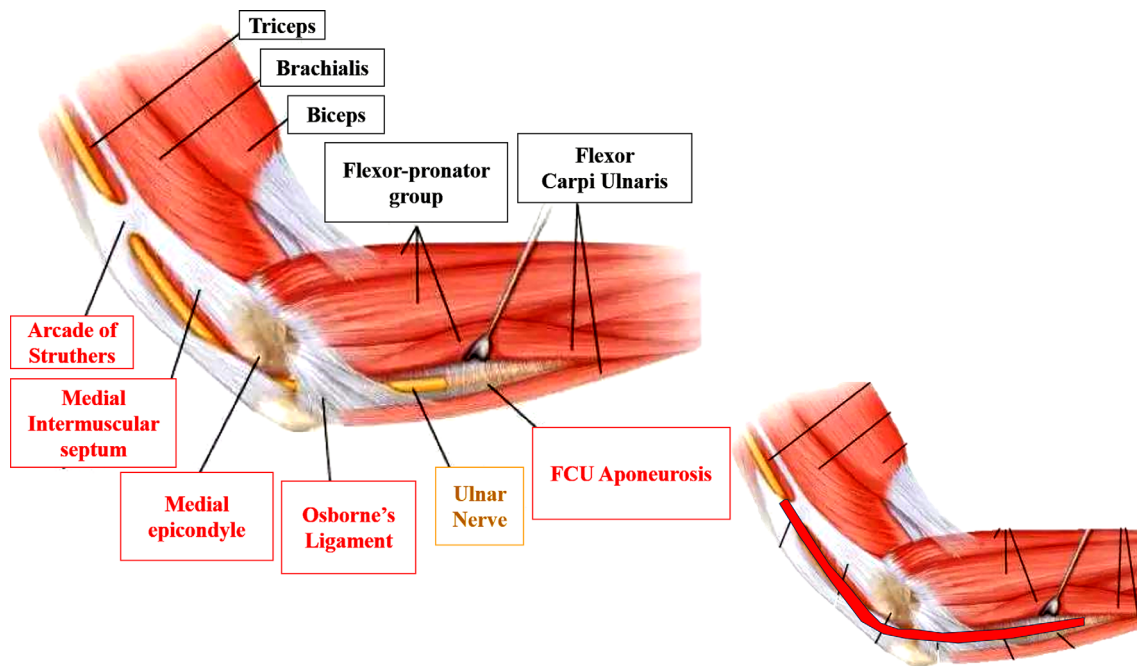


Figure 1. Schematic view of the medial elbow with possible sites of ulnar nerve compression (in red rectangles). At the bottom left, the release rate represents the percentage of the colored area's length that was found to be sectioned upon dissection.

10 upper extremities. All specimens were adults (3 males and 2 females) between 42 and 71 (mean age = 59 ± 6) and free from any deformity or prior elbow surgery.

URUN was done on one upper extremity of each of the five cadavers, while the open release of the ulnar nerve (ORUN) was performed on the contralateral upper limb to reduce the risk of anatomical variation bias. All procedures were timed and performed by a single surgeon (JM). Following each procedure, incision length was recorded, and a second operator (co-author OM) performed meticulous anatomic dissection of the medial elbow to assess the release of the cubital tunnel and record possible iatrogenic injuries to the ulnar nerve itself or surrounding soft tissues, such as the flexor carpi ulnaris (FCU), ulnar artery, the medial antebrachial cutaneous nerve (MABC nerve) or basilic vein.

For the purpose of this study, the release rate was defined as the percentage of the longitudinal distance that was sectioned during the procedure between the arcade of Struthers proximally and the aponeurosis of the FCU distally. [Figure 1](#) details the cubital tunnel, the most common possible sites of compression of the ulnar nerve, and the release rate.

The main outcome measures assessed were the release rate of the cubital tunnel and the iatrogenic injury rate. Secondary criteria selected were the operative time, learning curve, and incision length for each technique.

Ultrasound-guided surgical technique

The ultrasound-guided procedures were performed using GE logiq ultrasound machine and 9/15 transducer type. The surgical dissection was performed through a millimetric skin incision using a KEMIS[®] knife (Newclip[®] Technics, France)

([Figure 2](#)). This type of knife has previously been used for the transection of the interosseous membrane of the forearm [14] and carpal tunnel release [15, 16] with success.

With the elbow on an arm board, we first start by identifying the ulnar nerve in its groove on both a longitudinal and transverse US view. Identification of the entry point at the distal aspect of the ulnar groove is then performed using an intramuscular needle. Following that, a few millimeters incision is done using a 15-blade, and subcutaneous tissue dissection is performed with curved Halsted forceps until the distal aspect of Osborne's ligament is reached. The Kemis knife tip is then carefully inserted through our incision, and Osborne's ligament is slid under US control between the two arms of the C-shaped blade ([Figure 3](#)). The latter is advanced through the cubital tunnel retinaculum towards the Struthers' arcade, which is also released in the same fashion.

Then, using the same entry point, the blade is reinserted and oriented distally in the same plane and advanced under US guidance towards the aponeurosis between the two heads of the FCU that can now be released as well.

A complete section of the cubital tunnel is finally assessed with the same curved Halsted forceps under US transverse views. The release was completed, if needed, with the knife again.

Open surgical technique

The open technique consisted of dissection and identification of the ulnar nerve and *in situ* release of the cubital tunnel retinaculum, Struther's arcade, Osborne's ligament, and the aponeurosis between the two heads of FCU using a curved incision over the ulnar groove. ([Figures 2](#) and [3](#)).

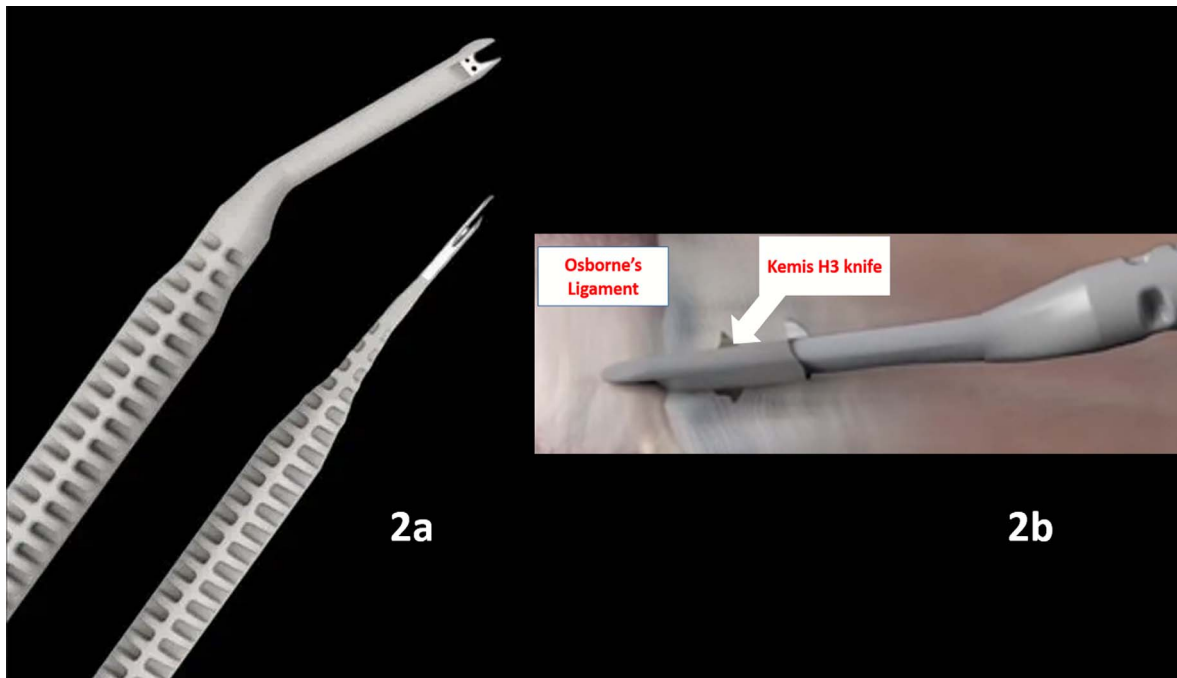


Figure 2. (a) Example of Kemis knives: on the left, the Kemis H3 blade used in the present study. On the right, the Kemis H1 blade can be used for treatment of trigger fingers or De Quervain tenosynovitis. (b) Illustration of the Kemis knife as used to transect Osborne's ligament.

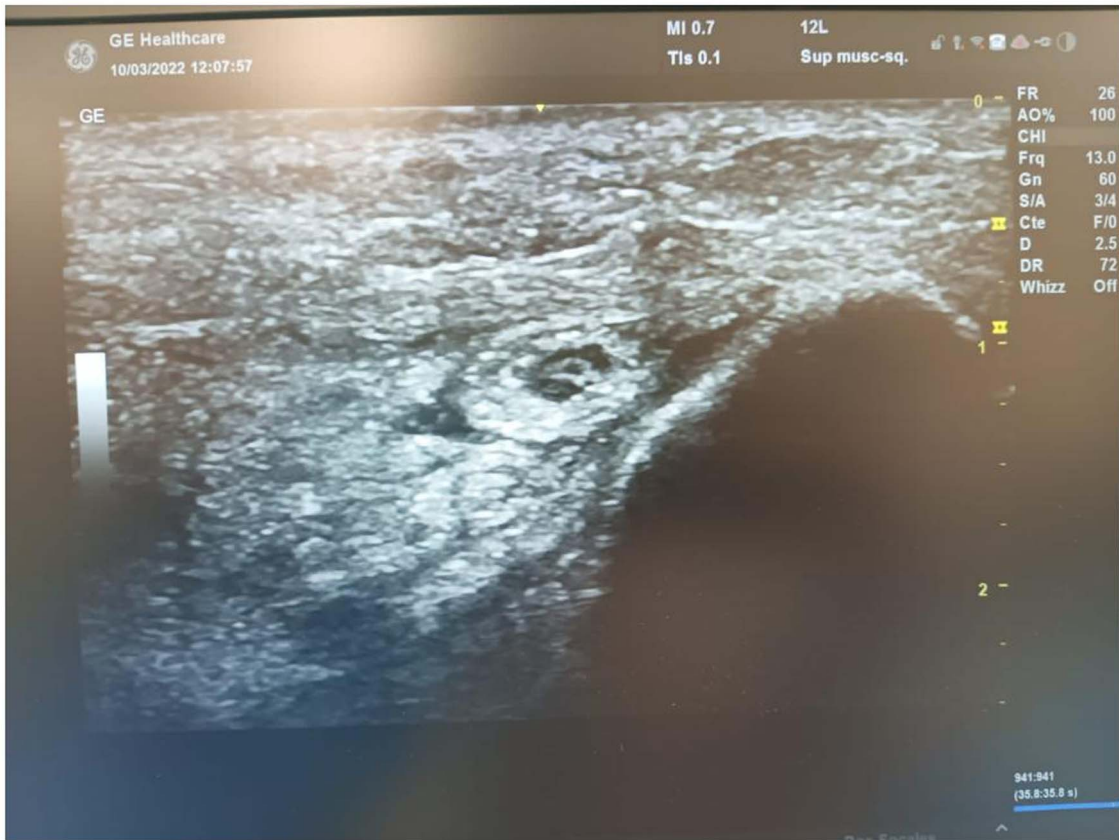

Figure 3. A transverse sonogram showing the compression site of ulnar nerve at medial elbow.

Table 1. Ultrasound-guided procedure outcomes.

Ultrasound-guided procedure (no)	1	2	3	4	5
Incision length (mm)	7	6	10	6	7
Cutting rate (%)	88	97	100	100	100
Duration (min)	24	22	14	11	12
Vascular injury	No	No	No	No	No
Flexor carpi ulnaris injury	Yes	No	No	No	No
Medial antebrachial cutaneous nerve injury	No	No	No	No	No
Osborne ligament release	Yes	Yes	Yes	Yes	Yes
Struthers ligament release	Yes	Yes	Yes	Yes	Yes
Flexor carpi ulnaris release	Yes	No	Yes	Yes	Yes

Table 2. Open release procedure outcomes.

Open release procedure (no)	1	2	3	4	5
Incision length	42	40	40	50	40
Cutting rate (%)	97	93	100	100	100
Duration (min)	29	34	32	40	25
Vascular injury	No	No	No	No	No
Flexor carpi ulnaris injury	No	No	Yes	No	No
Medial antebrachial cutaneous nerve injury	No	No	No	No	No
Osborne ligament release	Yes	Yes	Yes	Yes	Yes
Struthers ligament release	Yes	Yes	Yes	Yes	Yes
Flexor carpi ulnaris release	No	Yes	Yes	Yes	Yes

Statistical analysis

Qualitative variables were presented with their percentages. Quantitative variables were presented with their standard deviations and their minimum and maximum values. A Student's test was used for the paired variables. The significance threshold was 5% for all the tests.

Results

Section rates for both groups were comparable as the ultrasound-guided procedure had a mean rate of section of 0.97 ± 0.08 [0.88; 1], versus 0.93 ± 0.14 [0.93; 1] for the open release technique ($p = 0.35$). A complete section of the Osborne ligament and Struthers ligaments was consistently observed in both groups throughout the five trials.

The iatrogenic injury rate was also found to be comparable between the two groups since one case of FCU injury was noticed in each group, with no injuries in regards to other tendons, nerves (including the MABC and ulnar nerves), or vasculature in either group.

Operative time was shorter in the US-guided release group, with a mean duration of $16.6 \text{ min} \pm 6.9$ [11; 24], versus $32 \text{ min} \pm 12.9$ [29; 40] for the open release procedure ($p = 0.014$). The mean duration was divided by two between the first and the last cases in the ultrasound-guided technique, while it remained the same in the open release throughout.

Detailed data are reported in Tables 1 and 2 for the US-guided and open-release groups, respectively.

A fast learning curve was observed for both groups. Though incomplete section rates (and no release of the FCU aponeurosis) were noted in the first cases of both procedures,

they systematically reached 100% of the cases as of the 3rd case, regardless of the procedure. The learning curve was thus set at four cases for the ultrasound-guided technique to obtain a rapid, efficient, and injury-free release.

Finally, the mean incision length of the ultrasound-guided procedure was smaller than for the open technique ($7.2 \text{ mm} \pm 0.5$ [6; 10] in the ultrasound group, versus $42.4 \text{ mm} \pm 8.1$ [40, 50] in the open release technique one ($p = 0.96$).

Discussion

Cubital tunnel syndrome affects 1.8–5.9% of the general population [17], with inconsistent success rates for conservative measures (splinting, activity modification, steroid injection) [18]. When the latter fails, and surgical treatment is warranted, a wide variety of surgical options are available, with no consensus as to which is the most efficient or reliable [8, 9].

In this series of 10 cadaveric elbows, we compared the outcomes of an URUN to those of the standard open release (ORUN).

The result of our study suggests that URUN at the elbow could be as effective and safe as the open technique, with a shorter operative time and a fast learning curve provided that the operator is familiar with ultrasound imaging, all this through a significantly smaller incision.

However, a major limitation of this study is that it is purely anatomical, and long-term cohort studies on symptomatic patients' satisfaction are needed to confirm the superiority of URUN over ORUN. Moreover, the number of cadavers was limited to five for ethical considerations, and a larger number of procedures is needed to draw definitive conclusions as to the results mentioned above.

In this study, the total release rate was comparable for the two groups (95% and 100% in URUN and ORUN, respectively with no statistically significant difference ($p > 0.05$), while the number of iatrogenic lesions found after careful post-procedure dissection was identical in both series and similarly low. These findings highlight the similar effects of these two techniques in performing a complete release of the ulnar nerve, with none showing a clear superiority in terms of morbidity rate reduction.

These comparable outcomes were obtained with an operative time significantly shorter for the URUN group (16.6 min vs. 32 min), with the URUN being completed in nearly half as much time as the ORUN. This short operative time does not only favor URUN over ORUN but over endoscopic procedures as well, since the operative time of the latter varies in the literature between 35 min and 42 min [19, 20]. This advantage is significant when considering the cost of 1 min in the operating room is estimated to be 36–37\$ [21].

Furthermore, incomplete releases of the nerve were found only during the first two trials of both groups, the fourth and fifth trials showing a complete ulnar nerve release in both series, suggesting a similarly fast learning curve for an ultrasound-trained surgeon. This conclusion was furthermore supported for the URUN group as operative time was divided by two between the first and last trial. Further studies are needed to validate the hypothesized fast learning curve of URUN in a large population of surgeons.

Finally, a statistically significant difference in incision length was noted, with the ORUN incisions being nearly six times longer than their URUN counterparts. This highlights the minimally invasive character of the URUN, implying less scarring of soft tissue and better aesthetics, and suggests the possibility of reduced pain and faster recovery in live subjects [22]. It is worth mentioning that incision length in URUN was even smaller than that of the endoscopic techniques (15–30 mm) [23–26], or the mini-open release (1.5–2.5 cm) [27], potentially making the URUN the least invasive procedure to date.

More than 40% of patients with ulnar nerve entrapment at the elbow will eventually need surgery [28]. The challenge when it comes to surgical treatment in CuTS, as in every surgical procedure, is to provide patients with the most efficient treatment while reducing unnecessary trauma to surrounding areas as well as operative time. From this perspective, many techniques have been described. First, the open release of the ulnar nerve allows direct visualization of compressive sites to ensure freedom of the nerve's movement along its entire course [9]. Though it was found to be an effective technique with generally good results [29], complications such as superficial infections, wound dehiscence, incisional tenderness, and MABC nerve numbness was reported [30, 31], in addition to increased post-operative pain and delayed healing time [9]. The vast majority of surgeons still prefer open in situ decompression of the ulnar nerve at the elbow for its ease, low cost, and accessibility [32], with transposition progressively falling out of favor as multiple studies demonstrated an increased risk of complications with no added benefits [33–37].

The inconveniences of open ulnar nerve release led to the introduction of endoscopic decompression, first described in 1995 by Tsai et al. [5]. This technique appeared to offer the

same results as open in situ decompression but with less scar tenderness [38], less intraoperative trauma [31, 39], fewer complications [40–44], faster recovery with an earlier return to work [26], at the expenses of a slightly longer operative time [8], an increased equipment cost and the need for more trained staff [9].

Mini-open cubital tunnel release was then introduced by Taniguchi et al. in 2022 in an attempt to get comparable results with the endoscopic technique through a 1.5–2.0 cm incision without the disadvantages of the latter [6]. The six subsequent studies conducted so far [20, 45–49] showed similar outcomes to the endoscopic technique in terms of patient satisfaction or complications, without the need for endoscopic equipment or an adequately trained team [27].

Later, in an effort to improve the effectiveness furthermore of in situ decompression while minimizing complication rates, URUN was developed by Poujade et al. in 2014 [10]. Ultrasounds are a cheap and radiation-free tool for anatomical and dynamic evaluation of upper extremity nerves and other soft tissues [50, 51]. Moreover, the anatomy of the ulnar nerve and its surroundings in CuTs is well documented and detailed in the scientific literature [52], with studies demonstrating its ability to identify and localize the compression better than electromyography [53, 54]. As such, this technology gained importance as a reliable complementary diagnostic tool for ulnar nerve entrapment [55–57]. The therapeutic role of US in CuTS has been traditionally limited to guiding corticosteroid injections [58, 59] in the same way it is used in other pathologies, such as lateral epicondylitis [60]. Some authors advocate for the use of US to better localize the site of compression pre-operatively and therefore target their decompression [61], however, the use of US as a guiding tool for real-time nerve decompression is still sporadic, and literature concerning URUN is still sparse.

Table 3 summarizes the current literature regarding CuTS release under ultrasound. To Note that all studies to date addressed the most common sites of ulnar nerve entrapment, but not post-traumatic etiologies or CuTS caused by abnormal muscle variants [62].

In the study by Poujade et al., percutaneous URUN was performed on 16 cadaveric specimens with no control group [10]. Similarly to our findings, no iatrogenic damage was noted on the nerves, and no remaining compressive structures were noted after URUN though fibers of one structure or more remained but with no evidence of true compression. Furthermore, URUN was found to carry the advantage of adapting each procedure according to the site of compression. Moreover, short operative times that were found to match those of the present study were noted with the same trend towards a shorter operative time between the first and last procedure, implying a fast learning curve for US-trained surgeons.

Ultrasound-guided ulnar nerve decompression may allow for a targeted and precise soft tissue release of the ulnar nerve while keeping important structures in sight. This application of ultrasonography could be an asset in the armamentarium of minimally invasive surgical treatment of CuTS. If further studies validate our findings, this procedure could be performed in ambulatory care or the interventional radiology room under local anesthesia and light sedation, similarly to what is done in ultrasound-guided carpal tunnel release [15, 16, 63].

Table 3. Summary of current literature regarding US-guided CuTS release. NR: Not reported.

Study	Study design	Material used	Mean operative time	Mean Incision length	Outcomes	Limitations
Poujade et al. [10]	Cadaveric study on 16 elbows	Retractable Rosette blade	14.5 min	NR All were < 5 mm	– No remaining compressive structures – No iatrogenic injuries	– No comparison with a control group using another technique
Boettcher et al. [12]	Case report on a 19-year-old professional swimmer	Styilet inserted in a spinal gauge and rotated to create a “V” cutting shape	NR	NR	– Symptoms resolved – Patient returned to sport at 2 weeks	Only the Cubital tunnel retinaculum was transected
Guo et al. [11]	Cadaveric study on 19 elbows	Percutaneous looped thread cubital tunnel release. Loop & Shear™	20 min	No skin incision	Ulnar nerve was fully decompressed in all cases with no iatrogenic injury	– Only Osborne’s ligament and deep fascia were evaluated – No comparison with a control group using another technique
Kang et al. [13]	Cadaveric study on 29 elbows	Percutaneous looped thread cubital tunnel release. 3 types of dissecting threads were compared: – Smartwire-01 – Ultra V sswire – Smartwire-01	NR	No skin incision	– 2/29 specimens were incompletely dissected – No iatrogenic injuries	No analysis for common compression sites, such a Struther’s arcade or deep flexor pronator aponeurosis
Gruber et al. [64]	Case report on a 28-year-old road worker	Acufex hook knife	NR	NR	– Symptoms resolved at 8 days post-op – No iatrogenic injury	The Osborne’s ligament was the only structure to be transected

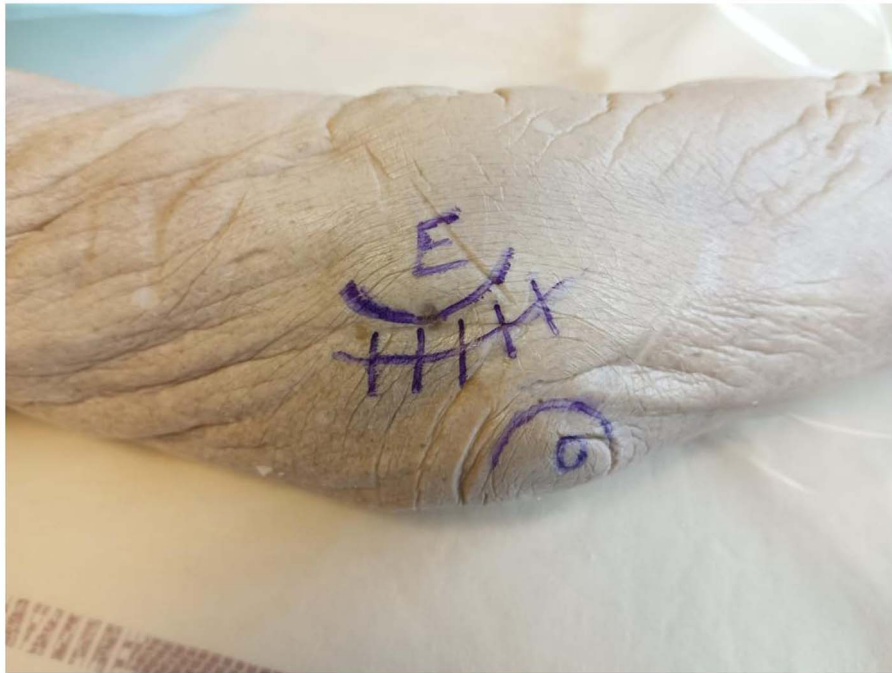


Figure 4. Incision of the open technique.

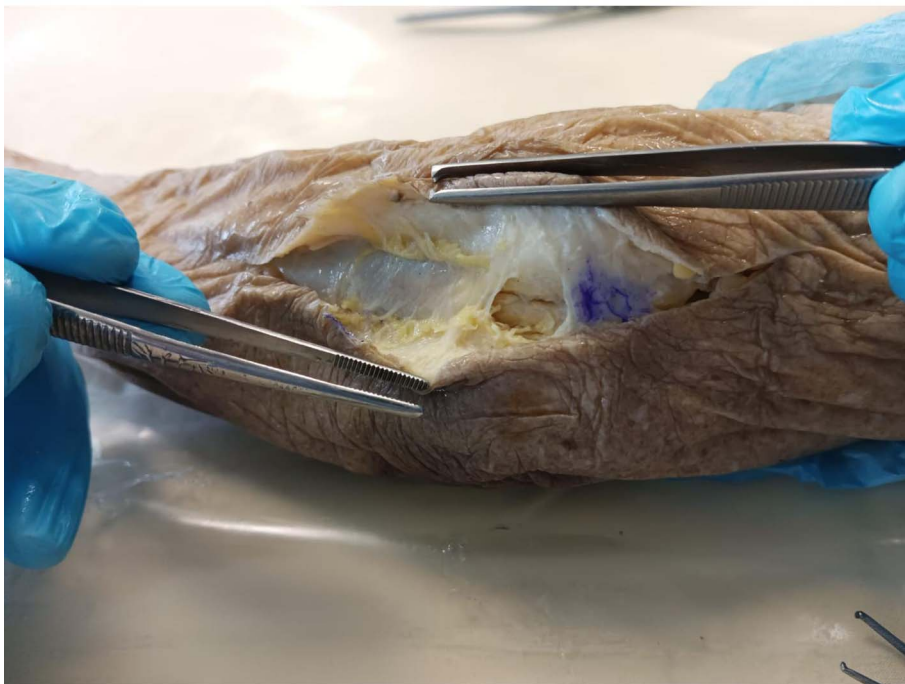


Figure 5. Sites of ulnar nerve compression.

Conflict of interest

The authors declare that they have no relevant financial or non-financial interest to report.

Funding

This research did not receive any specific funding.

Ethical approval

Ethical approval was obtained from the ethical review committee of our institution: Faculty of Medicine of Montpellier-Nîmes, France.

Informed consent

No informed consent was required for this study.

Author's contribution

J. Mansour: Writing, *J. Ghanimeh*: Writing, *A. Gherisi*: Review, *B. Moutinot*: Writing, *P. Kouyoumdjian*: Conceptualization, *R. Coulomb*: Reviewing, *O. Mares*: Reviewing, editing.

Acknowledgements. No acknowledgment for this study.

References

- Palmer BA, Hughes TB (2010) Cubital tunnel syndrome. *J Hand Surg* 35, 153–163.
- Assmus H, Antoniadis G, Bischoff C, et al. (2011) Cubital tunnel syndrome – A review and management guidelines. *Cent Eur Neurosurg* 72, 90–98.
- Fèvre E (1878) Étude sur les paralysies du nerf cubital. Doctoral dissertation. University of Paris.
- Buzzard EF (1922) Some varieties of traumatic and toxic ulnar neuritis. *The Lancet* 199, 317–319.
- Tsai TM, Bonczar M, Tsuruta T, Syed SA (1995) A new operative technique: Cubital tunnel decompression with endoscopic assistance. *Hand Clin* 11, 71–80.
- Taniguchi Y, Takami M, Takami T, Yoshida M (2002) Simple decompression with small skin incision for cubital tunnel syndrome. *J Hand Surg Edinb Scotl* 27, 559–562.
- Dellon AL (1989) Review of treatment results for ulnar nerve entrapment at the elbow. *J Hand Surg* 14, 688–700.
- Schmidt S, Kleist Welch-Guerra W, Matthes M, Baldauf J, Schminke U, Schroeder HWS (2015) Endoscopic vs. open decompression of the ulnar nerve in cubital tunnel syndrome: A prospective randomized double-blind study. *Neurosurgery* 77, 960–971.
- Carlton A, Khalid SI (2018) Surgical approaches and their outcomes in the treatment of cubital tunnel syndrome. *Front Surg* 5, 48.
- Poujade T, Hanouz N, Lecoq B, Hulet C, Collon S (2014) Ultrasound-guided surgical treatment for ulnar nerve entrapment: A cadaver study. *Chir Main* 33, 256–262.
- Guo D, Kliot M, McCool L, Senk A, Tonkin B, Guo D (2019) Percutaneous cubital tunnel release with a dissection thread: A cadaveric study. *J Hand Surg Eur* 44, 920–924.
- Boettcher BJ, Finnoff JT (2020) Ultrasound-guided cubital tunnel decompression in a collegiate swimmer: A case report. *Clin J Sport Med* 30, 15–17.
- Kang M, Nam YS, Kim IJ, Park HY, Ham JR, Kim JM (2022) A cadaveric study of thread cubital tunnel release with newly developed threads. *J Korean Neurosurg Soc* 65, 307–314.
- Descamps J, Costil V, Aparad T (2020) Ultrasound-guided transection of the interosseous membrane of the forearm. *Hand Surg Rehabil* 39, 167–170.
- Aparad T, Candelier G (2017) Surgical ultrasound-guided carpal tunnel release. *Hand Surg Rehabil* 36, 333–337.
- Candelier G, Aparad T (2016) Apport du Walant dans la chirurgie échoguidée du syndrome du canal carpien, une nouvelle approche hyper-ambulatoire. *Hand Surg Rehabil* 35, 438–439.
- An TW, Evanoff BA, Boyer MI, Osei DA (2017) The prevalence of cubital tunnel syndrome: A cross-sectional study in a US metropolitan cohort. *J Bone Joint Surg Am* 99, 408–416.
- Kooner S, Cinats D, Kwong C, Matthewson G, Dhaliwal G (2019) Conservative treatment of cubital tunnel syndrome: A systematic review. *Orthop Rev* 11, 7955.
- Krejčí T, Večeřa Z, Krejčí O, Šalounová D, Houdek M, Lipina R (2018) Comparing endoscopic and open decompression of the ulnar nerve in cubital tunnel syndrome: A prospective randomized study. *Acta Neurochir (Wien)* 160, 2011–2017.
- Bolster MAJ, Zöphel OT, van den Heuvel ER, Ruettermann M (2014) Cubital tunnel syndrome: A comparison of an endoscopic technique with a minimal invasive open technique. *J Hand Surg Eur* 39, 621–625.
- Childers CP, Maggard-Gibbons M (2018) Understanding costs of care in the operating room. *JAMA Surg* 153, e176233.
- Ioannidis A, Arvanitidis K, Filidou E, et al. (2018) The length of surgical skin incision in postoperative inflammatory reaction. *JSLs* 22(4), e2018.00045.
- Fok MWM, Cobb T, Bain GI (2021) Endoscopic cubital tunnel decompression – Review of the literature. *J Orthop Surg Hong Kong* 29, 1–12.
- Law TY, Hubbard ZS, Chieng LO, Chim HW (2017) Trends in open and endoscopic cubital tunnel release in the medicare patient population. *Hand (NY)* 12, 408–412.
- Hoffmann R, Siemionow M (2006) The endoscopic management of cubital tunnel syndrome. *J Hand Surg Edinb Scotl* 31, 23–29.
- Tsai TM, Chen IC, Majd ME, Lim BH (1999) Cubital tunnel release with endoscopic assistance: Results of a new technique. *J Hand Surg* 24, 21–29.
- Adkinson JM, Chung KC (2014) Minimal-incision in situ ulnar nerve decompression at the elbow. *Hand Clin* 30, 63–70.
- Osei DA, Groves AP, Bommarito K, Ray WZ (2017) Cubital tunnel syndrome: Incidence and demographics in a national administrative database. *Neurosurgery* 80, 417–420.
- Nathan PA, Istvan JA, Meadows KD (2005) Intermediate and long-term outcomes following simple decompression of the ulnar nerve at the elbow. *Chir Main* 24, 29–34.
- Gervasio O, Gambardella G, Zaccone C, Branca D (2005) Simple decompression versus anterior submuscular transposition of the ulnar nerve in severe cubital tunnel syndrome: A prospective randomized study. *Neurosurgery* 56, 108–117.
- Dützmans S, Martin KD, Sobotta S, et al. (2013) Open vs. retractor-endoscopic in situ decompression of the ulnar nerve in cubital tunnel syndrome: A retrospective cohort study. *Neurosurgery* 72, 605–616.
- Yahya A, Malarkey AR, Eschbaugh RL, Bamberger HB (2018) Trends in the surgical treatment for cubital tunnel syndrome: A survey of members of the American society for surgery of the hand. *Hand (NY)* 13, 516–521.
- Messina A, Messina JC (1995) Transposition of the ulnar nerve and its vascular bundle for the entrapment syndrome at the elbow. *J Hand Surg Edinb Scotl* 20, 638–648.
- Nabhan A, Ahlhelm F, Kelm J, Reith W, Schwerdtfeger K, Steudel WI (2005) Simple decompression or subcutaneous anterior transposition of the ulnar nerve for cubital tunnel syndrome. *J Hand Surg Edinb Scotl* 30, 521–524.
- Bartels RHMA, Verhagen WIM, van der Wilt GJ, Meulstee J, van Rossum LGM, Grotenhuis JA (2005) Prospective randomized controlled study comparing simple decompression versus anterior subcutaneous transposition for idiopathic neuropathy of the ulnar nerve at the elbow: Part 1. *Neurosurgery* 56, 522–530.

36. Biggs M, Curtis JA (2006) Randomized, prospective study comparing ulnar neurolysis in situ with submuscular transposition. *Neurosurgery* 58, 296–304.
37. Wade RG, Griffiths TT, Flather R, Burr NE, Teo M, Bourke G (2020) Safety and outcomes of different surgical techniques for cubital tunnel decompression: A systematic review and network meta-analysis. *JAMA Netw Open* 3, e2024352.
38. Byvaltsev VA, Stepanov IA, Kerimbayev TT (2020) A systematic review and meta-analysis comparing open versus endoscopic in situ decompression for the treatment of cubital tunnel syndrome. *Acta Neurol Belg* 120, 1–8.
39. Bacle G, Marteau E, Freslon M, et al. (2014) Cubital tunnel syndrome: comparative results of a multicenter study of 4 surgical techniques with a mean follow-up of 92 months. *Orthop Traumatol Surg Res* 100, 205–208.
40. Caliandro P, La Torre G, Padua R, Giannini F, Padua L (2012) Treatment for ulnar neuropathy at the elbow. *Cochrane Database Syst Rev* 11, CD006839.
41. Mariani PP, Golanò P, Adriani E, Llusà M, Camilleri G (1999) A cadaveric study of endoscopic decompression of the cubital tunnel. *Arthrosc J Arthrosc Relat Surg* 15, 218–222.
42. Oertel J, Keiner D, Gaab MR (2010) Endoscopic decompression of the ulnar nerve at the elbow. *Neurosurgery* 66, 817–824.
43. Kovachevich R, Steinmann SP (2012) Arthroscopic ulnar nerve decompression in the setting of elbow osteoarthritis. *J Hand Surg* 37, 663–668.
44. Toirac A, Giugale JM, Fowler JR (2017) Open versus endoscopic cubital tunnel in situ decompression: A systematic review of outcomes and complications. *Hand (NY)* 12, 229–235.
45. Calisaneller T, Ozdemir O, Caner H, Altinors N (2011) Simple decompression of the ulnar nerve at the elbow via proximal and distal mini skin incisions. *Turk Neurosurg* 21, 167–171.
46. Karthik K, Nanda R, Storey S, Stothard J (2012) Severe ulnar nerve entrapment at the elbow: Functional outcome after minimally invasive in situ decompression. *J Hand Surg Eur* 37, 115–122.
47. Lan ZD, Tatsui CE, Jalali A, et al. (2015) Outcomes of a novel minimalist approach for the treatment of cubital tunnel syndrome. *J Clin Neurosci* 22, 964–968.
48. Cho YJ, Cho SM, Sheen SH, Choi JH, Huh DH, Song JH (2007) Simple decompression of the ulnar nerve for cubital tunnel syndrome. *J Korean Neurosurg Soc* 42, 382–387.
49. Jeon IH, Micić I, Lee BW, Lee SM, Kim PT, Stojiljković P (2010) Simple in situ decompression for idiopathic cubital tunnel syndrome using minimal skin incision. *Med Pregl* 63, 601–606.
50. Tortora S, Messina C, Albano D, et al. (2021) Ultrasound-guided musculoskeletal interventional procedures around the elbow, hand and wrist excluding carpal tunnel procedures. *J Ultrason* 21, 169–176.
51. Burt AM, Huang BK (2017) Imaging review of lipomatous musculoskeletal lesions. *SICOT J* 3, 34.
52. Aird C, Thoirs K, Maranna S, Massy-Westropp N (2019) Ultrasound measurements and assessments of the ulnar nerve at the elbow and cubital tunnel: A scoping review. *J Diagn Med Sonogr* 35, 474–482.
53. Beekman R, Schoemaker MC, Van Der Plas JPL, et al. (2004) Diagnostic value of high-resolution sonography in ulnar neuropathy at the elbow. *Neurology* 62, 767–773.
54. Yoon JS, Walker FO, Cartwright MS (2010) Ulnar neuropathy with normal electrodiagnosis and abnormal nerve ultrasound. *Arch Phys Med Rehabil* 91, 318–320.
55. Beekman R, Visser LH, Verhagen WI (2011) Ultrasonography in ulnar neuropathy at the elbow: A critical review. *Muscle Nerve* 43, 627–635.
56. Babusiaux D, Laulan J, Bouilleau L, et al. (2014) Contribution of static and dynamic ultrasound in cubital tunnel syndrome. *Orthop Traumatol Surg Res* 100, 209–212.
57. Mezian K, Jačisko J, Kaiser R, et al. (2021) Ulnar neuropathy at the elbow: From ultrasound scanning to treatment. *Front Neurol* 12, 661441.
58. Vuillemin V, Guerini H, Morvan G (2012) Musculoskeletal interventional ultrasonography: The upper limb. *Diagn Interv Imaging* 93, 665–673.
59. Rampen AJJ, Wirtz PW, Tavy DLJ (2011) Ultrasound-guided steroid injection to treat mild ulnar neuropathy at the elbow. *Muscle Nerve* 44, 128–130.
60. Ben-Nafa W, Munro W (2018) The effect of corticosteroid versus platelet-rich plasma injection therapies for the management of lateral epicondylitis: A systematic review. *SICOT J* 4, 11.
61. Gao J-M, Yuan Y, Gong K-T, Ma X-L, Chen X (2021) Ultrasound-assisted precise in situ decompression for cubital tunnel syndrome. *Orthop Surg* 13, 840–846.
62. Jeon I-H, Kim P-T, Park I-H, Kyung H-S, Ihn J-C (2002) Cubital tunnel syndrome due to the anconeus epitrochlearis in an amateur weight lifter. *SICOT Case-Reports*.
63. Petrover D, Rchette P (2018) Treatment of carpal tunnel syndrome: From ultrasonography to ultrasound guided carpal tunnel release. *Joint Bone Spine* 85, 545–552.
64. Gruber H, Honold S, Skalla E, Korschake M, Loizides A (2022) Novel minimally invasive ultrasound-guided cubital tunnel release: Extending the scope? *Ultraschall Med – Eur J Ultrasound* 43, 403–405.

Cite this article as: Mansour J, Ghanimeh J, Ghersi A, Moutinot B, Coulomb R, Kouyoumdjian P & Mares O (2022) Percutaneous ultrasound-guided ulnar nerve release technique compared to open technique: A cadaveric study. *SICOT-J* 8, 40