



Primary adrenal lymphoma causing hypoaldosteronism in a cat

Jessica F Romine¹, Angela R Kozicki² and Marc S Elie¹

Journal of Feline Medicine and Surgery
Open Reports
1–6

© The Author(s) 2016
Reprints and permissions:
sagepub.co.uk/journalsPermissions.nav
DOI: 10.1177/2055116916684409
jfmsopenreports.com

This paper was handled and processed
by the American Editorial Office (AAFP)
for publication in JFMS Open Reports



Abstract

Case summary A 10-year-old, 5.1 kg (11.2 lb), male castrated cat was presented with signs of lethargy and decreased appetite at home after being previously healthy. Serum biochemical analysis identified normokalemia (5.1 mmol/l; reference interval [RI] 3.4–5.6 mmol/l) and severe hyponatremia (123 mmol/l; RI 145–158 mmol/l), with an Na/K ratio of 24 (RI 32–41). Baseline serum cortisol was low to normal, but serum aldosterone was markedly decreased with a pre-adrenocorticotropic hormone stimulation concentration of 13 pmol/l (RI 194–388 pmol/l) and post-adrenocorticotropic hormone stimulation concentration of 21 pmol/l (RI 277–721 pmol/l). Hematologic and biochemical analyses were otherwise unremarkable. Abdominal ultrasound revealed bilaterally enlarged adrenal glands with no other abnormalities noted; thoracic radiographs also did not identify any signs of metastasis. Fine-needle aspiration was strongly suggestive of lymphoma of the adrenal glands, and PCR for antigen receptor rearrangement was positive for B-cell clonal expansion; based on these findings, a diagnosis of primary adrenal B-cell lymphoma was made. Stable disease was achieved for a short period of time following vincristine, cyclophosphamide, prednisolone and fludrocortisone therapy, followed by progressive adrenal enlargement and electrolyte derangements that responded to neither doxorubicin nor adjustments in fludrocortisone dosage. Ultrasonographic metastasis was not identified at any time, and other organ derangements were not noted on hematologic or biochemical analyses. The cat was euthanized 55 days after initial presentation.

Relevance and novel information This is the first report of primary adrenal lymphoma in a cat, with presenting signs compatible with hypoaldosteronism. Lymphoma should be a differential for cats presenting with adrenal enlargement or clinical signs and biochemical changes consistent with hypoaldosteronism or hypoadrenocorticism.

Accepted: 1 November 2016

Case description

A 10-year-old, 5.1 kg (11.2 lb), male castrated domestic shorthair cat was examined for a 1 day history of lethargy and hiding in unusual places. The cat had eaten during the day but at a slower pace than normal and had not displayed any vomiting, diarrhea, coughing or sneezing. Before this incident the cat did not have any known medical issues, was housed indoors and had an up-to-date vaccine status. A SNAP FeLV/FIV ELISA assay (IDEXX) was negative 2 years prior to presentation. On physical examination the cat was alert, appeared euhydrated and had a body condition score of 7/9.

Results of hematologic testing were all within normal limits (see Table S1 in the supplementary material). Serum biochemical analysis revealed hypochloremia (97 mmol/l; reference interval [RI] 104–128 mmol/l), mild hypermagnesemia (1.3 mmol/l; RI 0.75–1.25 mmol/l),

normal potassium (5.1 mmol/l; RI 3.4–5.6 mmol/l) and severe hyponatremia (123 mmol/l; RI 145–158 mmol/l) with an Na/K ratio of 24 (RI 32–41) (see Table S2 in the supplementary material). Total thyroxine was normal (32.1 nmol/l; RI 10.3–51.5 nmol/l). Urine specific gravity was 1.028 (RI 1.015–1.060); no other abnormalities were noted on urinalysis. Indirect systolic blood pressure obtained via Doppler was 85 mmHg. A baseline serum

¹Department of Internal Medicine, BluePearl Veterinary Partners, Southfield, MI, USA

²Department of Oncology, BluePearl Veterinary Partners, Southfield, MI, USA

Corresponding author:

Jessica Romine DVM, BluePearl Veterinary Partners,
29080, Inkster Road, Southfield, MI 48034, USA
Email: jessica.romine@bluepearlvet.com



Creative Commons Non Commercial CC-BY-NC: This article is distributed under the terms of the Creative Commons

Attribution-NonCommercial 3.0 License (<http://www.creativecommons.org/licenses/by-nc/3.0/>) which permits non-commercial use, reproduction and distribution of the work without further permission provided the original work is attributed as specified on the SAGE and Open Access pages (<https://us.sagepub.com/en-us/nam/open-access-at-sage>).

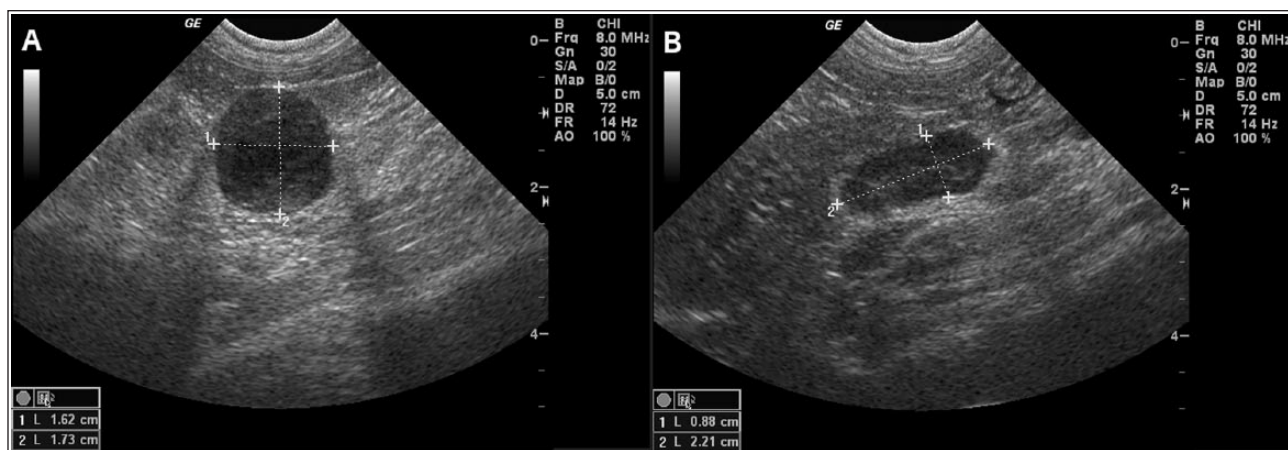


Figure 1 Ultrasonographic images of the (a) left and (b) right adrenal glands at presentation. Note the heterogeneous and hypoechoic appearance; the right adrenal gland retains a recognizable adrenal shape

cortisol concentration was low to normal at 57.4 nmol/l (RI 8.3–242.8 nmol/l).

Three-view thoracic radiographs identified a small caudal vena cava and otherwise normal cardiovascular structures. Abdominal ultrasound (GE Logiq 9 Ultrasound Machine) performed by a board-certified radiologist identified a markedly enlarged (2 cm × 1.6 cm × 1.7 cm), heterogeneous and hypoechoic left adrenal gland and an enlarged (2.2 cm × 0.8 cm × 0.8 cm) hypoechoic right adrenal gland (Figure 1). No evidence of vascular invasion was identified in either adrenal gland. The remainder of the abdomen was normal, with no lymphadenopathy or other changes noted.

The cat initially received a 30 ml/kg intravenous (IV) bolus of saline (0.9% NaCl) and was then administered saline at 125 ml/kg/day. The cat ate overnight and its blood pressure improved to 130 mmHg. On day 2 the cat's electrolyte derangements had improved (sodium 141 mmol/l, potassium 4.3 mmol/l) but were still present (see Table S3 in the supplementary material). Mild hyperthermia was noted, at 39.6°C (103.2°F). Serology for *Toxoplasma gondii* antibodies were submitted and empiric treatment with clindamycin (12 mg/kg IV q12h) was instituted. An adrenocorticotropic hormone (ACTH) stimulation test, using previously described protocols,¹ was performed with a 5 µg/kg dose of cosyntropin (Amphastar Pharmaceuticals) to measure pre- and post-ACTH serum aldosterone concentration. Cortisol concentrations were also intended to be measured; unfortunately, owing to laboratory miscommunications, these were not performed.

On day 3 the cat continued to eat well; sodium had increased but was still below the RI at 144 mmol/l and potassium had increased further to 4.4 mmol/l. Its blood pH had also decreased, to 7.289 (previously 7.337; RI 7.250–7.400). The results of the aldosterone testing revealed a pre-ACTH aldosterone concentration of

13 pmol/l (RI 194–388 pmol/l) and a post-ACTH concentration of 21 pmol/l (RI 277–721 pmol/l), indicating severe hypoaldosteronism. Fludrocortisone acetate (0.01 mg/kg PO q24h) was added to the cat's treatments.

On day 4, *T gondii* titers were negative at <1:64 for both IgG and IgM, and clindamycin and IV fluid therapy were discontinued. Ultrasound revealed a static right adrenal gland but enlargement of the left adrenal gland (increased to 2.3 cm × 1.6 cm × 1.8 cm). Ultrasound-guided fine-needle aspiration of the left adrenal gland was performed, and a cytologic diagnosis of lymphoma was made by a board-certified clinical pathologist. PCR for antigen receptor rearrangement (PARR) was positive for B-cell clonal expansion. Cytology of the liver and spleen did not show evidence of metastasis to those organs. The cat was discharged to the owner on fludrocortisone pending consultation with the oncology service.

Seven days after initial presentation the cat was presented to the oncology service for assessment of bilateral lymphoma of the adrenal glands. It weighed 4.9 kg. The cyclophosphamide–vincristine–doxorubicin–prednisolone (CHOP) UW-Madison protocol was selected,² and the cat received 0.7 mg/m² vincristine IV and was discharged with prednisolone (2.0 mg/kg PO q24h), maropitant (1.6 mg/kg PO q24h as needed for nausea), mirtazapine (0.76 mg/kg PO q72h as needed for inappetence) and continued fludrocortisone.

The cat's owner reported that the cat initially did well at home, but 7 days after receiving vincristine it became inappetent and lethargic. The cat presented the next day, where its body weight was 4.70 kg and a complete blood count revealed a normal white blood cell count. The cat received 32 ml/kg Lactated Ringer's Solution subcutaneously and prednisolone was continued at the current dose (2.1 mg/kg PO q24h). It was re-evaluated on day 20 since initial presentation where its body weight had increased to 4.75 kg and its owner reported improved

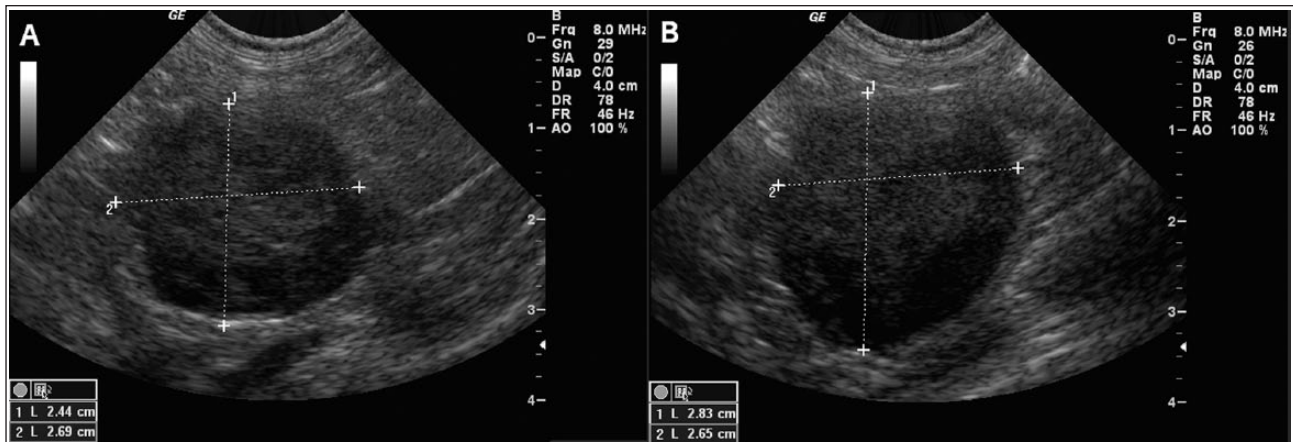


Figure 2 Ultrasonographic images of the (a) left and (b) right adrenal glands on day 54. Both adrenal glands are now markedly enlarged with a complete loss of normal architecture

appetite and energy levels. The cat received 250 mg/m² cyclophosphamide orally. Electrolytes were revealed to be once again deranged, with a sodium of 133 mmol/l and a potassium of 4.9 mmol/l, so its fludrocortisone was increased to 0.01 mg/kg (PO q12h). Prednisolone was tapered to 1.6 mg/kg (PO q24h).

On day 27 the cat was stable and doing well, with a leukocyte count of $8.43 \times 10^9/l$ (RI 3.5–17.0 $\times 10^9/l$) and a neutrophil count of $7.31 \times 10^9/l$ (RI 2.5–8.5 $\times 10^9/l$) (Table S1 in the supplementary material). It received a decreased dose of 0.6 mg/m² of vincristine given its inappetence after the initial dose, and prednisolone was tapered to 1.1 mg/kg (PO q24h), but on day 31 the cat was presented to the emergency service for lethargy and anorexia. The cat's weight had decreased to 4.4 kg and it was mildly febrile at 39.4°C (102.9°F). Biochemical analysis revealed a mild hyponatremia at 142 mmol/l and normokalemia at 4.3 mmol/l (Table S3 in the supplementary material). Complete blood count revealed a non-regenerative anemia at 0.25 l/l with 17,000/ μ l reticulocytes (RI 0–45,000/ μ l), along with a severe leukopenia at $0.6 \times 10^9/l$, including a lymphopenia at $0.348 \times 10^9/l$ (RI 1.2–8.0 $\times 10^9/l$) and severe neutropenia at $0.06 \times 10^9/l$. Bone marrow suppression secondary to chemotherapy was suspected, an IV catheter was placed using aseptic technique and the cat was hospitalized on 0.9% NaCl IV at 75 ml/kg/day, enrofloxacin (5.1 mg/kg IV q24h), ampicillin (22.7 mg/kg IV q8h) and maropitant (1.0 mg/kg SC q24h). Barrier nursing was maintained throughout hospitalization. Fludrocortisone (0.01 mg/kg PO q12h) was continued. The cat was discharged 48 h later on amoxicillin-clavulanic acid (14.2 mg/kg PO q12h), prednisolone (1.1 mg/kg PO q24h) and fludrocortisone, which was increased to 0.02 mg/kg in the morning and 0.01 mg/kg in the evening.

The cat was presented on day 35 for re-evaluation; it was doing well at home but its body weight had

decreased to 4.3 kg. Recheck abdominal ultrasound revealed a stable left adrenal gland (2.3 cm \times 1.8 cm \times 1.8 cm) and a more enlarged right adrenal gland (2.1 cm \times 2.0 cm \times 1.9 cm). The abdomen otherwise remained normal. Doxorubicin (1.0 mg/kg IV) was administered with plans to transition to a single-agent protocol because of the lack of response to vincristine and cyclophosphamide, and evidence of progressive disease based on declining body weight and enlarging adrenal glands. By day 48 the cat weighed 4.0 kg, but its owner reported it was much improved at home with a good appetite and energy level. Electrolyte measurements revealed a low-to-normal sodium level (144 mmol/l) and high normal potassium level (4.5 mmol/l). The cat received a second dose of doxorubicin and prednisolone was continued at 1.2 mg/kg (PO q24h).

On day 54 the cat was presented for abdominal ultrasound; its body weight had decreased further to 3.8 kg and its appetite had become moderately decreased. Abdominal ultrasound revealed progressive enlargement of both the left (2.4 cm \times 2.6 cm \times 2.9 cm) and right (2.8 cm \times 2.6 cm \times 2.8 cm) adrenal glands, with the surrounding tissue noted to be mildly hyperechoic (Figure 2). No lymphadenopathy or further abnormalities were identified in the rest of the abdomen. The cat received 400 IU/kg asparaginase subcutaneously and was hospitalized for IV fluid therapy. The following day its electrolyte abnormalities had worsened, with a hyponatremia of 132 mmol/l and a hyperkalemia of 5.9 mmol/l; it remained lethargic and inappetent. Owing to lack of response to therapy and evidence of progressive disease the owners elected humane euthanasia; necropsy was declined.

Discussion

To our knowledge, this is the first description of a primary adrenal lymphoma (PAL) in a cat. This is a rare but

well-described syndrome in humans,³ but has not been reported in cats. Few studies have identified hypoadrenocorticism of various causes in cats,⁴⁻⁹ none of which identified lymphoma as an underlying cause, apart from a single case report of two cats with lymphoma metastasizing to the adrenal glands.¹⁰ A retrospective study of 33 cats with adrenal masses identified 17 carcinomas, 13 adenomas and three pheochromocytomas but no cases of lymphoma.¹¹ The single reported case study of two cats with hypoadrenocorticism as a manifestation of adrenal lymphoma identified multiple sites of metastasis, with evidence such as abdominal effusion or a mass effect present.¹⁰ A retrospective evaluation of metastatic tumors to the adrenal glands in domestic animals identified bilateral masses in 50% of cats, and lymphoma was identified as one of the metastasizing tumors.¹² The infiltration was severe and obliterating in 60%, regardless of underlying histopathology, which was suspected in the cat of the current report given that adrenal function must be compromised by at least 90% in order to detect clinical changes.¹³ In this cat, in contrast, thoracic radiographs and abdominal imaging revealed no abnormalities throughout the progression of the disease, with only the adrenal glands themselves increasing in size. Normal adrenal glands in cats measure from 0.45–1.37 cm in length,¹⁴ whereas this cat's adrenal glands ultimately reached 2.9 cm in length.

In one human study 71.4% of cases of PAL presented with hypocortisolism,¹⁵ whereas this cat's baseline cortisol concentrations were low to normal at the time of presentation. In the previous report, one cat had a low cortisol concentration and one cat had a low to normal cortisol concentration.¹⁰ This is consistent with Peterson's findings that not all cats with hypoadrenocorticism had cortisol concentrations below the RI, but all were at least low to normal.⁴ Aldosterone concentrations were not measured in either case of metastatic lymphoma, but that report did identify hyperkalemia in both cats.¹⁰ Previous reports of hypoadrenocorticism in cats have not thoroughly examined aldosterone concentrations in response to ACTH stimulation, although all 10 cats in the 1989 study did have abnormal serum sodium:potassium ratios, consistent with hypoaldosteronism.⁴ At least one case report has identified both low cortisol and aldosterone concentrations both pre- and post-ACTH administration.¹⁶ Studies have also confirmed that cats with normal adrenal function will show large increases in serum aldosterone concentrations after administration of both 125 µg/cat and 5 µg/kg,^{1,14} indicating that a low serum aldosterone concentration post-ACTH stimulation is a reliable indicator of mineralocorticoid insufficiency. A study has evaluated the effects of lymphoma on adrenal testing in dogs; none of these dogs had ACTH stimulation results consistent with hypoadrenocorticism,¹⁷ suggesting that lymphoma

is not an expected cause of low cortisol or aldosterone concentrations after ACTH stimulation.

Repeat cortisol concentration was not measured after the initial ACTH stimulation in this cat because of concurrent prednisolone administration as a part of the CHOP protocol, so whether it was initially hypocortisolemic or this eventually developed, hypocortisolemia cannot be determined. However, given the low-to-normal basal cortisol, hypotension and lack of stress leukogram or hyperglycemia upon initial presentation, along with the apparent response to corticosteroid supplementation, it is likely that hypocortisolemia was also present. Initial improvements in the cat's demeanor and appetite can likely be attributed to the exogenous corticosteroid administration (in the form of both fludrocortisone and prednisolone), as well as vincristine. This would also be consistent with PAL in humans, where hypoadrenocorticism is more common than hypoaldosteronism alone.³ Ideally histopathologic evaluation of the adrenal gland would also have been performed post mortem to evaluate changes in the zona glomerulosa, as well as the zona fasciculata. Post-mortem examination would also have allowed for confirmation of PAL – although lymphadenopathy or changes in other organs were not identified based on serial ultrasonography or biochemistry, the possibility of a separate primary tumor cannot be completely ruled out in this case. However, at no time were changes such as a mass effect or abdominal effusion noted, which were present in the two cats in which lymphoma metastasized to the adrenal glands.¹⁰

This is also the first known report of the use of chemotherapy for treatment of PAL in a cat – the two cats in the previous study of lymphoma and hypoadrenocorticism were euthanized without undergoing any chemotherapy other than corticosteroids administered prior to diagnosis.¹⁰ After vincristine and cyclophosphamide, stable disease was evident based on static ultrasound findings, and progressive disease was identified after two doses of doxorubicin; although the cat improved clinically at home after each dose it subsequently declined within 1–3 weeks each time. This is consistent with human studies, where the success rate is poor for those with tumor-induced adrenocortical insufficiency.¹⁸⁻²² In one study, all four patients with non-Hodgkin's lymphoma with signs of hypoadrenocorticism died of lymphoma within 6 months of the initiation of chemotherapy.¹⁸ Even in more recent studies where >50% of patients were alive after 1 year, the long-term prognosis remains poor.²³⁻²⁵

In the human literature, <200 cases of PAL have been reported,³ accounting for <1% of non-Hodgkin lymphomas,²⁶ and 10% of cases of bilateral adrenal masses.³ The two most common subtypes are diffuse large B cell (78%) and peripheral T cell (7%),³ and up to half of reported patients presented with signs of adrenal insufficiency.²⁶⁻²⁸ PARR of adrenal gland aspirates

in this cat similarly identified B-cell clonal expansion. In humans the disease tends to be highly symptomatic and aggressive, and appears to have a predilection for elderly males, although younger people and females have also been affected.³ The prognosis is poor compared with that of nodal diffuse large B-cell lymphoma,²⁶ and adrenalectomy does not appear to confer a survival benefit in humans.²⁹

More recently the addition of rituximab, a chimeric monoclonal antibody against the protein CD20, which is primarily found on the surface of immune system B cells, to the traditional CHOP protocol (R-CHOP) has been utilized in human patients with PAL leading to improved survival rates.^{29,30} One study reports that a single patient receiving R-CHOP achieved complete remission after three cycles of chemotherapy, remaining tumor-free 3 years after chemotherapy.³¹ A larger study of 31 patients identified a complete remission rate of 54.8% and an overall response rate of 87.0% with R-CHOP, with a 2 year overall survival of 68.3%,²⁹ an improvement over CHOP alone in PAL patients. The tumor in this case was found to be B cell in origin, although immunocytochemistry was not performed so the value of specific anti-CD20 monoclonal antibodies cannot be determined. The use of these therapies is just beginning to be investigated in dogs,^{32,33} and, at the time of writing, has not been investigated in cats but may offer improved survival in these species as well given the apparent similarities to the form of the disease seen in humans.

Conclusions

This case report describes a cat that presented for investigation of mild signs of lethargy and hyporexia, with laboratory testing consistent with hypoaldosteronism and adrenal insufficiency. A diagnosis of primary adrenal B-cell lymphoma was made using fine-needle aspiration and PARR, but the cat responded poorly to treatment for both lymphoma and hypoadrenocorticism. PAL has not previously been reported in cats, and should be a differential in cases of hypoaldosteronism, hypoadrenocorticism or adrenal masses. Future reports would provide more insight regarding presentations and prognosis.

Supplementary material

The following files are available:

Table S1 Complete blood count results over the course of the cat's disease

Table S2 Chemistry values at presentation

Table S3 Selected chemistry concentrations over the course of the cat's disease

Funding The authors received no financial support for the research, authorship, and/or publication of this article.

Conflict of interest The authors declared no potential conflicts of interest with respect to the research, authorship, and/or publication of this article.

References

- DeClue AE, Martin LG, Behrend EN, et al. **Cortisol and aldosterone response to various doses of cosyntropin in healthy cats.** *J Am Vet Med Assoc* 2011; 238: 176–182.
- Withrow SJ, Vail DM and Page RL. **Hematopoietic tumors.** In: Small animal clinical oncology. 5th ed. St Louis, MO: Elsevier Saunders, 2013, pp 608–678.
- Rashidi A and Fisher SI. **Primary adrenal lymphoma: a systematic review.** *Ann Hematol* 2013; 92: 1583–1593.
- Peterson ME, Greco DS and Orth DN. **Primary hypoadrenocorticism in ten cats.** *J Vet Intern Med* 1989; 3: 55–58.
- Johnessee JS, Peterson ME and Gilbertson SR. **Primary hypoadrenocorticism in a cat.** *J Am Vet Med Assoc* 1983; 183: 881–882.
- Tasker S, MacKay AD and Sparkes AH. **A case of feline primary hypoadrenocorticism.** *J Feline Med Surg* 1999; 1: 257–260.
- Hock CE. **Atypical hypoadrenocorticism in a Birman cat.** *Can Vet J* 201; 52: 893–896.
- Stonehewer J and Tasker S. **Hypoadrenocorticism in a cat.** *J Small Anim Pract* 2001; 42: 186–190.
- Kasabalis D, Bodina E and Saridomichelakis MN. **Severe hypoglycaemia in a cat with primary hypoadrenocorticism.** *J Feline Med Surg* 2012; 14: 755–758.
- Parnell NK, Powell LL, Hohenhaus AE, et al. **Hypoadrenocorticism as the primary manifestation of lymphoma in two cats.** *J Am Vet Med Assoc* 1999; 214: 1208–1211.
- Daniel G, Mahony OM, Markovich JE, et al. **Clinical findings, diagnostics and outcome in 33 cats with adrenal neoplasia (2002–2013).** *J Feline Med Surg* 2016; 18: 77–84.
- Labelle P and De Cock HE. **Metastatic tumors to the adrenal glands in domestic animals.** *Vet Pathol* 2005; 42: 52–58.
- Feldman EC and Nelson RW. **Hypoadrenocorticism (Addison's disease).** In: Canine and feline endocrinology and reproduction. 3rd ed. St Louis, MO: Elsevier Saunders, 2004; 394–439.
- Zimmer C, Hörauf A and Reusch C. **Ultrasonographic examination of the adrenal gland and evaluation of the hypophyseal-adrenal axis in 20 cats.** *J Small Anim Pract* 2000; 41: 156–160.
- Lomte NK, Bandgar TR, Khare S, et al. **Bilateral adrenal masses: a single center experience.** *Endocr Connect* 2016; 5: 92–100.
- Sicken J and Neiger R. **Addisonian crisis and severe acidosis in a cat: a case of feline hypoadrenocorticism.** *J Feline Med Surg* 2013; 15: 941–944.
- Gieger TL, Felman EC, Wallack ST, et al. **Lymphoma as a model for chronic illness: effects on adrenocortical function testing.** *J Vet Intern Med* 2003; 17: 154–157.
- Gamelin E, Beldent V, Rousselet MC, et al. **Non-Hodgkin's lymphoma presenting with primary adrenal insufficiency. A disease with an underestimated frequency?** *Cancer* 1992; 69: 2333–2336.
- Gunn J, Cuthbert R and Trueman A. **Lymphoma presenting with Addison's disease.** *Postgrad Med J* 1992; 68: 229.

- 20 Efremidis SC, Harsoulis F, Douma S, et al. **Adrenal insufficiency with enlarged adrenals.** *Abdom Imaging* 1996; 21: 168–171.
- 21 Harris GJ, Tio FO and Von Hoff DD. **Primary adrenal lymphoma.** *Cancer* 1989; 63: 799–803.
- 22 Mantzios G, Tsigotis P, Veliou F, et al. **Primary adrenal lymphoma presenting as Addison's disease: case report and review of the literature.** *Ann Hematol* 2004; 8: 460–463.
- 23 Kasaliwal R, Goroshi M, Khadilkar K, et al. **Primary adrenal lymphoma: a single-center experience.** *Endocr Pract* 2015; 21: 719–724.
- 24 Holm J, Breum L, Stenfeldt K, et al. **Bilateral primary adrenal lymphoma presenting with adrenal insufficiency.** *Case Rep Endocrinol* 2012; 2012: 638298.
- 25 Wang J, Ma J, Hu C, et al. **Primary adrenal nodular lymphocyte-predominant Hodgkin lymphoma: a case report and review of the literature.** *Oncol Lett* 2014; 8: 1147–1150.
- 26 Mozos A, Ye H, Chuang WY, et al. **Most primary adrenal lymphomas are diffuse large B-cell lymphomas with non-germinal center B-cell phenotype, BCL6 gene rearrangement and poor prognosis.** *Mod Pathol* 2009; 22: 1210–1217.
- 27 Grigg AP and Connors JM. **Primary adrenal lymphoma.** *Clin Lymphoma* 2003; 4: 154–160.
- 28 Schreiber CS, Sakon JR, Simião FP, et al. **Primary adrenal lymphoma: a case series study.** *Ann Hematol* 2008; 87: 859–861.
- 29 Kim YR, Kim JS, Min YH, et al. **Prognostic factors in primary diffuse large B-cell lymphoma of adrenal gland treated with Rituximab-CHOP chemotherapy from the Consortium for Improving Survival of Lymphoma (CISL).** *J Hematol Oncol* 2012; 49–58.
- 30 Lim KH, Chiou TY, Lin CJ, et al. **Rituximab in the treatment of primary bilateral adrenal lymphoma with adrenal crisis.** *Med Oncol* 2008; 25: 107–109.
- 31 Yang Y, Ye T, Wang Z, et al. **Complete remission of primary bilateral adrenal lymphoma achieved by Rituximab-CHOP chemotherapy.** *Cent Eur J Med* 2011; 6: 778–782.
- 32 Rue SM, Eckelman BP, Efe JA, et al. **Identification of a candidate therapeutic antibody for treatment of canine B-cell lymphoma.** *Vet Immunol Immunopathol* 2005; 164: 148–159.
- 33 Regan D, Guth A, Coy J, et al. **Cancer immunotherapy in veterinary medicine: current options and new developments.** *Vet J* 2016; 207: 20–28.