



NOTE

Wildlife Science

Plasma endotoxin activity in Eastern grey kangaroos (*Macropus giganteus*) with lumpy jaw disease

Yukari SOTOHIRA^{1,2)}, Kazuyuki SUZUKI^{1)*}, Marina OTSUKA¹⁾,
Masakazu TSUCHIYA³⁾, Toshio SHIMAMORI¹⁾, Yasunobu NISHI¹⁾,
Kenji TSUKANO¹⁾ and Mitsuhiro ASAKAWA¹⁾

¹⁾School of Veterinary Medicine, Rakuno Gakuen University, 582 Bunkyo-dai-Midorimachi, Ebetsu, Hokkaido 069-8501, Japan

²⁾Tozu no mori Zoological Park, 4-1-8 Kamiitozu, Kokurakita, Kitakyushu, Fukuoka 803-0845, Japan

³⁾Endotoxin and Microbial Detection, Charles River, 1023 Wappoo Road, Suite 43B, Charleston, SC 29407, U.S.A.

ABSTRACT. Progressive pyogranulomatous osteomyelitis involving the mandible or maxilla of captive macropods, referred to as “Lumpy jaw disease (LJD)”, is one of the most significant causes of illness and death in captive macropods. The aim of the present study was to evaluate the relationship between the severity of LJD and plasma endotoxin activity in kangaroos. Plasma samples obtained from moderate (n=24) and severe LJD (n=12), and healthy kangaroos (n=46), were diluted 1:20 in endotoxin-free water and heated to 80°C for 10 min. Plasma endotoxin activity was measured using the Limulus amoebocyte lysate (LAL)-kinetic turbidimetric (KT) assay. Plasma endotoxin activity was higher in kangaroos with severe LJD (0.199 ± 0.157 EU/ml) than in those with moderate LJD (0.051 ± 0.012 EU/ml, $P < 0.001$) and healthy controls (0.057 ± 0.028 EU/ml, $P < 0.001$). Our results suggest that the severity of LJD in captive macropods may be related to the plasma endotoxin activity.

KEY WORDS: captive, endotoxin, lumpy jaw, macropod, severity

J. Vet. Med. Sci.

79(6): 1138–1141, 2017

doi: 10.1292/jvms.16-0631

Received: 26 December 2016

Accepted: 25 April 2017

Published online in J-STAGE:

8 May 2017

Progressive pyogranulomatous osteomyelitis involving the mandible or maxilla of captive macropods [5, 10, 13, 15, 18], referred to as “Lumpy jaw disease (LJD)”, is one of the most significant causes of illness and death in captive macropods [15]. LJD commences as periodontitis, with invasion of the mucosa by saprophytic bacteria, such as *Fusobacterium necrophorum*, *Corynebacterium pyogenes* and *Dichelobacter nodosus*, which extends into adjacent bones, resulting in osteomyelitis [15]. Antiabong *et al.* [2] showed that LJD resulted in a decline in bacterial diversity in the oral flora, while gingivitis was associated with an increase in bacterial diversity. Samuel [18] demonstrated that the lesions and oral cavities of 50 affected animals yielded a wide range of aerobic and anaerobic organisms. The most frequent isolate from lesions (81%) was *Fusobacterium necrophorum* [18]. Therefore, the primary cause of LJD in the kangaroo is believed to be *F. necrophorum* [4, 6]. *F. necrophorum*, a Gram-negative, non-spore-forming anaerobe, is a normal inhabitant of the alimentary tracts of animals. The pathogenic mechanisms underlying disease caused by *F. necrophorum* are complex and have not yet been elucidated in detail. Several toxins and secreted products, including leucotoxin, endotoxin, hemolysin, hemagglutinin, proteases and an adhesin, have been implicated as virulence factors [17]. A PCR survey and sequence analyses of potential periodontal pathogens in captive wallaby populations have revealed a correlation between LJD and the detection of *F. necrophorum* subspecies *necrophorum* and its leucotoxin gene [3].

The systemic complications and deleterious outcomes associated with Gram-negative infections have been attributed to the exaggerated inflammatory responses largely elicited by a highly pro-inflammatory component of the Gram-negative bacterial envelope known as endotoxin or bacterial lipopolysaccharide [9]. Endotoxin is the primary virulence factor of many Gram-negative bacteria and is released from bacteria at the time of cell death, initiating an inflammatory response [7]. Endotoxin released from an infected root canal has been shown to trigger the release of interleukin-1 alpha and TNF-alpha from macrophages [14]. Endotoxin is known to be responsible for many of the pathophysiological signs observed during Gram-negative bacterial infections in mammals, including fever, leucopenia, complement activation, the activation of macrophages and changes in the plasma levels of metabolites, minerals, acute phase reactants and hormones. To the best of our knowledge, comparative studies of the relationship

*Correspondence to: Suzuki, K., School of Veterinary Medicine, Rakuno Gakuen University, 582 Bunkyo-dai-Midorimachi, Ebetsu, Hokkaido 069-8501, Japan. e-mail: kazuyuki@rakuno.ac.jp

©2017 The Japanese Society of Veterinary Science



This is an open-access article distributed under the terms of the Creative Commons Attribution Non-Commercial No Derivatives (by-nc-nd) License. (CC-BY-NC-ND 4.0: <https://creativecommons.org/licenses/by-nc-nd/4.0/>)

Table 1. Number, sex, age and body weight of kangaroos enrolled in this study

Groups		Sex	N	Age (years old)	Body weight (kg)
Controls		female	27	6.3 ± 3.4	19.9 ± 5.7
		male	19	5.0 ± 2.9	28.0 ± 13.2
Lumpy jaw disease	moderate	female	16	6.8 ± 3.0	19.8 ± 5.5
		male	8	5.6 ± 3.2	25.3 ± 11.9
	severe	female	5	4.8 ± 2.9	15.8 ± 6.2
		male	7	4.6 ± 3.7	23.3 ± 13.9

between plasma endotoxin activity and the severity of LJD have not yet been performed in macropods. Therefore, the aim of our study was to evaluate if plasma endotoxin activity was increased in captive kangaroos with LJD and correlated with the severity of the disease.

All procedures were reviewed and approved by the Institutional Animal Care and Use Committee of the School of Veterinary Medicine, Rakuno Gakuen University (Japan). Twenty-one female and fifteen male grey kangaroos (*Macropus giganteus*) with LJD, aged (mean ± SD) 5.8 ± 3.2 years old and with a body weight of 21.2 ± 9.8 kg, were examined in this study. The definitive diagnosis of LJD was made based on clinical findings, such as facial swelling, weight loss, excessive salivation and flicking of the tongue [15]. Kangaroos with systemic signs of disease, such as dehydration, anorexia, and depression, requiring medical treatment by a veterinarian were defined as having “severe LJD”. The main treatment was antibiotic therapy using penicillin and/or subcutaneous fluid therapy. The group with disease included 5 female and 7 male kangaroos. Twenty-seven female and nineteen male Eastern grey kangaroos, aged 5.8 ± 3.2 years old and with a body weight of 23.8 ± 10.6 kg, were used as the control group. The health status of the control animals was determined on the basis of a physical examination and serum biochemical analysis by zoo veterinarians. All animals were kept at Hibiki Animal World (Fukuoka, Japan) and consumed concentrated pellets (ZC Pellets, Oriental Yeast Co., Ltd., Tokyo, Japan) for herbivores in accordance with the manufacturer’s guidelines and had *ad libitum* access to hay (timothy grass and alfalfa), vegetables (including carrots, cabbage and potatoes), apples and water. The number, sex, age and body weight of the kangaroos in each group are summarized in Table 1. In each group, the body weight of males tended to be higher than that of females, but no significant differences in body weight and age were observed between the groups or the sexes.

Four ml of whole blood was collected for the endotoxin analysis via jugular venipuncture into heparinized tubes and then centrifuged for 10 min at 3,000 g at room temperature within 1 hr of collection. Approximately 1.8 ml of plasma was harvested and stored in sampling tubes (CryoTube™ vials, Nunc, Roskilde, Denmark) at -30°C for later analyses. Immediately prior to testing, plasma samples were diluted 20-fold in endotoxin-free water (Otsuka distilled water, Otsuka Pharmaceutical Co., Ltd., Tokyo, Japan) and mixed in a vortex mixer for 10 sec. Specimens were then heated for 10 min at 80°C in order to inactivate interfering substances, such as proteases.

Endotoxin-free water was used as the blank in all tests. The USP endotoxin reference standard (RSE, USP Endotoxin Reference Standard Lot G, United States Pharmacopeial Convention Inc., Rockville, MD, U.S.A.), which contained 10,000 endotoxin units (EU) per vial, was used as the positive control. The LAL reagent for the LAL KT assay (Endosafe® KTA², Charles River, Charleston, SC, U.S.A.) was reconstituted with Endotoxin-Specific Buffer Solution (Charles River) in order to eliminate any interference from β-glucans. The traditional LAL-based assay was performed in a 96-well microplate (Endosafe® 96-well, flat bottom microplate M9001, Charles River), and endotoxin activity was determined using a microplate reader (Sunrise™, Tecan Group Ltd., Männedorf, Switzerland) and EndoScan-V™ endotoxin-measuring software (Charles River). The range covered by the standard curve (0.003 to 3.0 EU/ml, was established according to the package insert of the LAL kit. The lower limit of quantitation for this assay was 0.027 EU/ml.

A test result was considered valid if the spike recovery values and coefficient of variation (CV) fell within the acceptance criteria established for the KT assay. Spike recovery values are considered valid, if they are between 50 and 200% according to the Bacterial Endotoxin Test in the US Pharmacopeia [20]. USP chapter 85 [20], which addresses photometric bacterial endotoxin test methods, allows for a wide recovery range for the positive control, between 50 and 200%, because small discrepancies in test conditions and cartridge flaws contribute to variable recovery values for the positive control [8, 11, 12, 16]. The absolute value of the correlation coefficient of the standard curve generated using reference standard endotoxin was greater than or equal to 0.980 for the range of endotoxin concentrations established according to the Bacterial Endotoxin Test in the US Pharmacopeia [20]. When any criterion, mainly the recovery of the positive control, was not within the acceptable range, the test was not considered to be valid [11]. In this study, the LAL-KT assay effectively recovered endotoxin from plasma, the linearity of the standard curve and its CV were satisfactory for the KT assay over the range of concentrations tested [19].

Sample endotoxin activities were analyzed using SPSS (ver 21. IBM Japan, Tokyo, Japan). The medians for plasma endotoxin activity in kangaroos were compared among the groups using the Kruskal-Wallis test after the *F*-test. Figure 1 shows the relationships between plasma endotoxin activity and LJD. Plasma endotoxin activity (median [min-max] EU/ml) was higher in kangaroos with severe LJD (0.130 [0.066–0.612] EU/ml) than in those with moderate LJD (0.049 [0.027–0.099] EU/ml, *P*<0.001) and in healthy controls (0.049 [0.027–0.104] EU/ml, *P*<0.001). In moderate cases without systemic signs, plasma endotoxin activity was not significantly different from that seen in healthy kangaroos.

ROC curves were used to characterize the sensitivity and specificity of measurement of the plasma endotoxin activity as an

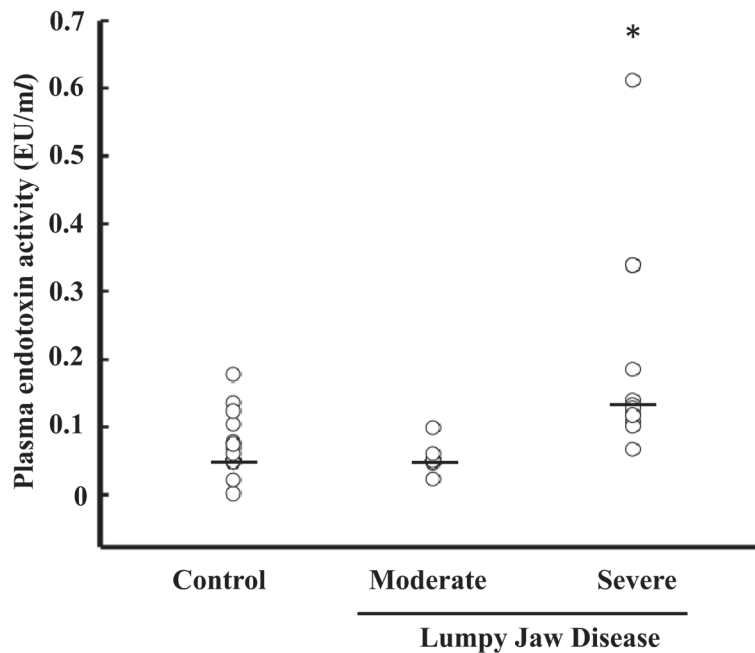


Fig. 1. Medians of plasma endotoxin activity in kangaroos with moderate and severe lumpy jaw disease (LJD). The asterisk indicates $P < 0.001$ vs control and moderate LJD, respectively.

indicator of severe LJD. The optimal cut-off point was calculated by determining the Youden index [1]. The Youden index (J) is defined as the maximum vertical distance between the ROC curve and diagonal or chance line and is calculated as $J = \text{maximum} [\text{sensitivity} + \text{specificity} - 1]$. The cut-off point on the ROC curve that corresponds to J is regarded as the optimal cut-off point [1]. The significance level was set at 0.05. The area under the ROC curve for plasma endotoxin activity was 0.969 ($P < 0.001$). The proposed diagnostic cut-off point for use of plasma endotoxin activity to identify kangaroos with severe LJD based on analyses of the ROC curves was 0.064 EU/ml. The sensitivity and specificity at the proposed diagnostic cut-offs for plasma endotoxin activity were 100 and 88.6%, respectively.

In conclusion, we herein investigated the diagnostic value of plasma endotoxin activity in kangaroos with systemic signs of disease caused by oral necrobacillosis and identified plasma endotoxin activity as a sensitive marker of severe LJD. The activity of endotoxin in the plasma was higher in kangaroos with severe LJD than in those in moderate LJD and in healthy controls. Our results indicate that the severity of LJD in captive macropods was related to the plasma endotoxin activity. The assessment of plasma endotoxin activity may be a useful diagnostic tool to the predict outcome of LJD in captive macropods.

ACKNOWLEDGMENTS. This study was supported by a Grant-in-Aid for Science Research from the Ministry of Education, Culture, Sports, Science and Technology of Japan (no. 21580393, 26450431 and 26460513).

REFERENCES

1. Akobeng, A. K. 2007. Understanding diagnostic tests 3: Receiver operating characteristic curves. *Acta Paediatr.* **96**: 644–647. [[Medline](#)] [[CrossRef](#)]
2. Antiabong, J. F., Boardman, W., Moore, R. B., Brown, M. H. and Ball, A. S. 2013. The oral microbial community of gingivitis and lumpy jaw in captive macropods. *Res. Vet. Sci.* **95**: 996–1005. [[Medline](#)] [[CrossRef](#)]
3. Antiabong, J. F., Boardman, W., Smith, I., Brown, M. H., Ball, A. S. and Goodman, A. E. 2013. A molecular survey of a captive wallaby population for periodontopathogens and the co-incidence of *Fusobacterium necrophorum* subspecies *necrophorum* with periodontal diseases. *Vet. Microbiol.* **163**: 335–343. [[Medline](#)] [[CrossRef](#)]
4. Barber, D., Campbell, J., Davey, J., Luke, T., Agren, E. and Beveridge, I. 2008. Unilateral failure of development of mandibular premolars and molars in an Eastern Grey kangaroo (*Macropus giganteus*) and its effects on molar progression. *Aust. Vet. J.* **86**: 64–66. [[Medline](#)] [[CrossRef](#)]
5. Borland, D., Coulson, G. and Beveridge, I. 2012. Oral necrobacillosis (“Lumpy Jaw”) in a free-ranging population of eastern grey kangaroos (*Macropus giganteus*) in Victoria. *Aust. Mammal.* **34**: 29–35. [[CrossRef](#)]
6. Brookins, M. D., Rajeev, S., Thornhill, T. D., Kreinheder, K. and Miller, D. L. 2008. Mandibular and maxillary osteomyelitis and myositis in a captive herd of red kangaroos (*Macropus rufus*). *J. Vet. Diagn. Invest.* **20**: 846–849. [[Medline](#)] [[CrossRef](#)]
7. Burvenich, C., Bannerman, D. D., Lippolis, J. D., Peelman, L., Nonnecke, B. J., Kehrl, M. E. Jr. and Paape, M. J. 2007. Cumulative physiological events influence the inflammatory response of the bovine udder to *Escherichia coli* infections during the transition period. *J. Dairy Sci.* **90** Suppl 1: E39–E54. [[Medline](#)] [[CrossRef](#)]

8. Cooper, J. F., Latta, K. S. and Smith, D. 2010. Automated endotoxin testing program for high-risk-level compounded sterile preparations at an institutional compounding pharmacy. *Am. J. Health Syst. Pharm.* **67**: 280–286. [[Medline](#)] [[CrossRef](#)]
9. Erskine, R. J., Tyler, J. W., Riddell, M. G. Jr. and Wilson, R. C. 1991. Theory, use, and realities of efficacy and food safety of antimicrobial treatment of acute coliform mastitis. *J. Am. Vet. Med. Assoc.* **198**: 980–984. [[Medline](#)]
10. Finnie, E. P. 1976. Husbandry and diseases of orphaned pouch-young marsupials. *Aust. Vet. Pract.* **6**: 19–28.
11. Fukumori, N. T., de Campos, D. G., Massicano, A. V., de Pereira, N. P., da Silva, C. P. and Matsuda, M. M. 2011. A portable test system for determination of bacterial endotoxins in ¹⁸F-FDG, ^{99m}Tc, and lyophilized reagents for labeling with ^{99m}Tc. *J. Nucl. Med. Technol.* **39**: 121–124. [[Medline](#)] [[CrossRef](#)]
12. Gee, A. P., Sumstad, D., Stanson, J., Watson, P., Proctor, J., Kadidlo, D., Koch, E., Sprague, J., Wood, D., Styers, D., McKenna, D., Gallelli, J., Griffin, D., Read, E. J., Parish, B. and Lindblad, R. 2008. A multicenter comparison study between the Endosafe PTS rapid-release testing system and traditional methods for detecting endotoxin in cell-therapy products. *Cytotherapy* **10**: 427–435. [[Medline](#)] [[CrossRef](#)]
13. Hartley, M. P. and Sanderson, S. 2003. Use of antibiotic impregnated polymethylmethacrylate beads for the treatment of chronic mandibular osteomyelitis in a Bennett's wallaby (*Macropus rufogriseus rufogriseus*). *Aust. Vet. J.* **81**: 742–744. [[Medline](#)] [[CrossRef](#)]
14. Hong, C. Y., Lin, S. K., Kok, S. H., Cheng, S. J., Lee, M. S., Wang, T. M., Chen, C. S., Lin, L. D. and Wang, J. S. 2004. The role of lipopolysaccharide in infectious bone resorption of periapical lesion. *J. Oral Pathol. Med.* **33**: 162–169. [[Medline](#)] [[CrossRef](#)]
15. Jakson, S. 2003. Chapter 9. Macropods. pp. 245–295. *In: Australian Mammals: Biology and Captive Management*. CSIRO Publishing, Melbourne.
16. Jimenez, L., Rana, N., Travers, K., Tolomanoska, V. and Walker, K. 2010. Evaluation of the Endosafe® portable testing system™ for the rapid analysis of biopharmaceutical samples. *PDA J. Pharm. Sci. Technol.* **64**: 211–221. [[Medline](#)]
17. Nagaraja, T. G., Narayanan, S. K., Stewart, G. C. and Chengappa, M. M. 2005. *Fusobacterium necrophorum* infections in animals: pathogenesis and pathogenic mechanisms. *Anaerobe* **11**: 239–246. [[Medline](#)] [[CrossRef](#)]
18. Samuel, J. L. 1983. Jaw disease in macropod marsupials: bacterial flora isolated from lesions and from the mouths of affected animals. *Vet. Microbiol.* **8**: 373–387. [[Medline](#)] [[CrossRef](#)]
19. Sotohira, Y., Suzuki, K., Sasaki, H., Sano, T., Tsuchiya, M., Suzuki, Y., Shimamori, T., Tsukano, K., Sato, A., Yokota, H. and Asakawa, M. 2016. Plasma endotoxin activity in kangaroos with oral necrobacillosis (lumpy jaw disease) using an automated handheld testing system. *J. Vet. Med. Sci.* **78**: 971–976. [[Medline](#)] [[CrossRef](#)]
20. The United States Pharmacopeial 2014. Chapter 85 Bacterial endotoxin test. pp. 92–96. *In: The United States Pharmacopeia, 37th ed.*, The National Formulary, Convention, Rockville.