

## Four Case Reports of Endometriosis-Related Hemoperitoneum in Pregnancy

Fu-Mei Gao, Guo-Li Liu

Department of Obstetrics and Gynecology, Peking University People's Hospital, Peking University, Beijing 100044, China

To the Editor: Endometriosis is a common gynecologic condition that affects approximately 10% of females of reproductive age.<sup>[1]</sup> It is a chronic inflammatory disease that is defined by the presence of endometrial-like tissue outside the uterine cavity. Endometriosis commonly occurs in the peritoneum, ovaries, and rectovaginal septum, but may also be found in other abdominal or extra-abdominal sites. Clinically, the symptoms of endometriosis include dysmenorrhea, pelvic pain, deep dyspareunia, and particularly infertility. It is well recognized that pregnancy can relieve endometriosis-related symptoms and may lead to the curation of endometriosis. Pregnancy is therefore considered as one of the therapeutic options for this disease. Whereas the relationship between endometriosis and infertility has been extensively studied, the influence of endometriosis on pregnancy complications remains elusive, which needs to be explored.

Spontaneous hemoperitoneum in pregnancy (SHiP) is a rare but serious pregnancy complication, which is associated with high rates of maternal and fetal morbidity and mortality. Importantly, the etiology of SHiP is still unclear. Notably, it is proposed that endometriosis may be a potential risk factor for SHiP.<sup>[2]</sup> Herein, we presented four cases of endometriosis-related SHiP.

A 38-year-old multipara at 25<sup>+5</sup> weeks of pregnancy was admitted to the emergency department. She had acute diffuse abdominal and pelvic pains, which occurred 24 h before presenting to hospital. Her previous history included: (1) spontaneous delivery at 38 weeks of gestation 12 years ago; (2) laparoscopic salpingostomy due to hydrosalpinx; and (3) endometriosis diagnosed by laparoscope. Her current pregnancy was conceived after *in vitro* fertilization and embryo transfer (IVF-ET) following gonadotrophin-releasing hormone antagonist treatment for endometriosis. On admission, premature uterine contractions were observed, and magnesium sulfate was applied to restrain uterine contraction. However, her abdominal pain became aggravated after 24 h

in admission. Her pulse rate was 110 beats/min, and blood pressure was 90/60 mmHg. The hemoglobin level decreased from 97 g/L to 73 g/L. Free peritoneal fluid was observed using ultrasound and computerized tomographic (CT) scan. Abdominal paracentesis showed the presence of uncoagulated blood. Emergency explorative laparotomy was performed, revealing 2000 ml free blood and clots in the abdomen. Active bleeding was detected from the varicose veins posterior of the lower uterine segment. A stillborn baby was delivered by cesarean section and hemostasis was accomplished. During surgery, blood loss was estimated to be 2400 ml, and 6 units of whole blood was transfused. The patient was discharged after an uneventful recovery period of 7 days.

A 29-year-old primipara was admitted for oligohydramnios at 40<sup>+2</sup> weeks of gestation. The ultrasonography revealed a 5 cm cystic mass in the left adnexa with an internal echo suggesting of an endometrioma. After admission, uterine contractions were regular and spontaneous rupture of membranes occurred. When the cervix was dilated to 5 cm, fetal heart deceleration persisted at 69–88 bpm for 5 min. Emergency cesarean section was performed, revealing 1500 ml free blood in the abdomen. A healthy 3390 g boy was delivered with Apgar scores of 6 at 1 min and 9 at 5 min. During surgery, the left adnexa was tightly adhered to the posterior surface of the uterus, and a cystic structure measuring 3 cm × 4 cm × 5 cm was observed on the left ovary. There was active bleeding from the fragile veins at the left posterior surface of the uterus and hemostasis was achieved. During surgery, 4 units of whole blood and 4 units of fresh-frozen plasma were transfused. Histopathology of

**Address for correspondence:** Dr. Guo-Li Liu,  
Department of Obstetrics and Gynecology, Peking University People's  
Hospital, Peking University, Beijing 100044, China  
E-Mail: liuguoli@pkuph.edu.cn

This is an open access article distributed under the terms of the Creative Commons Attribution-NonCommercial-ShareAlike 3.0 License, which allows others to remix, tweak, and build upon the work non-commercially, as long as the author is credited and the new creations are licensed under the identical terms.

© 2018 Chinese Medical Journal | Produced by Wolters Kluwer - Medknow

**Received:** 21-09-2017 **Edited by:** Yi Cui  
**How to cite this article:** Gao FM, Liu GL. Four Case Reports of Endometriosis-Related Hemoperitoneum in Pregnancy. Chin Med J 2018;131:502-4.

### Access this article online

#### Quick Response Code:



**Website:**  
www.cmj.org

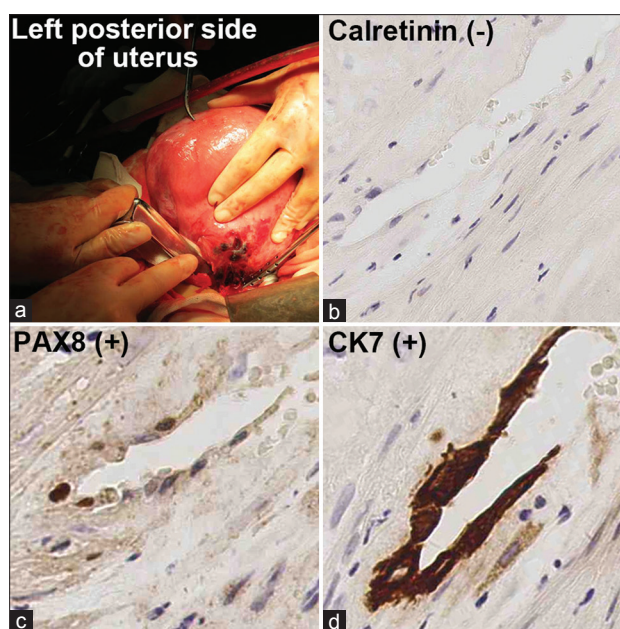
**DOI:**  
10.4103/0366-6999.225048

the cystic mass in the left adnexa showed the presence of ovarian endometrial cyst. The postoperative course was uneventful.

A 31-year-old primipara was admitted for spontaneous labor at 40<sup>+6</sup> weeks of gestation. She had an uncomplicated pregnancy and no history of endometriosis. On admission, her blood pressure and pulse rate were normal. The progress of labor was smooth. But when the uterus was stretched to near its full extent, she was immediately taken to the labor room for a rapid forceps delivery due to the Category III decelerations. About 3 h after the delivery, the patient complained of abdominal distension. About 5 h after the delivery, the hemoglobin value dropped from an initial value of 103 g/L on admission to 75 g/L. Transabdominal sonography and abdominal CT demonstrated free peritoneal fluid. Abdominal paracentesis was performed, and 5 ml of uncoagulated blood was removed. An emergency laparotomy was performed and one active bleeding site was found on the visceral surface of the left posterior side of the lower uterine segment. The local area had a blue to purple discoloration measuring 4 cm × 2 cm [Figure 1a]. Hemostasis was accomplished. Intraoperative blood loss was estimated to be 2000 ml, and 10 units of whole blood and 6 units of fresh-frozen plasma were transfused. Histopathology of the bleeding site was consistent with endometriosis, characterized by decidualization of the lesion and glandular structures. Immunostaining results showed calretinin (–), CK7 (+), and paired-box gene 8 (PAX-8) (+) [Figure 1b–1d]. The patient was discharged 6 days after delivery.

A 39-year-old multipara with a twin pregnancy at 33<sup>+5</sup> weeks of pregnancy was admitted to emergency room with acute diffuse abdominal and pelvic pain, which started 3 h before presenting to hospital. Her previous history included: (1) vaginal delivery at 38 weeks of gestation 5 years ago; (2) endometriosis diagnosed by laparoscope; (3) salpingostomy; and (4) laparoscopic bilateral salpingectomy. The current pregnancy was conceived after IVF-ET due to the tubal problem. Physical examination led to a suspected diagnosis of pelvic peritonitis. Dexamethasone was administered for promoting fetal pulmonary maturation, and magnesium sulfate was administered to restrain uterine contraction. An emergency explorative laparotomy was performed because of her unrelieved abdominal pain. There was active bleeding occurring from the fragile serous veins on the left side of the uterus, revealing 150 ml of free blood and clots in the abdomen. Two alive female fetuses (2260/2290 g) were delivered through cesarean section with Apgar scores of 10/8 at 1 min and 10/10 at 5 min. Then, the two female fetuses were transferred to the Neonatal Intensive Care Unit due to premature delivery. Hemostasis was achieved and the postoperative course of the mother was uneventful.

In the present study, we reported four cases of endometriosis-related SHiP. Among the four cases of SHiP, three patients had a history of severe endometriosis with Stage III–IV and two patients were conceived by IVF-ET.



**Figure 1:** (a) The site of bleeding in the left posterior side of the lower segment in the third case; (b–d) sections showing decidualized tissue with elongated glands with thin epithelium (H and E, original magnification × 200); (b) negative control; (c and d) immunoperoxidase stains with paired-box gene 8/CK7 show positive glandular epithelium.

The other one case was diagnosed with endometriosis after the surgery. Histopathological examination of the bleeding site in the four cases further confirmed the presence of endometriosis. Thus, the four cases of SHiP maybe related to endometriosis.

SHiP is a rare condition but is almost always a life-threatening complication associated with maternal and perinatal mortality.<sup>[2]</sup> Although improved resuscitative, anesthetic, and operative techniques have significantly decreased the maternal mortality rate, fetal mortality remained as high as 31%.<sup>[3]</sup> Typical presenting symptoms of this condition are acute or subacute abdominal pain, followed by hypovolemic shock and fetal distress. In the current study, we also found the symptoms of abdominal pain and fetal heart deceleration in all four cases. Moreover, the blood loss of three patients was above 1500 ml, resulted in a marked reduction in hemoglobin level and massive blood transfusion. This result is consistent with one previous report showing severe blood loss in SHiP patients.<sup>[4]</sup> To detect blood loss, routine hematologic analysis, ultrasound, CT scan, or magnetic resonance imaging are beneficial for revealing free peritoneal fluid. In addition, paracentesis can further establish the presence of hemoperitoneum. During our diagnosis, abdominal ultrasound and CT scan were used in three patients and two patients received paracentesis.

The common bleeding sites in SHiP include the serosa of the posterior wall of the uterus, the broad ligaments, or the uterosacral ligaments, and bleeding was recorded as venous at the site of varicosities.<sup>[4]</sup> Due to the enlarged uterus in advanced pregnancy and the occult bleeding site, it is difficult to make the diagnosis of SHiP preoperatively. The

bleeding site of our four cases was all from the posterior wall of the uterus, and they were all diagnosed with SHiP postoperatively. In this point, we should take consideration of the possibility of SHiP to the condition of fetal distress and reduced hemoglobin level without apparent reason. As a result, emergency explorative laparotomy was performed in all the four cases, which could prevent potential SHiP-induced maternal hypovolemic shock or fetal distress. During the surgery, sewing hemostasis should be performed to avoid complication and bleeding again. Importantly, hysterectomy should be performed if bleeding continues or uterus malformation occurs.

It has been proposed that endometriosis maybe a potential risk factor for SHiP. Several studies showed that >50% of cases of SHiP were associated with endometriosis.<sup>[1]</sup> In our reported cases, three women were known to have endometriosis before pregnancy and one woman was diagnosed with endometriosis after SHiP. These results are consistent with previous reports, suggesting the potential involvement of endometriosis in SHiP. Notably, it has been suggested that endometriosis-related SHiP could be caused by spontaneous rupture of utero-ovarian vessels or bleeding endometriosis implants.<sup>[1]</sup> This may be attributed to three factors: (1) utero-ovarian vessels are more friable due to chronic inflammations associated with endometriosis; (2) adhesions in combination with enlargement of the uterus during pregnancy can place these vessels under greater tension; and (3) decidualization of endometriotic lesions during pregnancy may cause utero-ovarian vessel perforation. Moreover, as venous pressure in the utero-ovarian circulation may increase during pregnancy, the increased venous pressure by physical efforts, such as muscular activity, coughing, defecation, coitus, or the pushing phase of labor, may accentuate the occurrence of SHiP.

As pregnancies in subfertile women diagnosed with endometriosis could be facilitated by assisted reproductive techniques, the incidence of SHiP may increase under such condition.<sup>[5]</sup> During the treatment of infertility, a high dosage of progesterone is used after IVF-ET, which can promote the process of decidualization. Thus, this treatment may result in extensive bleeding from the ectopic endometrium plant. In the four cases, two patients were conceived by IVF-ET. As the number of pregnant women with endometriosis treated by IVF-ET is increasing, it is important to recognize the condition of SHiP.

In the third case, although the patient had no history of endometriosis, the blue to purple discoloration (4 cm × 2 cm) in the bleeding site, and the histopathology of the bleeding site (calretinin [-], CK7 [+], and PAX-8 [+]), all indicated the presence of endometriosis. This case was different

from previous case reports, as in the previous reports, most of the patients already had a history of endometriosis before pregnancy. Therefore, the influence of potential endometriosis should be considered during pregnancy, which may lead to vascular fragility. In addition, the use of forceps during the labor should also be cautious, as this treatment may further promote the rupture of endometriosis-induced defective serious vessels. Thus, we should pay more attention to the patients with forceps delivery, especially the patients with the history of endometriosis.

In conclusion, SHiP is a rare but potentially fatal complication for both pregnant women and their unborn babies. Preformation of IVF on women with endometriosis may be a potential risk factor for SHiP. A greater awareness of SHiP and its associated risk factors, such as pelvic endometriosis, may facilitate the diagnosis of this condition and expedite the intervention to improve maternal and fetal outcomes.

### Declaration of patient consent

The authors certify that they have obtained all appropriate patient consent forms. In the form, the patients have given their consent for their images and other clinical information to be reported in the journal. The patients understand that their names and initials will not be published and due efforts will be made to conceal their identity, but anonymity cannot be guaranteed.

### Financial support and sponsorship

This study was supported by grants from the National Key Technology R&D Program (No. 2015BAI13B06) and the National Natural Science Foundation of China (No. 21507003).

### Conflicts of interest

There are no conflicts of interest.

## REFERENCES

1. Cozzolino M, Corioni S, Maggio L, Sorbi F, Guaschino S, Fambrini M, *et al.* Endometriosis-related hemoperitoneum in pregnancy: A Diagnosis to keep in mind. *Ochsner J* 2015;15:262-4.
2. Brosens IA, Lier MC, Mijatovic V, Habiba M, Benagiano G. Severe spontaneous hemoperitoneum in pregnancy may be linked to *in vitro* fertilization in patients with endometriosis: A systematic review. *Fertil Steril* 2016;106:692-703. doi: 10.1016/j.fertnstert.2016.05.025.
3. Wada S, Yoshiyuki F, Fujino T, Sato C. Uterine vein rupture at delivery as a delayed consequence of laparoscopic surgery for endometriosis: A case report. *J Minim Invasive Gynecol* 2009;16:510-2. doi: 10.1016/j.jmig.2009.05.001.
4. Lier M, Malik RF, van Waesberghe J, Maas JW, van Rumpst-van de Geest DA, Coppus SF, *et al.* Spontaneous haemoperitoneum in pregnancy and endometriosis: A case series. *BJOG* 2017;124:306-12. doi: 10.1111/1471-0528.14371.
5. Brosens I, Brosens JJ, Fusi L, Al-Sabbagh M, Kuroda K, Benagiano G, *et al.* Risks of adverse pregnancy outcome in endometriosis. *Fertil Steril* 2012;98:30-5. doi: 10.1016/j.fertnstert.2012.02.024.