

What's in a Gene? Pseudoexfoliation Syndrome and Pigment Dispersion Syndrome in the Same Patient

Olya Pokrovskaya · Colm O'Brien

Department of Ophthalmology, Mater Misericordiae University Hospital, and School of Medicine and Medical Sciences, University College Dublin, Dublin, Ireland

Key Words

Pseudoexfoliation · Pigment dispersion · Glaucoma · LOXL1

Abstract

Pseudoexfoliation syndrome (PXS) and pigment dispersion syndrome (PDS) are two of the commonest disorders to produce secondary open-angle glaucoma through trabecular meshwork blockage. Each is a defined clinical entity, and while genetics likely play a significant role in the pathogenesis of both, the specific genes involved appear to be distinct. There is surprisingly little published in the literature regarding the coexistence of PDS and PXS in the same patient. We present the intriguing case of a patient who developed PDS in one eye and PXS in the other. This unusual case acts as a platform for an interesting discussion of the genomics of PXS and PDS.

© 2016 The Author(s)
Published by S. Karger AG, Basel

Introduction

Pseudoexfoliation syndrome (PXS) and pigment dispersion syndrome (PDS) are common causes of raised intraocular pressure (IOP) and secondary glaucoma. PXS tends to affect an older population, whereas PDS is more likely to be seen in a younger, myopic patient cohort. PXS is a generalised disorder of the extracellular matrix characterised by the production and accumulation of fibrillar extracellular material in many ocular tissues, but is also associated with several systemic disorders including hearing loss, Alzheimer's disease, and vascular disease [1]. Recent genomic research has identified single nucleotide polymorphisms (SNPs) in the LOXL1 gene to be implicated in exfoliation syndrome and exfoliation glaucoma [2]. PDS is recognised as an autosomal dominant disorder, mapped to the 7q35–

q36 locus by linkage analysis, although the candidate gene is yet to be identified. Recent studies reveal that the exfoliation syndrome-associated LOXL1 gene variations are not involved in PDS, and there is also no evidence of linkage to the primary open-angle glaucoma (POAG)-associated 1q21–q31 locus, suggesting the presence of other yet uncharacterised loci in PDS [3].

Simultaneous diagnosis of PDS and PXS is rare, with only a handful of reports published in the literature. In the following case, we describe a patient who presented with PDS and subsequently developed PXS in her other eye. We present an up-to-date discussion of the current literature regarding the genomics of PDS and PXS.

Case Report

A 77-year-old Caucasian female presented to the glaucoma services at the Mater Misericordiae Hospital in 2007 for assessment of her anterior segment findings, first noted by an optometrist. She was a moderate myope, and best corrected visual acuity on the Snellen chart was 6/6 in both eyes with spectacle correction. Examination of her right eye revealed typical corneal Krukenberg spindle, pigment cells in the anterior chamber, and peripheral iris transillumination defects (fig. 1a–c). On gonioscopy, the iridocorneal angle was wide open with a heavily pigmented trabecular meshwork (TM) visible. Examination of the left anterior segment was unremarkable – with a clear cornea, no cells in the anterior chamber, and no iris transillumination defects seen. Iridocorneal angles were open on gonioscopy, with lesser pigmentation of the TM of the left than the right eye. IOP was 16 mm Hg on the right and 14 mm Hg on the left. Fundal examination revealed healthy looking tilted optic discs bilaterally, and normal macula, retina, and retinal vasculature. A diagnosis was made of right PDS, no treatment was indicated at this stage, and the patient was followed up on an annual basis.

Upon routine examination 7 years later, she had the same signs of PDS in her right eye, but had now developed evidence of PXS in her left eye. Pseudoexfoliative material was visible at the pupillary rim and on the anterior lens capsule in the left eye only (fig. 2c). There was corneal endothelial pigment dusting, and no iris transillumination defects were seen (fig. 2a, b). IOP was 14 mm Hg in both eyes, and optic disc appearance was unchanged, with tilted optic discs and a healthy neuroretinal rim bilaterally.

Discussion

While at present this patient does not present a therapeutic management dilemma, she is certainly an intriguing puzzle for the real glaucoma and genetics enthusiasts. In order to further understand the nature of this rare combination, it is helpful to first discuss the typical features of both PDS and PXS (table 1).

The two conditions differ in terms of their epidemiology. PDS is more common in younger, myopic patients in their third and fourth decades of life, and may undergo remission in the fifth and sixth decades [4]. Men and women are equally disposed to developing PDS; however, pigmentary glaucoma is two to three times more common in men. PXS does not appear to have a gender predilection, and the incidence increases with greater age [5]. Pseudoexfoliation glaucoma is more prevalent in men. There is also a geographic component – PXS is more common in Scandinavian countries. PDS is a bilateral condition in 90% of cases, whereas PXS is bilateral in 30%.

In terms of the pathophysiology, PDS is characterised by a concave posterior iris surface continuously rubbing against zonular fibres (reverse pupil block). This results in release of iris pigment granules into the anterior chamber, and characteristic slit-like transillumination defects in the iris mid-periphery. These pigment granules are then dispersed throughout the anterior chamber by aqueous convection currents, resulting in the classic corneal Krukenberg spindle and heavily pigmented TM. Deposition of pigment in the TM can cause impairment to normal aqueous humour outflow and increased IOP, leading to glaucoma.

Unlike PDS, which is confined to the eye, PXS is a systemic disease. PXS is best described as an age-related fibrilopathy of unknown aetiology, characterised by progressive accumulation of abnormal fibrillar extracellular material in many ocular and extraocular tissues, including skin and visceral organs. PXS is therefore associated with a higher incidence of ischaemic heart disease, myocardial infarction, transient ischaemic attacks, and stroke. Amyloid-like material is secreted into the anterior chamber and can be deposited on the zonules, anterior lens and the TM. The resultant weak zonules can increase the risk of lens subluxation and complicated cataract surgery. Friction occurs between the iris and the anterior lens, hence disrupting the iris pigment epithelium in the sphincter region. The consequent iris atrophy at the edge of the pupil margin results in the characteristic moth-eaten transillumination defects. Both pigment particles and dispersed exfoliation material can accumulate at the TM, blocking aqueous humour outflow. Hence, both PDS and PXS can cause secondary glaucoma with trabecular blockage, but via different mechanisms. On gonioscopic examination, PDS is characterised by a heavily pigmented wide open angle. In PXS, Sampaolesi's line is evident – a pigmented line anterior to Schwalbe's line. Trabecular pigment in PDS may clear over time, and IOP may return towards normal. Pigment clearance may occur more rapidly from the inferior than the superior angle, resulting in what has been described as a pigment reversal sign – often the only sign suggestive of previous PDS in older patients.

The lifetime risk of developing glaucoma with PDS is estimated to be 35–50% [6]. With PXS, the risk is approximately 1% per year – i.e. 5% at 5 years, 15% at 15 years. Management of both conditions should be tailored to the underlying pathology. Similar to POAG, initial medical treatment for both conditions is the usual course of action. Because of the increased pigmentation of the TM in both conditions, argon laser trabeculoplasty is generally considered to be more effective than in POAG; however, this is still usually not a long-term solution. There may be a role for pilocarpine and YAG laser peripheral iridotomy in PDS in view of the reverse pupil block. With regard to surgical management, trabeculectomy is the preferred method amongst most clinicians.

Because both PDS and PXS are reasonably common disorders, one would expect to encounter more patients with both conditions. This combination, however, is surprisingly rare and sparsely documented in the literature. The first published description of such patients was not until 1990, when Dr William Layden and colleagues [7] described a series of five patients who had PDS, and who subsequently developed PXS. One of the patients had typical signs of both exfoliation and pigmentary dispersion present in the same eye – with characteristic iris transillumination defects of both conditions present concurrently. All patients had increasingly uncontrollable IOP in one eye, had PXS in that eye, and were then found to have previously unrecognised PDS bilaterally (except for one monocular patient).

The next time that this intriguing combination emerged in the published literature was not until 1999, when a group from the New York Eye and Ear Infirmary described a larger series of 26 patients (by means of a clinic-based, cross-sectional study) who all had both a diagnosis of PDS and PXS [8]. The term overlap syndrome was introduced to describe the sequential appearance over time of two or more risk factors for glaucomatous damage. The appearance of a new risk factor in a patient whose condition had been previously stable may

lead to a change in the IOP control and altered disease course. All patients had bilateral PDS, and bilateral PXS was present in 9 of 26 patients.

With so little previously published data on this elusive combination, there are many as yet unanswered questions. We are particularly intrigued by the potential genetic associations of both conditions individually, and more interesting still, of the combination syndrome.

It is widely recognised that both PXS and PDS have a strong hereditary component. Family studies have consistently supported a role for genetic risk factors in PXS; however, the pattern of inheritance is uncertain [9]. Perhaps this is due to incomplete penetrance and the late onset of the disease. PDS is considered an autosomal dominant condition. In 1996, Ritch [10] attempted to tie together the various previous findings, drawing the conclusion that the likely gene involved was responsible for some aspect of the development of the middle third of the eye early in the third trimester. This may explain the association of PDS with lattice retinal degeneration [11] and retinal tears. The incidence of retinal detachment in individuals with PDS is estimated to be 12% [12].

The numerous genome-wide association studies which have been completed worldwide aid us in identifying risk alleles for various complex disorders, including ocular diseases such as age-related macular degeneration, glaucoma, diabetic retinopathy and myopia. Recently, several SNPs identified lysyl oxidase 1 (LOXL1) as a major genetic risk factor for PXS [2]. LOXL1 is a gene responsible for the cross-linking of collagen and elastin in the body – hence, altered LOXL1 expression in disease may result in compromised elastic structures in the eye. A strong association was demonstrated between two non-synonymous SNPs in exon 1 of LOXL1 and PXS in an Icelandic and Swedish population [2]. This finding was later replicated across multiple populations worldwide [13, 14].

A genome-wide linkage analysis completed by Andersen and colleagues [15] in 1997 included 4 pedigrees of Irish and Western-European ethnic background and concluded that a gene responsible for PDS maps to the telomere of the long arm of chromosome 7 (7q35–q36). This study further supported the autosomal dominant inheritance of the trait. The specific gene involved has yet to be identified.

Reports have also suggested an association between the myocilin (MYOC) gene and pigmentary glaucoma [16]. While the exact role of myocilin in glaucoma is unclear, it is thought to affect aqueous outflow by interacting with the extracellular matrix of the TM. An established association exists between MYOC mutations and POAG; however, the rare finding of these mutations in individuals with PDS may be a chance occurrence.

Several studies have investigated the possible associations between genetic loci attributed to various types of secondary glaucoma. However, no link has been established to date between the genetics of PDS and PXS which could explain the simultaneous existence of both syndromes in the same patient. No evidence of linkage has been found of PDS to the POAG-associated 1q21–q31 locus, suggesting that there may be other candidate loci yet uncharacterised [17]. Furthermore, several SNPs in the LOXL1 gene which are linked to PXS showed no association with PDS [3]. This strengthens the argument that these SNPs are specific to PXS and may not be involved with other secondary glaucomas.

Conclusion

While PDS and PXS share some clinical features, they do appear to be distinct clinical and likely genetic entities. It may be the case that the rare combination syndrome whereby PDS and PXS exist in the same patient is due to the coexistence of two separate mutations.

Statement of Ethics

The subject of this case report has given her informed consent for the publication of this article and associated photographs.

Disclosure Statement

The authors declare that they have no conflicts of interest.

References

- 1 Linner E, et al: The exfoliation syndrome in cognitive impairment of cerebrovascular or Alzheimer's type. *Acta Ophthalmol Scand* 2001;79:283–285.
- 2 Thorleifsson G, et al: Common sequence variants in the LOXL1 gene confer susceptibility to exfoliation glaucoma. *Science* 2007;317:1397–1400.
- 3 Rao KN, et al: Exfoliation syndrome and exfoliation glaucoma-associated LOXL1 variations are not involved in pigment dispersion syndrome and pigmentary glaucoma. *Mol Vis* 2008;14:1254–1262.
- 4 Lascaratos G, Shah A, Garway-Heath DF: The genetics of pigment dispersion syndrome and pigmentary glaucoma. *Surv Ophthalmol* 2013;58:164–175.
- 5 Sowka J: Pseudoexfoliation syndrome and pseudoexfoliative glaucoma. *Optometry* 2004;75:245–250.
- 6 Ritch R, Mudumbai R, Liebmann JM: Combined exfoliation and pigment dispersion: paradigm of an overlap syndrome. *Ophthalmology* 2000;107:1004–1008.
- 7 Layden W, et al: Combined exfoliation and pigment dispersion syndrome. *Am J Ophthalmology* 1990;109:530–534.
- 8 Mudumbai R, Liebmann J, Ritch R: Combined exfoliation and pigment dispersion: an overlap syndrome. *Trans Am Ophthalmol Soc* 1999;97:297–321.
- 9 Allingham RR, et al: Pseudoexfoliation syndrome in Icelandic families. *Br J Ophthalmol* 2001;85:702–707.
- 10 Ritch R: A unification hypothesis of pigment dispersion syndrome. *Trans Am Ophthalmol Soc* 1996;94:381–405; discussion 405–409.
- 11 Weseley P, et al: Lattice degeneration of the retina and the pigment dispersion syndrome. *Am J Ophthalmol* 1992;114:539–543.
- 12 Sampaolesi R: Retinal detachment and pigment dispersion syndrome (in German). *Klin Monbl Augenheilkd* 1995;206:29–32.
- 13 Fingert JH, et al: LOXL1 mutations are associated with exfoliation syndrome in patients from the midwestern United States. *Am J Ophthalmol* 2007;144:974–975.
- 14 Fan BJ, et al: DNA sequence variants in the LOXL1 gene are associated with pseudoexfoliation glaucoma in a U.S. clinic-based population with broad ethnic diversity. *BMC Med Genet* 2008;9:5.
- 15 Andersen JS, et al: A gene responsible for the pigment dispersion syndrome maps to chromosome 7q35-q36. *Arch Ophthalmol* 1997;115:384–388.
- 16 Alward WL, et al: Variations in the myocilin gene in patients with open-angle glaucoma. *Arch Ophthalmol* 2002;120:1189–1197.
- 17 Paglinauan C, et al: Exclusion of chromosome 1q21-q31 from linkage to three pedigrees affected by the pigment-dispersion syndrome. *Am J Hum Genet* 1995;56:1240–1243.

Table 1. Clinical features of PDS and PXS

	PDS	PXS
Age of onset	Young	Elderly
Inheritance	Autosomal dominant	Undefined
Cornea	Krukenberg spindle	Occasional endothelial pigment
Iris	Mid-peripheral iris transillumination defects	Transillumination at pupillary border
Anterior chamber	Floating pigment	Quiet
Iridocorneal angle	Wide open, posterior iris bowing	Open
Exfoliation material	None	Yes – visible on pupillary border and anterior lens
Lens	Normal	Exfoliation material, weak zonules

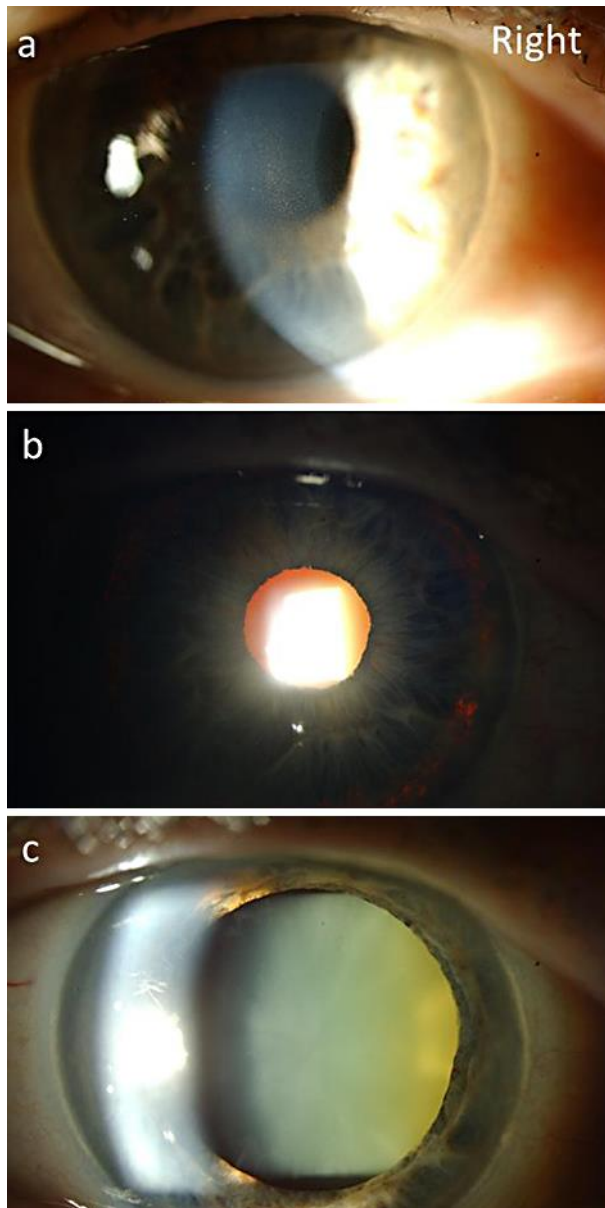


Fig. 1. Clinical findings of PDS in the right eye. **a** Krukenberg spindle. **b** Mid-peripheral iris transillumination defects. **c** No evidence of pseudoexfoliation on dilated examination.

Pokrovskaya and O'Brien: What's in a Gene? Pseudoexfoliation Syndrome and Pigment Dispersion Syndrome in the Same Patient

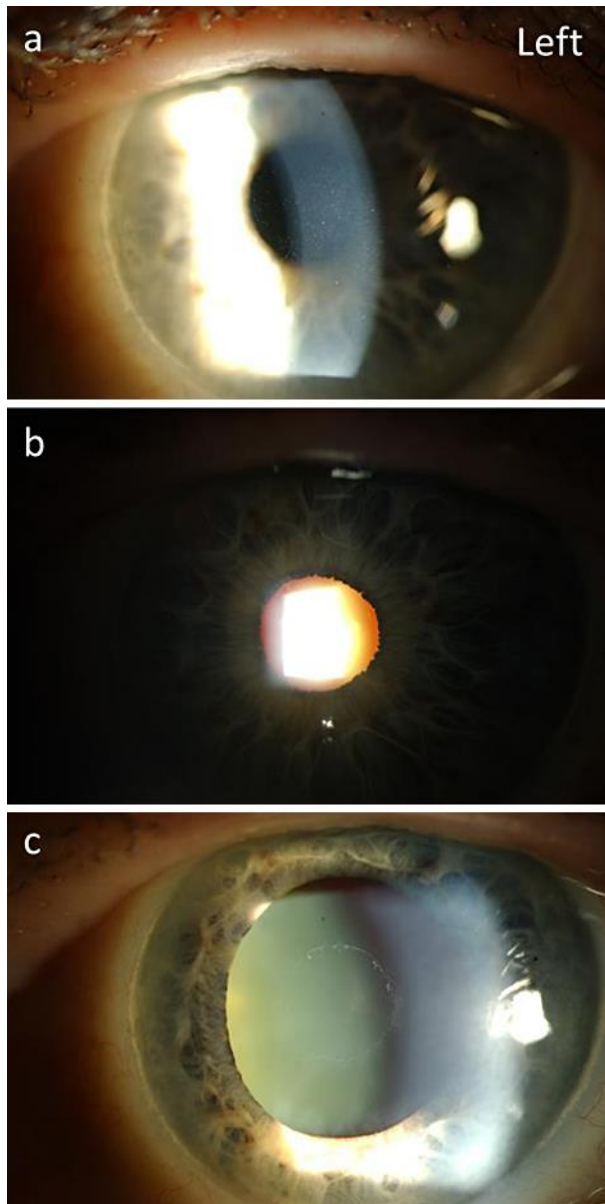


Fig. 2. Clinical findings of PXS in the left eye. **a** Mild corneal endothelial pigment dusting. **b** No significant iris transillumination defects. **c** Typical pseudoexfoliation material seen on the anterior lens.