

## Transforaminal Percutaneous Endoscopic Discectomy using Transforaminal Endoscopic Spine System technique: Pitfalls that a beginner should avoid

Stylianos Kapetanakis, Grigorios Gkardaris, Antonios G Angoules, Panagiotis Givissis

Stylianos Kapetanakis, Grigorios Gkardaris, Spine Department and Deformities, Interbalkan European Medical Center, Thessaloniki 55535, Greece

Antonios G Angoules, Department of Medical Laboratories, Technological Educational Institute of Athens, Athens 12243, Greece

Panagiotis Givissis, First Orthopaedic Department of "Aristotle University of Thessaloniki", "Papanikolaou" Hospital, Exohi, Thessaloniki 57010, Greece

ORCID number: Stylianos Kapetanakis (0000-0001-6276-2447); Grigorios Gkardaris (0000-0002-7877-2743); Antonios G Angoules (0000-0002-7118-958X); Panagiotis Givissis (0000-0002-8649-1159).

**Author contributions:** All authors equally contributed to this paper with conception and design of the study; all authors approved the final version of the article.

**Conflict-of-interest statement:** The authors of this manuscript declare that they have no conflict of interests.

**Open-Access:** This article is an open-access article which was selected by an in-house editor and fully peer-reviewed by external reviewers. It is distributed in accordance with the Creative Commons Attribution Non Commercial (CC BY-NC 4.0) license, which permits others to distribute, remix, adapt, build upon this work non-commercially, and license their derivative works on different terms, provided the original work is properly cited and the use is non-commercial. See: <http://creativecommons.org/licenses/by-nc/4.0/>

**Manuscript source:** Invited manuscript

**Correspondence to:** Antonios G Angoules, MD, PhD, Department of Medical Laboratories, Technological Educational Institute of Athens, 28 Agiou Spiridonos St, Athens 12243, Greece. [angoules@teiath.gr](mailto:angoules@teiath.gr)  
Telephone: +30-6-977011617

Received: July 17, 2017

Peer-review started: July 20, 2017

First decision: September 4, 2017

Revised: September 11, 2017

Accepted: October 17, 2017

Article in press: October 17, 2017

Published online: December 18, 2017

### Abstract

Transforaminal Percutaneous Endoscopic Discectomy (TPED) is a minimally invasive technique mainly used for the treatment of lumbar disc herniation from a lateral approach. Performed under local anesthesia, TPED has been proven to be a safe and effective technique which has been also associated with shorter rehabilitation period, reduced blood loss, trauma, and scar tissue compared to conventional procedures. However, the procedure should be performed by a spine surgeon experienced in the specific technique and capable of recognizing or avoiding various challenging conditions. In this review, pitfalls that a novice surgeon has to be mindful of, are reported and analyzed.

**Key words:** Transforaminal Percutaneous Endoscopic Discectomy; Transforaminal Endoscopic Spine System; Lumbar disk herniation; Pitfalls; Spine surgery

© **The Author(s) 2017.** Published by Baishideng Publishing Group Inc. All rights reserved.

**Core tip:** Transforaminal Percutaneous Endoscopic Discectomy (TPED) is an evolving minimally invasive technique that has been proven to be safe and effective in treating symptomatic lumbar disc herniation (LDH). However, this relatively new therapeutic approach requires special training and expertise so as to evade complications that may endanger the safety of the patient. In this review, current concepts regarding challenging indications

and contraindications of this novel technique are analyzed focusing on several conditions and pitfalls that a beginner spine surgeon should avoid when treating LDH using TPED with Transforaminal Endoscopic Spine System technique, so as to eliminate possible risks and thus improve outcomes.

Kapetanakis S, Gkasdaris G, Angoules AG, Givissis P. Transforaminal Percutaneous Endoscopic Discectomy using Transforaminal Endoscopic Spine System technique: Pitfalls that a beginner should avoid. *World J Orthop* 2017; 8(12): 874-880 Available from: URL: <http://www.wjgnet.com/2218-5836/full/v8/i12/874.htm> DOI: <http://dx.doi.org/10.5312/wjo.v8.i12.874>

## INTRODUCTION

Symptomatic lumbar disc herniation (LDH) is a common etiology for spine surgery. Although microdiscectomy is considered to be the gold standard method, the need for minimally invasive techniques and the improvements in the use of optics and surgical instruments have led to the utilization of Transforaminal Percutaneous Endoscopic Discectomy (TPED) using the Transforaminal Endoscopic Spine System (TESSYS) technique<sup>[1-3]</sup>.

TPED has several advantages such as direct visualization of the pathology, reduced soft tissue trauma, reduced blood loss, quicker recovery and preservation of the adjacent anatomy. It can be an effective and safe method in the hands of an experienced spine surgeon if specific steps are followed<sup>[1]</sup>. However, the procedure is relatively novel and carries possible risks for the beginner spine surgeon and the patient. Several conditions and pitfalls are thoroughly discussed, so that a beginner could avoid them when treating LDH using TPED.

### Indications

Generally, the indication for TPED, in compliance with clinical findings, is usually found to be persistent sciatica caused by LDH. There are several inclusion criteria such as radiculopathy, positive nerve root tension sign, sensory or motor neurological lesion on clinical examination, cauda equine syndrome, hernia confirmed by magnetic resonance imaging (MRI) of the lumbar spine. Failure of 12-wk conservative treatment is also a strong indication<sup>[2,3]</sup>.

### Challenging conditions

Various conditions have been reported as contraindications for TPED including: Recurrent herniated disc, migrated LDH, sequestration of the disc, central or lateral recess spinal stenosis, or previous surgery at the affected level, segmental instability or spondylolisthesis, spinal tumor or infection and vertebral fracture<sup>[1,4-6]</sup>. The following conditions should draw the maximum attention in the hands of an inexperienced spine surgeon.

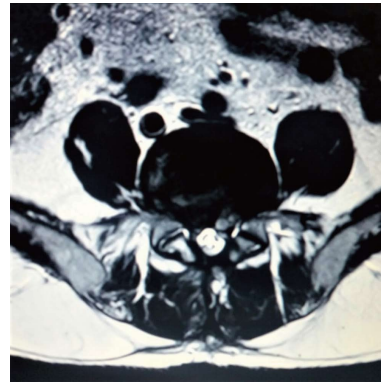


Figure 1 Case of recurrent disc herniation after open discectomy.

## SURGICAL TECHNIQUE-RELATED CONDITIONS

### Recurrent disc herniation

The gold standard treatment for recurrent LDH is considered to be open discectomy (Figure 1). However, in the hands of an experienced spine surgeon, TPED for recurrent LDH is a feasible and effective alternative to conventional repeated discectomy, while reducing tissue damage, scar tissue formation and instability<sup>[7]</sup>.

### Scar tissue formation

Conventional microdiscectomy is an open surgery with high risk of scar tissue formation contrary to endoscopic discectomy. In case of recurrent LDH and repetitive procedures scar tissue formation is almost inevitable. These cases can be difficult to manage with TPED. The altered anatomy of the region, the possible nerve tension and the difficult visualization of the anatomic structures are major obstacles for a beginner spine surgeon. Recently, percutaneous endoscopic interlaminar lumbar discectomy with dissection of the scar tissue from the medial facet joint rather than from the neural tissue has been proposed as an effective alternative surgical method on the background of recurrent disc herniation<sup>[8]</sup>. Also, less systemic cytokine response in patients following microendoscopic vs open lumbar discectomy has been found to exist, indicating the minimally invasive character of the first one<sup>[9]</sup>. Additionally, microendoscopic discectomy has been associated with lower risks for surgical site infection and major complications contrary to open discectomy<sup>[10]</sup>.

### Migrated or extruded LDH

TPED is usually appropriate for normal or caudal LDHs. Pediclectomy or translaminar approach may be required to remove an upward- or downward-migrated LDH<sup>[11,12]</sup> (Figures 2 and 3). Dorsal LDH located behind the dural sac is not treated with TPED. Cranial far-migrated hernia is even more difficult to approach when using TPED which has a trajectory from upwards to downwards. Open surgery is also proposed for far-migrated disc

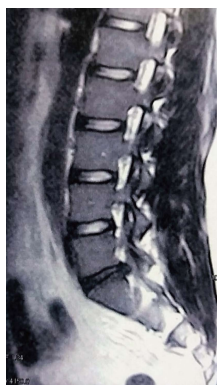

Figure 2 T2 weighted sagittal magnetic resonance imaging demonstrating a disc herniation located at the L5/S1 level.

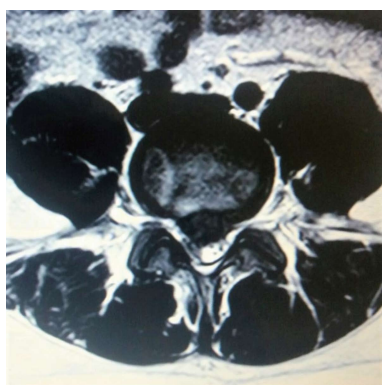


Figure 3 Case of a migrated central hernia.

herniations<sup>[12]</sup>. Even for extruded disc fragments endoscopic transforaminal discectomy has been proposed as a safe and effective alternative<sup>[13]</sup>.

## PATIENT-RELATED CONDITIONS

### ***Intracanal LDH at the L5/S1 level with a high and steep iliac crest***

High iliac crests refer usually to men contrary to women<sup>[14]</sup> (Figure 4). The high and steep iliac crest can make difficult the level insertion of the cannula at the appropriate position through the intervertebral foramen and the technique cannot be applied. In high iliac crest cases where the iliac crest is above the mid L5 pedicle, foraminoplasty may be considered for transforaminal access of L5-S1 disc herniation<sup>[15]</sup>. Lee *et al.*<sup>[16]</sup> also proposed the foraminoplastic approach in order to facilitate the insertion of the cannula. Tezuka *et al.*<sup>[17]</sup> indicated that treatment for the central type of LDH at the L5-S1 disc level is more difficult than at the L4-L5 due to the iliac crest. This can be solved by using a more perpendicular approach with the possible addition of a foraminoplasty<sup>[17]</sup>. Interlaminar approach can escape the blockade of crista iliaca, and offer several advantages including a faster puncture orientation, a shorter operation time, and less intraoperative radiation exposure<sup>[18]</sup>. Application of transiliac approach to

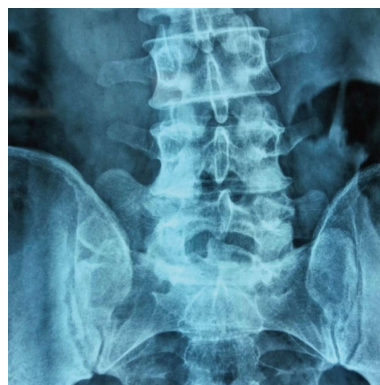


Figure 4 Case of high and steep iliac crests.

intervertebral endoscopic discectomy in L5/S1 LDH has also been suggested<sup>[19]</sup>. Additionally, it is reported that compared with the L5/S1 level, the L4/5 level might be easier to master after short-term professional training<sup>[20]</sup>. It is true that some propose the percutaneous endoscopic discectomy as the treatment of choice for foraminal and extraforaminal disc herniations at the L5-S1 level on appropriately selected patients<sup>[21]</sup>. Since this is considered the most difficult level, we can forecast that TPED might be established as a treatment for all lumbar levels.

### ***Scoliosis***

Scoliosis is a form of deformity which results in misalignment of the spine. Idiopathic scoliosis (Cobb angle  $\geq 10^\circ$ ) is more common in children aged 10-15 years old and has a prevalence estimated at 0.5%<sup>[22]</sup>. Degenerative scoliosis is observed in more than 30% of elderly patients with no history of spinal abnormalities and is typically diagnosed in patients older than 40 years<sup>[23]</sup>. The prevalence of  $10^\circ$ ,  $10^\circ$ - $20^\circ$  and  $> 20^\circ$  curves is 64%, 44% and 24%, respectively<sup>[24]</sup>. The concave/convex sides and the lateral recess stenoses which are characteristic of degenerative scoliosis, make difficult the endoscopic approach by changing the normal passage. Basically, the Kambin's triangle is altered making difficult the safe passage of the endoscopic instruments<sup>[4]</sup>. In coronal projection, the deformation of the lumbar spine affects the form of the meninge something which makes its traumatization more possible. Nevertheless, the use of TPED for LDH on the background of lumbar scoliosis has been recently attempted<sup>[25,26]</sup>.

### ***Spondylolysis-spondylolisthesis***

Spondylolysis is a unilateral or bilateral stress fracture of the pars interarticularis and is usually combined with spondylolisthesis. In spondylolistheses, alteration of the normal anatomy of the lumbar intervertebral foramen and its dimensions resulting in foraminal narrowing and disc bulging is observed<sup>[27]</sup>. The measurement of spondylolisthesis is based on the widely recognized method proposed by Meyerding<sup>[28]</sup> in 1932 (Figure 5). Meyerding defined the slippage on plain X-ray imaging in accordance to the vertebra below. The caudal



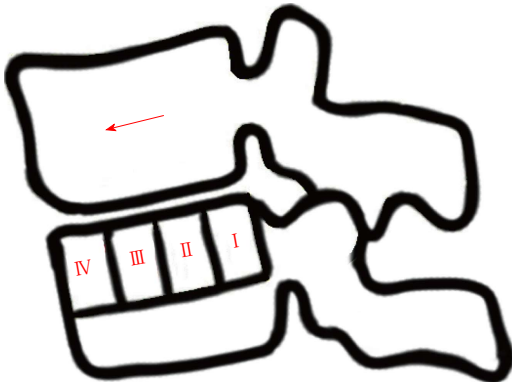


Figure 5 Meyerding's grading of spondylolisthesis regarding cranial anterior vertebral slippage in accordance with the vertebra below.

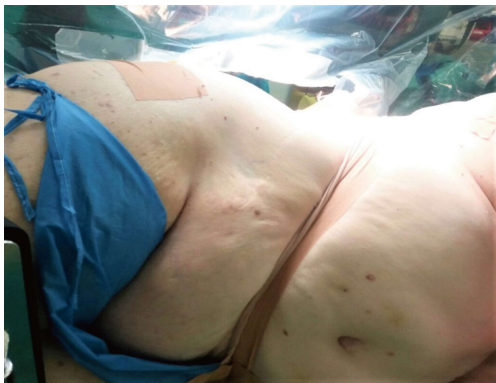

Figure 6 Case of an obese patient to be treated with Transforaminal Percutaneous Endoscopic Discectomy for lumbar disc herniation.

vertebra is divided into four parts. Grade I means a translation of the cranial vertebra of up to 25%, Grade II of up to 50%, Grade III of up to 75%, and Grade IV up to 100%<sup>[28]</sup>. Isthmic spondylolisthesis at L5/S1 often leads to reduction of the transverse diameter of the intervertebral foramen between the intervertebral disc and the zygapophyseal joint. The normal shape of the intervertebral foramen is altered, while spinal nerves and roots, sinuvertebral nerves, spinal arteries, and intervertebral veins are compressed between transforaminal and extraforaminal ligaments<sup>[29]</sup>. The radicular symptoms are usually caused by compression of the exiting L5 nerve root and its adjacent vessels in the L5-S1 foramen. In these cases the only surgical options have been lumbar laminectomy and lumbar fusion, however TPED with foraminoplasty appears as an effective upcoming treatment<sup>[30,31]</sup>. We believe that beginners should avoid TPED when dealing with spondylolistheses of 2<sup>nd</sup> grade and greater<sup>[32]</sup>. Using TPED, the conditions of spondylolysis and spondylolisthesis can not be treated.

#### Obese patients

In obese patients, a beginner spine surgeon will have to deal with technical considerations due to increased fat tissue, such as bad fluoroscopic verification and

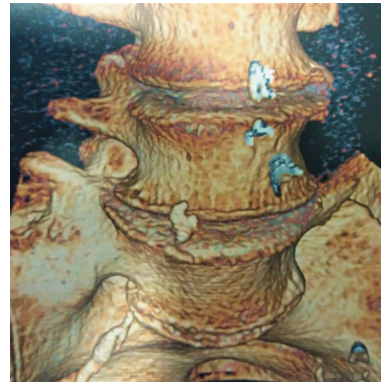


Figure 7 Case of Bertolotti's syndrome.

difficult transforaminal approach. TPED for LDH in obese patients has shown satisfactory early results, however more studies are needed to confirm its efficacy<sup>[33,34]</sup> (Figure 6).

#### Musoskeletal malformations

Several variations of the lumbar spine can be an obstacle for the realization of TPED with Bertolotti's syndrome being a common etiology of low back pain, especially for young people<sup>[35]</sup>. Lumbosacral transitional vertebrae are increasingly recognized as a common anatomical variant associated with altered patterns of degenerative spine changes. Bertolotti's syndrome refers to the association between lumbosacral transitional vertebrae and low back pain<sup>[36]</sup> (Figure 7). On the co-existence with LDH, Bertolotti's syndrome makes difficult the transforaminal passage through the Kambin's triangle during TPED<sup>[27]</sup>.

#### High LDH levels in conjunction with abnormal location/ variations of adjacent anatomic formations

Kidneys are important retroperitoneal organs adjacent to the lumbar spine. They are normally located between the transverse processes of T12-L3 vertebrae, with the left kidney typically more superior in position than the right<sup>[14]</sup> (Figure 8). Treating high level LDHs, especially T12-L1, L1-L2 and L2-L3, using TPED in accordance with abnormal location and possible variations of adjacent organs such as kidneys may result in their traumatization during the passage of the reamers and the cannula.

## SURGICAL PROCEDURE

TPED using the efficacy of TESSYS technique is performed under local anesthesia and mild sedation<sup>[1,3]</sup>. Patients are initially placed at the lateral decubitus position, lying down on the opposite side (Figure 9). Lesion is thus confronted upwards. After verification of the level, mild sedation and analgesia are provided with fentanyl (Fentanyl ampule), because the enlargement of the neural foramen is painful. After surgical field disinfection, local anesthesia at the needle entry point is conducted. This point is anatomically about 11 cm away from midline defined. Transforaminal promotion of the

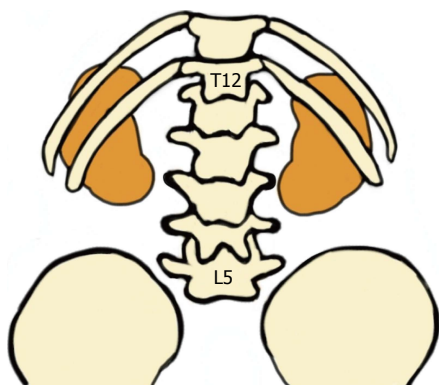


Figure 8 Posterior schematic illustration of the location of kidneys in accordance with lumbar spine levels.

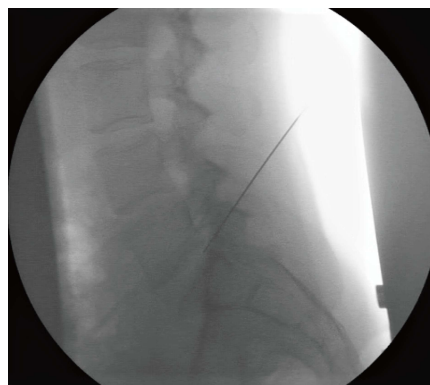


Figure 11 Fluoroscopic verification of the operated level and insertion of the needle.




Figure 9 Placement of the patient at the lateral decubitus position and disinfection of the surgical field.

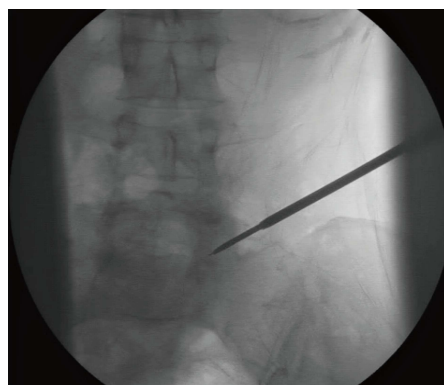


Figure 12 Sequential transforaminal passage of different size reamers.

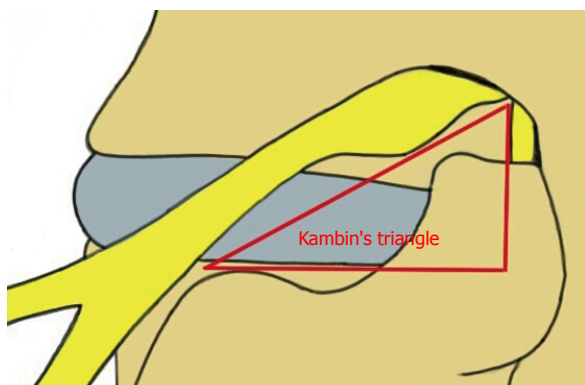


Figure 10 Kambin's triangle. The hypotenuse is parallel to the exiting nerve root, the base is according to the superior border of the transverse process of the caudal vertebra, and the height represents the trajectory of the traversing nerve root.

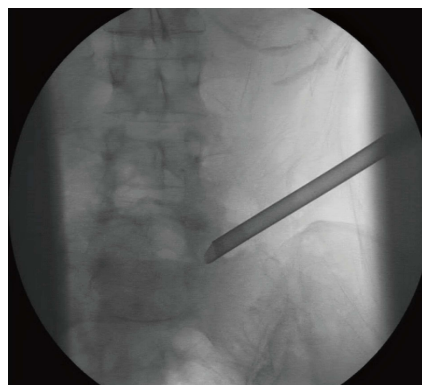


Figure 13 Insertion of the cannula and the endoscope afterwards.

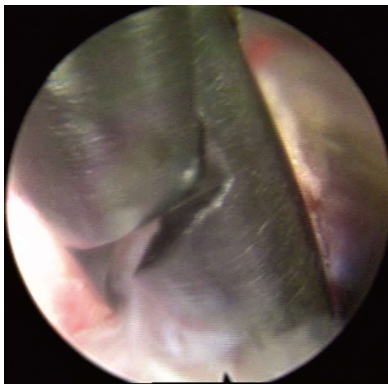
needle through the anatomic triangle of Kambin (safe zone) is subsequently performed<sup>[4]</sup> (Figures 10 and 11). Sequential transforaminal passage of three different size reamers (5.5, 6.5, 7.5 mm, joimax GmbH) constitute the next step (Figure 12). The cannula and endoscope are afterwards carefully inserted, in order to ensure nerve root preservation (Figure 13). Removal of herniated disc material is finally accomplished with

graspers (Figure 14). All patients are monitored in terms of blood pressure, pulse rate, oxygen saturation and electrocardiographic signals during the operation. Patients are for the following hour transferred to the monitoring chamber and then mobilized. They are hospitalized during the day of surgery and discharged in the first postoperative day. Possible complications could be: Nerve root damage, postoperative dysesthesia, dural tears, post-operative hematoma, wound infection and visceral injury<sup>[5,37,38]</sup>. Patients are usually scheduled to have a check-up 6 wk after the surgery

**Table 1** Summary of the indications, contraindications, advantages and disadvantages of the technique

Indications	Contraindications (for the beginners)
Radiculopathy	Surgical technique-related conditions
Positive nerve root tension sign	Recurrent disc herniation
Sensory or motor neurologic lesion on clinical examination	Scar tissue formation
Cauda equine syndrome	Migrated or extruded LDH
Hernia confirmed by MRI of the lumbar spine in compliance with clinical findings	Patient-related conditions
Failure of 12-wk conservative treatment	Intracanal LDH at the L5/S1 level with a high and steep iliac crest
	Scoliosis
	Spondylolysis-Spondylolisthesis
	Obese patients
	Muskeletal malformations
	High LDH levels in conjunction with abnormal location/
	variations of adjacent anatomic formations
Advantages	Disadvantages
Safe and effective technique	Careful selection of patients is needed
Direct visualization of the pathology	Limited space for surgical maneuvering
Less blood loss	Long learning curve
Less trauma and scar tissue	
Faster rehabilitation	
Preservation of the spine stability and the adjacent anatomy	

LDH: Lumbar disc herniation; MRI: Magnetic resonance imaging.

**Figure 14** Removal of herniated disc material with a grasper.

at the outpatient clinic. Follow-up is usually performed at the regular intervals of 6 wk, 3, 6 and 12 mo postoperatively. The indications, contraindications, advantages and disadvantages of the procedure are summarized in Table 1.

## CONCLUSION

TPED is an evolving minimally invasive technique which requires training and expertise. Every condition which alters the normal architecture of the spine and makes the access to the LDH difficult tests the abilities of the spine surgeon and sets a question mark on the feasibility and limits of TPED. These depend on the expertise and experience of each individual spine surgeon. It should be kept in mind that TPED is a combination of two interventional approaches involving the percutaneous and the endoscopic aspect; both of them indicate its demanding character. However, good training and coaching may overcome such difficulties offering a safe and efficient procedure to patients with

LDH.

## REFERENCES

- 1 **Kapetanakis S**, Charitoudis G, Thomaidis T, Theodosiadis P, Papathanasiou J, Giatroudakis K. Health-related quality of life after transforaminal percutaneous endoscopic discectomy: An analysis according to the level of operation. *J Craniovertebr Junction Spine* 2017; **8**: 44-49 [PMID: 28250636 DOI: 10.4103/0974-8237.199872]
- 2 **Kapetanakis S**, Giovannopoulou E, Charitoudis G, Kazakos K. Transforaminal Percutaneous Endoscopic Discectomy for Lumbar Disc Herniation in Parkinson's Disease: A Case-Control Study. *Asian Spine J* 2016; **10**: 671-677 [PMID: 27559446 DOI: 10.4184/asj.2016.10.4.671]
- 3 **Kapetanakis S**, Giovannopoulou E, Thomaidis T, Charitoudis G, Pavlidis P, Kazakos K. Transforaminal Percutaneous Endoscopic Discectomy in Parkinson Disease: Preliminary Results and Short Review of the Literature. *Korean J Spine* 2016; **13**: 144-150 [PMID: 27799995 DOI: 10.14245/kjs.2016.13.3.144]
- 4 **Kambin P**, Brager MD. Percutaneous posterolateral discectomy. Anatomy and mechanism. *Clin Orthop Relat Res* 1987; **223**: 145-154 [PMID: 3652568]
- 5 **Gadjradj PS**, Harhangi BS. Percutaneous Transforaminal Endoscopic Discectomy for Lumbar Disk Herniation. *Clin Spine Surg* 2016; **29**: 368-371 [PMID: 26945128 DOI: 10.1097/BSD.0000000000000366]
- 6 **Sairoyo K**, Egawa H, Matsuura T, Takahashi M, Higashino K, Sakai T, Suzue N, Hamada D, Goto T, Takata Y, Nishisho T, Goda Y, Sato R, Tsutsui T, Tonogai I, Kondo K, Tezuka F, Mineta K, Sugiura K, Takeuchi M, Dezaawa A. State of the art: Transforaminal approach for percutaneous endoscopic lumbar discectomy under local anesthesia. *J Med Invest* 2014; **61**: 217-225 [PMID: 25264038 DOI: 10.2152/jmi.61.217]
- 7 **Shin KH**, Chang HG, Rhee NK, Lim KS. Revisional percutaneous full endoscopic disc surgery for recurrent herniation of previous open lumbar discectomy. *Asian Spine J* 2011; **5**: 1-9 [PMID: 21386940 DOI: 10.4184/asj.2011.5.1.1]
- 8 **Kim CH**, Chung CK, Jahng TA, Yang HJ, Son YJ. Surgical outcome of percutaneous endoscopic interlaminar lumbar discectomy for recurrent disk herniation after open discectomy. *J Spinal Disord Tech* 2012; **25**: E125-E133 [PMID: 22744610 DOI: 10.1097/BSD.0b013e31825bd111]
- 9 **Huang TJ**, Hsu RW, Li YY, Cheng CC. Less systemic cytokine



- response in patients following microendoscopic versus open lumbar discectomy. *J Orthop Res* 2005; **23**: 406-411 [PMID: 15734255 DOI: 10.1016/j.orthres.2004.08.010]
- 10 **Ohya J**, Oshima Y, Chikuda H, Oichi T, Matsui H, Fushimi K, Tanaka S, Yasunaga H. Does the microendoscopic technique reduce mortality and major complications in patients undergoing lumbar discectomy? A propensity score-matched analysis using a nationwide administrative database. *Neurosurg Focus* 2016; **40**: E5 [PMID: 26828886 DOI: 10.3171/2015.10.FOCUS15479]
  - 11 **Dezawa A**, Mikami H, Sairyo K. Percutaneous endoscopic translaminal approach for herniated nucleus pulposus in the hidden zone of the lumbar spine. *Asian J Endosc Surg* 2012; **5**: 200-203 [PMID: 23095301 DOI: 10.1111/j.1758-5910.2012.00142.x]
  - 12 **Lee S**, Kim SK, Lee SH, Kim WJ, Choi WC, Choi G, Shin SW. Percutaneous endoscopic lumbar discectomy for migrated disc herniation: classification of disc migration and surgical approaches. *Eur Spine J* 2007; **16**: 431-437 [PMID: 16972067 DOI: 10.1007/s00586-006-0219-4]
  - 13 **Jasper GP**, Francisco GM, Telfeian AE. Endoscopic transforaminal discectomy for an extruded lumbar disc herniation. *Pain Physician* 2013; **16**: E31-E35 [PMID: 23340542]
  - 14 **Moore KL**, Dalley AF, Agur AMR. Clinically oriented anatomy. 7th ed. Baltimore: Lippincott Williams Wilkins, 2013
  - 15 **Choi KC**, Park CK. Percutaneous Endoscopic Lumbar Discectomy for L5-S1 Disc Herniation: Consideration of the Relation between the Iliac Crest and L5-S1 Disc. *Pain Physician* 2016; **19**: E301-E308 [PMID: 26815257]
  - 16 **Lee SH**, Kang HS, Choi G, Kong BJ, Ahn Y, Kim JS, Lee HY. Foraminoplasty ventral epidural approach for removal of extruded herniated fragment at the L5-S1 level. *Neurol Med Chir (Tokyo)* 2010; **50**: 1074-1078 [PMID: 21206181 DOI: 10.2176/nmc.50.1074]
  - 17 **Tezuka F**, Sakai T, Abe M, Yamashita K, Takata Y, Higashino K, Chikawa T, Nagamachi A, Sairyo K. Anatomical considerations of the iliac crest on percutaneous endoscopic discectomy using a transforaminal approach. *Spine J* 2017; Epub ahead of print [PMID: 28645675 DOI: 10.1016/j.spinee.2017.06.012]
  - 18 **Nie H**, Zeng J, Song Y, Chen G, Wang X, Li Z, Jiang H, Kong Q. Percutaneous Endoscopic Lumbar Discectomy for L5-S1 Disc Herniation Via an Interlaminar Approach Versus a Transforaminal Approach: A Prospective Randomized Controlled Study With 2-Year Follow Up. *Spine (Phila Pa 1976)* 2016; **41** Suppl 19: B30-B37 [PMID: 27454540 DOI: 10.1097/BRS.0000000000001810]
  - 19 **Bai J**, Zhang W, Wang Y, An J, Zhang J, Sun Y, Ding W, Shen Y. Application of transiliac approach to intervertebral endoscopic discectomy in L5/S1 intervertebral disc herniation. *Eur J Med Res* 2017; **22**: 14 [PMID: 28376859 DOI: 10.1186/s40001-017-0254-0]
  - 20 **Wu XB**, Fan GX, Gu X, Shen TG, Guan XF, Hu AN, Zhang HL, He SS. Learning curves of percutaneous endoscopic lumbar discectomy in transforaminal approach at the L4/5 and L5/S1 levels: a comparative study. *J Zhejiang Univ Sci B* 2016; **17**: 553-560 [PMID: 27381732 DOI: 10.1631/jzus.B1600002]
  - 21 **Lübberts T**, Abuamona R, Elsharkawy AE. Percutaneous endoscopic treatment of foraminal and extraforaminal disc herniation at the L5-S1 level. *Acta Neurochir (Wien)* 2012; **154**: 1789-1795 [PMID: 22782651 DOI: 10.1007/s00701-012-1432-z]
  - 22 **Stirling AJ**, Howel D, Millner PA, Sadiq S, Sharples D, Dickson RA. Late-onset idiopathic scoliosis in children six to fourteen years old. A cross-sectional prevalence study. *J Bone Joint Surg Am* 1996; **78**: 1330-1336 [PMID: 8816647 DOI: 10.2106/00004623-199609000-0006]
  - 23 **Robin GC**, Span Y, Steinberg R, Makin M, Mencil J. Scoliosis in the elderly: a follow-up study. *Spine (Phila Pa 1976)* 1982; **7**: 355-359 [PMID: 6215719 DOI: 10.1097/00007632-198207000-00005]
  - 24 **Grubb SA**, Lipscomb HJ, Coonrad RW. Degenerative adult onset scoliosis. *Spine (Phila Pa 1976)* 1988; **13**: 241-245 [PMID: 2968664 DOI: 10.1097/00007632-198803000-00004]
  - 25 **Kim R**, Kim RH, Kim CH, Choi Y, Hong HS, Park SB, Yang SH, Kim SM, Chung CK. The Incidence and Risk Factors for Lumbar or Sciatic Scoliosis in Lumbar Disc Herniation and the Outcomes after Percutaneous Endoscopic Discectomy. *Pain Physician* 2015; **18**: 555-564 [PMID: 26606007]
  - 26 **Wu B**, Zhang S, Lian Q, Yan H, Lin X, Zhan G. Lumbar Scoliosis Combined Lumbar Spinal Stenosis and Herniation Diagnosed Patient Was Treated with "U" Route Transforaminal Percutaneous Endoscopic Lumbar Discectomy. *Case Rep Orthop* 2017; **2017**: 7439016 [PMID: 28203471 DOI: 10.1155/2017/7439016]
  - 27 **Gkasdaris G**, Kapetanakis S. Clinical anatomy and significance of the lumbar intervertebral foramen: A review. *J Anatomical Soc India* 2015; **64**: 166-173 [DOI: 10.1016/j.jasi.2015.10.003]
  - 28 **Meyerding HW**. Spondylolisthesis. *Surg Gynecol Obstet* 1932; **54**: 371-377
  - 29 **Gkasdaris G**, Tripsianis G, Kotopoulos K, Kapetanakis S. Clinical anatomy and significance of the thoracic intervertebral foramen: A cadaveric study and review of the literature. *J Craniovertebr Junction Spine* 2016; **7**: 228-235 [PMID: 27891032 DOI: 10.4103/0974-8237.193266]
  - 30 **Jasper GP**, Francisco GM, Aghion D, Telfeian AE. Technical considerations in transforaminal endoscopic discectomy with foraminoplasty for the treatment of spondylolisthesis: Case report. *Clin Neurol Neurosurg* 2014; **119**: 84-87 [PMID: 24635932 DOI: 10.1016/j.clineuro.2014.01.019]
  - 31 **Jasper GP**, Francisco GM, Telfeian AE. Transforaminal endoscopic discectomy with foraminoplasty for the treatment of spondylolisthesis. *Pain Physician* 2014; **17**: E703-E708 [PMID: 25415785]
  - 32 **Lovell WW**, Winter RB, Morrissy RT, Weinstein SL. Lovell and Winter's pediatric orthopaedics. Vol. 1. Philadelphia, PA: Lippincott Williams Wilkins, 2006
  - 33 **Wang YP**, Zhang W, An JL, Zhang J, Bai JY, Sun YP. Evaluation of Transforaminal Endoscopic Discectomy in Treatment of Obese Patients with Lumbar Disc Herniation. *Med Sci Monit* 2016; **22**: 2513-2519 [PMID: 27425418 DOI: 10.12659/MSM.899510]
  - 34 **Bae JS**, Lee SH. Transforaminal full-endoscopic lumbar discectomy in obese patients. *Int J Spine Surg* 2016; **10**: 18 [PMID: 27441176 DOI: 10.14444/3018]
  - 35 **Manmohan S**, Dzulkarnain A, Nor Azlin ZA, Fazir M. Bertolotti's syndrome: A commonly missed cause of back pain in young patients. *Malays Fam Physician* 2015; **10**: 55-58 [PMID: 27099663]
  - 36 **Jancuska JM**, Spivak JM, Bendo JA. A Review of Symptomatic Lumbosacral Transitional Vertebrae: Bertolotti's Syndrome. *Int J Spine Surg* 2015; **9**: 42 [PMID: 26484005 DOI: 10.14444/2042]
  - 37 **Sairyo K**, Matsuura T, Higashino K, Sakai T, Takata Y, Goda Y, Suzue N, Hamada D, Goto T, Nishisho T, Sato R, Tsutsui T, Tonogai I, Mineta K. Surgery related complications in percutaneous endoscopic lumbar discectomy under local anesthesia. *J Med Invest* 2014; **61**: 264-269 [PMID: 25264043 DOI: 10.2152/jmi.61.264]
  - 38 **Ahn Y**. Transforaminal percutaneous endoscopic lumbar discectomy: technical tips to prevent complications. *Expert Rev Med Devices* 2012; **9**: 361-366 [PMID: 22905840 DOI: 10.1586/erd.12.23]

**P- Reviewer:** Chen YK, Emara KM, Lykissas MG **S- Editor:** Ji FF

**L- Editor:** A **E- Editor:** Lu YJ





Published by **Baishideng Publishing Group Inc**  
7901 Stoneridge Drive, Suite 501, Pleasanton, CA 94588, USA  
Telephone: +1-925-223-8242  
Fax: +1-925-223-8243  
E-mail: [bpgoffice@wjgnet.com](mailto:bpgoffice@wjgnet.com)  
Help Desk: <http://www.f6publishing.com/helpdesk>  
<http://www.wjgnet.com>

