

# Daclatasvir and Asunaprevir Combination Therapy-induced Hepatitis and Cholecystitis with Coagulation Disorder due to Hypersensitivity Reactions

Yuichi Miyashima, Yuichi Honma, Koichiro Miyagawa, Shinji Oe, Michio Senju, Michihiko Shibata, Masaaki Hiura, Shintaro Abe and Masaru Harada

---

## Abstract

---

A 70-year-old woman with chronic hepatitis C was admitted to our hospital due to liver injury, cholecystitis, and disseminated intravascular coagulation with a fever and skin rash. She had been on a combination regimen of daclatasvir and asunaprevir for 2 weeks of a 24-week regimen. Because of the symptoms, laboratory findings, results of a drug-induced lymphocyte stimulation test, and pathological findings of liver biopsy, we diagnosed her with drug-induced liver injury. Although daclatasvir and asunaprevir combination therapy is generally well-tolerated, some serious adverse effects have been reported. Our findings indicate that immunoallergic mechanisms were associated with daclatasvir and asunaprevir-induced liver injury.

**Key words:** asunaprevir, chronic hepatitis C, complement deficiency, daclatasvir, disseminated intravascular coagulation

(Intern Med 55: 3595-3601, 2016)

(DOI: 10.2169/internalmedicine.55.7347)

---

## Introduction

---

The combination therapy of daclatasvir, a hepatitis C virus (HCV) NS5A inhibitor, and asunaprevir, a second-generation NS3/4A protease inhibitor, was approved in July 2014 in Japan as the first interferon (IFN)-free therapy for chronic hepatitis C (CHC) caused by HCV genotype 1b. This combination therapy has been shown to achieve a high rate of sustained virological response (SVR) in null responders to IFN based therapy and populations ineligible or intolerant to IFN (1). An open-label phase-III clinical trial demonstrated an SVR rate of 85% after 24 weeks of daclatasvir and asunaprevir combination therapy (2). The common side effects are nasopharyngitis, elevation of alanine aminotransferase (ALT) and aspartate aminotransferase (AST), headache, diarrhea and pyrexia and serious adverse events are reported in 5.9% of patients during this treatment. About 91% of the patients with grade 3 or 4 ALT and AST elevation discontinued the treatment due to adverse effects (2). However, the discontinuation rate of this treatment due to side

effects is lower than in conventional IFN-based therapies. In spite of its high tolerability, some patients on daclatasvir and asunaprevir therapy have to stop this treatment due to severe side effects. A previous report described a patient who discontinued this therapy and started corticosteroid treatment after developing immunoallergic hepatitis (3). However, details regarding the mechanisms of daclatasvir and asunaprevir combination therapy-induced liver injury remain unclear, and elucidation of the mechanisms of the associated severe adverse effects is urgently needed.

We herein report a patient receiving daclatasvir and asunaprevir combination therapy who developed drug-induced liver injury, cholecystitis, and disseminated intravascular coagulation (DIC), in whom immunoallergic mechanisms were considered to be related to the liver injury.

---

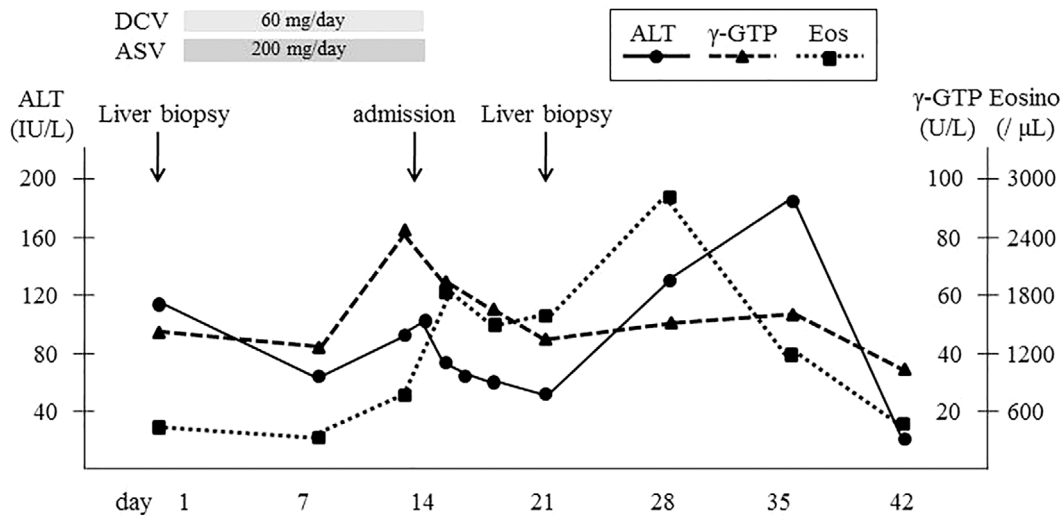
## Case Report

---

A 70-year-old woman with CHC was admitted to our hospital for general fatigue and a fever. She had been started on a combination therapy of daclatasvir (60 mg/day) and

**Table 1. The Laboratory Findings Before Starting the Antiviral Therapy.**

Hematology		TG	53 mg/dL	Coagulation	
WBC	5,300 / $\mu$ L	T-Chol	123 mg/dL	PT	100 %
Neut	45.8%	BUN	13 mg/dL	APTT	32.1 sec
Eos	8.7%	Cre	0.66 mg/dL	Fibrinogen	196 mg/dL
Baso	0.4%	Na	139 mEq/L	Tumor markers	
Lympho	38.6%	K	4.7 mEq/L	AFP	10.2 ng/mL
RBC	431 $\times 10^4$ / $\mu$ L	Cl	102 mEq/L	PIVKA-II	16 mAU/mL
Hb	13.6 g/dL	Hyaluronic acid	744 ng/dL	Virus markers	
Hct	40.7%	type IV collagen	196 ng/mL	HBs Ag	(-)
PLT	11.2 $\times 10^4$ / $\mu$ L	TSH	0.42 $\mu$ IU/mL	HBc-IgG	(-)
Biochemistry		FT4	1.50 ng/dL	HCV RNA	5.4 LIU/mL
TP	7.3 g/dL	Blood sugar	115 mg/dL	genotype	1B
Alb	3.7 g/dL	HbA1c(NGSP)	5.9%		
T-Bil	0.5 mg/dL	Serology			
D-Bil	0.2 mg/dL	CRP	0.01 mg/dL		
AST	95 IU/L	ANA	40 $\times$		
ALT	113 IU/L	AMA(M2)	2.2		
LDH	183 IU/L	IgG	1,813 mg/dL		
ALP	269 IU/L	IgA	200 mg/dL		
$\gamma$ -GTP	46 IU/L	IgM	414 mg/dL		

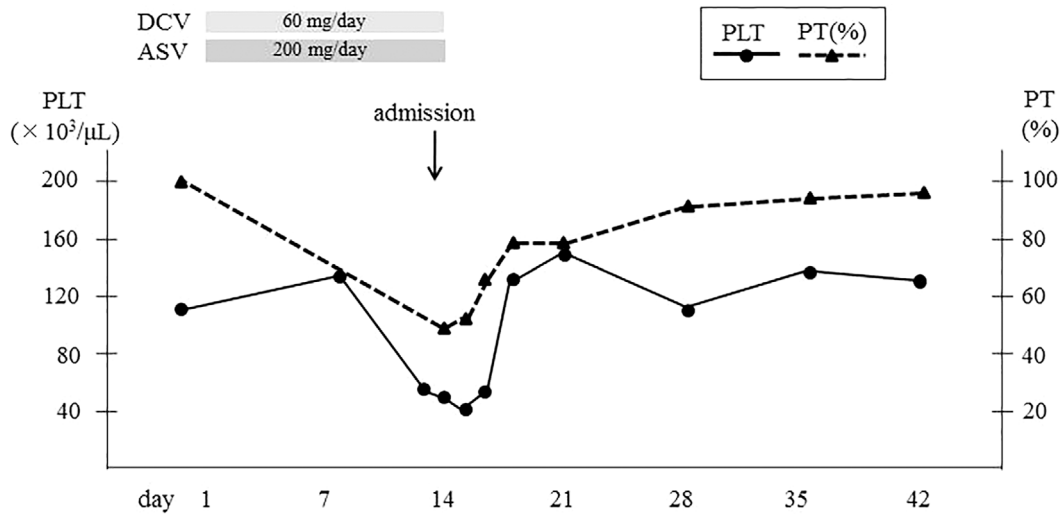
**Figure 1. The clinical course of the liver dysfunction and eosinophilia in the present case.**

asunaprevir (200 mg/day) at our hospital 2 weeks earlier, for a planned total of 24 weeks. She never received antiviral therapy for CHC. She had a history of drug allergy to some kinds of antibiotics but had no allergic diseases. The patient had a surgical history of ovarian tumor and blood transfusion at age 17. She was not a habitual drinker and did not take other drugs. There was no family history of liver diseases. The laboratory findings before starting the antiviral therapy are shown in Table 1. Serum ALT was 113 U/L, AST was 95 U/L, and HCV RNA was 6.1 log IU/mL. Her HCV genotype was 1b. Direct sequencing and a cycling-probe analysis did not show a Y93H or L31 mutation in the NS5A region of the HCV RNA. The white blood cell (WBC) count was 5,300/mm<sup>3</sup>, and the eosinophil count was 461/mm<sup>3</sup>. The combination therapy of daclatasvir and asunaprevir effectively improved the serum ALT (64 U/L) and AST (39 U/L) levels and decreased the HCV RNA (1.6

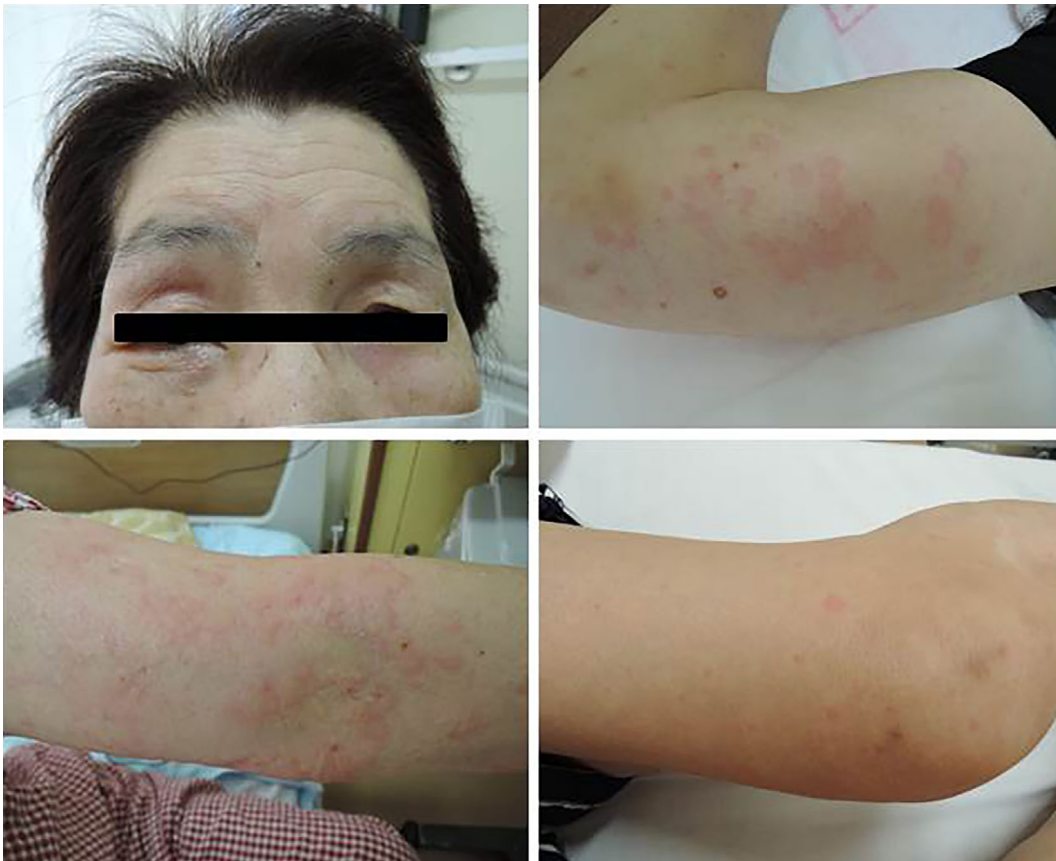log IU/mL) on Day 8 of the combination therapy.

The clinical course of the present patient is shown in Fig. 1 and 2. On Day 11 of the therapy, she developed general fatigue, a fever (38.6°C), and headache without nasopharyngitis or jaundice. On Day 14, a physical examination after admission showed tenderness in the right hypochondrium and palpable liver in the epigastrium. No findings of hepatic encephalopathy were evident. A rash covering the whole body was observed, including the face, trunk, and extremities, up to approximately 50% of the body surface without skin peeling or mucous membrane ulceration (Fig. 3).

The laboratory data on admission are shown in Table 2, with details as follows: the levels of ALT (102 U/L), AST (40 U/L),  $\gamma$ -GTP (82 U/L), and C-reactive protein (CRP) (1.65 mg/dL) were elevated, and the HCV RNA level was markedly decreased (undetectable) compared with her base-



**Figure 2.** The clinical course of the coagulation disorder in the present case.



**Figure 3.** Skin rashes covering the whole body of the patient.

line values. The total bilirubin (1.1 mg/dL) and alkaline phosphatase (ALP) (220 U/L) levels were not elevated, but the ammonia ( $\text{NH}_3$ ) (72  $\mu\text{g/dL}$ ) level was slightly elevated. The findings for hepatitis B surface antigen, anti-hepatitis A virus IgM, and anti-hepatitis E virus IgA antibody were negative, as were the findings for anti-cytomegalovirus (CMV) IgM and anti-Epstein-Barr virus (EBV) IgM antibody, while the findings for anti-CMV IgG, anti-EBV IgG, and anti-EBV-determined nuclear antigen (EBNA) antibody were positive. The findings for anti-human herpes virus

(HHV) 1 and 2 IgM-antibody were negative, while those for IgG-antibody was positive. The findings for HHV 6 DNA were negative, as were the findings for anti-nuclear antibody, while the findings for IgG, IgA and IgM levels were within the normal ranges. However, the IgE level was elevated (503 U/mL). The WBC count (14,000/ $\text{mm}^3$ ) and eosinophil count (1,820/ $\text{mm}^3$ ) were increased, while the platelet (PLT) count was unchanged (44,000/ $\text{mm}^3$ ). Coagulation tests revealed a decrease in the % of prothrombin time (PT) (49.9%), PT-international normalized ratio (INR)

**Table 2. The Laboratory Data on Admission.**

Hematology		TG	99 mg/dL	Coagulation	
WBC	14,000 / $\mu$ L	T-Chol	80 mg/dL	PT	49.9 %
Neut	68.9%	BUN	15 mg/dL	APTT	40.9 sec
Eos	13.0%	Cre	0.90 mg/dL	Fibrinogen	414 mg/dL
Baso	0.0%	Na	132 mEq/L	FDP	8.9 $\mu$ g/mL
Lympho	12.4%	K	3.8 mEq/L	AT-III	53 %
RBC	389 $\times 10^4$ / $\mu$ L	Cl	100 mEq/L	D-dimer	1.6 $\mu$ g/mL
Hb	12.5 g/dL	Fe	48 $\mu$ g/dL	Virus markers	
Hct	36.1%	Ferritin	311 ng/mL	HAV-IgM	(-)
PLT	4.4 $\times 10^4$ / $\mu$ L	NH <sub>3</sub>	72 $\mu$ g/dL	HBs Ag	(-)
Biochemistry		Serology		HCV RNA	undetectable
TP	6.4 g/dL	CRP	1.65 mg/dL	HEV-IgA	(-)
Alb	3.1 g/dL	ANA	<40 $\times$	EBV-IgM	(-)
T-Bil	1.1 mg/dL	IgG	1,265 mg/dL	EBV-IgG	(+)
D-Bil	0.8 mg/dL	IgA	153 mg/dL	EBNA	(+)
AST	40 IU/L	IgM	255 mg/dL	CMV-IgM	(-)
ALT	102 IU/L	IgE	503 U/mL	CMV-IgG	(+)
LDH	170 IU/L	C3	113 mg/dL	HHV1-IgM	(-)
ALP	220 IU/L	C4	<5.0 mg/dL	HHV2-IgM	(-)
$\gamma$ -GTP	63 IU/L	CH50	<5.0 U/mL	HHV6 DNA	undetectable

(1.55), and anti-thrombin III (53%). The levels of fibrin/fibrinogen degradation product (FDP) (8.9  $\mu$ g/mL) and d-dimer (1.6  $\mu$ g/mL) were elevated. In addition, the levels of serum complements, C4 (<5.0 mg/dL), and 50% hemolytic unit of complement (CH50) (<5.0 U/mL) were quite low, but C3 (113 mg/dL) and C1q (<1.5  $\mu$ g/mL) were within the normal ranges.

Abdominal ultrasonography and contrast-enhanced computed tomography (CT) revealed hepatomegaly, dullness of the edge and periportal collar signs in the liver, and marked wall thickness and sludge accumulation of the gallbladder (Fig. 4). A small amount of ascites in surface of the liver and pleural effusion in the right thoracic cavity were detected. Hematoxylin and eosin staining of liver biopsy before the initiation of the combination therapy showed moderate chronic inflammatory infiltrates in the expanded portal areas with mild fibrosis (Fig. 5a). Liver biopsy performed on admission showed inflammatory infiltrate of eosinophils, which had not been detected just before starting the combination therapy. Lymphocytes in the hepatic lobes and portal areas with interface hepatitis and mild fibrosis were demonstrated (Fig. 5b-d). No increases were noted in the levels of reticular fiber and collagen fiber on silver impregnation staining (Fig. 5e). Periodic acid schiff with diastase digestion (D-PAS) staining showed increased numbers of Kupffer cells in the sinusoid, indicating acute liver injury (Fig. 5f). The findings from a drug-induced lymphocyte stimulation test (DLST) for both daclatasvir (stimulation index; 265%) and asunaprevir (stimulation index; 205%) were positive.

Given the above findings, we diagnosed her with drug-induced liver injury, cholecystitis, and DIC due to daclatasvir and asunaprevir combination therapy and immediately stopped both drugs. The diagnosis of DIC was based on the DIC diagnostic criteria issued by the Japanese Association of Acute Medicine, including the findings of systemic inflammatory response syndrome (SIRS) (WBC >12,000/mm<sup>3</sup>,

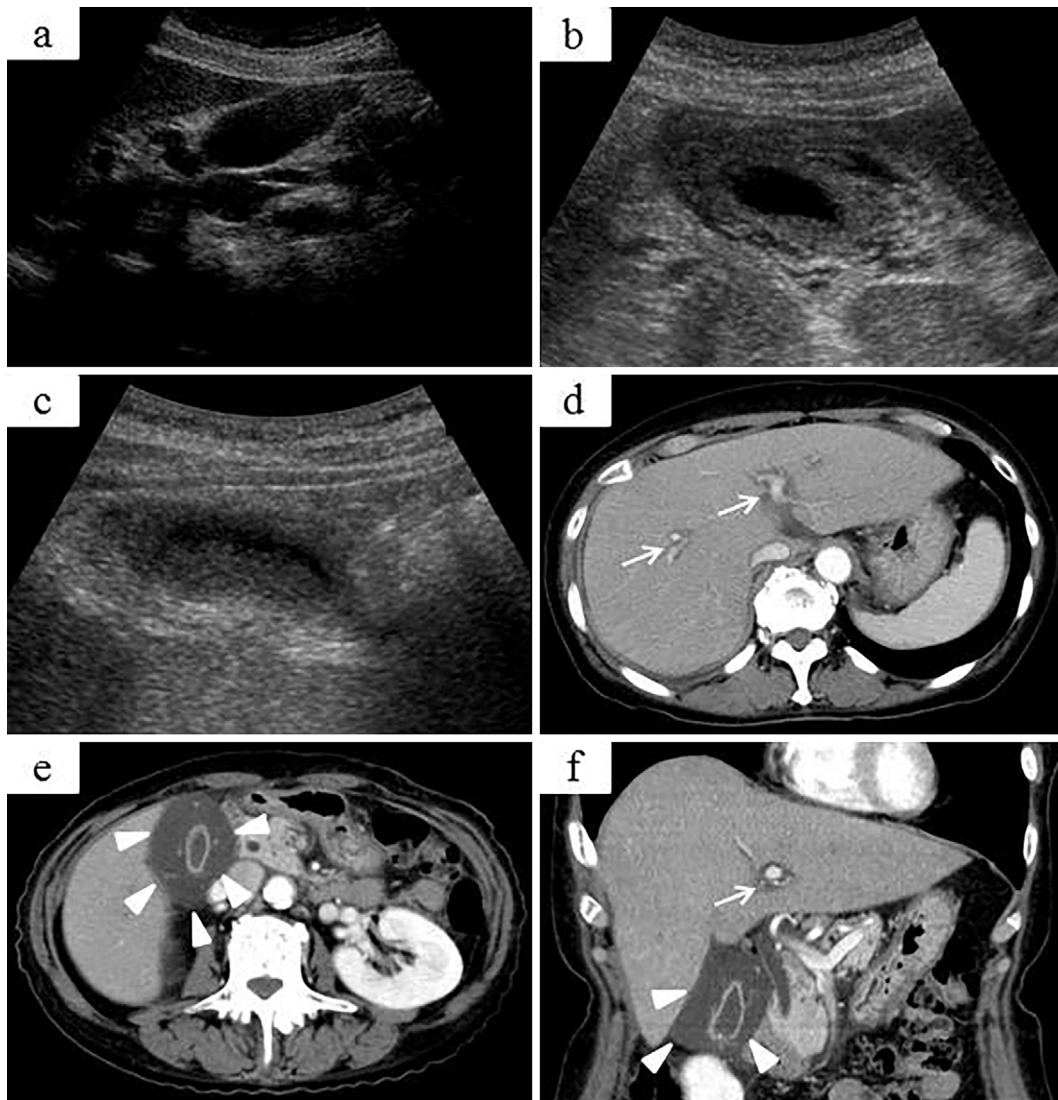
heart rate >90/min, respiratory rate >20/min), thrombocytopenia (PLT <80,000/mm<sup>3</sup>), and elevated PT-INR (PT-INR >1.2), and by the Japanese Ministry and Health, Labor and Welfare, including primary disease, thrombocytopenia (PLT <50,000/mm<sup>3</sup>) and elevated PT-INR (PT-INR >1.25). In addition, the elevated FDP and d-dimer levels and the decreased AT-III activity supported the diagnosis of DIC.

The symptoms, including a fever, skin rash, abdominal pain in the right hypochondrium, and epigastralgia, were resolved after the discontinuation of daclatasvir and asunaprevir. The laboratory examinations revealed improvement in the serum CRP, WBC count, thrombocytopenia, and coagulation abnormalities, but the elevation of ALT and AST levels and eosinophilia persisted for four weeks. The ultrasonography findings of hepatomegaly and thickening of the gallbladder wall gradually improved after discontinuing the therapy. HCV RNA remained below the detectable limit (<1.2 log IU/mL) 4 weeks after stopping daclatasvir and asunaprevir. However, because the HCV RNA subsequently increased (5.0 log IU/mL) at 8 weeks after discontinuing the combination therapy, the patient did not achieve an SVR.

## Discussion

The combination therapy of daclatasvir and asunaprevir was the first IFN-free oral treatment approved in Japan. To date, this combination therapy has been introduced in many patients with CHC, and a high SVR rate has been achieved. A low rate of serious adverse effects and good tolerability are among the promising features of this therapy; however, elevated levels of ALT and AST occur in about 16% and 13% of patients, respectively (2).

The incidence of adverse events, such as the elevation of levels of aminotransferases, is reported to differ between Japanese and European patients (4). A similar ethnic difference has also been observed in the occurrence of side ef-



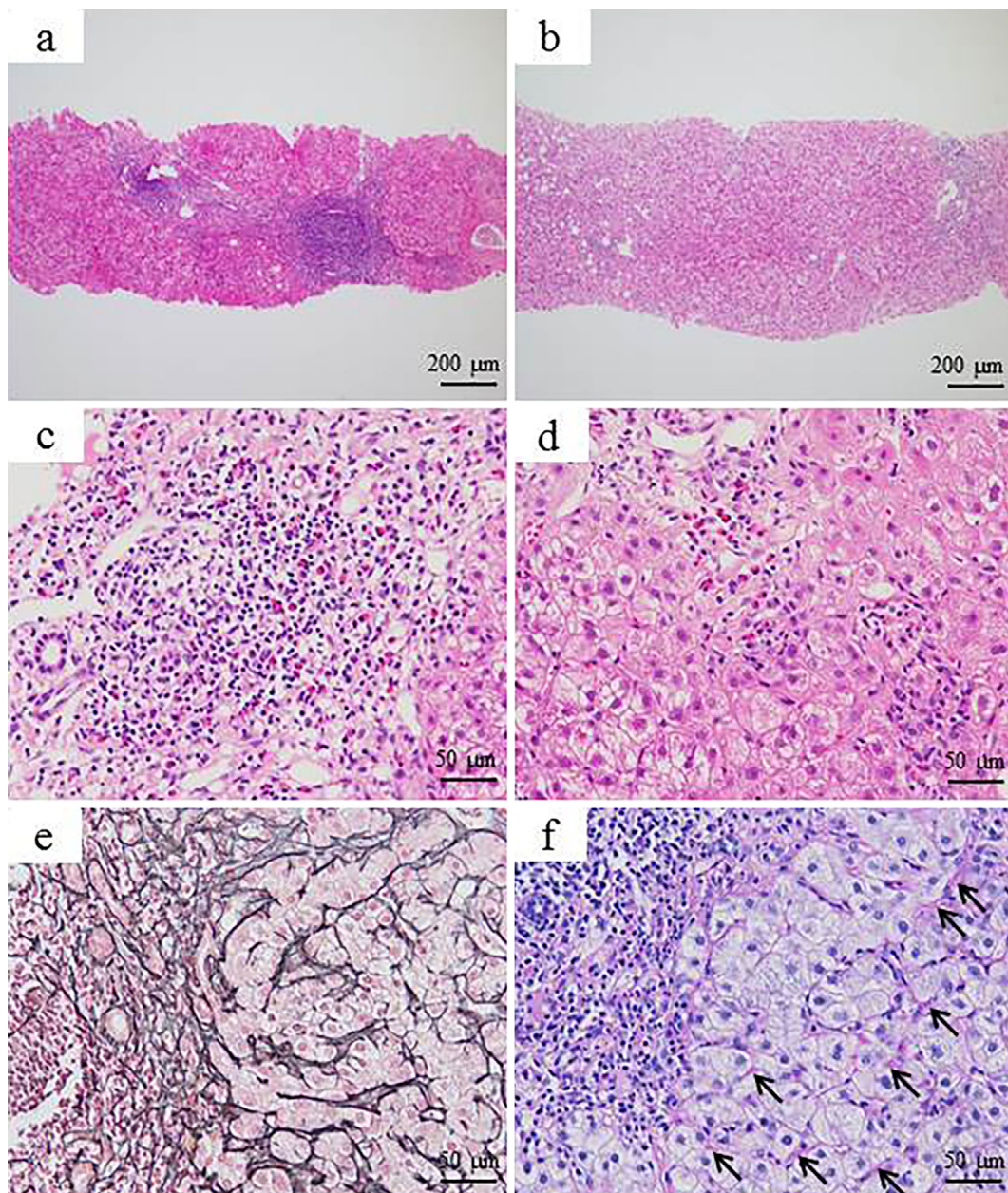
**Figure 4.** Abdominal ultrasonography and contrast-enhanced computed tomography (CE-CT) images of the patient. (a) The ultrasonography findings of the patient before the daclatasvir and asunaprevir combination therapy. (b) The ultrasonography findings of the patient on admission. (c) The ultrasonography findings of the patient 4 weeks after discontinuing the daclatasvir and asunaprevir combination therapy. (d) (e) The axial CE-CT images of the patient. (d) The periportal collar sign (arrow) and (e) subserosal edema of the gallbladder wall (arrowhead) were revealed. (f) Sagittal contrast-enhanced computed tomography revealed the periportal collar sign (arrow) and subserosal edema of the gallbladder wall (arrowhead).

fects. However, although a previous report had suggested an immunoallergic mechanism for daclatasvir and asunaprevir combination therapy-induced hepatic injury (3), the mechanisms of daclatasvir and asunaprevir combination therapy-induced hepatic injury are poorly understood.

The present case was diagnosed as liver injury, cholecystitis, and DIC based on the findings from laboratory examinations and the abdominal physical and imaging findings. The ALT elevation and eosinophilia in this patient persisted more than five weeks after stopping the combination therapy. The clinical course of drug-induced liver injury after discontinuation of causing drugs seems to be variable. The elevation of liver enzymes with drug-induced liver injury has been reported to persist for several months after discontinuing the

causal agents (5). Previous reports have been shown that the severity grading of rash associated with telaprevir, another NS3/4A protease inhibitor for CHC (6, 7). The skin findings for the present case support a moderate (grade 2) but not severe grade on the telaprevir-associated rash severity scale.

As previously reported (3), we also suspected drug-induced hypersensitivity syndrome (DIHS) based on the symptoms, such as a fever and skin rash, and the laboratory findings, including eosinophilia. DIHS is characterized by a skin rash, a fever, leukocytosis with eosinophilia or atypical lymphocytosis, and the liver dysfunction (8, 9). The diagnostic criteria for DIHS include maculopapular rash developing over three months after starting drugs, lymphadenopathy, a fever, leukocytosis, hepatitis, and HHV 6 reactivation.



**Figure 5.** The histopathological findings of the liver biopsy specimen. (a) Hematoxylin and Eosin (H&E) staining, of the liver biopsy specimen before starting the combination therapy. Liver section showed moderate chronic inflammatory infiltrates in the expanded portal areas with mild fibrosis (Scale bar=200  $\mu\text{m}$ ). (b) (c) (d) H&E staining of the liver biopsy specimen on admission showed moderate acute eosinophil infiltration in the liver parenchyma and expanded portal areas with the features of interface hepatitis and mild fibrosis (Scale bars=200  $\mu\text{m}$  and 50  $\mu\text{m}$ , respectively). (e) Silver impregnation staining of the liver biopsy specimen on admission showed no increase in the reticular or collagen fibers (Scale bar=50  $\mu\text{m}$ ). (f) Periodic acid schiff with diastase digestion (D-PAS) staining of the liver biopsy specimen on admission showed an increased number of Kupffer cells (arrows) in the sinusoid (Scale bar=50  $\mu\text{m}$ ).

The diagnosis of DIHS is confirmed by the presence of five of the six symptoms (10). The liver dysfunction occurs in up to 70% of DIHS (10). The eosinophilia may often be delayed for several weeks and occur even after the elevated liver enzyme levels have returned to baseline (10). In the present case, the allergic symptoms, aminotransferase elevation, and eosinophilia were evident. However, the onset time of the symptoms and absence of HHV 6 reactivation did not

meet the criteria. We considered the persistent elevation of ALT and eosinophilia in the present case to correspond to the course of immune-mediated drug-induced liver injury.

Interestingly, the findings for the DLST for both daclatasvir and asunaprevir were strongly positive. The sensitivity of DLST is considered to be about 50%. Given that the DLST is considered to be useful for diagnosing drug-induced liver injury (11, 12), we considered that daclatasvir and asunapre-

vir were the liver injury-causing drugs in the present patient. To our knowledge, this is the first report to verify directly by the DLST that daclatasvir and asunaprevir-induced liver injury was associated with immunoallergic mechanisms. In addition, the comparison of the pathological findings of the liver biopsy specimens before and after the combination therapy strongly indicated the presence of allergic reactions.

We diagnosed the patients with acalculous cholecystitis based on the findings from the physical examination, such as tenderness in the right hypochondrium; the laboratory data, such as an increase in the WBC count and elevation of CRP levels; and the imaging findings, such as wall thickening and debris in the gallbladder. A number of drugs have been reported to induce gallbladder diseases, including hypersensitivity-induced cholecystitis (13). Most cases of acute cholecystitis are caused by gallstones, but an allergic reaction has also been reported to be involved in some cases (14). To our knowledge, there are no specific imaging findings associated with drug-induced or allergic cholecystitis. We speculated that the wall thickening of the gallbladder was due to interstitial edema in the subserosal layer with dilated capillaries and lymphatics induced by allergic mechanisms as well as other etiologies (14).

Drug-induced cholecystitis and DIC by allergic mechanisms have been reported (15, 16). Cholecystitis and DIC developed together in the present case along with other allergic symptoms and immediately improved after discontinuing the combination therapy. We therefore speculated that the cholecystitis and DIC might have been complications of the combination therapy.

However, the C4 and CH50 levels in this patient were quite low. Complement activity is associated with acetaminophen-induced liver injury (17) and is involved in the pathogenesis of a variety of liver diseases (18). The levels of serum complements, including C1q, C3, C4, and CH50, are decreased in patients with liver dysfunction (19). In the present patient, the levels of C3, C4, and CH50 had been extremely low in previous blood examinations (18 years prior). We therefore considered that the liver injury in this patient was related to a low complement activity, although the details regarding this relationship remain unclear.

In conclusion, we herein reported a case of daclatasvir and asunaprevir-induced liver injury, acalculous cholecystitis, and DIC. To our knowledge, this is the first report to directly verify daclatasvir and asunaprevir-induced liver injury by both the DLST and the pathological findings of a liver biopsy. Our present findings will enable the formulation of a new hypothesis regarding the mechanisms of daclatasvir and asunaprevir-induced liver injury.

**The authors state that they have no Conflict of Interest (COI).**

## References

1. Suzuki Y, Ikeda K, Suzuki F, et al. Dual oral therapy with daclatasvir and asunaprevir for patients with HCV genotype 1b infection and limited treatment options. *J Hepatol* **58**: 655-662, 2013.
2. Kumada H, Suzuki Y, Ikeda K, et al. Daclatasvir plus asunaprevir for chronic HCV genotype 1b infection. *Hepatology* **59**: 2083-2091, 2014.
3. Fujii Y, Uchida Y, Mochida S. Drug-induced immunoallergic hepatitis during combination therapy with daclatasvir and asunaprevir. *Hepatology* **61**: 400-401, 2015.
4. Manns M, Pol S, Jacobson IM, et al. All-oral daclatasvir plus asunaprevir for hepatitis C virus genotype 1b: a multinational, phase 3, multicohort study. *Lancet* **384**: 1597-1605, 2014.
5. Verma S, Kaplowitz N. Diagnosis, management and prevention of drug-induced liver injury. *Gut* **58**: 1555-1564, 2009.
6. Cacoub P, Bourlière M, Lübke J, et al. Dermatological side effects of hepatitis C and its treatment: patient management in the era of direct-acting antivirals. *J Hepatol* **56**: 455-463, 2012.
7. Biesbroeck LK, Scott JD, Taraska C, Moore E, Falsey RR, Shinohara MM. Direct-acting antiviral-associated dermatitis during chronic hepatitis C virus treatment. *Am J Clin Dermatol* **14**: 497-502, 2013.
8. Chaiken BH, Goldberg BI, Segal JP. Dilantin sensitivity; report of a case of hepatitis with jaundice, pyrexia and exfoliative dermatitis. *N Engl J Med* **242**: 897-898, 1950.
9. Kano Y, Shiohara T. The variable clinical picture of drug-induced hypersensitivity syndrome/drug rash with eosinophilia and systemic symptoms in relation to the eliciting drug. *Immunol Allergy Clin North Am* **29**: 481-501, 2009.
10. Shiohara T, Inaoka M, Kano Y. Drug-induced hypersensitivity syndrome (DIHS): a reaction induced by a complex interplay among herpesviruses and antiviral and antidrug immune responses. *Allergol Int* **55**: 1-8, 2006.
11. Takikawa H, Takamori Y, Kumagi T, et al. Assessment of 287 Japanese cases of drug induced liver injury by diagnostic scale of the international consensus meeting. *Hepatol Res* **192**: 192-195, 2003.
12. Tajiri K, Shimizu Y. Practical guidelines for diagnosis and early management of drug-induced liver injury. *World J Gastroenterol* **14**: 6774-6785, 2008.
13. Michielsen PP, Fierens H, Van Maercke YM. Drug-induced gallbladder disease. Incidence, aetiology and management. *Drug Saf* **7**: 32-45, 1992.
14. Kimura Y, Takada T, Strasberg SM, et al. TG13 current terminology, etiology, and epidemiology of acute cholangitis and cholecystitis. *J Hepatobiliary Pancreat Sci* **20**: 8-23, 2013.
15. Benn'rad M, Leclerc-Mercier S, Blanche P, et al. Drug-induced hypersensitivity syndrome: clinical and biologic disease patterns in 24 patients. *Medicine (Baltimore)* **88**: 131-140, 2009.
16. Figtree MC, Miyakis S, Tanaka K, Martin L, Konecny P, Krilis S. Dapsone hypersensitivity syndrome causing disseminated intravascular coagulation. *BMJ Case Rep* 2009 (in press).
17. Singhal R, Ganey PE, Roth RA. Complement activation in acetaminophen-induced liver injury in mice. *J Pharmacol Exp Ther* **341**: 377-385, 2012.
18. Qin X, Gao B. The complement system in liver diseases. *Cell Mol Immunol* **3**: 333-340, 2006.
19. Ellison RT, Horsburgh CR Jr, Curd J. Complement levels in patients with hepatic dysfunction. *Dig Dis Sci* **35**: 231-235, 1990.

The Internal Medicine is an Open Access article distributed under the Creative Commons Attribution-NonCommercial-NoDerivatives 4.0 International License. To view the details of this license, please visit (<https://creativecommons.org/licenses/by-nc-nd/4.0/>).