

Impact of Aneurysmal Neck Position in Endovascular Therapy for Anterior Communicating Artery Aneurysms

Hidemichi ITO,¹ Hidetaka ONODERA,¹ Daisuke WAKUI,¹ Masashi UCHIDA,¹
Taigen SASE,¹ Hiroyuki MORISHIMA,² Kotaro OSHIO,¹ and Yuichiro TANAKA¹

¹*St. Marianna University School of Medicine, Kawasaki, Kanagawa;*

²*Kawasaki City Tama Municipal Hospital, Kawasaki, Kanagawa*

Abstract

Anterior communicating artery (ACoA) aneurysms have a complex architecture and many variations, making endovascular therapy more difficult in some cases. The aim of this study was to investigate whether the neck position of an aneurysm was identifiable for determining the immediate angiographic success and procedural complications in the coiling of the ACoA aneurysms. We conducted a retrospective case review of 40 patients with ACoA aneurysms treated by endovascular therapy from 2008 to 2015. The mean age was 66.8 years. Thirty-five aneurysms were ruptured; five were unruptured. For the analysis, the patients were divided into two groups according to the neck position of aneurysms: the true ACoA group, 9 patients with the neck located on the ACoA itself; and the other ACoA group, 31 patients with the neck at the junction of the A1 and A2 portions of an anterior cerebral artery. Morphological characteristics (dome size, dome direction, rate of wide neck, and angulation of aneurysms in relation to the parent artery) were analyzed along with immediate angiographic results, volume embolization ratio (VER), and procedural complications. Small aneurysms with superior dome projection and acute angulation of the aneurysm direction occurred more often in the true ACoA group. The rates of complete obliteration, VER, and procedural complications were 33.3%, 32.3%, and 22.2% in the true ACoA group and 54.8%, 36.3%, and 6.5% in the other ACoA group, respectively. True ACoA aneurysms could present an anatomical difficulty in endovascular coiling. Aneurysmal neck position should be accurately assessed to achieve successful embolization of the ACoA aneurysms.

Key words: anterior communicating artery aneurysm, endovascular therapy, morphology, volume embolization ratio

Introduction

Anterior communicating artery (ACoA) aneurysms are the most common type of intracranial aneurysms.¹⁾ Due to the deep, midline location of these aneurysms and the number of important small perforating arteries arising from the ACoA, microsurgical neck clipping remains an arduous task. Since the International Subarachnoid Aneurysm Trial revealed the efficacy of endovascular treatment for ruptured aneurysms, endovascular therapy has commonly been performed for ACoA aneurysms.²⁾ Furthermore, the continuing evolution of endovascular techniques and devices have dramatically changed the ability of endovascular coiling as a therapeutic alternative for ACoA aneurysms.^{3–5)} However, ACoA aneurysms have a unique anatomical architecture and many

variations, making endovascular therapy more difficult in some cases than others. Several investigators have described the morphological criteria for unsuccessful endovascular therapy; however, more detailed pre-therapeutic analyses of the anatomical features of ACoA aneurysms are still necessary.^{4,6–9)} In the present study, we describe our experience with endovascular coil embolization for ACoA aneurysms. We performed a retrospective analysis of aneurysm morphology corresponding to both successful and unsuccessful endovascular therapy to assess the difficulties of coil embolization in terms of the neck position of aneurysms.

Materials and Methods

I. Patients

We performed a retrospective review of 347 medical records of patients from April 2008 through

March 2015 who underwent coil embolization for cerebral aneurysms at our university hospital and its affiliated hospitals. We included 40 patients who received therapy for ACoA aneurysms at those hospitals during that 8-year period. Twenty-six patients were women (65.0%) and 14 were men (35.0%). Their ages ranged from 44 years to 90 years, with an average age of 66.8 years. Thirty-five aneurysms (87.5%) presented with a subarachnoid hemorrhage, and 5 (12.5%) were incidental. Of these, 8 were categorized as Hunt and Hess Grade I, 6 as Grade II, 8 as Grade III, 10 as Grade IV, and 3 as Grade V. All cases presenting subarachnoid hemorrhage underwent coil embolization within 48 h after the primary hemorrhage. The aneurysm sizes ranged from 2.2 mm to 13.0 mm in diameter, with an average of 4.8 mm. Sixteen aneurysms (40.0%) were small, 21 (52.5%) were medium, 3 (7.5%) were large, and 20 (50.0%) were wide-neck aneurysms. We separated the patients into two anatomical groups according to the aneurysmal neck position located exclusively on the ACoA itself (true ACoA group) or at the junction between the A1 and A2 portions of an anterior cerebral artery (other ACoA group).

The indications for coil embolization included poor neurological grade, poor general condition, anticipated surgical difficulty, and refusal of surgery. The study design was approved by the ethics review board of our hospital.

II. Analyses of anatomical characteristics

We analyzed the aneurysmal morphology on digital subtraction and three-dimensional (3D) angiograms at the time of embolization. Several anatomic characteristics were recorded blindly with respect to the

embolization results. These characteristics included dome size, superior/inferior direction of the aneurysm dome with respect to horizontal lines, the rate of wide neck aneurysms, and aneurysms angle, defined as the angle between the parent artery and the aneurysmal dome projection.

A small aneurysm was defined as that with a dome of < 4 mm at the largest diameter. Medium aneurysms were those with dome diameters of 4 mm to 10 mm. Large aneurysms were those with dome diameters of > 10 mm. Dome-to-neck ratios were categorized into those > 2 and those \leq 2. Wide-neck aneurysms were defined as those having a dome-to-neck ratio of < 2, excluding the diameter of their neck size. The aneurysm angle was measured on 3D angiograms, according to Songsaeng et al.,⁹⁾ as follows: first, the direction of the parent artery was determined by a line toward the aneurysm neck, and then, by a line from the aneurysm neck to the dome (Figs. 1, 2). The smallest angle between these two lines was determined. Measurements were done using a dedicated 3D workstation (Infinix Celeve-i, Toshiba Medical Systems Corporation, Otawara Tochigi).

III. Surgical procedures

All procedures were performed via the transfemoral approach, under general anesthesia. After placement of the sheath, systemic heparinization was achieved. Patients with unruptured aneurysms received 75 mg clopidogrel daily for 7 days before the procedures. After the procedures, all the patients received antiplatelet therapy for 3 months. Aneurysms were routinely embolized with coils through a 6 French guide catheter (Envoy, Cordis, Johnson & Johnson, Fremont, California, USA). With the

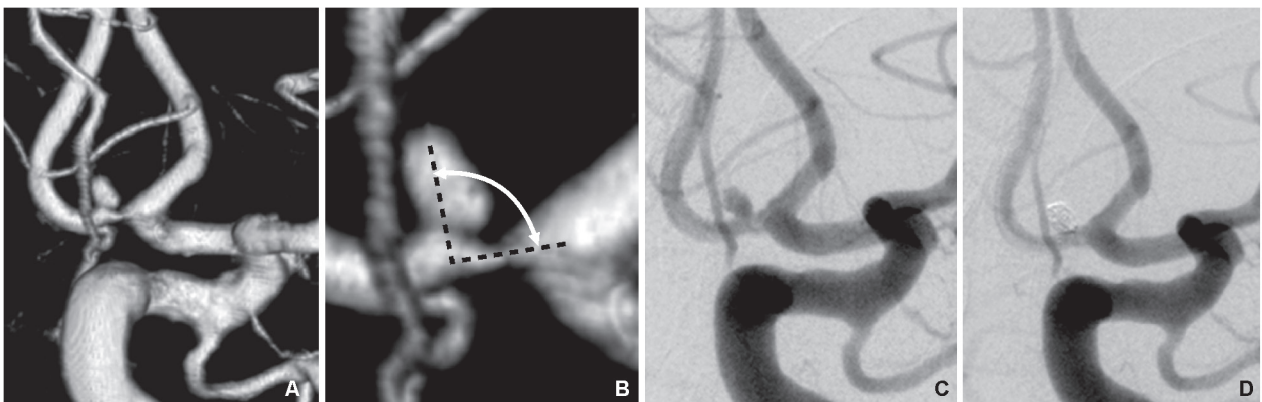


Fig. 1 A typical case in the true ACoA group. **A:** A three-dimensional (3D) angiogram (working projection view) showing a 3.1-mm anterior communicating artery aneurysm with a superior projection. **B:** The method to determine the aneurysm angle is described in the text and below. The minimum angle (93°) was measured between the direction of the parent vessel and the major aneurysm axis. **C:** An internal carotid artery angiogram (working projection view) showing the aneurysm. **D:** The postprocedural angiogram demonstrating complete obliteration.

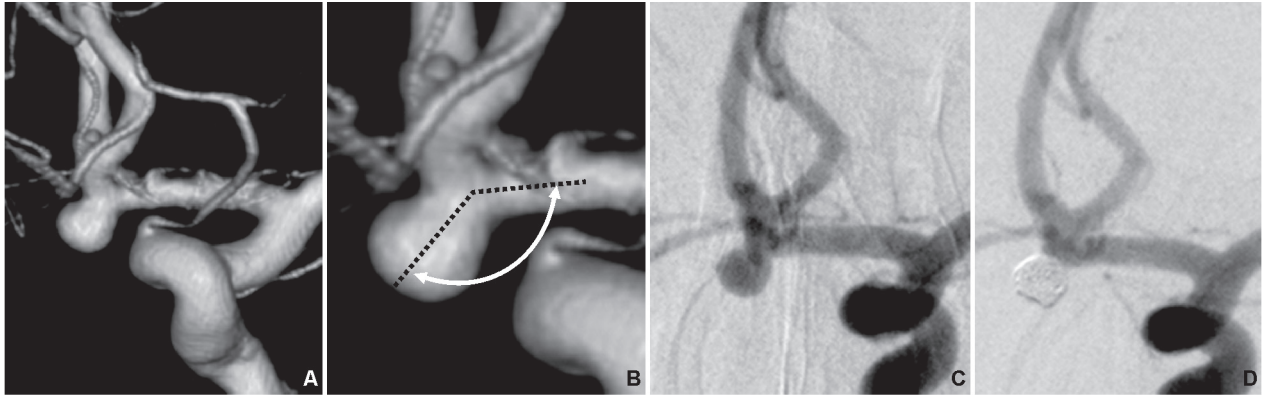


Fig. 2 A typical case in the other ACoA group. **A:** A three-dimensional (3D) angiogram (working projection view) showing a 4.3-mm anterior communicating artery aneurysm with an inferior projection. **B:** The 126° aneurysm angle was determined as described previously. **C:** An internal carotid artery angiogram showing the aneurysm. **D:** The postprocedural angiogram demonstrating complete obliteration.

guide catheter in position within the prepetrous portion of an internal carotid artery, the aneurysm was accessed with a microcatheter (SL-10, Stryker, Kalamazoo, Michigan, USA). A soft-tipped microguidewire (Transend™, Boston Scientific, Natick, Massachusetts, USA; Chikai, Asahi Intecc Co. Ltd., Nagoya, Aichi) was used to steer the microcatheter. When necessary, the microcatheter tip was pre-steam-shaped to ease subsequent negotiation through the A1 segment into the aneurysm. The microguidewire with microcatheter was slowly advanced into the aneurysm. A single microcatheter technique was primarily attempted, and for wide-necked aneurysms, balloon assistance was performed according to the surgeon's preferences. Coils were deployed into the aneurysm under "roadmap" conditions. The coils used were Guglielmi detachable coils (Boston Scientific, Natick, Massachusetts, USA), Target detachable coils (Stryker, Kalamazoo, Michigan, USA), and ED coils (Kaneka Medix Corp., Osaka). Dense packing was attempted in all aneurysms. Immediate post-treatment angiograms were used to assess the immediate extent of aneurysm occlusion after coil embolization. An embolization was considered complete obliteration when there was no contrast filling of the dome and neck of an aneurysm. A neck remnant was defined as residual filling of the neck of the aneurysm. Body filling was indicated by contrast medium in the neck and body of an aneurysm. Volume embolization ratio (VER) was calculated by the formula (coil volume/aneurysm volume) × 100%. VER of ≥ 25% and < 25% was considered high and low, respectively.

IV. Statistical analyses

All values are expressed as mean ± standard deviation. Mann-Whitney U test was used for all

statistical analyses. Statistical significance was assigned to values of $p < 0.05$ or $p < 0.01$.

Results

There were 9 (22.5%) aneurysms in the true ACoA group and 31 (77.5%) aneurysms in the other ACoA group. The comparison of baseline characteristics including sex, age, and patients' initial neurological status between the two groups showed no significant differences.

The sizes of the aneurysms were 3.2 ± 0.7 mm in the true ACoA group and 5.7 ± 3.0 mm in the other ACoA group ($p = 0.002$). All the aneurysms in the true ACoA group were small. Seven (22.5%; 7/31) of the aneurysms in the other ACoA group were small ($p < 0.01$). Six aneurysms in the true ACoA group (66.7%; 6/9) and 16 aneurysms in the other ACoA group (51.6%; 16/31) had superiorly oriented dome ($p = 0.43$). The number of aneurysms with wide necks was 5 (55.6%) in the true ACoA group and 15 (48.4%) in the other ACoA group ($p = 0.71$). The aneurysm angle was $100.3 \pm 7.6^\circ$ in the true ACoA group and $160.7 \pm 24.0^\circ$ in the other ACoA group ($p < 0.01$). The true ACoA group exhibited more acute aneurysm angle compared with that in the other ACoA group (Table 1).

The endovascular approach, rather than a microsurgical clip application, was chosen for the following reasons: poor neurological grade in 18 patients, poor general condition in 11, and anticipated surgical difficulty in 3 patients. Eight patients refused surgery.

Eighteen aneurysms (45.0%; 18/40) were treated with a combination of Target and ED coils, 13 aneurysms (32.5%; 13/40) were treated exclusively with Target coils, and 9 aneurysms (22.5%; 9/40)

Table 1 Baseline characteristics and aneurysm morphology of patients in the true anterior communicating artery (ACoA) and other ACoA groups

Variables	True ACoA group (n = 9)	Other ACoA group (n = 31)	P Value
Sex, male	2 (22.2)	12 (38.9)	0.367
Age	68.6 ± 13.1	65.7 ± 12.7	0.503
SAH (%)	8 (88.9)	27 (87.1)	0.454
Size (mm)			
Mean	3.2 ± 0.7	5.7 ± 3.0	0.002
Median (range)	3.3 (2.2–3.9)	4.5 (2.2–13.0)	
Small (< 4)	9 (100)	7 (22.5)	< 0.01
Medium (4–10)	0	21 (67.8)	
Large (> 10)	0	3 (9.7)	
Superior projection	6 (66.7)	16 (51.6)	0.430
Wide neck	5 (55.6)	15 (48.4)	0.708
Angulation (degree)	100.3 ± 7.6	160.7 ± 24.0	0.002

ACoA: anterior communicating artery, SAH: subarachnoid hemorrhage.

were treated exclusively with Guglielmi detachable coils. In four (10.0%; 4/40) cases, the technique of balloon assistance was used. None of the cases required stenting.

Complete obliteration was observed in 20 cases (50.0%; 20/40). Neck remnant was observed in 17 cases (42.5%; 17/40). Body filling was observed in 3 cases (7.5%; 3/40). The rate of complete obliteration was 33.3% (3/9) in the true ACoA group and 54.8% (17/31) in the other ACoA group. There were no unsuccessful attempts of coil embolization. The average VER was 35.1 ± 9.2% (32.3 ± 8.5% in the true ACoA group and 36.3 ± 10.9% in the other ACoA group). Among the small aneurysms in the other ACoA group, the VER was 44.3 ± 9.0% and higher compared with the true ACoA group with significant difference ($p < 0.05$). Based on these findings, the true ACoA group had lower angiographical results compared with the other ACoA groups.

There were four procedure-related complications (10.0%; 4/40) in both groups combined; 2 (22.2%; 2/9) in the true ACoA group and 2 (6.5%; 2/31) in the other ACoA group. All those four cases with hemorrhagic complications due to coil perforations had initially presented with subarachnoid hemorrhage and small aneurysms. There were no cases of thromboembolic complications during the procedure (Table 2). The patients in the true ACoA group had a tendency to develop intraoperative hemorrhagic complications.

Table 2 Angiographic results and complications of patients in the true ACoA and other ACoA groups

Variables	True ACoA group (n = 9)	Other ACoA group (n = 31)	P Value
Angiographic results			
Complete obliteration	3 (33.3)	17 (54.8)	0.262
Neck remnant	5 (55.6)	12 (38.7)	0.374
Body filling	1 (11.1)	2 (6.5)	0.645
VER	32.3 ± 8.5	36.3 ± 10.9	0.249
VER, limited in small aneurysms	32.3 ± 8.5	44.3 ± 9.0	0.015
Complications			
Hemorrhagic	2 (22.2)	2 (6.5)	0.170
Ischemic	0	0	

ACoA: anterior communicating artery, VER: volume embolization ratio.

Regarding the clinical neurological outcome prior to discharge, 35 patients (87.5%) remained neurologically intact, improved, or unchanged from the initial clinical status. The post-treatment clinical examination revealed a permanent new neurological motor deficit in three cases (7.5%); mild in two, and severe in one case. Of these, two patients deteriorated due to severe vasospasm, one deteriorated from disuse, i.e., muscle atrophy, due to severe pneumonia and old age. A total of two patients died (5.0%). Both patients were originally categorized as Hunt and Hess Grade V and died of intraprocedural rupture due to coil perforation.

Discussion

Interestingly, the anatomical characteristics were substantially different between the two groups. The true ACoA group had properties of small dome size and acute aneurysm angle significantly, and a tendency of a superior direction of the aneurysm dome, compared with those in the other ACoA group.

Reviewing the vascular anatomy, the diameter of the A1 segment of the anterior cerebral artery averaged around 2.5 mm, and that of the ACoA averaged from 1.2 mm to 1.5 mm, which is about half of the A1 segment diameter.^{10,11} Perlmutter et al. reported that the ACoA perforating branches arose mostly from the superior aspects of the parent artery (54%).¹⁰ From these anatomical characteristics, small size and superior dome projection could be observed frequently in the true ACoA group. Concerning

aneurysm projection, the true ACoA group could be comparable to those with sidewall aneurysms, with an acute angle from the parent vessel. Conversely, in the other ACoA group, the hemodynamic factors along the course of the A1 segment might associate with the formation of the various dome directions with obtuse angulation in relation to the A1 segment, as in the case with terminal type aneurysms.¹²⁾

Few publications have addressed the endovascular treatment of ACoA aneurysms specifically, but instead, have described several factors affecting the results of coil embolization for ACoA aneurysms.^{4,6-9)} Based on the neck position, Gonzalez et al. suggested that the neck directly on the ACoA was one of the unsuccessful factors for complete obliteration.⁷⁾ However, the reasons were not described in detail. In the present study, we have identified other anatomical factors in each type of group affecting the outcomes for coil embolization of ACoA aneurysms.

Generally, small aneurysms and small neck aneurysms are associated with complete obliteration.^{6,7)} However, the locations of ACoA aneurysms and small aneurysms are also critical factors for intraprocedural rupture and require gentle manipulation.¹³⁻¹⁵⁾ Unfortunately, endovascular access to the ACoA aneurysms could be difficult due to their complex vessel architecture, and it leads to technical risk including a microguidewire jump, resulting in perforating the aneurysm. Moreover, small aneurysms are most likely to occur at this location compared to the branch points of the circle of Willis.⁶⁾ Our rate of intraprocedural ruptures was 10.0%, all of which were small aneurysms. Sluzewski et al. reported seven intraprocedural ruptures in a total of 264 aneurysms, and 4 of the aneurysms were 4 mm or less.¹⁶⁾ Schuette et al. reported an intraprocedural rupture rate of 2.9% (8/273) among ACoA aneurysms greater than 4 mm compared with 13.5% (10/74) in aneurysms less than 4 mm.¹⁵⁾ These were in agreement with our findings.

Regarding dome projection, Proust et al. have categorized aneurysm projection into anterior/posterior projection of the aneurysm dome with respect to the axis of the pericallosal arteries. Each type is considered to correspond approximately to the inferior and superior projections in the present study. In addition, they described a rate of 75.8% for complete obliteration in the posteriorly orientated aneurysms, compared with 100% in those with the anteriorly directed dome in a prospective study of 37 patients with ACoA aneurysms who underwent endovascular embolization.⁸⁾ As most of the A1 segment of the anterior cerebral artery runs downward, aneurysms with a superior dome projection could lead to poor maneuverability of

the microcatheters. This could make it difficult to properly and safely navigate and stabilize the microcatheters inside the aneurysms because of the sharp curvature of the A1 segment of the anterior cerebral artery towards the inside of the aneurysm. Songsaeng et al. classified the direction of the aneurysm dome in relation to the three axes of the head: cranial, caudal, and medial.⁹⁾ They concluded that the caudal orientation was associated with successful complete obliteration in 96 ACoA aneurysms, and investigated the classification of $< 90^\circ$, $90^\circ - < 160^\circ$, and $160^\circ - 180^\circ$ for the aneurysm angle. They also reported that an angle between 160° and 180° is one of the factors for complete obliteration of ACoA aneurysms.⁹⁾ In contrast, the acute angles could lead to instability inside the aneurysms and poor controllability of the microcatheters. Thus, at the end of the coil embolization, microcatheters readily migrate into the parent arteries leading to incomplete obliteration of the aneurysms.

In the present study, superior dome projection and acute aneurysm angle accounted for a large portion of the true ACoA group. Because each of these two factors plays key roles in the stability of the catheter system, inferior effect of embolization in the true ACoA group could be resulted. Moreover, the higher risk of rupture in small size and acute-angled aneurysm is believed to be due to increased restriction of microcatheter movement within the aneurysm, resulting in greater shear stress within the aneurysm dome.^{15,16)} As a consequence, intraprocedural rupture also could be higher in the true ACoA group.

This study has certain limitations. First, this was a retrospective study. Second, there were relatively few cases of unruptured aneurysms, and cases of medium-large size aneurysms with the neck at the ACoA were not included; therefore, larger studies are warranted in the future.

In conclusion, we revealed the features of an ACoA aneurysm whose neck was located directly at the ACoA that strongly associated with each morphological factors of unsuccessful endovascular therapies.⁶⁻⁹⁾ Consequently, incomplete obliteration and intraprocedural rupture in treating ACoA aneurysms with endovascular embolization are more common in the true ACoA aneurysms.

Conflicts of Interest Disclosure

The authors have no conflicts of interest and have registered online self-reported conflict of interest disclosure statement forms through the website for Japan Neurosurgical Society members.

References

- 1) Yasargil MG: Anterior communicating artery aneurysms, in Yasargil G (ed): *Microneurosurgery, Vol II*. New York, Thieme-Verlag, 1999, pp 169–223
- 2) Molyneux A, Kerr R, Stratton I, Sandercock P, Clarke M, Shrimpton J, Holman R, International Subarachnoid Aneurysm Trial (ISAT) Collaborative Group (2002): International Subarachnoid Aneurysm Trial (ISAT) of neurosurgical clipping versus endovascular coiling in 2143 patients with ruptured intracranial aneurysms: a randomized trial. *Lancet* 360: 1267–1274, 1994
- 3) Bartolini B, Blanc R, Pistocchi S, Redjem H, Piotin M: “Y” and “X” stent-assisted coiling of complex and wide-neck intracranial bifurcation aneurysms. *AJNR Am J Neuroradiol* 35: 2153–2158, 2014
- 4) Guglielmi G, Viñuela F, Duckwiler G, Jahan R, Cotroneo E, Gigli R: Endovascular treatment of 306 anterior communicating artery aneurysms: overall, perioperative results. *J Neurosurg* 110: 874–879, 2009
- 5) Moret J, Pierot L, Boulin A, Castaings L, Rey A: Endovascular treatment of anterior communicating artery aneurysms using Guglielmi detachable coils. *Neuroradiology* 38: 800–805, 1996
- 6) Birknes JK, Hwang SK, Pandey AS, Cockroft K, Dyer AM, Benitez RP, Veznedaroglu E, Rosenwasser RH: Feasibility and limitations of endovascular coil embolization of anterior communicating artery aneurysms: morphological considerations. *Neurosurgery* 59: 43–52; discussion 43–52, 2006
- 7) Gonzalez N, Sedrak M, Martin N, Vinuela F: Impact of anatomic features in the endovascular embolization of 181 anterior communicating artery aneurysms. *Stroke* 39: 2776–2782, 2008
- 8) Proust F, Debono B, Hannequin D, Gerardin E, Clavier E, Langlois O, Fréger P: Treatment of anterior communicating artery aneurysms complementary aspects of microsurgical and endovascular procedures. *J Neurosurg* 99: 3–14, 2003
- 9) Songsaeng D, Geibprasert S, ter Brugge KG, Willinsky R, Tymianski M, Krings T: Impact of individual intracranial arterial aneurysm morphology on initial obliteration and recurrence rates of endovascular treatments: a multivariate analysis. *J Neurosurg* 114: 994–1002, 2011
- 10) Perlmutter D, Rhoton AL: Microsurgical anatomy of the anterior cerebral-anterior communicating-recurrent artery complex. *J Neurosurg* 45: 259–272, 1976
- 11) Yasargil MG: *Microsurgery vol. 1 Operative Anatomy*. Stuttgart, New York, Thieme-Verlag, 1984, pp 92–116
- 12) Ujiie H, Liepsch DW, Goetz M, Yamaguchi R, Yonetani H, Takakura K: Hemodynamic study of the anterior communicating artery. *Stroke* 27: 2086–2093; discussion 2094, 1996
- 13) Oishi H, Yamamoto M, Shimizu T, Yoshida K, Arai H: Endovascular therapy of 500 small asymptomatic unruptured intracranial aneurysms. *AJNR Am J Neuroradiol* 33: 958–964, 2012
- 14) Pierot L, Spelle L, Vitry F; ATENA Investigators: Immediate clinical outcome of patients harboring unruptured intracranial aneurysms treated by endovascular approach: results of the ATENA study. *Stroke* 39: 2497–2504, 2008
- 15) Schuette AJ, Hui FK, Spiotta AM, Obuchowski NA, Gupta R, Moskowitz SI, Tong FC, Dion JE, Cawley CM: Endovascular therapy of very small aneurysms of the anterior communicating artery: five-fold increased incidence of rupture. *Neurosurgery* 68: 731–737; discussion 737, 2011
- 16) Sluzewski M, Bosch JA, van Rooij WJ, Nijssen PC, Wijnalda D: Rupture of intracranial aneurysms during treatment with Guglielmi detachable coils: incidence, outcome, and risk factors. *J Neurosurg* 94: 238–240, 2001

Address reprint requests to: Hidemichi Ito, MD, Department of Neurosurgery, St. Marianna University School of Medicine, 2-16-1 Sugao, Miyamae, Kawasaki-shi, Kanagawa 216-8511, Japan.
e-mail: hdmcito@marianna-u.ac.jp