

A novel technique for extraction of a leadless pacemaker that embolized to the pulmonary artery in a young patient: A case report



Sanjaya Gupta, MD, FHRS,* Ken Cho, MD,[†] John Papagiannis, MD, FHRS,*[‡]
Svjetlana Tisma-Dupanovic, MD, FHRS,*[‡] John Borsa, MD^{†§}

From the *Division of Cardiology, Saint Luke's Mid-America Heart Institute, Kansas City, Missouri, [†]Department of Radiology, Saint Luke's Hospital of Kansas City, Kansas City, Missouri, [‡]Division of Cardiology, Children's Mercy Hospital, Kansas City, Missouri, and [§]Department of Radiology, University of Missouri Kansas City, Kansas City, Missouri.

Introduction

The advent of leadless pacemakers facilitated right ventricular pacing while avoiding short-term risks of pneumothorax and surgical site infection and long-term risk of vascular stenosis.¹ Until recently, the only available pacing mode on a leadless pacemaker was VVI, which limited its usage to patients with permanent atrial fibrillation with bradycardia, patients requiring only intermittent backup ventricular pacing, and patients with vascular access issues that prohibit traditional pacemaker implantation. The Micra AV (Medtronic PLC, Dublin, Ireland) leadless cardiac pacemaker was recently FDA approved and allows for atrial sensed-ventricular paced applications, which have broadened potential usage to include patients in sinus rhythm with symptomatic second- and third-degree heart block.² The Micra leadless pacemaker is delivered via a 23F deflectable sheath inserted typically from the right groin. The device is attached to the myocardium by nitinol tines and is typically placed in a location on the right ventricular septum or apex. In a recently published series of long-term follow-up of Micra pacemakers, the rate of major complications was 1.51% and 1 device dislodgement without embolization was reported.³ We hereby describe a novel technique for retrieval of a dislodged Micra AV device, which occurred in the first pediatric patient implanted with such a device, at the time of publication (Medtronic Inc, personal communication).

KEYWORDS Atrioventricular synchrony; Congenital heart block; Device embolization; Leadless pacemaker; Large sheath/double snare technique; Surgical site infection
(Heart Rhythm Case Reports 2020;6:724–728)

The authors report the following financial conflicts of interest: Dr Gupta receives modest research grant support from Medtronic, Abbott, and Bristol Myers Squibb and consults for Boston Scientific and Respicardia. None of these conflicts are relevant to this manuscript. **Address reprint requests and correspondence:** Dr Sanjaya Gupta, Saint Luke's Mid-America Heart Institute, 9th Floor – Cardiovascular Research, 4400 Wornall Rd, Kansas City, MO 64111. E-mail address: sgupta@saint-lukes.org.

Case report

A 15-year-old male patient with a history of congenital second- and third-degree heart block underwent dual-chamber pacemaker placement in 2017 from a left axillary vein approach at the age of 13. Although the procedure was uncomplicated, he developed a left-sided surgical site infection 9 months later that grew *Staphylococcus hominis*, *Staphylococcus epidermidis*, and *Micrococcus luteus*. He underwent left-sided device and lead extraction and completed a prolonged course of intravenous antibiotic therapy before undergoing a right-sided dual-chamber pacemaker implantation in September 2018. Given his history of surgical site infection, this pacemaker was implanted with an antimicrobial pouch (TYRX Absorbable Antibacterial Envelope; Medtronic PLC, Dublin, Ireland), and parenteral antibiotics were given both pre and post device placement and oral doxycycline was given for 6 months post implantation. Although this procedure was uncomplicated, he developed another surgical site infection in January 2020 and underwent device and lead extraction. Both wound and blood cultures were positive for *Streptococcus pyogenes*. The patient received a prolonged course of antibiotic therapy with vancomycin initially and then ceftriaxone. During his 3-week course of antibiotic therapy, he continued to have intermittent symptomatic second- and third-degree heart block but did not require temporary transvenous pacing. His previously implanted pacemaker had a 91.2% ventricular pacing rate (in AS-VP mode), which confirmed that he would likely need his pacemaker replaced. Given his history of recurrent device infections occurring at times remote from initial implantation and despite extensive measures to prevent infection, various treatment options were considered, including submuscular implant. The Micra AV leadless pacemaker had recently been approved and became commercially available the week that device reimplantation was being considered. Although leadless pacing is traditionally not considered in patients this young, given his history of recurrent device infections despite extensive anti-infective measures, it was

KEY TEACHING POINTS

- Recurrent surgical site infections separated in time from the original implant suggest alternate methods of pacing should be considered.
- Use of a large-bore, long sheath to retrieve an embolized device in the pulmonary artery provides proximity and support as well as allows safe passage through the heart without injuring adjacent structures.
- Use of a 2-snare technique at the distal and proximal ends of an embolized leadless pacemaker facilitates retraction of the tines and distal control of the device while the proximal snare is used to retract the device.

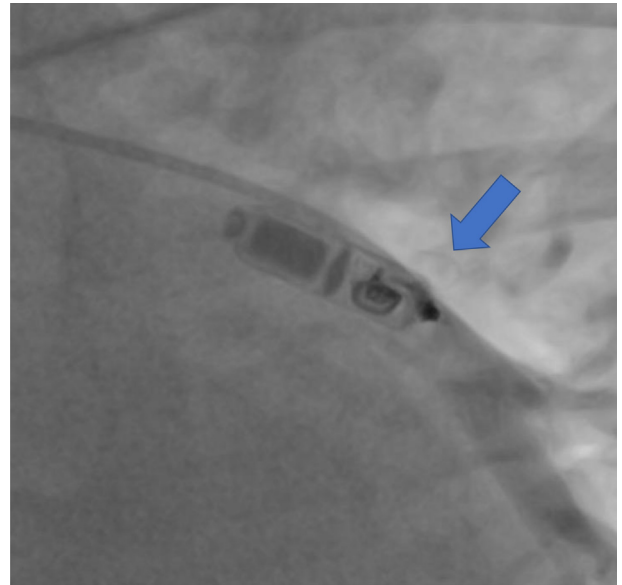


Figure 1 Initial angiogram demonstrating leadless pacemaker lodged in interlobar branch of pulmonary artery with tine penetrating vessel wall (*arrow*) without extravasation of contrast.

felt that the Micra AV leadless pacemaker was the best option for him.

The patient underwent placement of a Micra AV pacemaker via transcatheter placement from the right groin. After contrast injection was performed through the catheter to visualize the right ventricle, a location was chosen on the distal right ventricular septum. The pull and hold test confirmed that 3 out of the 4 tines were fully attached to the ventricular myocardium. The engagement of the 3 tines was confirmed with 2 cardiac electrophysiologists, 1 of whom had extensive experience with leadless pacemaker implantation. The device had sensed R waves of 13.5 mV, a pacing impedance of 500 ohms and pacing threshold of 0.5 V @ 0.24 ms. The following day, the device check revealed that the sensing had decreased to 10.0 mV, the impedance was stable at 500 ohms, and the pacing threshold increased to 3.75 V at 1.0 ms. A chest radiograph as well as echocardiogram both confirmed that the leadless pacemaker was attached to the ventricular septum but its position had shifted slightly from the original implant position.

Subsequently, the patient returned to the electrophysiology laboratory for planned repeat Micra AV device placement and retrieval of the original Micra AV via snare. Immediately prior to the procedure, the device was interrogated and there was lack of capture of ventricular myocardium at any output. Fluoroscopy confirmed that the original Micra AV had migrated to the left pulmonary artery. A second Micra AV was placed on the mid-ventricular septum following a contrast injection. Once again, a pull and hold test demonstrated that 3 out of 4 tines were engaged with the ventricular myocardium. Acutely, the sensing was 12.6 mV, the impedance was 630 ohms, and the pacing threshold was 0.5 V at 0.24 ms. After deployment of the second Micra AV, the Micra sheath was advanced to the distal right ventricular outflow tract; however, the original Micra AV had migrated to the left pulmonary artery and was

beyond the reach of the Micra sheath. Several attempts were made to retrieve the dislodged Micra AV via snare, but these were not successful owing to a very distal position of the device and difficulty in directing the snare to the vessel of interest without proximal support. The decision was made to abandon further attempts at retrieval at that time and consider alternative options.

A computed tomography scan of the chest confirmed that the original Micra AV had embolized to the interlobar branch of the left pulmonary artery. The patient began to experience chest pain and there was concern for possible thrombus formation around the device. A repeat extraction attempt was planned with the assistance of interventional radiology 2 days after the initial extraction attempt to accommodate the complex scheduling needs of a coordinated effort.

The patient was placed under general anesthesia and intubated with a double-lumen endotracheal tube. A full cardiac surgical team was on backup with a cardiac surgeon present in the room during the procedure. Access to the right common femoral vein was obtained via ultrasound guidance and use of a 5F Micro-Introducer kit (Vascular Solutions, Minneapolis, MN), with subsequent placement of a 0.035" guidewire (Cook, Bloomington, IN) followed by a 7F vascular sheath (Cordis, Santa Clara, CA). The vein was then preclosed using 2 Perclose devices (Abbott Vascular, Santa Clara, CA). A 90-degree 6F Pigtail Soft-Vu catheter (Angiodynamics, Queensbury, NY) was then used to navigate through the right atrium to the right ventricle and then to the main pulmonary artery without dislodging the ventricular Micra AV. Once the Pigtail catheter was in place, a 260-cm-length, 1 cm floppy Amplatz Super Stiff 0.035" guidewire (Boston Scientific, Marlborough, MA) was placed through the catheter into a branch of the left pulmonary artery. The Pigtail catheter was subsequently removed and a

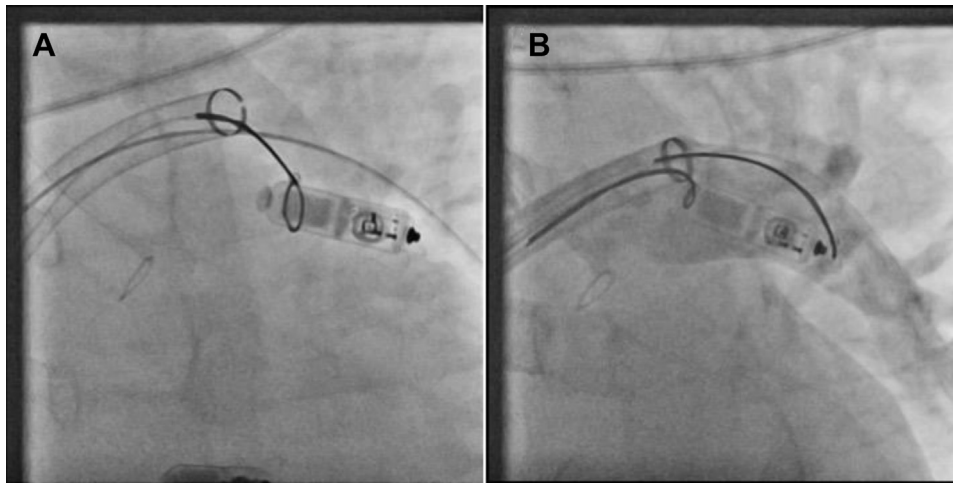


Figure 2 **A:** Initial retrieval with single snare that was unsuccessful owing to persistent engagement of tines in vessel wall. The Amplatz Super Stiff wire (Boston Scientific, Marlborough, MA) is located in an adjacent interlobar branch of the pulmonary artery to help stabilize the sheath. **B:** Double-snare technique with distal and proximal snare attachment. By cinching down the distal snare at the base of the tines, it retracts these tines from the vessel wall and enables distal control of the device while the proximal snare is used to retract the device. Contrast injection demonstrates the tines are free from the vessel wall and there is no extravasation of contrast.

tapered dilator was used to dilate the common femoral vein before a 24F Gore Dry-Seal sheath (Gore Medical, Flagstaff, AZ) was placed over the wire to the inferior vena cava. Systemic anticoagulation with intravenous heparin was then given via bolus. Next, a T24 Flowtriever sheath (Inari Medical, Irvine, CA) was placed over the wire into the left main pulmonary artery. This sheath, which is traditionally used to perform aspiration thrombectomy of pulmonary emboli, has the appropriate length and flexibility to reach the interlobar branch of the pulmonary artery and was confirmed prior

to the case to have adequate diameter to retrieve the Micra AV leadless pacemaker.

After the Amplatz guidewire was placed into an adjacent branch of the pulmonary artery to maintain access, a contrast injection under cine fluoroscopy was performed to confirm the location of the device in relation to the pulmonary arterial anatomy. It was noted that 1 of the device tines was in an extravascular location; however, there was no extravasation of contrast at baseline (Figure 1). A 20mm goose-neck 6F snare (Medtronic PLC, Dublin, Ireland) was used in attempts

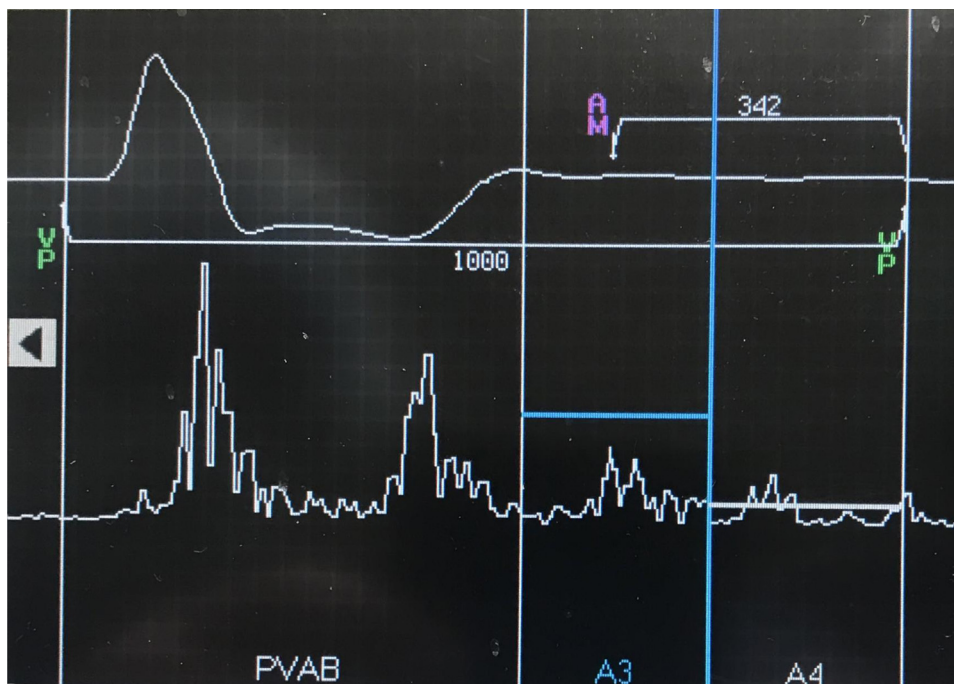


Figure 3 Manual atrial mechanical test post implant demonstrating post-ventricular atrial blanking (PAVB) period; A3 period, which corresponds to a sensed atrial mechanical event (AM); and then ventricular pacing (VP) following the A4 period.

to retrieve the Micra AV. With difficulty, the snare was successfully placed around the body of the pacemaker, but the device could not be removed with gentle manual traction applied to the body of the pacemaker, despite several attempts (Figure 2a). Since the distal tip of the device and tines were lodged into the distal aspect of the interlobar branch, it was not possible to grab the tines directly or turn the device.

The 20mm goose-neck snare was then advanced over the body of the device and secured at the distal tip of the device at the base of the tines. A second 20mm goose-neck snare was then advanced via the T24 Flowtriever over the body of the device and then slowly withdrawn while the snare was tightened to secure it at the proximal aspect of the Micra AV (Figure 2b). The distal snare was then tightened further, which retracted the tines from the wall of the vessel. Both proximal and distal snares were then used together to retract the device and pull it into the main body of the pulmonary artery. The Amplatz wire was withdrawn and then the Micra AV could be pulled into the T24 Flowtriever sheath and removed from the body. A repeat pulmonary angiogram confirmed that there was no extravasation of contrast outside of the pulmonary vasculature. Protamine was given to reverse anticoagulation in the event of microperforation of a pulmonary vessel that may have occurred. The sheath was removed carefully under fluoroscopy to prevent dislodgement of the second Micra AV. The femoral vein was closed via securing both Perclose sutures. Fluoroscopy confirmed that the second Micra AV was unchanged and a repeat device interrogation showed stable parameters that were unchanged from the beginning of the case. The patient was transferred to recovery and discharged the following day. Post procedure, the patient's chest pain resolved completely. At follow-up, device interrogation confirmed normal pacemaker function and his chest and groin incision healed completely. His device interrogation demonstrated appropriate atrial mechanical sensing and ventricular pacing (Figure 3). At follow-up visit, he made a full recovery and his device check demonstrated he had a total amount of ventricular pacing of 82% in an AS-VP pacing mode.

Discussion

There are several novel aspects of this case that merit discussion. Given the fact that this patient had recurrent surgical site infections at different anatomic locations that were remote from the time of implantation, the decision was made to pursue a leadless pacemaker, which avoids the presence of a subcutaneous device and also allows him the option of atrioventricular synchrony. This is the first reported demonstration of atrioventricular synchrony achieved with a leadless pacemaker in a pediatric patient. The Micra AV has a projected battery longevity of 12 or more years at current programmed outputs, at which time a second Micra AV can be placed or an alternate device will be considered.

It is noteworthy that despite having 3 out of 4 tines engaged and having excellent sensing and pacing thresholds, the original Micra AV leadless pacemaker still completely

dislodged. This is extraordinarily unusual. The septal placement is the most common position for leadless pacemaker placement, and the second Micra AV pacemaker was placed slightly higher on the interventricular septum and has been stable.

This is also the first reported case of the T24 Flowtriever sheath used to retrieve an embolized leadless pacemaker. This sheath has greater length and greater flexibility than currently available cardiac sheaths and allowed the necessary approximation to the location of the embolized device. The use of a 2-snare technique was pivotal to the success of this extraction, as it facilitated atraumatic retraction of the tines from the vessel wall as well as enabled control of both proximal and distal ends of the device to safely and securely pull the device into the sheath. An additional advantage of the T24 Flowtriever sheath was that it had the necessary luminal diameter to remove the device internally and provide safe passage out of the body and avoid having to drag the pacemaker with its exposed tines through the pulmonic valve, right ventricle, and tricuspid valve. Finally, this case highlights the importance of a team-based approach to patient care and through collaboration with interventional radiology, cardiac anesthesiology, cardiac surgery, and pediatric electrophysiology it was possible to achieve a successful outcome for this patient.

There have been other reports of retrieving leadless pacemakers via use of snares. There are reports of devices that dislodged, but remained within the heart, that were extracted using 2 snares with either 1 or 2 deflectable sheaths.⁴⁻⁶ There are other case reports that describe embolization of a leadless pacemaker to the pulmonary artery.^{7,8} However, our case differs from each of these other reports by the description of a single large sheath to retrieve a Micra from a branch of a pulmonary artery using a 2-snare technique to safely retract the distal tines and control both ends of the device.

Conclusion

For patients with recurrent surgical site infections, use of a leadless pacemaker that allows for atrioventricular synchrony is a feasible alternative, even in young patients. In the advent of embolization of a leadless pacemaker to the pulmonary artery, use of a double-snare technique via a large, flexible sheath is an effective method to retrieve the device in a safe manner.

References

1. Reynolds D, Duray GZ, Omar R, et al. A leadless intracardiac transcatheter pacing system. *N Engl J Med* 2016;374:533-541.
2. Steinwender C, Khelae SK, Garweg C, et al. Atrioventricular synchronous pacing using a leadless ventricular pacemaker: Results from the MARVEL 2 Study. *JACC Clin Electrophysiol* 2020;6:94-106.
3. Roberts PR, Clementy N, Al Samadi F, et al. A leadless pacemaker in the real-world setting: The Micra Transcatheter Pacing System Post-Approval Registry. *Heart Rhythm* 2017;14:1375-1379.
4. Fichtner S, Estner HL, Nábauer M, Hausleiter J. Percutaneous extraction of a leadless Micra pacemaker after dislocation: a case report. *Eur Heart J Case Rep*, <https://doi.org/10.1093/ehjcr/ytz113>.

5. Goyal R, Markowitz SM, Ip JE. Double-snare technique for capturing a wandering leadless pacemaker. *JACC Clin Electrophysiol* 2019;5:872–873.
6. Kawaski M, Yamada T, Watanabe T, Furukawa Y, Fukunami M. Extraction of “a floating leadless pacemaker”: A case report. *HeartRhythm Case Rep* 2020; 6:457–459.
7. Sundaram S, Choe W. The one that got away: A leadless pacemaker embolizes to the lungs. *Heart Rhythm* 2016;13:2316.
8. Tam TK, Chan YSJ, Chan CPG, Chan KYA, Chan CY. Leadless pacemaker tether failure during recapture attempt leading to device embolization. *HeartRhythm Case Rep* 2019;5:247–250.