

Case Report

NIPAL4 deletion identified in an American Bully with autosomal recessive congenital ichthyosis and response to topical therapy

Amaury Briand* , Noelle Cochet-Faivre* , Edouard Reyes-Gomez^{†,‡} ,
Ambre Jaraud-Darnault[‡], Laurent Tiret[‡]  and Lucie Chevallier[‡] 

*Department of Parasitology, Mycology, Dermatology, EA 7380 UPEC Dynamyc, Ecole nationale vétérinaire d'Alfort, Maisons-Alfort, France, [†]Anatomical Pathology Unit, BioPôle Alfort, Ecole nationale vétérinaire d'Alfort, Maisons-Alfort, France and [‡]U955 – IMRB, Team 10 - Biology of the neuromuscular system, Inserm, UPEC, Ecole nationale vétérinaire d'Alfort, Maisons-Alfort, France

Abstract

Ichthyoses represent a heterogeneous group of hereditary cornification disorders characterized by generalized scaling of the skin. An autosomal recessive congenital ichthyosis (ARCI) has been described in American Bulldogs and is caused by a variant in the *NIPAL4* gene encoding for the ICHTHYIN protein. So far, this variant has not been described in other breeds. A 1.5-year-old female pedigreed American Bully was referred for generalized scaling and bad coat quality since adoption at 8 weeks of age. Clinical examination, cytological and histopathological examination, and DNA testing were performed. Clinical examination revealed a generalized scaling; cytological evaluation using impression with acetate tapes showed a secondary *Malassezia* dermatitis. Histopathological examination revealed a moderate to marked, diffuse, compact orthokeratotic hyperkeratosis with the formation of large scales. Few *Malassezia* were observed in the *stratum corneum* associated with minimal mixed perivascular inflammation and moderate epidermal hyperplasia. DNA testing of the dog revealed that he carries two defective alleles of the *NIPAL4* gene previously described in the American Bulldog. We performed a commercially available breed detection test which, although not specifically testing for “American Bully” signatures, revealed a high probability of American Bulldog DNA signature within the past three generations. Topical treatment using a combination of keratolytic and keratomodulator shampoo, emollient and moisturizers spray and antimicrobial wipes achieved a marked clinical improvement after only 1 month. Continuous topical treatment was necessary to maintain clinical improvement. To the authors’ knowledge, this is the first description of the deleterious *NIPAL4* variant in an American Bully as well as the first description of clinical management and follow-up of ARCI in this breed.

Keywords: American Bully, Canine dermatology, dog, genetic testing, hereditary disorder, *NIPAL4* variant.

Correspondence: Amaury Briand, Department of Parasitology, Mycology, Dermatology, EA 7380 UPEC Dynamyc, Ecole nationale vétérinaire d'Alfort, Maisons-Alfort, France. E-mail: amaury.briand@vet-alfort.fr

Introduction

Ichthyosis comprises a heterogeneous group of hereditary cornification disorders which provoke generalized scaling of the skin due to defects in cornification and desquamation. Human ichthyoses are classified as either syndromic or nonsyndromic ichthyoses, the latter group subclassified into common ichthyosis, autosomal recessive congenital ichthyosis (ARCI), keratinopathic ichthyoses and

other forms of ichthyoses (Oji *et al.* 2010). In dogs, several forms of ichthyosis have been described and are currently subdivided into epidermolytic and nonepidermolytic based on light microscopy (Credille 2008). Several breed-specific causative variants have been identified such as: *KRT10* in the Norfolk Terrier, causing epidermolytic ichthyosis; *PNPLA1* in the Golden Retriever, *TGMI* in the Jack Russel Terrier, *SLC27A4* in the Great Dane, *ASPRVI* in the German Shepherd and *NIPAL4* in

the American Bulldog causing different forms of nonepidermolytic ichthyosis (Credille *et al.* 2009; Grall *et al.* 2012; Metzger *et al.* 2015; Bauer *et al.* 2017; & Casal *et al.* 2017). Clinically, American Bulldog ichthyosis is described as an ARCI similar to human lamellar ichthyosis or congenital ichthyosiform erythroderma. It is associated with a variant (g.52737379del) affecting the *NIPAL4* gene encoding for the protein ICHTHYIN. The variant consists of the deletion of one base pair yielding a premature stop codon and a truncated and defective ichthyin protein (Casal *et al.* 2017). Currently, the exact mechanism of action of this protein remains elusive; it may function as a magnesium transporter for fatty acid transport protein 4 (FATP4) and may also be associated with transglutaminase 1 and FATP4 in processing lipids to maintain epidermal barrier function. Ichthyosis due to this variant is inherited as an autosomal recessive disorder (Mauldin *et al.* 2015; & Casal *et al.* 2017). Affected American Bulldogs present a dishevelled pelage with generalized soft white scales; the glabrous skin of the abdomen presents a brown discoloration, slight erythema and diffusely adherent light brown scales. These clinical signs tend to worsen at adult age and are often complicated by *Malassezia* overgrowth associated with pruritus (Mauldin *et al.* 2015; & Casal *et al.* 2017). Microscopic skin lesions include diffuse laminated to compact orthokeratotic hyperkeratosis with hypergranulosis and acanthosis. Multifocally, granular layer keratinocytes present perinuclear clear space. In many cases, *Malassezia* can be found within the corneal layer (Mauldin *et al.* 2015). Currently, continuous topical treatment is considered the best option for all types of ichthyosis. Usually, best results are achieved with keratolytic agents, emollient and topical antimicrobial treatment (Mauldin 2013). Only sparse information is available on the treatment and follow-up of dogs with ARCI caused by the *NIPAL4* variant (Mauldin *et al.* 2015; & Casal *et al.* 2017).

Since 2004, a new breed of dog called the American Bully has been recognized initially by the American Bully Kennel Club and later in 2013 by the United Kennel Club in the United States and supposedly results from crossing the American

Staffordshire Terrier and the American Pit Bull Terrier (Levêque & Fontbonne 2017).

Here we report the clinical management and follow-up of an ARCI associated with a variant in the *NIPAL4* gene in an American Bully.

Case report

A 1.5-year-old pedigree female American Bully was referred to the clinics of the Alfort School Veterinary Hospital for generalized scaling and bad coat quality. The dog had been adopted at 8 weeks of age and already presented generalized scaling, dry skin and dishevelled pelage. Initially, large scales had been noted on the back, which progressively extended to the entire body.

At first presentation, the dog exhibited a diffuse and severe scaling with large white scales loosely adherent to the skin or with embedded hair shafts on the dorsum and lateral thighs. Small and large adherent grey scales were present on the muzzle, around the eyes and on the pinna. Small and white scales with erythema and severe xerosis were visible on glabrous skin of the ventrum, axillae and groin. Skin and hair presented a dull and a greasy appearance (Fig. 1a,c,e). Mild pruritus was reported by the owners especially on interdigital spaces, groin and axillae. No other abnormality was noted on physical examination.

Skin impression with acetate tapes from the axillae and the interdigital spaces revealed *Malassezia* in moderate quantity.

Punch skin biopsies were taken from the flank, the interscapular zone and the ventral abdomen. Samples were fixed in 10% buffered formalin and routinely processed. Sections were stained with haematoxylin, eosin and saffron (HES). The main finding was a moderate to marked, diffuse, compact orthokeratotic hyperkeratosis with formation of large scales (Fig. 2a,b). Few *Malassezia sp.* were observed in the *stratum corneum* and associated with minimal mixed perivascular inflammation and minimal epidermal hyperplasia.

History, clinical signs and microscopic findings suggested an ichthyosis associated with *Malassezia* dermatitis. This clinical presentation was highly

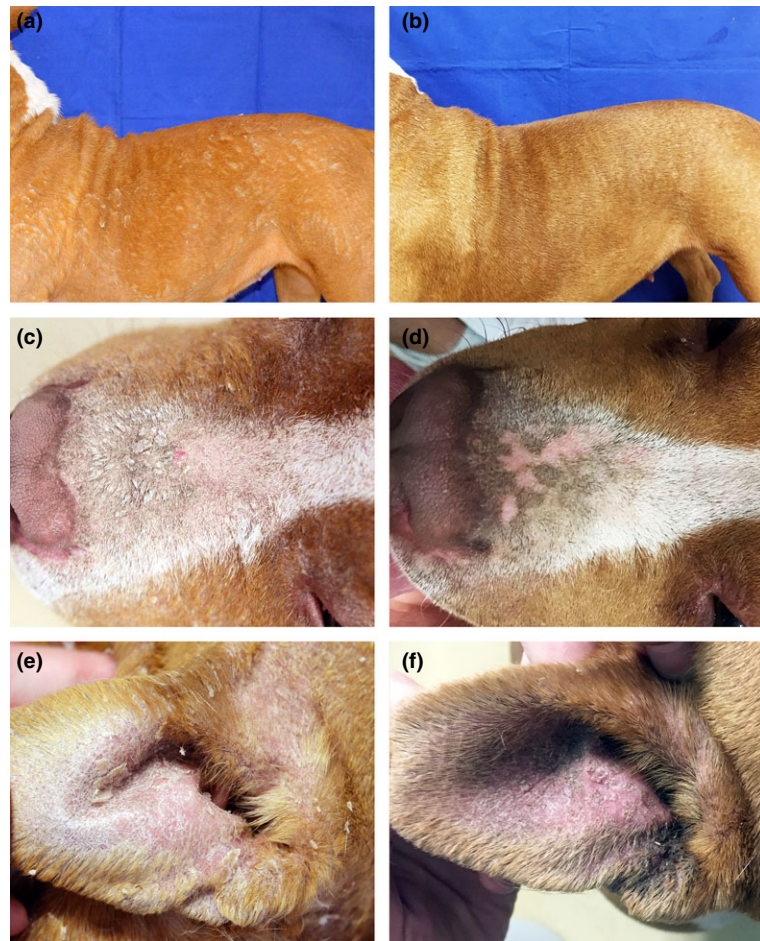


Fig. 1 Clinical aspect at initial presentation (a,c,d) and following 6 months of topical therapy (b,d,e). (a) Severe scaling with large white scales loosely adherent to the skin or with embedded hair shafts on the dorsum and lateral thighs. (b) Marked improvement with only sparse pityriasis-form scaling on the trunk. (c) Small and large adherent grey scales on the muzzle. (d) Marked improvement with only discreet small greasy adherent scales remaining on the muzzle. (e) Large adherent grey scales on the pinna. (f) Improvement with small greasy adherent scales remaining on the pinna.

suggestive of an ARCI variant similar to the American Bulldog form.

Genetic testing for the known *NIPAL4* deletion was performed (PennGen, Philadelphia, PA, USA), which confirmed the dog to be homozygous for this variant. Sampling of the dog's parents or other relatives could not be performed. Because the sire, dam and three littermates were clinically healthy at the day of this report, we hypothesized that both parents were obligate carriers for this autosomal recessive disorder. Analysis of the pedigree provided by the kennel club showed that all the

ancestors of the previous five generations were registered as American Bully. To clarify the breed ancestry of this ichthyosis affected American Bully at the DNA level, we performed a commercially available breed detection test (Wisdom Panel™ canine breed detection test; Wisdom Health™) which, although not specifically testing for “American Bully” signatures, revealed high likelihood matches to American Bulldog DNA ancestry within the past three generations.

Initial treatment consisted of topical treatment reinforcement using keratolytic, antiseborrheic and

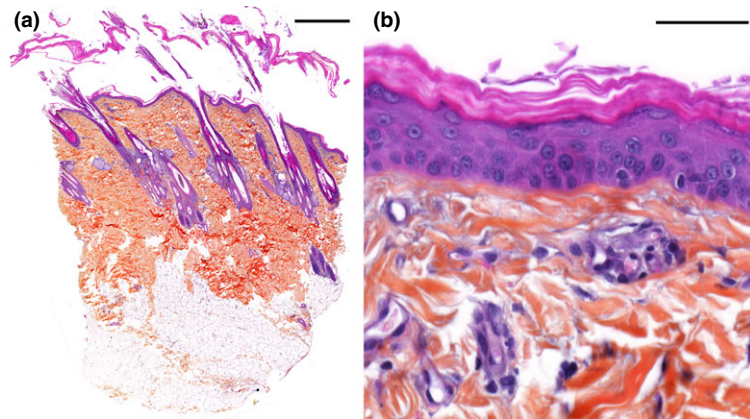


Fig. 2 Skin biopsy; histological lesions at first presentation. (a) Large scales of compact orthokeratotic hyperkeratosis (HES, bar = 1 mm). (b) Laminated compact orthokeratotic hyperkeratosis, minimal epidermis hyperplasia and absence of dermal inflammation (HES, bar = 50 μ m).

emollient shampoo (Zincoseb[®] Shampooing, ICF, Palazzo Pignano, Italy¹) every other day followed by application of emollient spray (Ermidra[®] Spray, ICF, Palazzo Pignano, Italy¹). Glabrous skin was scrubbed every day with chlorhexidine and climbazole containing wipes (CLX[®] Wipes, ICF, Palazzo Pignano, Italy¹) in order to treat *Malassezia* proliferation. After 2 weeks, bathing frequency was decreased to once a week, followed by emollient spray application. Wipe application frequency was also decreased progressively to twice weekly. One month after initiating the treatment, a net improvement of skin lesions was noted with regression of scaling and erythema. A relapse of clinical signs was observed following a decrease in the treatment frequency which lead to a resumption of the initial prescription. Six months after initial presentation, marked improvement was noted with only sparse pityriasiform scaling on the trunk (Fig. 1b). Small greasy adherent scales remained on both pinnae and ears (Fig. 1d,f). One year after the initial presentation and under continuous topical treatment, the dermatological examination remained stable with a very mild erythema compared to the initial presentation and the observation of only a few *Malassezia*.

¹Correction added on 12 April 2019, after first online publication: MP Labo; Grasse, France corrected to ICF, Palazzo Pignano, Italy.

Discussion

To the authors' knowledge, it is the first description showing that the *NIPAL4* variant yielding a truncated protein segregates in the American Bully breed.

The *NIPAL4* variant described in the American Bulldog has not yet been observed in any other breed (Casal *et al.* 2017).

In our case, finding the exact same variant in an American Bully with at least one American Bulldog ancestor strongly suggests that the variant had been acquired through a founder effect and did not arise *de novo*. This statement might seem controversial for American Bully breeders postulating that the Bully originally arose from a crossing of American Staffordshire Terrier with American Pit Bull Terrier founders, but not from American Bulldog (Levêque & Fontbonne 2017). However, traditional breed clubs, which have not recognized the American Bulldog breed, state that interbreeding with American Bulldogs occur frequently.

The ichthyosis form observed in this American Bully is very similar to that observed in the American Bulldog, which suggests that the variant has similar phenotypic effects on these two different genetic backgrounds. Nevertheless, the genetic background of the American Bully may influence treatment success, long-term effects of the disease as well as other aspects of disease progression. Further phenotypic

descriptions of *NIPAL4* mutated American Bully dogs are needed to address this later point.

To the best of our knowledge, this is the first report of ichthyosis due to the deletion in the *NIPAL4* gene in an American Bully. As such, we can hypothesize that the variant frequency is still quite low or restricted to a subpopulation or lineage of American Bully. Genotyping a significant number of American Bullies would be of interest and provide a reliable estimation of the deleterious allele frequency in the *NIPAL4* gene. In addition, comparing haplotypes among variants between American Bulldogs and American Bully dogs would allow the quantification of the number of generations from the putative common ancestor, and thus help clarify this point.

Symptomatic treatment of every form of ichthyosis aims to restore the function of the skin barrier. To date, no treatment allows a complete persistent regression of clinical signs. Continuous treatment is necessary to maintain a regression of clinical signs and relapse is often reported soon after treatment frequency is decreased (Mauldin 2013; & Tamamoto-Mochizuki *et al.* 2016). In the case described, a rapid relapse of clinical signs was observed after decreasing the frequency of topical treatments which confirmed the necessity of continuous treatment. Different treatment options have been described such as oral retinoids, fatty acid supplementation and topical treatments (Mauldin 2013; Miller *et al.* 2013; & Tamamoto-Mochizuki *et al.* 2016). According to one review, topical therapy using keratolytic agents, emollients and topical antimicrobials remains the best option. In the American Bulldog, special care should be taken for secondary fungal skin infection and oral antifungal therapy may be necessary (Mauldin 2013).

In this case, topical treatments alone appeared efficient as clinical improvement was noted after few months. The combination of a shampoo containing keratolytic and keratomodulator components with a spray containing emollient moisturizers and the additional use of antimicrobial wipes yielded an acceptable clinical improvement. It is difficult to assess which component was the most beneficial in this case. Ermidra[®] spray (ICF, Palazzo Pignano, Italy¹) has been shown to restore skin barrier function after

experimentally induced skin barrier defect (Fardouet & Pin 2011). Components such as liposome, glycerol and panthenol participate in the reduction of transepidermal water loss through the restoration of lipid lamellae in the horny layer (Fardouet & Pin 2011). Along with the keratolytic and emollient effect of the shampoo, zinc gluconate in both the shampoo and the spray regulates keratinocytes differentiation and participates in lipid metabolism (Kaufman *et al.* 2014). The wipes used here have been shown to be efficient against *Malassezia* dermatitis, and are interesting in this case where secondary *Malassezia* dermatitis is present (Cavana *et al.* 2015). Other combinations of topical treatments (sometimes combined with oral fatty acid supplementation) have been described such as emollient, moisturizers, essential oil and more recently a combination of gluconolactone and other hydroxyl acids (Tamamoto-Mochizuki *et al.* 2016; & Puigdemont *et al.* 2018). In any case, a combination of different treatments seems to be a good option even if clinical response is never complete and continuous treatment is necessary.

In conclusion, we report the clinical management of an ARCI in an American Bully, carrying two copies of the *NIPAL4* variant previously identified in the American Bulldog. That this form of genetically induced ichthyosis can be found in this breed and that the genetic test currently intended for American Bulldogs is valid in American Bullies is of interest. Availability of this test will enable American Bully breeders to detect carriers among their breeding stock and avoid at risk crosses, providing them with a unique opportunity to get rid of the deleterious allele before its large dissemination within the breeding stock. It would be interesting to evaluate the frequency of this variant in a large transcontinental cohort of healthy American Bullies to get a better insight of *NIPAL4*-associated ichthyosis risk in this breed.

Acknowledgements

The authors acknowledge Prof. Urs Giger (UPenn, USA) for DNA testing and Dr Jonas Donner (Wisdom Panel[™]) for the diversity-based ancestry analysis. We are also grateful to the French Cani-DNA Biological Resources Center.

Sources of funding

This study was self-funded.

Conflicts of interest

No conflicts of interest have been declared.

Ethical statement

The authors confirm that the ethical policies of the journal, as noted on the journal's author guidelines page, have been adhered to. No ethics approval was required as no experimentation was conducted on the treated dog and the consultation was conducted normally.

Contributions

AB supervised the clinical case and follow-up, participate to write and edit the article. NCF participated in the case follow-up and to write and edit the article. ERG histopathological analysis; manuscript writing, review and edition; figure preparation and edition. AJ contributed to extract dog DNA. LT participated to write and edit the manuscript. LC contributed to manage DNA resources for genetic testing and breed heritage analysis and participated to write the manuscript.

References

- Bauer A., Waluk D.P., Galichet A., Timm K., Jagannathan V., Sayar B.S. *et al.* (2017) A de novo variant in the *ASPRVI* gene in a dog with ichthyosis. *PLoS Genetics* **13**, e1006651.
- Casal M.L., Wang P., Mauldin E.A., Lin G., Henthorn P.S. (2017) A Defect in *NIPAL4* is associated with autosomal recessive congenital ichthyosis in american bulldogs. *PLoS ONE* **12**, e0170708.
- Cavana P., Peano A., Petit J.Y., Tizzani P., Perrot S., Ben-signor E., Guillot J. (2015) A pilot study of the efficacy of wipes containing chlorhexidine 0.3%, climbazole 0.5% and Tris-EDTA to reduce *Malassezia pachydermatis* populations on canine skin. *Veterinary Dermatology* **26**, 278–e61.
- Credille K.M. (2008) Primary cornification defects. In: *A Practical Guide to Canine Dermatology* (eds E. Guaguère, P. Prélaud). Merial: Lyon.
- Credille K.M., Minor J.S., Barnhart K.F., Lee E., Cox M.L., Tucker K.A. *et al.* (2009) Transglutaminase 1-deficient recessive lamellar ichthyosis associated with a *LINE-1* insertion in Jack Russell terrier dogs. *British Journal of Dermatology* **161**, 265–272.
- Fardouet L., Pin D. (2011) Etude de l'efficacité du spray hydratant ERMIDRA® sur la réparation de la fonction barrière de la peau dans un modèle expérimental de rupture chronique de la barrière cutanée. [s.n.], S.I., Université Claude Bernard (Lyon), VetAgro Sup.
- Grall A., Guaguère E., Planchais S., Grond S., Bourrat E., Hausser I. *et al.* (2012) *PNPLA1* mutations cause autosomal recessive congenital ichthyosis in golden retriever dogs and humans. *Nature Genetics* **44**, 140–147.
- Kaufman K.L., Mann F.A., Kim D.Y., Lee S., Yoon H.Y. (2014) Evaluation of the effects of topical zinc gluconate in wound healing. *Veterinary Surgery* **43**, 972–982.
- Levêque A., Fontbonne A. (2017) La reproduction des terriers de type Bull et de l'American Bully : étude des dossiers des chiens suivis au Centre d'Etude en Reproduction Canine de l'Ecole Nationale Vétérinaire d'Alfort (CERCA) entre 2010 et 2016.
- Mauldin E.A. (2013) Canine ichthyosis and related disorders of cornification in small animals. *The Veterinary Clinics of North America Small Animal Practice* **43**, 89–97.
- Mauldin E.A., Wang P., Evans E., Cantner C.A., Ferracane J.D., Credille K.M. *et al.* (2015) Autosomal recessive congenital ichthyosis in american bulldogs is associated with *NIPAL4* (ICHTHYIN) deficiency. *Veterinary Pathology* **52**, 654–662.
- Metzger J., Wöhlke A., Mischke R., Hoffmann A., Hewicker-Trautwein M., Küch E.M. *et al.* (2015) A novel *SLC27A4* splice acceptor site mutation in great danes with ichthyosis. *PLoS ONE* **10**, e0141514.
- Miller W.H., Griffin C.E. & Campbell K.L. (2013) Ichthyosis. In: *Muller & Kirk's Small Animal Dermatology*. 7th edn, 577–579. (eds W.H. Miller, C.E. Griffin & K.L. Campbell), Elsevier: St Louis.
- Oji V., Tadani G., Akiyama M., Bardon C.B., Bodemer C., Bourrat E. *et al.* (2010) Revised nomenclature and classification of inherited ichthyoses: results of the first ichthyosis consensus conference in Sorèze 2009. *Journal of the American Academy of Dermatology* **63**, 607–641.
- Puigdemont A., Furiani N., Lucia M.D., Carrasco I., Ordeix L., Fondevila D. *et al.* (2018) Topical polyhydroxy acid treatment for autosomal recessive congenital ichthyosis in the golden retriever: a prospective pilot study. *Veterinary Dermatology*. **29**(4), 323–e113.
- Tamamoto-Mochizuki C., Banovic F., Bizikova P., Laprais A., Linder K.E., Olivry T. (2016) Autosomal recessive congenital ichthyosis due to *PNPLA1* mutation in a golden retriever-poodle cross-bred dog and the effect of topical therapy. *Veterinary Dermatology* **27**, 306–e75.