

**Received:** 2012.07.15  
**Accepted:** 2012.08.29  
**Published:** 2012.09.18

## A case of emphysematous cystitis complicated with miliary tuberculosis

**Hideo Soga<sup>1</sup>, Osamu Imanishi<sup>2</sup>**

<sup>1</sup> Department of Urology, Hyogo Prefectural AWAJI Hospital, Shimokamo, Sumoto, Hyogo, Japan

<sup>2</sup> Imanishi Urological Clinic, Iwayakitamachi, Nada-ku, Kobe, Hyogo, Japan

### Summary

**Background:**

Emphysematous cystitis occurs mostly in diabetics with poor glycemic control or in immunocompromised patients. In most cases, diabetes mellitus correlates with the occurrence of emphysematous cystitis. The risk of relapse after tuberculosis cure or treatment completion is high among patients with diabetes mellitus.

**Case Report:**

A 64-year-old diabetic man suffering from high fever and lower abdominal pain was admitted to the emergency ward. Due to the results of radiographic examinations, he was diagnosed with an emphysematous cystitis. Although the emphysematous cystitis improved with urinary drainage and antibiotic therapy, the high fever recurred and respiratory symptoms appeared. This patient was diagnosed with a crisis of the pulmonary tuberculosis. He was started on the antituberculosis therapy, and he recovered.

**Conclusions:**

This is the first report of a case of emphysematous cystitis that was complicated with pulmonary tuberculosis.

**key words:**

**emphysematous cystitis • pulmonary tuberculosis**

**Full-text PDF:**

<http://www.amjcaserep.com/fulltxt.php?ICID=883449>

**Word count:**

1177

**Tables:**

–

**Figures:**

3

**References:**

15

**Author's address:**

Hideo Soga, Department of Urology, Hyogo prefectural AWAJI Hospital, 1-6-6, Shimokamo, Sumoto, Hyogo, Japan, e-mail: uro-hideo@pop11.odn.ne.jp

## BACKGROUND

Emphysematous cystitis (EC) is a rare urinary tract infection that results in the production of gas by bacteria and that occurs mostly in diabetics with poor glycemic control or in immunocompromised patients [1,2]. Diabetes mellitus (DM) is a metabolic disorder that weakens the immune system. According to the recent systematic reviews, DM was associated with a 3.11-fold increased risk of tuberculosis (TB) in the cohort studies [3]. Furthermore, the random effects pooled relative risk was 3.89 for relapse after TB cure or treatment completion among patients with DM versus those without DM [4]. Thus, DM has been reported to be positively associated with TB. *Mycobacterium tuberculosis*, which is one of the most important pathogens in compromised hosts, is responsible for TB, which annually affects 8 to 9 million people worldwide and accounts for approximately 2 to 3 million deaths each year [5]. In Japan, the number of new cases is above 20,000/year [6]. We describe a case of EC that was complicated with pulmonary TB.

## CASE REPORT

A 64-year-old Japanese man presented to our hospital with a 2-week history of high fever and difficulty in micturination. Before the visit, the patient has been diagnosed with pharyngitis and had been administered antibiotics (Levofloxacin) at another clinic. At the first visit, urinary retention was revealed with lower abdominal pain. His past medical history included DM and a brain infarction. Laboratory data revealed a white blood cell count of 6400, a hemoglobin level of 12.0 g/dL, a hematocrit of 36.0%, a platelet count of  $26.9 \times 10^4$ , a serum glucose level of 525 mg/dL, a HbA1c level of 7.3%, and a C-reactive protein (CRP) concentration of 12.0 mg/dL. A urine culture yielded *Escherichia coli* ( $10^8$  CFU/mL). An abdominal radiography showed an accumulation of gas in the urinary bladder wall and lumen (Figure 1A). An abdominal computed tomography (CT) demonstrated bilateral hydronephrosis, air-fluid levels in the urinary bladder, and gas accumulation in the urinary bladder wall (Figure 1B).

According to these radiographic examinations, this patient was diagnosed with EC, and antibiotics (Meropenem Hydrochloride; 1.0 g/day) were started. The glucose levels were regulated with insulin. Continuous urinary drainage with a urethral catheter improved the upper urinary

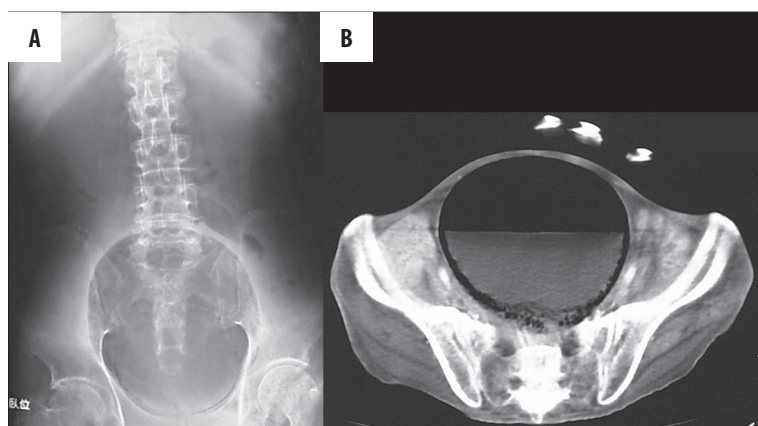
tract obstruction. Furthermore, a characteristic accumulation of air in the urinary bladder wall obviously decreased. Although the fever went down within four days, it increased again with an exacerbation of respiratory symptoms, including cough, sputum, and difficulty in breathing. Although the white blood cell count did not increase, the CRP concentration increased (Figure 2). Antibiotics were administered for another week because aspiration pneumonia was suspected from the results of a chest CT scan (Figure 3A). However, the patient's condition did not improve. Finally the patient was diagnosed with a crisis of pulmonary TB after positive results of a TB polymerase chain reaction examination of the sputum were obtained and from the radiographic findings of the reexamined chest CT scan (Figure 3B). The patient received anti-TB therapy for two months, and he left the hospital in an improved condition.

## DISCUSSION

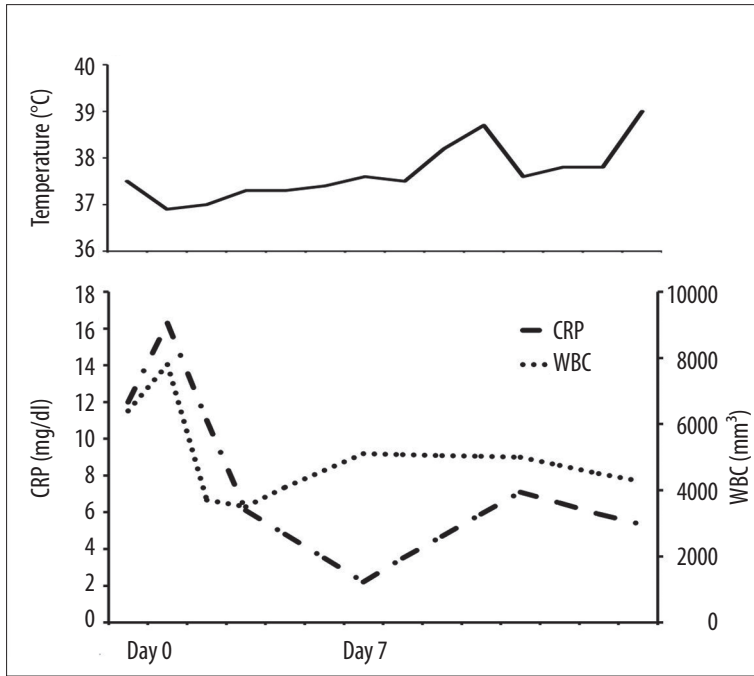
EC is a rare cystitis in which bacteria produce gas in the urinary bladder wall and lumen. The most commonly reported etiologic microorganism is *Escherichia coli*, and other causative organisms include *Klebsiella pneumoniae* or a mixture of *Escherichia coli* and *Klebsiella pneumoniae*. In addition, other reported causative organisms include *Enterobacter aerogenes*, *Staphylococcus aureus*, *Proteus mirabilis*, *Nocardia*, *Clostridium perfringens*, *Candida albicans*, *Candida tropicalis*, and fungus [1,7]. However, EC does not invariably arise by the isolated bacteria.

Most of the cases are accompanied by DM, showing that uric glucose is relevant to this infection [1]. However, some researchers have noted that albumin was more important factor than glucosuria for gas production [8]. Bacterial fermentation of glucose or albumin creates carbon dioxide gas bubbles, which collect in the submucosa or lumen of the bladder [9]. The risk factors of this disease include (i) advanced age, (ii) female gender, (iii) DM, (iv) neurogenic bladder, (v) urethral catheter placement, (vi) a vesicorectal fistula, (vii) end-stage renal disease, and (viii) outlet obstruction [10]. In the present case, the laboratory tests revealed that HbA1c was 7.3% with a serum glucose level of 525 mg/dL at the first visit. According to the medical history, both the DM and the brain infarction might have been the cause of the urinary disorder.

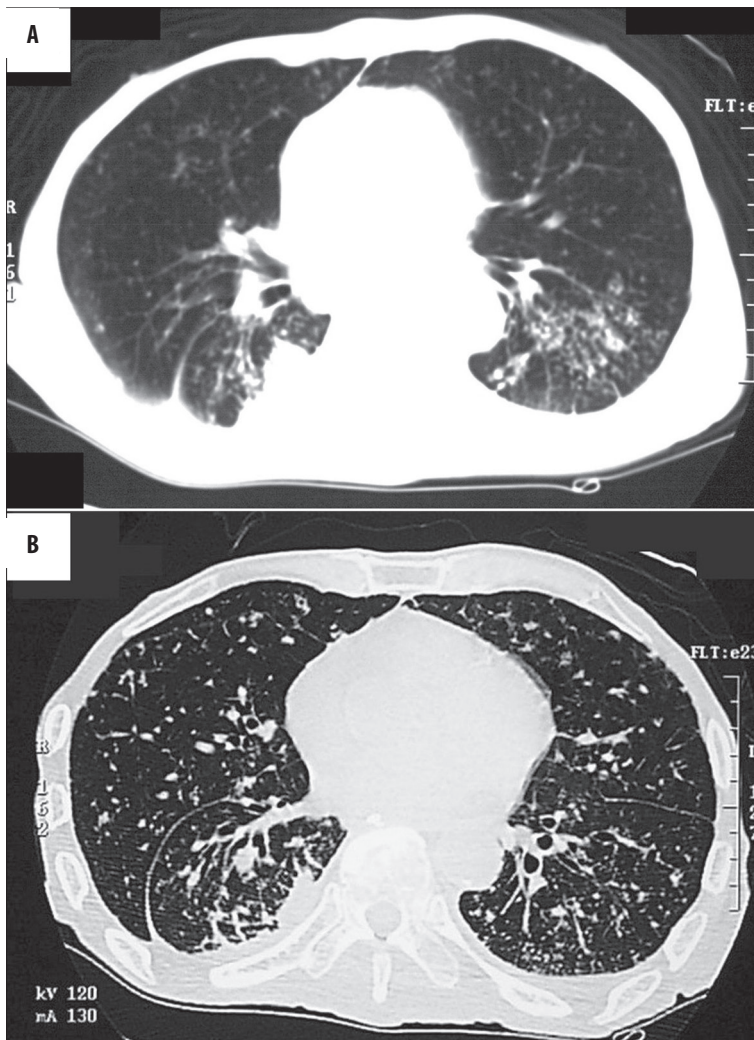
Early diagnosis and the prompt start of the primary treatment with broad-spectrum antibiotics is the key to successful



**Figure 1.** (A) X-ray of the abdomen revealed an area of increased radiolucency within the pelvis, representing air in the expected location of the urinary bladder. (B) CT scan of the pelvis revealing gas accumulation in the wall and lumen of the urinary bladder.



**Figure 2.** Clinical course after admission.



**Figure 3.** CT scan of the chest; (A) At one week after the initiation of the treatment, a CT scan shows parenchymal consolidation in the posterior segment of right upper lobe, and pleural effusion. (B) At two weeks after the initiation of the treatment, a CT scan shows bilateral small parenchymal consolidation with cavitations and small nodules. The crisis of the pulmonary tuberculosis was diagnosed.

therapy. The methods of diagnosis include plain X-ray films of the abdomen, abdominal CT, cysto-urethroscopy, and bladder ultrasonography [1]. However, CT is a highly sensitive examination tool that allows for the early detection of intraluminal or intramural gas [11]. In most cases, EC therapy requires a prolonged course of antibiotics (3 to 6 weeks) with broad-spectrum antibiotics [12]. According to a suggested algorithm shown in a systematic review by Mokabberi R and Ravakhah K [13], antibiotic treatment alone for 1–2 days is recommended for the initiation of the treatment. However, particularly in patients with urinary retention or neurogenic bladder, continuous catheter drainage is effective [9]. In DM patients, prompt blood sugar control is inevitable. Patients suffering from EC who are not responding to medical therapy or those with severe necrotizing infections might require a partial cystectomy, a cystectomy, or surgical debridement [14,15].

The incidence of pulmonary TB has been reported to be higher in diabetics patients than in non-diabetic patients. According to a recent systematic review, DM was associated with a 3.11-fold increased risk of TB in cohort studies [3]. Furthermore, the random effects pooled relative risk was 3.89 for relapse after TB cure or treatment completion among patients with DM versus those without DM, suggesting that DM increases the risk of the combined outcome of relapse [4]. EC is an uncommon infection that occurs mostly in diabetics and immunocompromised patients. In the review of 53 reported cases by Grupper et al, DM was present in 33 (62.2%) of the patients and 12 (22.6%) had documented immunosuppressive comorbidities [2]. In the present case, the antibiotics (Levofloxacin) that were started at another clinic might have covered the respiratory symptoms of pulmonary TB. Although the influence of TB on the EC was not clear, the present case had exhibited an immunosuppressive status since the miliary TB had occurred during the treatment. The present case had some risk factors for EC, which were DM, neurogenic bladder, and an immunosuppressive status. However, which of the above-mentioned risk factors had affected the EC the most was uncertain.

## CONCLUSIONS

To the best knowledge this is the first report of a case of EC that was complicated with pulmonary TB and that responded successfully to conservative treatment. EC is the

most common diagnosis when there is gas within the wall of the bladder. In most cases, DM correlates with the occurrence of EC. Furthermore, these patients might be in an immunosuppressive status. The risk of relapse after TB cure or treatment completion is high among patients with DM. This case report suggested that we should pay more attention to patients with EC who have respiratory symptoms and look for a possible relapse of TB.

## REFERENCES:

1. Thomas AA, Lane BR, Thomas AZ et al: Emphysematous cystitis: a review of 135 cases. *BJU Int*, 2007; 100: 17–20
2. Grupper M, Kravtsov A, Potasman I: Emphysematous cystitis: illustrative case report and review of the literature. *Medicine (Baltimore)*, 2007; 86: 47–53
3. Jeon CY, Murray MB: Diabetes mellitus increases the risk of active tuberculosis: a systematic review of 13 observational studies. *PLoS Med*, 2008; 5: e152
4. Baker MA, Harries AD, Jeon CY et al: The impact of diabetes on tuberculosis treatment outcomes: a systematic review. *BMC Med*, 2011; 9: 81
5. Teixeira HC, Abramo C, Munk ME: Immunological diagnosis of tuberculosis: problems and strategies for success. *J Bras Pneumol*, 2007; 33: 323–34
6. Tuberculosis-Surveillance-Center. Tuberculosis Annual Report 2008 – Series 1. Summary of TB notification statistics in 2008. *Kekkaku*, 2009; 84: 693–96
7. Greene MH. Emphysematous cystitis due to *Clostridium perfringens* and *Candida albicans* in two patients with hematologic malignant conditions. *Cancer*, 1992; 70: 2658–63
8. Hawtrey CE, Williams JJ, Schmidt JD: Cystitis emphysematosa. *Urology*, 1974; 3: 612–14
9. Quint HJ, Drach GW, Rappaport WD, Hoffmann CJ: Emphysematous cystitis: a review of the spectrum of disease. *J Urol*, 1992; 147: 134–37
10. Karashima E, Ejima J, Nakamura H et al: Emphysematous cystitis with venous bubbles. *Intern Med*, 2005; 44: 590–92
11. Grayson DE, Abbott RM, Levy AD, Sherman PM: Emphysematous infections of the abdomen and pelvis: a pictorial review. *Radiographics*, 2002; 22: 543–61
12. Kumar A, Turney JH, Brownjohn AM, McMahon MJ: Unusual bacterial infections of the urinary tract in diabetic patients – rare but frequently lethal. *Nephrol Dial Transplant*, 2001; 16: 1062–65
13. Mokabberi R, Ravakhah K: Emphysematous urinary tract infections: diagnosis, treatment and survival (case review series). *Am J Med Sci*, 2007; 333: 111–16
14. Tanaka K, Takenaka A, Kusuda Y et al: [A case report of a patient with emphysematous cystitis who was cured by early cystectomy under a life threatening condition]. *Hinyokika kyo*, 2002; 48: 741–44
15. Kuo CY, Lin CY, Chen TC et al: Clinical features and prognostic factors of emphysematous urinary tract infection. *J Microbiol Immunol Infect*, 2009; 42: 393–400