



Load-Bearing Shifts in Laminae and Ligament Morphology: Comparing Spinal Canal Dimensions Using Supine versus Upright Lumbar MRI in Adults without Back Pain

Niladri Kumar Mahato¹

¹Department of Biomedical Sciences, Ohio University, Athens, Ohio, United States

Address for correspondence Niladri Kumar Mahato, MBBS, MS, DNB, PhD, Department of Biomedical Sciences, Ohio University, Athens, OH 45701, United States (e-mail: nm620511@ohio.edu).

Indian J Radiol Imaging 2023;33:344–350.

Abstract

Purpose The effects of weight bearing on lumbar spinal canal dimensions are not well reported in the low back pain (LBP) literature. Since axial loading induces changes in anatomical configuration of the lumbar spine, supine spine imaging may not uncover dimensional changes associated with physiological weight bearing that could be demonstrated in imaging in the upright position.

Methods This study compared anteroposterior spinal canal dimensions measured at the level of the intervertebral discs in the supine and upright lumbar spine magnetic resonance images in adults without a history or current back pain. Additionally, interlaminar distances were measured between the centers of adjacent laminae involving a spinal segment. These parameters were utilized to ascertain the deformation incurred at the ligamentum flavum due to load bearing.

Results Within and between-sessions *t*-tests, factorial and repeated-measures analysis of variance showed significant alterations in canal dimensions at certain levels, secondary to the upright positioning of the spine. Measurement reliability assessed between sessions and scanning positions using intraclass correlation coefficients demonstrated strong agreement.

Conclusion Imaging studies involving physiological weight bearing may be useful to understand the potential etiological effects of such changes in mechanical LBP.

Keywords

- ▶ intervertebral
- ▶ ligamentum flavum
- ▶ low back pain
- ▶ MRI
- ▶ lumbar stenosis
- ▶ weight bearing

Introduction

Routine magnetic resonance imaging (MRI) utilized to diagnose low back pain (LBP) and segmental instability is acquired in the supine position. More recently upright MRIs have been applied for clinical diagnosis and for experimental imaging to study spine mechanics.^{1–6} The results comparing these two (supine versus upright) imaging approaches have reported quantitative

differences in measurements secondary to biomechanical alterations induced by spine loading.^{7–9} Additionally, soft tissue elements in the spine are best visualized by MRI, and upright imaging may be helpful in unmasking certain changes in the spine anatomy hitherto undetected with supine imaging.^{10,11}

Studies have shown that ligamentum flavum hypertrophy (LFH), mostly resulting from facet degenerative changes, or

article published online
May 6, 2023

DOI <https://doi.org/10.1055/s-0043-1768061>.
ISSN 0971-3026.

© 2023. Indian Radiological Association. All rights reserved.
This is an open access article published by Thieme under the terms of the Creative Commons Attribution-NonDerivative-NonCommercial-License, permitting copying and reproduction so long as the original work is given appropriate credit. Contents may not be used for commercial purposes, or adapted, remixed, transformed or built upon. (<https://creativecommons.org/licenses/by-nc-nd/4.0/>)
Thieme Medical and Scientific Publishers Pvt. Ltd., A-12, 2nd Floor, Sector 2, Noida-201301 UP, India

its anterior buckling into the spinal canal as leading causes of spinal canal stenosis and disc space narrowing.^{12–14} On the other hand, spine instability and instrumented laminectomies are also linked to LFH and canal narrowing at the segments adjacent to the intervention.^{15–19} Mechanistically, LFH is implicated in degenerative lumbar spinal stenosis resulting from direct compression of the spinal canal involving the cauda equina, reduction in the anteroposterior diameter (APD) of the intervertebral foramen, squeezing of the nerve roots with numbness and LBP symptoms, and painful lower extremities.^{15,17,20} Several studies have also probed into the microstructural changes associated with pathological LFH.^{21–24} However, there are only a few studies that have implicated associative or etiological relationship between LF or its pathological buckling, to degenerative disc disease, degenerative spondylolisthesis, or chronic LBP or leg pain.^{13,18,25}

Although changes in the disc and foraminal dimensions, listhetic shifts between vertebrae induced by upright position have been reported in the imaging/back pain literature, there are hardly any imaging studies specifically reporting comparative changes at the posterior elements of the lumbar spine measured in the spine and upright position, simultaneously validating the reliability of such quantification.^{8,10,26–30} Intuitively, posterior elements of the spinal canal, the laminae and the LF, would be the structures affected the most by the increased lumbar lordosis on weight bearing and as such, quantification of their deformation warrants further investigation in context of axial loading of the trunk.^{31,32} This study compares anteroposterior canal dimensions and interlaminar distances at levels as affected by spatial changes following weight bearing. Such approach to LBP imaging and the results reported in this study comparing two different loading conditions may be useful for diagnosing critical narrowing of the canal in symptomatic patients.

Materials and Methods

The study used an open, upright MRI to image the lumbar spines from volunteers without a history or concurrent back pain. It was hypothesized that upright imaging could demonstrate significant changes involving sagittal dimensions of the lumbar spinal canal and the interlaminar distances. Imaging was performed in two sessions: each involved imaging once in the upright and once in the supine positions. Lumbar canal and interlaminar dimensions were measured

at the intervertebral and lumbosacral discs levels in all the images.

Participant selection: Data was obtained from 13 volunteers aged between 18 and 60 years (mean: 38 [± 12] years; 7 females/6 males). Individuals were excluded at screening if they reported LBP more than or equal to 2 on the numeric pain rating scale, a history of spinal surgery, any orthopaedic or neurologic impairment, cancer or tumors, cardiopulmonary disorders, clinical depression, or were taking medications or supplements for LBP. General compatibility for MRI was assessed; subjects with a body mass index (BMI) more than 32 kg/m² or with any debilitating condition that impaired standing inside an open MRI system were excluded. The institutional review board approved the study protocol (institutional review board #16-F-13), and all subjects gave written informed consent. Visit 1 included study orientation and subject consent. Visits 2 and 3 were scheduled 1 week apart at the university MRI facility (►Fig. 1). One male participant dropped out of the study due to personal reasons.

Imaging protocol: Scout images were obtained isocentered at the L3–L4 intervertebral discs after participants were secured supine on the MRI table. With the footrest height-adjusted and recorded, the table was rotated to 87 degrees vertical as the participants eased into a WB position, with their feet shoulder-width apart. Participants were comfortably secured above the knee and at the pelvis using cushioned straps accompanying the MRI machine to help maintain an upright position during imaging. Images were acquired using an open-field magnet (0.25 T) G-Scan Brio WB MRI (Esaote S.p.A., Genova, Italy) in an upright position. Next, individuals were brought to the supine position by tilting the table to the horizontal plane. Participants laid supine and rested for 5 minutes to relax the spine before image acquisition was initiated. Sagittal MRIs of the lumbar spine (L1–S1) were acquired in both positions using a fast spin echo T₂ sequence (TR = 3520 milliseconds; TE = 125 milliseconds; # of acquisition = 1; matrix = 288 × 234; field of view = 320 × 320; oversampling = 185%; slice thickness = 4 mm; gap = 1 mm; acquisition time: 4 minutes, 41 seconds). Scanning time and sequences were as described in earlier studies reporting less than 5 minutes of scan time at each position. Typically, each participant spent approximately 45 minutes per session, including positioning, tilting, image acquisition, and resting time.

Image analysis: All DICOM images were transferred to a proprietary image analysis platform (OrthoCAD, Esaote S.p.A.,

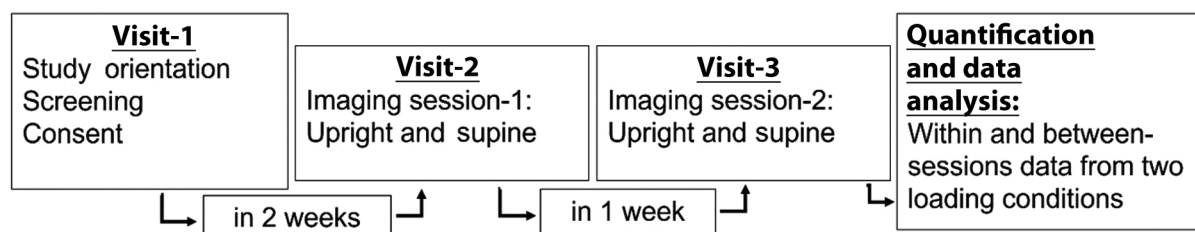


Fig. 1 Timeline and objectives of the study visits.

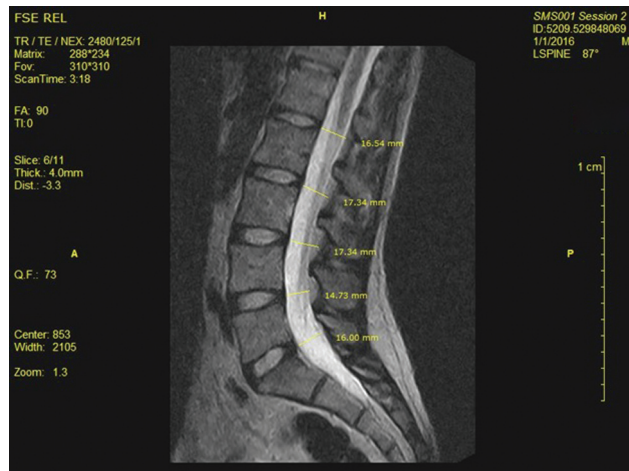


Fig. 2 T₂-weighted image showing the lumbar spinal canal. The anteroposterior dimensions are marked across the spinal canal as measured by the software tool at the five lumbar zones.

Genova, Italy). Borders of the lumbar spine, first sacral vertebral bodies, spinal canal, and vertebral foramina were manually outlined on the image slices using the software. Images were then segmented and digitized by proprietary three-dimensional segmentation software (OrthoCAD). Semiautomated segmentation and measurement tools available in the software were used to quantify lumbar spinal canal APDs at the lumbar and lumbosacral disc levels (**►Fig. 2**), and the interlaminar distances measured at between the centers of the laminae at each spinal motion segment (**►Fig. 3**), in millimeters.

Statistical analysis: Supine and upright measurements obtained from the two sessions were compared separately for reliability using Pearson's correlation coefficient. Within-session differences between supine and upright images were tested for statistical significance using a two-tailed paired student's *t*-test. Considering potential changes in magnification and minor variabilities associated with participant

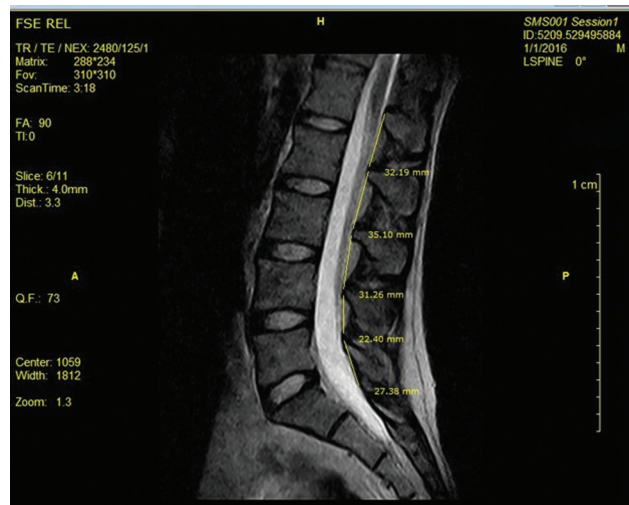


Fig. 3 Interlaminar distances shown measured between the center points of the laminae arches across each spinal motion segment.

positioning within the scanner in the two imaging sessions, the differences calculated between the supine and upright images were normalized for each session. This was done by subtracting the supine from the upright measurement, dividing that value by the supine dimension at each level and taking the absolute value for analysis: $([\text{supine}-\text{upright}]/\text{upright})$. A student's *t*-test (2-tailed) was then applied to test the significance of difference in measurements in the two spatial positions acquired in each session (within-session) separately. A two-factor repeated measured analysis of variance (ANOVA; without replication; 2 positions \times 2 sessions) was applied, followed by multiple *post-hoc* comparisons (Tukey's) to determine the significance of variance for each dimension for images acquired in both positions, and across the two imaging sessions (between-session; IBM SPSS Statistics for Windows, Version 24.0, IBM Corp., Armonk, New York, United States).

Results

(1) Spinal canal A-P dimensions (APD, in millimeters; **►Table 1**): APD of the spinal canal were measured as the anteroposterior space available at the level of the intervertebral discs (referred to as zones), perpendicularly across the spinal canal (**►Figs. 2** and **4**). The measurements showed a decrease in this dimension with weight bearing. Additionally, the decrease in this dimension in the upright position correlated and corresponded to the distance measured across each zone in the supine position (**►Table 2**). Pearson's statistic showed strong correlation and reliability for measurements when comparing separately the supine and upright imaging, both within and across the two imaging sessions. Strong correlation was found in the normalized differences between the imaging sessions indicating consistency in detecting supine versus upright alterations (**►Table 2**). *T*-tests ($p < 0.01$) repeated measures and factorial ANOVA demonstrated statistically significant *F* values for differences in supine versus upright imaging for APD when applied to all four imaging conditions (2 positions \times 2 sessions; $F [3,59] = 6.32$; $p < 0.01$).

(2) Interlaminar distance (ILD, in millimeters; **►Table 1**): The ILD at each level was measured between the center points of the laminae in a spinal segment (**►Figs. 3** and **5**). Significant decrease with load bearing was observed except at the lumbosacral (L5-S1) segment. Pearson's statistic showed strong correlation and reliability for measurements when comparing separately the supine and upright imaging, both within and across the two imaging sessions. Strong correlation was found in the normalized differences between the imaging sessions indicating consistency in detecting supine versus upright alterations. *t*-tests ($p < 0.01$) repeated measures and factorial ANOVA demonstrated statistically significant *F* values for differences in supine versus upright imaging for ILD when applied to all four imaging conditions (2 positions \times 2 sessions; $F [3,59] = 5.47$; $p < 0.01$).

Table 1 Descriptive statistics of the spinal canal A-P (anteroposterior) dimensions and interlaminar distances measured in images acquired in supine and upright positions ($n = 12$)

Spinal canal A-P dimension	Zone: L1-L2	Zone: L2-L3	Zone: L3-L4	Zone: L4-L5	Zone: L5-S1
Supine	16.73 (± 2.89)	15.90 (± 2.62)	15.72 (± 2.15)	14.86 (± 2.23)	12.62 (± 2.10)
Upright	16.11 (± 2.36)	15.11 (± 2.05)	14.34 (± 2.40)	13.27 (± 2.13)	12.20 (± 2.20)
t-test (supine vs. upright)	0.14	0.02 ^a	0.03 ^a	0.00 ^a	0.53
Correlation (session 1 vs. 2)	0.82	0.81	0.78	0.88	0.83
Interlaminar distance	L1-L2	L2-L3	L3-L4	L4-L5	L5-S1
Supine	32.02 (± 3.01)	30.99 (± 2.73)	30.37 (± 3.82)	26.49 (± 2.10)	23.02 (± 2.91)
Upright	29.49 (± 3.29)	28.31 (± 2.91)	28.88 (± 2.43)	25.51 (± 2.66)	23.54 (± 2.47)
t-test (supine vs. upright)	0.00 ^a	0.00 ^a	0.02 ^a	0.03 ^a	0.48
Correlation (session 1 vs. 2)	0.84	0.72	0.80	0.75	0.88

Note: All measurements (average (\pm standard deviation) are in millimeters. The spinal canal A-P (anteroposterior) dimension was measured at the level of the intervertebral discs (lumbar zones) and the interlaminar distances were measured between the mid-laminae of each motion segment. ^aStatistically significant at $p < 0.05$.

However, pairwise Tukey's Honestly Significant Difference comparisons returned higher significance (<0.01) for supine versus upright measurements only involving the APD at the L4-L5 zone and for ILD at the L1-L2 and L2-L3 junctions in the statistical comparison. This could be an expected statistical outcome given that the means compared in this study (2 supine, 2 upright) may have lacked impactfully very different individual values since the pairs of supine and upright averages were clustered together, apparently due to the small sample size and obvious absence of potentially back pain related structural discrepancies. However, it may be noted that all comparisons (correlations between similar imaging positions both within and between the two imaging sessions, differences between contrasting imaging positions

both within and between the two imaging sessions) tested consistent with the paired student's *t*-test, the same result being asserted by the significant F statistic. Intraclass correlation coefficients (ICC) calculated for measured variables by session and by scanning positions and intra-rater reliability analysis performed using absolute agreement and a two-way random model reporting single measures for ICC, demonstrated strong correlations.

Discussion

This study was undertaken to address the question if upright MRI could detect significant alterations at the posterior elements of the spinal canal compared with supine imaging.

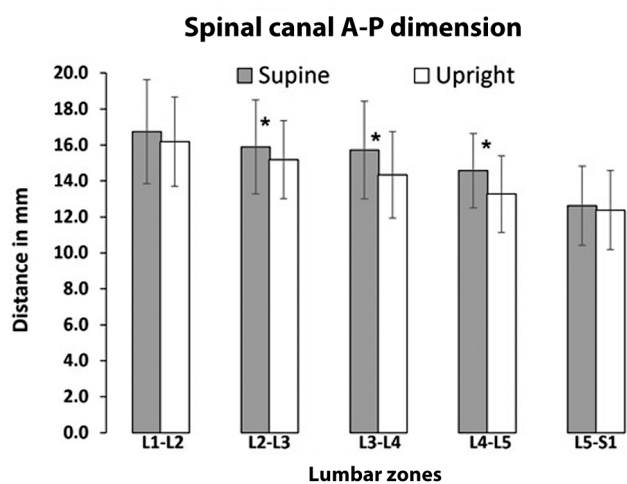


Fig. 4 Graph showing the anteroposterior dimension (APDs; in millimeters) measured in the supine and upright images. Asterisks represent the lumbar zones returning significant values when comparing the two loading conditions ($p < 0.05$).

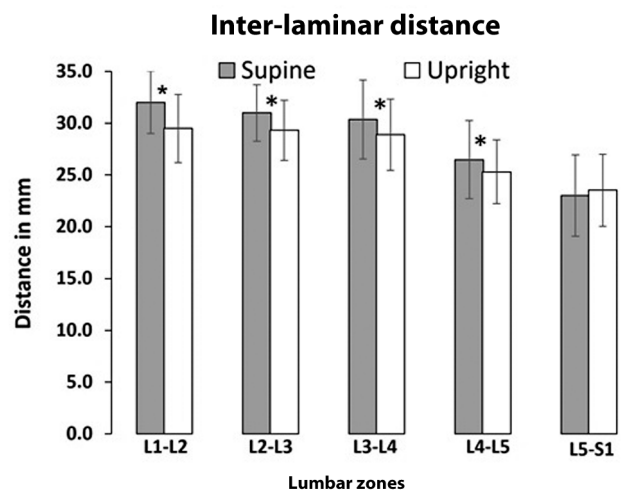


Fig. 5 Graph showing the interlaminar distances (in millimeters) measured in the supine and upright images. Asterisks represent lumbar zones returning significant values when comparing the two loading conditions ($p < 0.05$).

Table 2 Intraclass correlation coefficients (ICC) calculated for measured variables by session and by scanning positions

	Spinal canal A-P dimension					Interlaminar distance				
	Zone: L1-L2	Zone: L2-L3	Zone: L3-L4	Zone: L4-L5	Zone: L5-S1	L1-L2	L2-L3	L3-L4	L4-L5	L5-S1
ICC (supine)	0.72	0.88	0.91	0.95	0.88	0.97	0.92	0.84	0.94	0.82
95% CI	0.58-0.71	0.81-0.93	0.90-0.95	0.91-0.97	0.81-0.96	0.96-0.98	0.87-0.95	0.75-0.90	0.91-0.96	0.57-0.73
ICC (upright)	0.77	0.91	0.93	0.96	0.92	0.98	0.83	0.89	0.94	0.71
95% CI	0.65-0.85	0.86-0.94	0.88-0.96	0.93-0.96	0.85-0.95	0.97-0.98	0.74-0.90	0.82-0.93	0.91-0.96	0.66-0.88

Abbreviations: A-P, anteroposterior; CI, confidence interval.
 Note: Intratester reliability analysis was performed using absolute agreement and a two-way random model reporting single measures for ICC, in SPSS.

Since changes in the dimensions at the posterior aspect of the spinal canal have been attributed to critical narrowing of the passage resulting in clinical symptoms, this study aimed to investigate the physiological effect of axial load bearing on these structures dorsal to the canal in a non-LBP cohort.

The study indicates that load bearing decreases the APDs of the spinal canal at all the disc levels, most significantly at the L2-5 zones of the lumbar motion segments. However, this sagittal space is minimally affected at the lumbosacral (L5-S1) junction. Since the position of the vertebral body remains constant with the posterior arch (and laminae) as they form the vertebral canal, changes occurring secondary to weight bearing in the upright position are manifested at the intervertebral levels corresponding to the intervertebral disc and the LF planes. Measurements obtained in this study demonstrate that the APD measures at these planes are affected and reduced probably due to mechanical deformation at the discs, listhetic tendency of the superior vertebrae, and dynamic shifts in the anterior LF curvatures at these planes caused by the increased lordotic curvature of the lumbar spine induced by the upright position of the individual.³³

With upright loading of the spine, the ILD changes significantly at all lumbar vertebral levels except at the lumbosacral junction. This occurs simultaneously with the increase in the lumbar lordotic curvature, opening of the anterior intervertebral space as the loading pivots on the facet joints, approximation of the vertebral laminae, with concurrent anterior bulking of the LF elements.³ These changes may be effective minimally at the lumbosacral posterior elements that are structurally somewhat different from the typical posterior element articulations in a lumbar motion segment.³⁴ This observation is in alignment with studies that have explored reciprocal changes occurring in the dimensions of the posterior elements with forward flexion using different investigation techniques.³⁵

Accordingly, this study is probably the very few ones that have not only investigated weight bearing shifts in the posterior elements of the spinal canal but also tested the reliability of such measurements across multiple imaging sessions. Evidence from this study points out that upright weight bearing position may induce significant changes even in asymptomatic cohorts and that upright imaging may unmask baseline deformations at the posterior elements even in people without back pain and can help in deciding if such postural changes are innocuous or consequential depending on the degree of such changes and their symptomatic correlations. Notwithstanding, from a technical standpoint it is worth noticing that quantitative data from these anatomical parameters could be acquired and analyzed with high reliability using an upright MRI paradigm.³⁶

None of the participants in this study ever had chronic or acute back pain episode. Also, since all individuals were within a specific BMI range, we assume that the anatomical changes reported in this study are within physiological limits and represent the effects of normal load bearing in the upright position. Two participants in this study, though did not report back pain, showed some evidence of disc

degeneration at their L3-L4 and lumbosacral levels. The primary aim of the study was to determine the consistency and reliability of detecting anatomical changes in supine versus upright imaging across multiple sessions. This study is a descriptive, cross-sectional study investigating the reliability of such measurements. Consequently, the data analyzed in this study involves scans from participants without concurrent or previous history of back pain. Selecting LBP-free subjects offers flexibility in not having to control variables related to associated specific LBP situations. Involving LBP patients for such a study would certainly be useful in generating clinically relevant data. We plan to recruit more participants in a larger follow-up study (involving a similar imaging arms and protocols) with chronic LBP patients, with appropriate statistical power and sample size. Examination of diagnostic anatomical entities in the load-bearing position could be critical in identifying specific structural causes of spinal stenosis; markers that may remain undetected in recumbent MRI, especially in patients with degenerative disc disease where weight bearing may induce significantly detectable changes in the linear dimensions measured in this study. Thus, follow-up studies will be required involving symptomatic patients to ascertain and compare the role of the posterior element changes in inducing critical narrowing of the spinal canal causing back pain symptoms associated with lumbar stenosis.³⁷ Imaging studies involving physiological weight bearing in patients with back pain may be useful to understand the etiological effects of such changes in mechanical LBP.

Conclusion

Upright imaging can detect shifts in the posterior element morphology at the lumbar spinal canal, as induced by weight bearing.

Conflict of Interest

None declared.

Acknowledgment

Author acknowledges support from Ohio Musculoskeletal and Neurological institute (OMNI) and the CTRU for facilitating with the imaging and data collecting efforts. Data used in the study was partly acquired for another research project funded by Grant #13-08-682 (Assessment of the In-Vivo Segmental Vertebral Motion Characteristics of Lumbar Vertebrae) from the American Osteopathic Association.

References

- Rajasekaran S, Bajaj N, Tubaki V, Kanna RM, Shetty AP. ISSLS Prize winner: the anatomy of failure in lumbar disc herniation: an in vivo, multimodal, prospective study of 181 subjects. *Spine* 2013; 38(17):1491–1500
- Vogt L, Pfeifer K, Pportscher And M, Banzer W. Influences of nonspecific low back pain on three-dimensional lumbar spine kinematics in locomotion. *Spine* 2001;26(17):1910–1919
- Yao Q, Wang S, Shin JH, Li G, Wood K. Motion characteristics of the lumbar spinous processes with degenerative disc disease and degenerative spondylolisthesis. *Eur Spine J* 2013;22(12): 2702–2709
- Mahato NK, Sybert D, Law T, Clark B. Effects of spine loading in a patient with post-decompression lumbar disc herniation: observations using an open weight-bearing MRI. *Eur Spine J* 2017;26 (Suppl 1):17–23
- Mahato NK, Montuelle S, Goubeaux C, et al. Quantification of intervertebral displacement with a novel MRI-based modeling technique: assessing measurement bias and reliability with a porcine spine model. *Magn Reson Imaging* 2017;38:77–86
- Xia Q, Wang S, Kozanek M, Passias P, Wood K, Li G. In-vivo motion characteristics of lumbar vertebrae in sagittal and transverse planes. *J Biomech* 2010;43(10):1905–1909
- Mahato NK, et al. Effects of spine loading in a patient with post-decompression lumbar disc herniation: observations using an open weight-bearing MRI. *Eur Spine J* 2016;26(Suppl 01). Doi: 10.1007/s00586-016-4581-6
- Kanno H, Ozawa H, Koizumi Y, et al. Changes in lumbar spondylolisthesis on axial-loaded MRI: do they reproduce the positional changes in the degree of olisthesis observed on X-ray images in the standing position? *Spine J* 2015;15(06):1255–1262
- Tarantino U, Fanucci E, Iundusi R, et al. Lumbar spine MRI in upright position for diagnosing acute and chronic low back pain: statistical analysis of morphological changes. *J Orthop Traumatol* 2013;14(01):15–22
- Danielson B, Willén J. Axially loaded magnetic resonance image of the lumbar spine in asymptomatic individuals. *Spine* 2001;26 (23):2601–2606
- Oppenheim JS, Mills J. Recurrent lumbar disc herniation treated with interspinous fusion and instrumentation: a case series. *Surg Technol Int* 2013;23:269–272
- Zhu X, Qiu Z, Liu Z, et al. CT-guided percutaneous lumbar ligamentum flavum release by needle knife for treatment of lumbar spinal stenosis: a case report and literature review. *J Pain Res* 2020;13:2073–2081
- Munns JJ, Lee JY, Espinoza Orías AA, et al. Ligamentum flavum hypertrophy in asymptomatic and chronic low back pain subjects. *PLoS One* 2015;10(05):e0128321
- Chokshi FH, Quencer RM, Smoker WRK. The “thickened” ligamentum flavum: is it buckling or enlargement? *Am J Neuroradiol* 2010;31(10):1813–1816
- Poletti CE. Central lumbar stenosis caused by ligamentum flavum: unilateral laminotomy for bilateral ligamentectomy: preliminary report of two cases. *Neurosurgery* 1995;37(02):343–347
- Park J-B, Kong CG, Suhl KH, Chang ED, Riew KD. The increased expression of matrix metalloproteinases associated with elastin degradation and fibrosis of the ligamentum flavum in patients with lumbar spinal stenosis. *Clin Orthop Surg* 2009;1(02):81–89
- Alvarez JA, Hardy RH Jr. Lumbar spine stenosis: a common cause of back and leg pain. *Am Fam Physician* 1998;57(08):1825–1834, 1839–1840
- Kim YU, Park JY, Kim DH, et al. The role of the ligamentum flavum area as a morphological parameter of lumbar central spinal stenosis. *Pain Physician* 2017;20(03):E419–E424
- Kasim FB, Tosun O, Kasim E, et al. “Thickened” ligamentum flavum caused by laminectomy. *Neurol Neurochir Pol* 2015;49(03): 145–149
- Reyes-Sánchez A, García-Ramos CL, Deras-Barrientos CM, Alpizar-Aguirre A, Rosales-Olivarez LM, Pichardo-Bahena R. Ligamentum flavum in lumbar spinal stenosis, disc herniation and degenerative spondylolisthesis. An histopathological description. *Acta Ortop Mex* 2019;33(05):308–313
- Yamada T, Horikawa M, Sato T, et al. Hypertrophy of the ligamentum flavum in lumbar spinal canal stenosis is associated with abnormal accumulation of specific lipids. *Sci Rep* 2021;11(01):23515
- Amudong A, Muheremu A, Abudouexit T. Hypertrophy of the ligamentum flavum and expression of transforming growth factor beta. *J Int Med Res* 2017;45(06):2036–2041

- 23 Chen J, Liu Z, Zhong G, et al. Hypertrophy of ligamentum flavum in lumbar spine stenosis is associated with increased miR-155 level. *Dis Markers* 2014;2014:786543
- 24 Park J-B, Lee JK, Park SJ, Riew KD. Hypertrophy of ligamentum flavum in lumbar spinal stenosis associated with increased proteinase inhibitor concentration. *J Bone Joint Surg Am* 2005; 87(12):2750-2757
- 25 Cheung PWH, Tam V, Leung VYL, et al. The paradoxical relationship between ligamentum flavum hypertrophy and developmental lumbar spinal stenosis. *Scoliosis Spinal Disord* 2016;11(01):26
- 26 Kanno H, Endo T, Ozawa H, et al. Axial loading during magnetic resonance imaging in patients with lumbar spinal canal stenosis: does it reproduce the positional change of the dural sac detected by upright myelography? *Spine* 2012;37(16):E985-E992
- 27 Hiwatashi A, Danielson B, Moritani T, et al. Axial loading during MR imaging can influence treatment decision for symptomatic spinal stenosis. *Am J Neuroradiol* 2004;25(02):170-174
- 28 Hsieh MS, Tsai MD. Diagnosis of herniated intervertebral disc assisted by 3-dimensional, multiaxial, magnetic resonance imaging. *J Formos Med Assoc* 1999;98(05):347-355
- 29 Choi KC, Kim JS, Jung B, Lee SH. Dynamic lumbar spinal stenosis: the usefulness of axial loaded MRI in preoperative evaluation. *J Korean Neurosurg Soc* 2009;46(03):265-268
- 30 Jinkins JR, et al. Upright, dynamic flexion-extension MRI of the spine: kinetic MRI (kMRI). *Radiology* 2001;221:568-568
- 31 Meakin JR, Gregory JS, Smith FW, Gilbert FJ, Aspden RM. Characterizing the shape of the lumbar spine using an active shape model: reliability and precision of the method. *Spine* 2008;33(07):807-813
- 32 Meakin JR, Gregory JS, Aspden RM, Smith FW, Gilbert FJ. The intrinsic shape of the human lumbar spine in the supine, standing and sitting postures: characterization using an active shape model. *J Anat* 2009;215(02):206-211
- 33 Riesenburger RI, Safain MG, Ogbuji R, Hayes J, Hwang SW. A novel classification system of lumbar disc degeneration. *J Clin Neurosci* 2015;22(02):346-351
- 34 Pal GP. Weight transmission through the sacrum in man. *J Anat* 1989;162:9-17
- 35 Wang S, Passias P, Li G, Li G, Wood K. Measurement of vertebral kinematics using noninvasive image matching method-validation and application. *Spine* 2008;33(11):E355-E361
- 36 Mahato NK, Montuelle S, Clark BC. Assessment of in vivo lumbar inter-vertebral motion: reliability of a novel dynamic weight-bearing magnetic resonance imaging technique using a side-bending task. *Asian Spine J* 2019;13(03):377-385
- 37 Thomas JS, Clark BC, Russ DW, France CR, Ploutz-Snyder R, Corcos DMRELIEF Study Investigators. Effect of spinal manipulative and mobilization therapies in young adults with mild to moderate chronic low back pain: a randomized clinical trial. *JAMA Netw Open* 2020;3(08):e2012589-e2012589