



Outward subcortical curvature associated with sub-clinical depression symptoms in adolescents

Lisanne M. Jenkins^{a,*}, Jessica J. Chiang^b, Katherine Vause^b, Lauren Hoffer^b, Kathryn Alpert^a, Todd B. Parrish^{c,d}, Gregory E. Miller^b, Lei Wang^{a,c}

^a Department of Psychiatry and Behavioral Sciences, Northwestern University, Chicago, IL, United States

^b Institute for Policy Research and Department of Psychology, Northwestern University, Chicago, IL, United States

^c Department of Radiology, Northwestern University, Chicago, IL, United States

^d Department of Biomedical Engineering, Northwestern University, Chicago, IL, United States

ARTICLE INFO

Keywords:

Morphometry
Subcortical
MRI
Sub-clinical depression

ABSTRACT

Objective: Subclinical or subthreshold depressive symptoms (StD) are frequent in adolescence and are related to suicidality and onset of depression in adulthood, however, their neurobiology is poorly understood. We examined the relationship between StD and subcortical grey matter structures in unmedicated adolescents with no history of axis I diagnosis.

Methods: 277 youths from Chicago aged 14 years participated, undergoing a structural MRI scan and completing the Revised Children's Anxiety and Depression Scale (RCADS). Blood samples provided a composite of five pro-inflammatory cytokines. Regions of interest (ROI) for vertex-based surface analysis were the left and right amygdala, hippocampus, thalamus, caudate, nucleus accumbens, pallidum and putamen. Covariates were age, pubertal status, socioeconomic disadvantage and intracranial volume. Males and females were analysed separately.

Results: StD had positive associations (outward shape) with subcortical morphology in the right amygdala and left hippocampus in females, and the bilateral putamen and the left caudate, hippocampus and thalamus in males. However, we also found negative associations with StD (inward contractions) in the hippocampus in females and the caudate in males. Pro-inflammatory cytokines did not mediate the relationship between StD and outward morphology or volume.

Conclusion: This is one of the first studies to examine subcortical morphology of basal ganglia and thalamic regions related to StD in adolescents, and the first study to report mostly positive associations between StD, volume and outward morphology in youths. These findings could reflect intact neurogenesis or resilience to depression, however longitudinal research is needed to further understand the neurobiology of StD in adolescents.

1. Introduction

Adolescence is a critical period for the onset of depressive disorders, with 14 percent of males and 28 percent of females experiencing a depressive episode by age 18 (Hankin et al., 1998). Subclinical or subthreshold depressive symptoms (StD) are frequent in adolescence (Pine et al., 1999), with a lifetime prevalence as high as 26 percent (Fergusson et al., 2005). Despite not meeting diagnostic criteria, StD can be distressing and impairing, are related to functional impairment and suicidality (Balazs et al., 2013), and onset of depression in adulthood (Pine et al., 1999). An improved understanding of the neurobiology of StD in adolescence could lead to early detection mechanisms

to reduce burden of disease in these individuals, and reduce risk for conversion to major depressive disorder (MDD), which is a leading cause of disability, globally.

Structural neuroimaging studies have attempted to identify biomarkers of MDD. Meta-analyses, which largely include adults, have reported reduced volume of subcortical grey matter (GM) structures, including the hippocampus (Arnone et al., 2012; Schmaal et al., 2016), thalamus and basal ganglia (Kempton et al., 2011). These findings are also reported in studies specific to children and adolescents. For example, pediatric MDD has been associated with smaller volume of the hippocampus, particularly on the left (Caetano et al., 2007; MacMaster and Kusumakar, 2004; MacMaster et al., 2008), right striatum (Matsuo et al.,

* Corresponding author at: Psychiatry and Behavioral Sciences, Northwestern University, 710 Lake Shore Drive, Suite 1315, Chicago, IL 60611, United States.

E-mail address: lisanne.jenkins@northwestern.edu (L.M. Jenkins).

<https://doi.org/10.1016/j.nicl.2020.102187>

Received 28 October 2019; Received in revised form 27 December 2019; Accepted 16 January 2020

Available online 17 January 2020

2213-1582/ © 2020 Published by Elsevier Inc. This is an open access article under the CC BY-NC-ND license

(<http://creativecommons.org/licenses/by-nc-nd/4.0/>).

Table 1
Demographic characteristics of the sample.

	Male (n = 96) Mean (SD) or n	Female (n = 160) Mean (SD) or n	statistic
Age in years	13.90 (0.49)	13.92 (0.56)	$t(254) = 0.40, p = .691$
Caucasian (n)	Yes = 42, No = 54	Yes = 62, No = 98	$\chi^2(1) = 0.62, p = .43$
Hispanic (n)	Yes = 32, No = 64	Yes = 48, No = 112	$\chi^2(1) = 0.31, p = .58$
Puberty category (n)	pre-pubertal = 1 early pubertal = 10 mid-pubertal = 59 late-pubertal = 24 post-pubertal = 2	pre-pubertal = 0 early pubertal = 0 mid-pubertal = 21 late-pubertal = 104 post-pubertal = 35	$\chi^2(4) = 98.65, p < .001$
Intracranial Volume (cms ³)	1619.10 (134.74)	1464.73 (120.91)	$t(254) = -9.47, p < .001$
Disadvantage	0 = 38 1 = 23 2 = 12 3 = 14 4 = 9	0 = 57 1 = 37 2 = 26 3 = 17 4 = 23	$\chi^2(4) = 2.82, p = .589$
RCADS MDD T (Winsorized)	45.66 (10.01)	47.58 (9.58)	$t(254) = 1.53, p = .128$
RCADS Anxiety T (Winsorized) ¹	46.54 (10.32)	45.75 (9.52)	$t(254) = -0.62, p = .538$

Note.

¹ One value for the RCADS Anxiety T score was Winsorized to be within 3SD of the mean.

2008), and bilateral amygdala (Rosso et al., 2005), although the amygdala finding is sometimes absent (MacMaster et al., 2008) or greater than healthy controls (MacMillan et al., 2003).

Fewer neuroimaging studies have been performed in StD, but some studies report reduced volume in subcortical regions in adults. For example, one study found adults with StD had decreased GM volume in the bilateral globus pallidus and increased GM volume in the left thalamus, which correlated with symptom severity (Li et al., 2017). Another study found StD was associated with reduced volume of the hippocampus only in males (Spalletta et al., 2014). Li et al. (2015) found that in 20-year-old women, StD was associated with increased left amygdala volume.

Very few studies have examined the impact of StD on subcortical GM in youths. Vulser et al. (2015) found that adolescents aged 16 with StD had smaller caudate volumes at age 14 compared to healthy controls. Studies of adolescents at risk for developing MDD have also reported subcortical GM abnormalities. For example, girls aged 9–15 years at high familial risk but who had not experienced onset of MDD were found to have reduced hippocampal volume (Chen et al., 2010) compared to a low-risk group.

Morphology, or shape analysis, of subcortical structures may be more sensitive than measurements of volume, as it provides localized regions of shape changes, whereas volume only provides a single value for an entire structure, hence less information. E.g. Watanabe et al. (2017) did not find volumetric differences between adults with first-episode MDD and healthy controls, but they did find significant inward contractions, predominantly in the cornu ammonis (CA1) and subiculum in the bilateral hippocampi in the MDD group. Other studies in adults have also reported bilateral morphological changes in hippocampal sub-regions including the subiculum and CA1, in adults with acute MDD (Cole et al., 2010) and at five-year follow-up after a first episode (Isikli et al., 2013). Hippocampal shape differences in adolescents with early-onset depression have also been reported (Ramezani et al., 2014). The only study to examine subcortical morphology as it related to MDD in structures other than the hippocampus, is Lu et al. (2016). These researchers found regionally contracted areas of the ventromedial and dorsolateral bilateral putamen, and dorsal and ventral areas of the left thalamus in adults with first-episode MDD.

Analysis of subcortical morphology can capture localized variations of the structures, including functionally distinct subregions, and could enlighten discrepant findings in the literature. While morphology and volume of the hippocampus and to a lesser extent the amygdala have been studied in MDD, we aimed to extend our analysis to the basal ganglia, given the importance of these regions in reward, and known reward processing deficits in MDD. We also attempted to extend the

finding of contracted thalamus in first-episode MDD by Lu et al. to our sample of youths. As such, our study was the first to examine the relationship between StD and multiple subcortical surface shapes in adolescents. We hypothesized that StD would be negatively associated with volume and morphology (i.e. greater StD would be associated with lower volume and more inward surface contractions compared to the population average) of subcortical GM. Given sexual dimorphisms in subcortical structural maturation patterns (Giedd et al., 2015), stress-related changes in brain morphology (McLaughlin et al., 2009), that females are almost twice as likely to develop MDD than males (Kessler et al., 1993), and that differences in the prevalence of clinical and StD emerge following puberty (Balazs et al., 2013), we tested this hypothesis separately in males and females.

2. Methods

2.1. Participants

Participants comprised 277 youths from the greater Chicago community. Exclusion criteria were: history of prescription medication during the prior three months, chronic medical or psychiatric illness, infectious disease during the past two weeks, and current pregnancy. A parent or caregiver completed interviews about their youth.

Youths completed an MRI scan at Northwestern University. Of the 277 youths enrolled, the final analytic sample was 256. Fifteen individuals were too obese or anxious or could not schedule a scan. Visual inspection of FreeSurfer parcellations of T1 images resulted in exclusion of individuals due to poor segmentations (3 female, 2 male), and presence of agenesis of the corpus callosum (1 female). Demographic information is displayed in Table 1. As expected, compared to males, female youth had significantly smaller intra-cranial volume and were at a more advanced pubertal stage, providing further justification for examining males and females separately.

2.2. Measures

The short version of the Revised Children's Anxiety and Depression Scale (RCADS) (Ebesutani et al., 2012) is a 25 item self-report measure. Higher scores indicate worse symptoms. Subscales measure symptoms of Anxiety and Major Depressive Disorder (MDD). T scores (adjusted for gender and grade) of the MDD scale were used to measure StD. Three values greater than 3 standard deviations (SD) from the mean were Winsorized (Dixon, 1960) to the highest value within three SDs. These outliers can be seen in Fig. 1. As axis I diagnoses were exclusion criteria, we consider these symptoms subthreshold. However, following

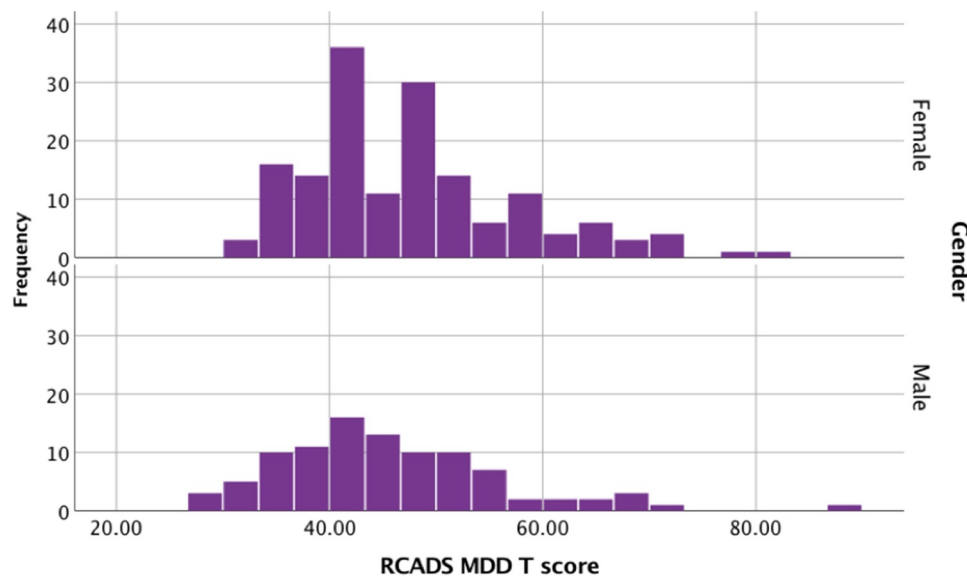


Fig. 1. Histogram of RCADS-MDD by gender, showing three outliers (three rightmost observations) that were Winsorized to the next highest value within 3 standard deviations for that gender.

Winsorization, 8 of 256 individuals scored slightly above the RCADS-25 clinical threshold (70) with T scores of 70.55 (3), 72.73 and 72.86 (4).

Parents of youths completed the MacArthur Sociodemographic Questionnaire (Singh-Manoux et al., 2005), an 11 item self-report measure of socio-economic status (SES). From five of these items, a composite socioeconomic *Disadvantage* score was calculated which taps concrete exposures related to low SES. One point is received for the presence of each of the following: low household income, parent(s) have a high school education or less, parental unemployment, single parent household, and receipt of government assistance.

Following an overnight fast, venous blood was drawn from youths into a Serum Separator Tube (Becton-Dickinson) by antecubital venipuncture. five biomarkers of low-grade inflammation were measured: C-reactive protein (CRP), interleukin-6 (IL-6), interleukin-8 (IL-8), interleukin10 (IL-10), and tumor necrosis factor- α (TNF- α). For full methodological details please see Supplemental material. Raw values of each marker were log-10 transformed. Logged values were converted into z-scores, and averaged into a low-grade inflammation composite, following previous research.

2.3. Image acquisition and surface mapping

T1-weighted Magnetization prepared rapid gradient echo (MPRAGE) images were acquired (TR = 2300, TE = 1.91, TI = 1100, voxel size = 0.80 isotropic, acquisition matrix = 320 \times 320, field of view = 256 \times 256, flip angle = 7) on a 3T Siemens Prisma scanner at the Center for Translational Imaging at Northwestern University. Surfaces of seven ROIs (bilateral hippocampus, amygdala, nucleus accumbens, caudate, putamen, pallidum and thalamus) were automatically generated for each participant using the FS + LDDMM pipeline (Khan et al., 2008). This combines FreeSurfer's (FS) probabilistic voxel-based classification and a deformable, high dimensional template-based method of large deformation diffeomorphic metric mapping (LDDMM) (Beg et al., 2005). FS (version 5.3) subcortical labeling obtained the initial subcortical segmentations. This was followed with image alignment and intensity normalization with LDDMM (Beg et al., 2005), which produces smooth transformations for each region of interest (ROI). In previous research (Csernansky et al., 2004) we have established that diffeomorphic mapping of structural MRI resulted in reliable and valid maps between anatomical atlases and participant scans, with sub-mm precision. Furthermore, we have demonstrated valid and

reliable surface-based representations of anatomical structures based on these maps, which produced disease-specific biomarkers of deformation patterns (e.g. Csernansky et al., 2004; Wang et al., 2007, 2006).

2.4. Subcortical surface processing

Each subcortical surface was visually inspected, then rigidly registered to atlas space to calculate a population average. For each participant, local shape variation was calculated from the population average (all participants) by quantifying the perpendicular amplitude between surfaces at a vertex-to-vertex level. Quantification of perpendicular change between surfaces was assigned a positive (outward variation from population average) or negative (inward variation) value. For each ROI, shape variation values at each vertex were also summed across the whole surface to calculate overall volume for each participant for each ROI, utilizing the volume enclosed within the surfaces.

2.5. Statistical analyses

Associations between RCADS MDD T score (RCADS-MDD) and volume of subcortical regions were examined in linear regression models. Associations between RCADS-MDD and local shape variation of subcortical regions in surface-based analyses were performed using SurfStat (<http://www.math.mcgill.ca/keith/surfstat>) implemented in MATLAB. Morphometric changes were regressed onto RCADS-MDD to localize significant regions of local shape variation. Regions showing a positive association with StD are regions where higher StD is associated with outward shape variation from the population average. Regions of negative association with StD are regions where higher StD is associated with inward shape variation from the population average. Separate models were tested for each ROI. To test whether the pro-inflammatory cytokine composite mediated the relationship between RCADS-MDD and morphology, we used the PROCESS module implemented in SPSS. Age, puberty status (from the Pubertal Development Scale (Petersen et al., 1988)), total intracranial volume (ICV, estimated by FS) and socioeconomic disadvantage were covaried in all volumetric and surface analyses. Race is not typically included as a covariate in similar studies, and we expected any variance related to race to be mostly explained by SES and ICV. To confirm, we included race and ethnicity as covariates in analyses and the pattern of results did not alter,

Table 2
Linear regressions of subcortical volume onto RCADS-MDD, separately for males and females.

Structure	Males						Females					
	hem	Full model [†] R ²	MDD B	MDD SE (B)	MDD β	MDD p	Full model [†] R ²	MDD B	MDD SE (B)	MDD β	MDD p	
Hippocampus	L	.41	3.23	1.99	.14	.109	.46	2.75	1.45	.11	.061	
	R	.42	0.44	2.12	.02	.838	.41	3.21	1.68	.12	.058	
Amygdala	L	.35	1.88	1.25	.13	.135	.41	2.03	0.86	.15	.020*	
	R	.35	-0.41	1.28	-0.03	.750	.37	2.38	0.97	.16	.016*	
Caudate	L	.54	1.84	3.05	.05	.548	.48	0.62	2.19	.02	.778	
	R	.47	2.44	3.40	.06	.475	.43	-0.13	2.33	< -0.01	.957	
NAcc	L	.47	0.24	0.35	.06	.492	.37	0.35	0.29	.08	.231	
	R	.37	-0.15	0.44	-0.03	.737	.32	0.45	0.33	.09	.173	
Pallidum	L	.39	1.45	1.62	.08	.372	.51	0.16	1.04	.01	.881	
	R	.40	1.60	1.61	.09	.323	.55	-0.15	0.96	-0.01	.878	
Putamen	L	.39	8.18	3.86	.18	.037*	.42	0.21	2.63	.01	.935	
	R	.35	7.24	4.31	.15	.097	.46	-0.38	2.71	-0.01	.888	
Thalamus	L	.58	7.90	4.49	.13	.082	.57	6.32	3.08	.11	.042*	
	R	.60	3.49	3.96	.06	.380	.56	4.83	2.79	.09	.086	

Note.

* $p < .05$ (bold-face), RCADS-MDD = Major Depressive Disorder score on the Revised Children's Anxiety and Depression Scale.

[†] Full models include covariates age, Puberty category, intracranial volume (cms³), and socioeconomic Disadvantage, and are reported in Supplemental eTables 2 and 3.

therefore we did not further consider race or ethnicity in analyses.

To account for multiple comparisons, Random Field Theory (RFT) was applied using SurfStat. RFT considers both peaks and spatial extent by modeling noise as Gaussian random fields. This approach provided significant clusters of vertices (vertices $p < .01$) at the family-wise error rate (FWER) of $p < .05$ across each ROI. We additionally used FWER correction to account for the seven ROIs, thus results for each ROI are significant at the FWER corrected $p < .007$. Significance was visualized as a color map on the overall average surface.

3. Results

An independent samples *t*-test found that RCADS-MDD did not differ between males and females (Table 1, Fig. 1).

3.1. RCADS-MDD and volume

Mean subcortical volumes for males and females are reported in Table 1. Table 2 summarizes results of the volume regressions. In females, there was a significant association between RCADS-MDD and volume of the left and right amygdala, and the left thalamus. There were trending values for the left and right hippocampi. For males, there was a significant association between RCADS-MDD and left putamen volume. In all cases the standardized regression coefficients were positively signed, indicating that as RCADS-MDD increased, so did the volume of the bilateral amygdala and left thalamus in females, and the left putamen in males.

3.2. RCADS-MDD and morphology

Figs. 2 and 3 show the morphological results for males and females, respectively. Warm colors indicate regions where RCADS-MDD is positively associated with local shape variation (i.e., more MDD symptoms are associated with more outward local shape variation), and cool colors indicate areas where it is negatively associated with local shape variation (i.e., more MDD symptoms related to more inward local shape variation).

In males, positive associations between morphology and RCADS-MDD were found in the lateral putamen bilaterally and in the dorsal and anterior putamen in the left hemisphere. Positive associations were also found in the left anterior hippocampal head, superolateral thalamus, and caudate head. There was a negative association in the left ventral caudate body.

In females, there was a positive association between morphology

and RCADS-MDD in the left posterior-inferior subiculum of the hippocampus and the right superior-anterior amygdala. There was a negative association in the left superior-anterior hippocampal tail.

3.3. Mediation by inflammation

Mediation analysis did not find any significant indirect effect of the cytokine composite on the relationship between RCADS-MDD and any measure of volume or mean morphology of any ROI (see Table 3).

4. Discussion

We examined the relationship between StD and subcortical structural volume and morphology in adolescents. Our hypothesis of negative associations between RCADS-MDD and volume and morphology of the ROIs was largely not supported, although local regions of the hippocampus in females and caudate in males did show negative associations. Predominantly, we found volume and outward morphology were positively associated with higher StD. This relationship was not mediated by inflammation. While most literature reports negative associations between StD and volume and GM morphology, we describe recent evidence consistent with our findings. Potential mechanisms of the morphological changes are discussed in relation to clinical characteristics.

StD was positively associated with volume of the right amygdala. These results support findings of increased amygdala volume in 20-year-old females with StD (Li et al., 2015), adults with first-episode MDD (Frodl et al., 2002), and female adolescents (Whittle et al., 2014). Meta-analyses have suggested antidepressant (Hamilton et al., 2008) and antipsychotic medications (Schmaal et al., 2016) relate to increased subcortical volumes in MDD. However, amygdala volume correlates with depression in first-episode, medication-naïve patients (van Eijndhoven et al., 2009), and in the present study, previous psychiatric history and taking prescription medication within the past three months were exclusion criteria. Therefore, the present results cannot be explained by medication effects.

Consistent with our putamen finding, Shad et al. (2012) reported that adolescents with MDD had larger volume of the putamen and pallidum than healthy controls. The same study however, reported lower volume of the bilateral caudate and thalamus in MDD patients, although when they covaried for SES, their results lost significance (Shad et al., 2012). A study of adults with StD found smaller volume of the bilateral thalamus (Webb et al., 2014), contrary to our thalamic finding in males here. Our observed positive associations between

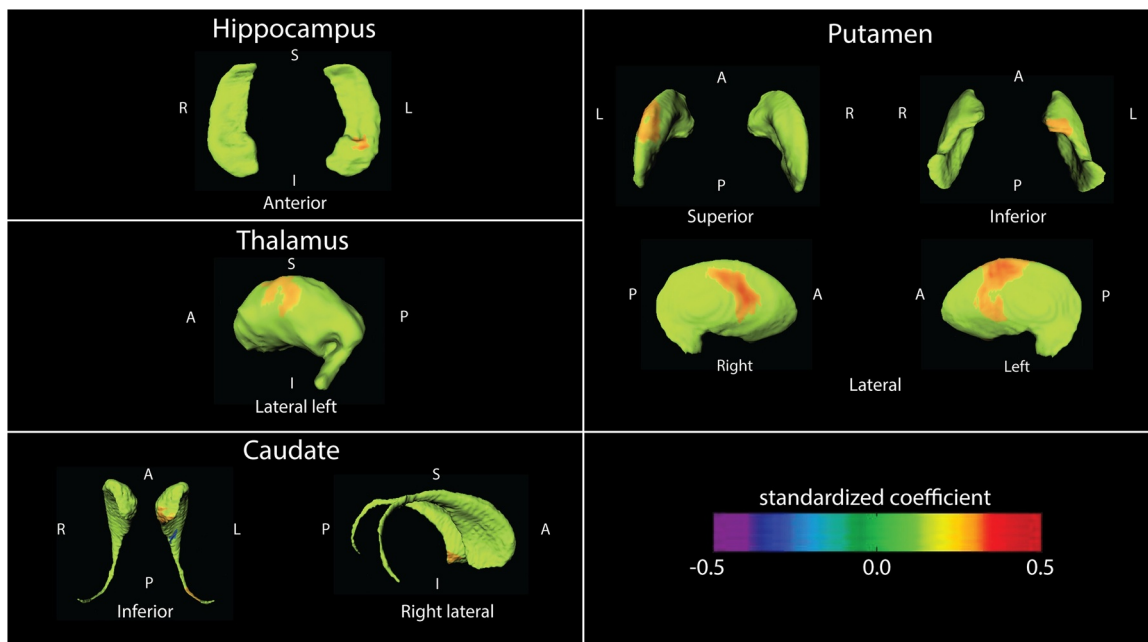


Fig. 2. Regression of local shape variation onto RCADS-MDD for males ($n = 96$) with age, puberty category, intracranial volume and socioeconomic disadvantage as covariates. Note. A = anterior, I = inferior, P = posterior, S = superior, L = left, R = right. Regions in green do not have any significant association with RCADS-MDD.

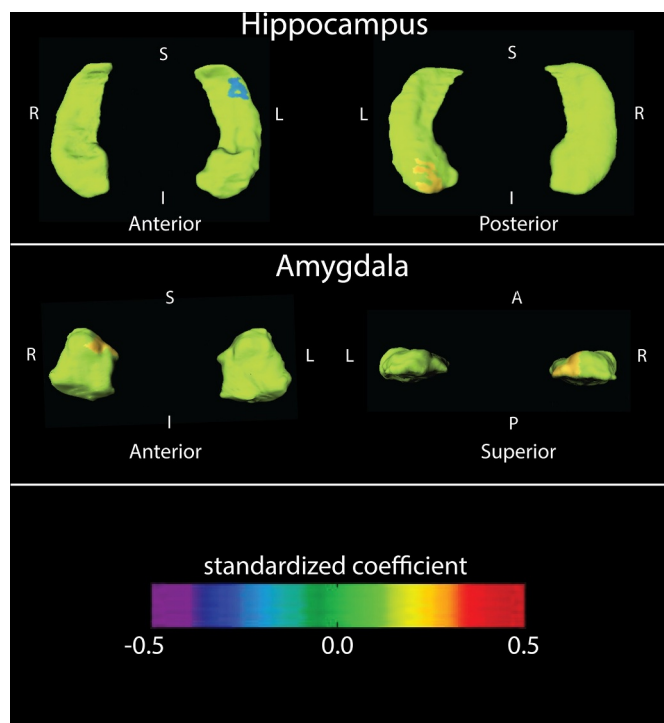


Fig. 3. Regression of local shape variation onto RCADS-MDD for females ($n = 160$) with age, puberty category, intracranial volume and socioeconomic disadvantage as covariates. Note. A = anterior, I = inferior, P = posterior, S = superior, L = left, R = right.

volume and StD contrast reports of decreased subcortical volumes in pediatric MDD (Caetano et al., 2007; Matsuo et al., 2008; Rosso et al., 2005) and meta-analyses of studies primarily or solely comprised of adults, in the basal ganglia (Arnone et al., 2012; Kempton et al., 2011; Koolschijn et al., 2009), thalamus (Kempton et al., 2011), hippocampus (Kempton et al., 2011; Koolschijn et al., 2009) and amygdala (Bora et al., 2012). However, a recent meta-analysis of first-episode medication-naïve patients with MDD found increased GM in the right

Table 3

Mediation analysis: Summary of non-significant indirect effects of morphology (per ROI) on RCADS-MDD through inflammation composite.

Gender	ROI	direction	Effect	Boot SE	LLCI	ULCI
Male	hippocampus	outward	0.47	0.64	-0.69	1.87
	thalamus	outward	0.44	-0.73	-0.73	1.11
	caudate	outward	0.10	0.38	-0.59	1.01
	caudate	inward	-0.76	0.83	-2.85	0.39
	putamen	outward	0.44	0.59	-0.47	1.81
Female	amygdala	outward	-0.01	0.27	-0.57	0.58
	hippocampus	outward	-0.11	0.26	-0.72	0.35
	hippocampus	inward	-0.06	0.36	-0.88	0.65

Note. RCADS-MDD = Major Depressive Disorder score on the Revised Children's Anxiety and Depression Scale, ROI = region of interest, Boot SE = bootstrap standard error, LLCI = lower limit confidence interval, ULCI = upper limit confidence interval.

putamen and bilateral thalamus (Wang et al., 2017). Thus, additional research is required to elucidate the relationship between StD and subcortical GM.

The lack of regional overlap in the morphology findings between males and females was striking. In males, positive associations between morphology and StD were observed in the bilateral putamen, left caudate, hippocampal head, and lateral thalamus. In contrast, for females, positive associations were found in the left posterior hippocampus and right amygdala. Males and females showed negative associations in the left caudate and left hippocampus, respectively. The males and females in this study did differ significantly in pubertal stage, to be expected at this age, however we included pubertal status as a covariate in all models. The different pattern of results for males and females could be due to differences in the biological effects of gonadal hormones on brain development.

The hippocampus showed regions of positive associations with StD in both males and females, but there was also a negative association in the left hippocampus tail in females, partly in line with our hypothesis. That we found this effect in females only could reflect the increased vulnerability of females to mood disorders (Kessler et al., 1993). This negative hippocampal association supports previous studies in adults with MDD that have reported inward contractions in the hippocampus,

including the left or bilateral tail (Cole et al., 2010; Isikli et al., 2013; Posener et al., 2003; Watanabe et al., 2017). Only one morphological study of subcortical GM as it relates to MDD has been reported in adolescents, which reported shape differences in the putamen and hippocampus between MDD patients and controls (Ramezani et al., 2014). The only other area of inward contraction we observed was in the left caudate for males, not supporting Lu et al. (2016) who found inward contractions of the putamen and thalamus. However, that study was of adults with first-episode MDD, and as discussed next, clinical characteristics such as disease state and course are important to consider.

Researchers have attributed the structural alterations associated with MDD, particularly of the hippocampus and amygdala (Lupien et al., 2009) to stress, as it's one of the strongest predictors of MDD. Chronic stress produces prolonged activation of the hypothalamic-pituitary-adrenal (HPA) axis (Lupien et al., 2009), involving the same pathophysiological process as inflammation (Zunszain et al., 2011). However, mediation analysis did not find that our pro-inflammatory cytokine composite mediated the relationship between RCADS-MDD and morphology, thus an alternative explanation is required.

Evidence that our results reflect a preclinical stage comes from research that has considered disease course. A recent study (Yuksel et al., 2018) found amygdala volume increased only in adults with a mild course of depression (0–1 episodes over a 3-year follow-up) compared with those with a severe course (> 1 episode). Some researchers argue that initial MDD episodes are associated with increased amygdala volume that decreases following repeated episodes (McEwen, 2003; Merz et al., 2018). A risk-enriched longitudinal study of adolescents (Whittle et al., 2014) found that first-episode MDD was associated with attenuated reduction in putamen volume over four years, with attenuated growth of the hippocampus in males and accelerated growth of the amygdala in females. Whittle et al. suggested these abnormal developments may represent a vulnerability for MDD, and reflect a departure from the normative pattern of development, both growth and volume reduction, potentially due to lack of synaptic pruning or myelination. Similarly, Muetzel et al. (2018) found that internalizing and externalizing problems were related to attenuated increases in subcortical volume in a non-clinical sample of 8-year-old children measured over two years. Thus, our results may reflect an alteration in the normal pattern of development of subcortical regions associated with StD.

Our study is the first to our knowledge to report positive associations between subthreshold depressive symptoms and subcortical volume and outward morphology in adolescents. However, antidepressant treatment has been reported to normalize reduced hippocampal volume in MDD (Arnone et al., 2013). Further, increases in basal ganglia volume and local outward increases of morphometry differentiate treatment responders to ECT from non-responders (Wade et al., 2016). Thus, it's possible the positive associations between StD and morphology reflect intact plasticity and neurogenesis, and/or resilience to depression.

The present study was cross-sectional, and such a design does not allow inferences about causality or developmental trajectories. Future longitudinal research is needed. We restricted our analysis to subcortical regions, and cortical regions also play a role in MDD and emotion regulation, and consistent with our results, research has reported increased cortical thickness in untreated MDD (Qiu et al., 2014). There is a lack of dimensional studies of StD examining subcortical volume and morphology; out of necessity our hypotheses had to be based on categorical studies comparing patients with StD or active MDD to healthy controls. An even greater lack of such studies in adolescents exists, and consequently we had to rely on adult literature, however, the participants in our study were 14 years of age and therefore still undergoing neurodevelopment of subcortical structures (Giedd et al., 2015). Studies of StD differ in their definition of StD, with some including participants who scored within a mid-range on questionnaire

measures of symptoms (Li et al., 2015, 2017), or who reported at least three of the DSM criteria (Vulser et al., 2015). Most similar to the present study, some included participants scoring anywhere within the full sub-clinical range (Spalletta et al., 2014). Thus, it's possible that our participants may have had less severity of depressive symptoms than some previous studies. Future RDoC-inspired studies like the present one will be useful to confirm our findings.

This is the first study to report primarily positive associations between StD, volume and outward morphology in youths. Future longitudinal research, ideally utilizing dimensional measures, will further our understanding of the neurobiology of StD.

Acknowledgements

This study was funded by NHLBI (PI: Miller) R01 HL122328, and funded in part by NIH grant R01 EBO20062, NSF grants 1734853 and 1636893. Supported by a NARSAD Young Investigator Grant from the Brain & Behavior Research Foundation, 24778.

Supplementary materials

Supplementary material associated with this article can be found, in the online version, at doi:10.1016/j.nicl.2020.102187.

References

- Arnone, D., McIntosh, A.M., Ebmeier, K.P., Munafo, M.R., Anderson, I.M., 2012. Magnetic resonance imaging studies in unipolar depression: systematic review and meta-regression analyses. *Eur. Neuropsychopharmacol.* 22, 1–16.
- Arnone, D., McKie, S., Elliott, R., Juhasz, G., Thomas, E.J., Downey, D., Williams, S., Deakin, J.F.W., Anderson, I.M., 2013. State-dependent changes in hippocampal grey matter in depression. *Mol. Psychiatry* 18, 1265–1272.
- Balazs, J., Miklosi, M., Keresztesy, A., Hoven, C.W., Carli, V., Wasserman, C., Apter, A., Bobes, J., Brunner, R., Cosman, D., Cotter, P., Haring, C., Iosue, M., Kaess, M., Kahn, J.P., Keeley, H., Marusic, D., Postuvan, V., Resch, F., Saiz, P.A., Sisask, M., Snir, A., Tubiana, A., Varnik, A., Sarchiapone, M., Wasserman, D., 2013. Adolescent sub-threshold-depression and anxiety: psychopathology, functional impairment and increased suicide risk. *J. Child Psychol. Psychiatry* 54, 670–677.
- Beg, M.F., Miller, M.I., Troune, A., Younes, L., 2005. Computing large deformation metric mappings via geodesic flows of diffeomorphisms. *Int. J. Comput. Vis.* 61, 139–157.
- Bora, E., Fornito, A., Pantelis, C., Yucel, M., 2012. Gray matter abnormalities in major depressive disorder: a meta-analysis of voxel based morphometry studies. *J. Affect. Disord.* 138, 9–18.
- Caetano, S.C., Fonseca, M., Hatch, J.P., Olvera, R.L., Nicoletti, M., Hunter, K., Lafer, B., Pliszka, S.R., Soares, J.C., 2007. Medial temporal lobe abnormalities in pediatric unipolar depression. *Neurosci. Lett.* 427, 142–147.
- Chen, M.C., Hamilton, J.P., Gotlib, I.H., 2010. Decreased hippocampal volume in healthy girls at risk of depression. *Arch. Gen. Psychiatry* 67, 270–276.
- Cole, J., Toga, A.W., Hojatkishani, C., Thompson, P., Costafreda, S.G., Cleare, A.J., Williams, S.C.R., Bullmore, E.T., Scott, J.L., Mitterschiffthaler, M.T., Walsh, N.D., Donaldson, C., Mirza, M., Marquand, A., Nosarti, C., McGuffin, P., Fu, C.H.Y., 2010. Subregional hippocampal deformations in major depressive disorder. *J. Affect. Disord.* 126, 272–277.
- Csernansky, J.G., Wang, L., Joshi, S.C., Ratnanather, J.T., Miller, M.I., 2004. Computational anatomy and neuropsychiatric disease: probabilistic assessment of variation and statistical inference of group difference, hemispheric asymmetry, and time-dependent change. *Neuroimage* 23, S56–S68.
- Dixon, W.J., 1960. Simplified estimation from censored normal samples. *Ann. Math. Stat.* 31, 385–391.
- Ebesutani, C., Reise, S., Chorpita, B.F., Ale, C., Regan, J., Young, J., Higa-McMillan, C., Weisz, J., 2012. The revised child anxiety depression Scale- short version: scale reduction via exploratory bifactor modeling of the broad anxiety factor. *Psychol. Assess.* 24, 833–845.
- Fergusson, D.M., Horwood, L.J., Ridder, E.M., Beautrais, A.L., 2005. Subthreshold depression in adolescence and mental health outcomes in adulthood. *Arch. Gen. Psychiatry* 62, 66–72.
- Frodl, T., Meisenzahl, E., Zetsche, T., Bottlender, R., Born, C., Groll, C., Jager, M., Leinsinger, G., Hahn, K., Moller, H.-J., 2002. Enlargement of the amygdala in patients with a first episode of major depression. *Biol. Psychiatry* 51, 708–714.
- Giedd, J.N., Raznahan, A., Alexander-Bloch, A., Schmitt, E., Gogtay, N., Rapoport, J.L., 2015. Child psychiatry branch of the national institute of mental health longitudinal structural magnetic resonance imaging study of human brain development. *Neuropsychopharmacology* 40, 43–49.
- Hamilton, J.P., Siemer, M., Gotlib, I.H., 2008. Amygdala volume in major depressive disorder: a meta-analysis of magnetic resonance imaging studies. *Mol. Psychiatry* 13, 993–1000.
- Hankin, B.L., Abramson, L.Y., Moffitt, T.E., Silva, P.A., McGee, R., Angell, K.E., 1998. Development of depression from preadolescence to young adulthood: emerging

- gender differences in a 10-year longitudinal study. *J. Abnorm. Psychol.* 107, 128–140.
- Isikli, S., Ugurlu, O., Durmusoglu, E., Kizilates, G., Kitis, O., Ozan, E., Eker, C., Coburn, K., Gonul, A.S., 2013. Altered hippocampal formation shape in first-episode depressed patients at 5-year follow-up. *J. Psychiatr. Res.* 47, 50–55.
- Kempton, M.J., Salvador, Z., Munafo, M.R., Geddes, J.R., Simmons, A., Frangou, S., Williams, S.C.R., 2011. Structural neuroimaging studies in major depressive disorder: meta-analysis and comparison with bipolar disorder. *Arch. Gen. Psychiatry* 68, 675–690.
- Kessler, R.C., McGonagle, K.A., Swartz, M., Blazer, D.G., Nelson, C.B., 1993. Sex and depression in the national comorbidity survey: 1. Lifetime prevalence, chronicity and recurrence. *J. Affect. Disord.* 29, 85–96.
- Khan, A.R., Wang, L., Beg, M.F., 2008. FreeSurfer-initiated fully-automated subcortical brain segmentation in MRI using large deformation diffeomorphic metric mapping. *Neuroimage* 41, 735–746.
- Koolschijn, P.C.M.P., van Haren, N.E.M., Lensvelt-Mulders, G.J.L.M., Hulshoff Pol, H.E., Kahn, R.S., 2009. Brain volume abnormalities in major depressive disorder: a meta-analysis of magnetic resonance imaging studies. *Hum. Brain Mapp.* 30, 3719–3735.
- Li, H.J., Wei, D.T., Sun, J.Z., Chen, Q.L., Zhang, Q.L., Qiu, J., 2015. Brain structural alterations associated with young women with subthreshold depression. *Scientific Reports* 5, 6.
- Li, J., Wang, Z.J., Hwang, J.W., Zhao, B.C., Yang, X.J., Xin, S.C., Wang, Y., Jiang, H.L., Shi, P., Zhang, Y., Wang, X., Lang, C., Park, J., Bao, T.Y., Kong, J., 2017. Anatomical brain difference of subthreshold depression in young and middle-aged individuals. *Neuroimage-Clin.* 14, 546–551.
- Lu, Y., Liang, H.M., Han, D., Mo, Y., Li, Z.F., Cheng, Y.Q., Xu, X.F., Shen, Z.L., Tan, C.Y., Zhao, W., Zhu, Y., Sun, X.J., 2016. The volumetric and shape changes of the putamen and thalamus in first episode, untreated major depressive disorder. *Neuroimage-Clin.* 11, 658–666.
- Lupien, S.J., McEwen, B.S., Gunnar, M.R., Heim, C., 2009. Effects of stress throughout the lifespan on the brain, behaviour and cognition. *Nat. Rev. Neurosci.* 10, 434–445.
- MacMaster, F.P., Kusumakar, V., 2004. Hippocampal Volume in Early Onset Depression 2 *BMC Medicine*.
- MacMaster, F.P., Mirza, Y., Szekes, P.R., Mkiecik, L.E., Easter, P.C., Taormina, S.P., Lynch, M., Rose, M., Moore, G.J., Rosenberg, D.R., 2008. Amygdala and hippocampal volumes in familial early onset major depressive disorder. *Biol. Psychiatry* 63, 385–390.
- MacMillan, S., Szekes, P.R., Moore, G.J., Madden, R., Lorch, E., Ivey, J., Banerjee, P., Rosenberg, D.R., 2003. Increased amygdala: hippocampal volume ratios associated with severity of anxiety in pediatric major depression. *J. Child Adolesc. Psychopharmacol.* 13, 65–73.
- Matsuo, K., Rosenberg, D.R., Easter, P.C., MacMaster, F.P., Chen, H.H., Nicoletti, M., Caetano, S.C., Hatch, J.P., Soares, J.C., 2008. Striatal volume abnormalities in treatment-naïve patients diagnosed with pediatric major depressive disorder. *J. Child Adolesc. Psychopharmacol.* 18, 121–131.
- McEwen, B.S., 2003. Mood disorders and allostatic load. *Biol. Psychiatry* 54, 200–207.
- McLaughlin, K.J., Baran, S.E., Conrad, C.D., 2009. Chronic stress- and sex-specific neuro-morphological and functional changes in limbic structures. *Mol. Neurobiol.* 40, 166–182.
- Merz, E.C., Tottenham, N., Noble, K.G., 2018. Socioeconomic status, amygdala volume, and internalizing symptoms in children and adolescents. *J. Clin. Child. Adolesc. Psychol.* 47, 312–323.
- Muetzel, R.L., Blanken, L.M.E., van der Ende, J., El Marroun, H., Shaw, P., Sudre, G., van der Lugt, A., Jaddoe, V.W.V., Verhulst, F.C., Tiemeier, H., White, T., 2018. Tracking brain development and dimensional psychiatric symptoms in children: a longitudinal population-based neuroimaging study. *Am. J. Psychiatry* 175, 54–62.
- Petersen, A.C., Crockett, L., Richards, M., Boxer, A., 1988. A self-report measure of pubertal status: reliability, validity, and initial norms. *J. Youth Adolesc* 17, 117–133.
- Pine, D.S., Cohen, E., Cohen, P., Brook, J., 1999. Adolescent depressive symptoms as predictors of adult depression: moodiness or mood disorder? *Am. J. Psychiatry* 156, 133–135.
- Posener, J.A., Wang, L., Price, J.L., Gado, M.H., Province, M.A., Miller, M.I., Babb, C.M., Csernansky, J.G., 2003. High-dimensional mapping of the hippocampus in depression. *Am. J. Psychiatry* 160, 83–89.
- Qiu, L., Lui, S., Kuang, W., Huang, X., Li, J., Li, J., Zhang, J., Chen, H., Sweeney, J.A., Gong, Q., 2014. Regional Increases of Cortical Thickness in Untreated, First-Episode Major Depressive Disorder 4. *Translational Psychiatry*, pp. 7.
- Ramezani, M., Johnsrude, L., Rasoulian, A., Bosma, R., Tong, R., Hollenstein, T., Harkness, K., Abolmaesumi, P., 2014. Temporal-lobe morphology differs between healthy adolescents and those with early-onset of depression. *Neuroimage-Clin.* 6, 145–155.
- Rosso, I.M., Cintron, C.M., Steingard, R.J., Renshaw, P.F., Young, A.D., Yurgelun-Todd, D.A., 2005. Amygdala and hippocampus volumes in pediatric major depression. *Biol. Psychiatry* 57, 21–26.
- Schmaal, L., Veltman, D.J., van Erp, T.G.M., Samann, P.G., Frodl, T., Jahanshad, N., Loehrer, E., Tiemeier, H., Hofman, A., Niessen, W.J., Vernooij, M.W., Ikram, M.A., Wittfeld, K., Grabe, H.J., Block, A., Hegenscheid, K., Volzke, H., Hoehn, D., Cizisch, M., Lagopoulos, J., Hatton, S.N., Hickie, I.B., Goya-Maldonado, R., Kramer, B., Gruber, O., Couvy-Duchesne, B., Renteria, M.E., Strike, L.T., Mills, N.T., de Zubicaray, G.I., McMahon, K.L., Medland, S.E., Martin, N.G., Gillespie, N.A., Wright, M.J., Hall, G.B., MacQueen, G.M., Frey, E.M., Carballedo, A., van Velzen, L.S., van Tol, M.J., van der Wee, N.J., Veer, I.M., Walter, H., Schnell, K., Schramm, E., Normann, C., Schoepf, D., Konrad, C., Zurovski, B., Nickson, T., McIntosh, A.M., Pappmeyer, M., Whalley, H.C., Sussmann, J.E., Godlewska, B.R., Cowen, P.J., Fischer, F.H., Rose, M., Penninx, B., Thompson, P.M., Hibar, D.P., W, E.N.-M.D.D., 2016. Subcortical brain alterations in major depressive disorder: findings from the enigma major depressive disorder working group. *Mol. Psychiatry* 21, 806–812.
- Shad, M.U., Muddasani, S., Rao, U., 2012. Gray matter differences between healthy and depressed adolescents: a voxel-based morphometry study. *J. Child Adolesc. Psychopharmacol.* 22, 190–197.
- Singh-Manoux, A., Marmot, M.G., Adler, N.E., 2005. Does subjective social status predict health and change in health status better than objective status? *Psychosom. Med.* 67, 855–861.
- Spalletta, G., Piras, F., Caltagirone, C., Fagioli, S., 2014. Hippocampal multimodal structural changes and subclinical depression in healthy individuals. *J. Affect. Disord.* 152, 105–112.
- van Eijndhoven, P., van Wingen, G., van Oijen, K., Rijpkema, M., Goraj, B., Verkes, R.J., Voshaar, R.O., Fernandez, G., Buitelaar, J., Tendolkar, I., 2009. Amygdala volume marks the acute state in the early course of depression. *Biol. Psychiatry* 65, 812–818.
- Vulser, H., Lemaître, H., Artiges, E., Miranda, R., Penttilä, J., Struve, M., Fadaï, T., Kappel, V., Grimmer, Y., Goodman, R., Stringaris, A., Poustka, L., Conrod, P., Frouin, V., Banaschewski, T., Barker, G.J., Bokde, A.L.W., Bromberg, U., Buchel, C., Flor, H., Gallinat, J., Garavan, H., Gowland, P., Heinz, A., Ittermann, B., Lawrence, C., Loth, E., Mann, K., Nees, F., Paus, T., Pausova, Z., Rietschel, M., Robbins, T.W., Smolka, M.N., Schumann, G., Martinot, J.L., Paillere-Martinot, M.L., Consortium, I., 2015. Subthreshold depression and regional brain volumes in young community adolescents. *J. Am. Acad. Child Adolesc. Psychiatry* 54, 832–840.
- Wade, B.S.C., Joshi, S.H., Njau, S., Leaver, A.M., Vasavada, M., Woods, R.P., Gutman, B.A., Thompson, P.M., Espinoza, R., Narr, K.L., 2016. Effect of electroconvulsive therapy on striatal morphometry in major depressive disorder. *Neuropsychopharmacology* 41, 2481–2491.
- Wang, L., Beg, F., Ratnanather, T., Ceritoglu, C., Younes, L., Morris, J.C., Csernansky, J.G., Miller, M.I., 2007. Large deformation diffeomorphism and momentum based hippocampal shape discrimination in dementia of the alzheimer type. *IEEE Trans. Med. Imaging* 26, 462–470.
- Wang, L., Miller, J.P., Gado, M.H., McKeel, D.W., Rothermich, M., Miller, M.I., Morris, J.C., Csernansky, J.G., 2006. Abnormalities of hippocampal surface structure in very mild dementia of the alzheimer type. *Neuroimage* 30, 52–60.
- Wang, W.N., Zhao, Y.J., Hu, X.Y., Huang, X.Q., Kuang, W.H., Lui, S., Kemp, G.J., Gong, Q. Y., 2017. Conjoint and dissociated structural and functional abnormalities in first-episode drug-naïve patients with major depressive disorder: a multimodal meta-analysis. *Scientific Reports* 7, 13.
- Watanabe, R., Kakeda, S., Watanabe, K., Liu, X.D., Katsuki, A., Umeno-Nakano, W., Hori, H., Abe, O., Yoshimura, R., Korogi, Y., 2017. Relationship between the hippocampal shape abnormality and serum cortisol levels in first-episode and drug-naïve major depressive disorder patients. *Depress. Anxiety* 34, 401–409.
- Webb, C.A., Weber, M., Mundy, E.A., Kilgore, W.D.S., 2014. Reduced gray matter volume in the anterior cingulate, orbitofrontal cortex and thalamus as a function of mild depressive symptoms: a voxel-based morphometric analysis. *Psychol. Med.* 44, 2833–2843.
- Whittle, S., Lichter, R., Dennison, M., Vijayakumar, N., Schwartz, O., Byrne, M.L., Simmons, J.G., Yucel, M., Pantelis, C., McGorry, P., Allen, N.B., 2014. Structural brain development and depression onset during adolescence: a prospective longitudinal study. *Am. J. Psychiatry* 171, 564–571.
- Yuksel, D., Engelen, J., Schuster, V., Dietsche, B., Konrad, C., Jansen, A., Dannlowski, U., Kircher, T., Krug, A., 2018. Longitudinal brain volume changes in major depressive disorder. *J. Neural Transm.* 125, 1433–1447.
- Zunszain, P.A., Anacker, C., Cattaneo, A., Carvalho, L.A., Pariante, C.M., 2011. Glucocorticoids, cytokines and brain abnormalities in depression. *Prog. Neuropsychopharmacol. Biol. Psychiatry* 35, 722–729.