

## Overview on coinfection of HTLV-1 and tuberculosis: Mini-review

Masoud Keikha<sup>a,b</sup>, Mohsen Karbalaei<sup>c,\*</sup>

<sup>a</sup> Department of Microbiology and Virology, Faculty of Medicine, Mashhad University of Medical Sciences, Mashhad, Iran

<sup>b</sup> Student Research Committee, Mashhad University of Medical Sciences, Mashhad, Iran

<sup>c</sup> Department of Microbiology and Virology, School of Medicine, Jiroft University of Medical Sciences, Jiroft, Iran

### ARTICLE INFO

#### Keywords:

ATLL  
HAM/TSP  
HTLV-1  
Iran  
*Mycobacterium tuberculosis*  
Tuberculosis

### ABSTRACT

Human T-cell leukemia virus type 1 (HTLV-1) is one of the human retroviruses that causes various complications in humans, including lymphoma. *Mycobacterium tuberculosis* (*Mtb*), on the other hand, is a causative agent of tuberculosis (TB), a deadly infectious disease. According to the literature, patients infected with HTLV-1 are prone to TB due to lack of regulation in the immune system. In the present study, we discussed the association between previous HTLV-1 infection and TB susceptibility. We also reviewed the histopathological findings of respiratory involvement following HTLV-1 infection and the management of this infection.

### 1. Introduction

Among infectious diseases, tuberculosis (TB) is one of the ten leading causes of death in the world. According to the World Health Organization (WHO) report, in 2019 there were about 10 million cases of TB and 1.2 million deaths among HIV-negative people [1]. Overall, one-third of the world's population is infected with *Mycobacterium tuberculosis* (*Mtb*) as latent TB infection (LTBI) cases [2]. Although most LTBI patients have no clinical symptoms during their lifetime, about 5–10% of them will progress to active TB [3].

After *Mtb* enters the lungs, four categories are predictable for its fate including; 1) immediate clearance of *Mtb* from lungs, 2) active TB caused by replication of tubercle bacilli in the human's body, 3) LTBI which is characterized by the formation of granulomas due to immune-response to prevent bacteria from replicating and spreading in the body, 4) reactivation of LTBI that occurs during decreased immune response activity (Fig. 1) [4,5].

### 2. Progression of LTBI to active TB

#### 2.1. LTBI phase

LTBI is a specific stage of infection that shows the balance between the microbe and the host immune response. In the LTBI phase, intracellular growth of *Mtb* is reduced by immune cells especially Th1, Th17, CTLs, B cells, as well as cytokines such as IFN- $\gamma$ , TGF- $\beta$  or IL-1 $\beta$  [6,7].

Depending on the host epigenetic events, excessive secretion of cytokines such as IFN- $\gamma$ , TNF- $\alpha$ , and IL-1 $\beta$  can cause tissue damage resulting in active proliferation of *Mtb* [8,9].

#### 2.2. Predisposing factors for the activation of latent TB

Progression of TB from the states of latent phase mode to active TB is more common among the patients with underlying conditions such as cancer, diabetes, immunodeficiency, transplantation, as well as in patients infected with viruses such as HIV or HTLV-1 [10]. Studies show that dysregulation of the immune response in HTLV-1-infected patients is considered a hallmark for LTBI progressing to active TB infection; during infection with the virus, T regulatory (T reg) cells increase, while *Mtb* inhibitory cell lines such as Mucosal-associated invariant T (MAIT) cells and Invariant natural killer T (iNKT) cells decrease [11–15].

### 3. Coinfection of TB and HTLV-1

#### 3.1. HTLV-1

HTLV-1 was first identified by Poiesz et al. in a patient with cutaneous T cell lymphoma (CTCL) in the United States [16]. HTLV-1 is a type C Retrovirus (Deltaretrovirus) and is prevalent in various regions including Japan, Africa, Latin America, the Caribbean, and the Middle East, especially Iran [17]. Approximately 5–10 million people worldwide are infected with HTLV-1; of these 90–95% of infected persons live

\* Corresponding author.

E-mail address: [mohsen.karbalaei@jmu.ac.ir](mailto:mohsen.karbalaei@jmu.ac.ir) (M. Karbalaei).

<https://doi.org/10.1016/j.jctube.2021.100224>

asymptomatic carriers (ACs), but 2–6% of them develop to Adult T-cell leukemia/lymphoma (ATLL) as well as 2–3% progress to HTLV-1-associated myelopathy/tropical spastic paraparesis (HAM/TSP) [18]. HTLV-1 is transmitted in a variety of ways such as unsafe sexual contact, injection, blood transfusion, congenital, and breastfeeding [19].

### 3.2. HTLV-1 and TB

HTLV-1 is a successful intracellular pathogens that provides persistent infection due to its ability to attack the immune response. Several strategies for persistent HTLV-1 infection include; I) inhibition of IRF3 by SOCS1, II) clonal proliferation of T reg cells, III) over-expression of surface molecules (e.g. FasL, KIR2DL2, CADM1 or CCL22), and IV) infection of CD4 + T cells [20]. In addition, HTLV-1 is transmitted throughout cell-cell contacts and causes a variety of disorders during the course of infection including uveitis, infective dermatitis, arthritis, lymphadenitis, polymyositis, Sjogren syndrome, and bronchiolitis [20,21]. In general, it seems that the previous HTLV-1 infection may make the host susceptible to infectious diseases such as TB [14]. Based on the evidence in the present study, we discussed the role of HTLV-1 infection in the pathogenesis of *Mtb*.

### 3.3. Global statistics about the TB and HTLV-1 coinfection

According to Grassi et al. study, there is a significant relationship between co-infection with HTLV-1 and *Mtb* in areas where these infectious pathogens are endemic. They showed that the incidence of TB in patients with HTLV-1 was 3.3 per 1000 cases, while the incidence of TB in healthy individuals was 1.1 per 1000 cases [14]. In another study, Pedral-Sampaio et al. reported that 8.5% of HTLV-1-infected patients were also infected with TB [22]. In their study, Bastos et al. reported that 10% of TB patients were also infected with HTLV-1 [23].

Studies show that people infected with HTLV-1 are also unable to produce TNF- $\alpha$ , so they are more likely to develop TB [23]. Verdonck et al. showed that TB mortality was higher in HTLV-1 infected individuals than in healthy ones [24]. Based on studies, the immune response to *Mtb* antigens is suppressed in these patients; in accordance with this theory, Tachibana et al. found that the Mantoux test was

negative in asymptomatic HTLV-1 individuals [25]. Moreover, Mascarenhas et al. have shown that Polymorphonuclear leukocytes (PMNs) of HTLV-1-infected individuals were unable to migrate to the PPD injection site [26]. It is suggested that the HTLV-1 infection can cause a 2–4-fold increase in progression to TB infection [27].

### 3.4. Immunological characteristics in HTLV-1 infection

HTLV-1 infection leads to activation of CD4 + T cells, resulting in spontaneous lymph proliferation and overexpression of cytokines; HAM/TSP patients have high levels of proinflammatory cytokines such as IL-4, IL-6, IL-8, IFN- $\gamma$ , MIP1 $\alpha$ , TNF- $\alpha$ , as well as in ATLL patients the expression of IL-2, TGF- $\beta$ , IL13, IL-15 leads to activation of NF- $\kappa$ B signaling pathway [28,29]. Moreover, Souza et al. confirmed that there was a significant overexpression of IFN $\gamma$ /IL-10 and TNF/IL-10 ratios in HAM/TSP patients with TB compared to non-TB patients [30]. However, it is not yet clear how HTLV-1-infected individuals are susceptible to *Mtb*, whereas there is overexpression of cytokines in their activated T cells.

In general, there are several immunologic events in HTLV-1-infected people that increase their susceptibility to TB including; 1) impairment of TNF- $\alpha$  production, 2) impairment of IL-1 $\beta$  and IL-17 production, 3) increasing in the number of T reg cells 4) overexpression of TGF- $\beta$  production, 5) malfunction of HTLV-1-infected lymphocytes (Fig. 2/ Table 1) [23,28–33].

### 3.5. TB in facing with all features of HTLV-1

Kawabata et al. showed that HTLV-1 was isolated from Bronchoalveolar lavage (BAL) samples specimens in HTLV-1-infected individuals (HAM/TSP and asymptomatic carriers) [31]. Clinical findings showed that the total number of pulmonary lymphocytes (Th1, CTLs, and T reg cells) is higher in these patients than healthy individuals [32,33]. Teruya et al. observed overexpression of ICAM-1, cytokines (IL-1 $\alpha$ , IL-1, IL-6, IL-8, and TNF), and chemokines (MIP-1 $\alpha$ , IP-10, CCL2, and CCL5) in PMNs of HTLV-1-infected cases with pulmonary complications [34]. Therefore, we conclude that HTLV-1 can alter the nature of pulmonary involvement, especially in TB pathogenesis (Table 1) [33–35].

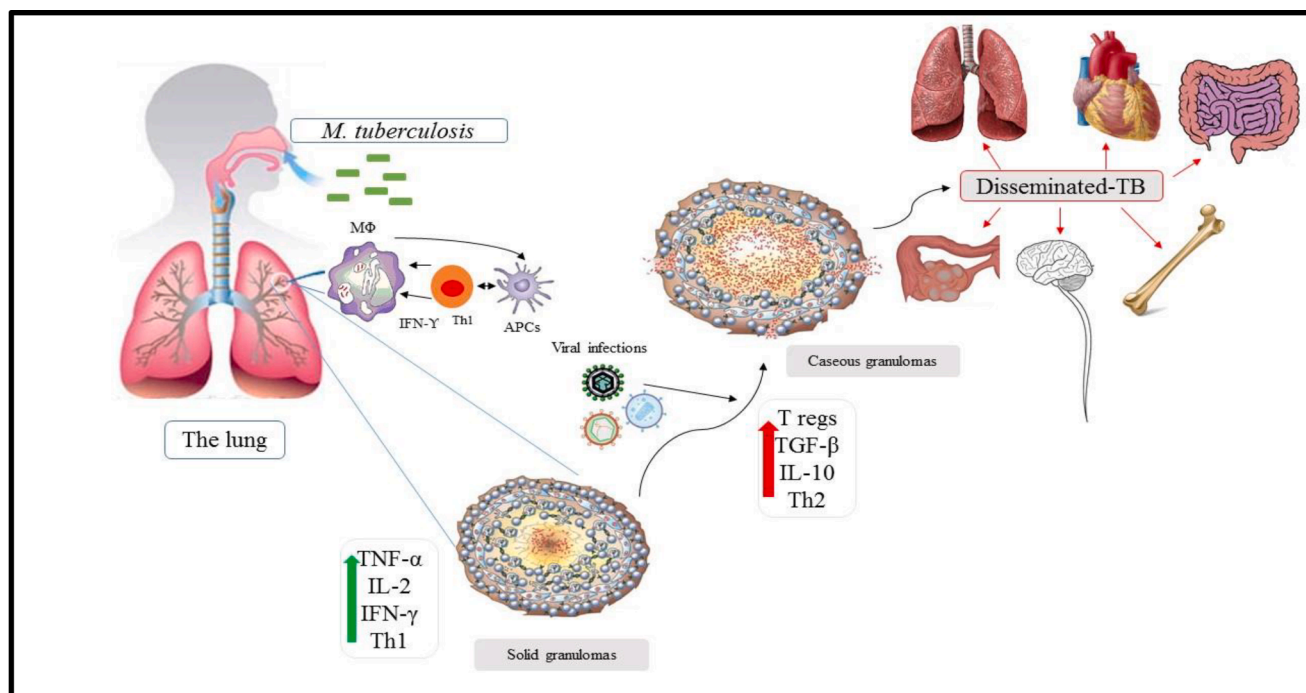


Fig. 1. Different outcomes of tuberculosis infection. This figure is inferred from Khademi et al. study.

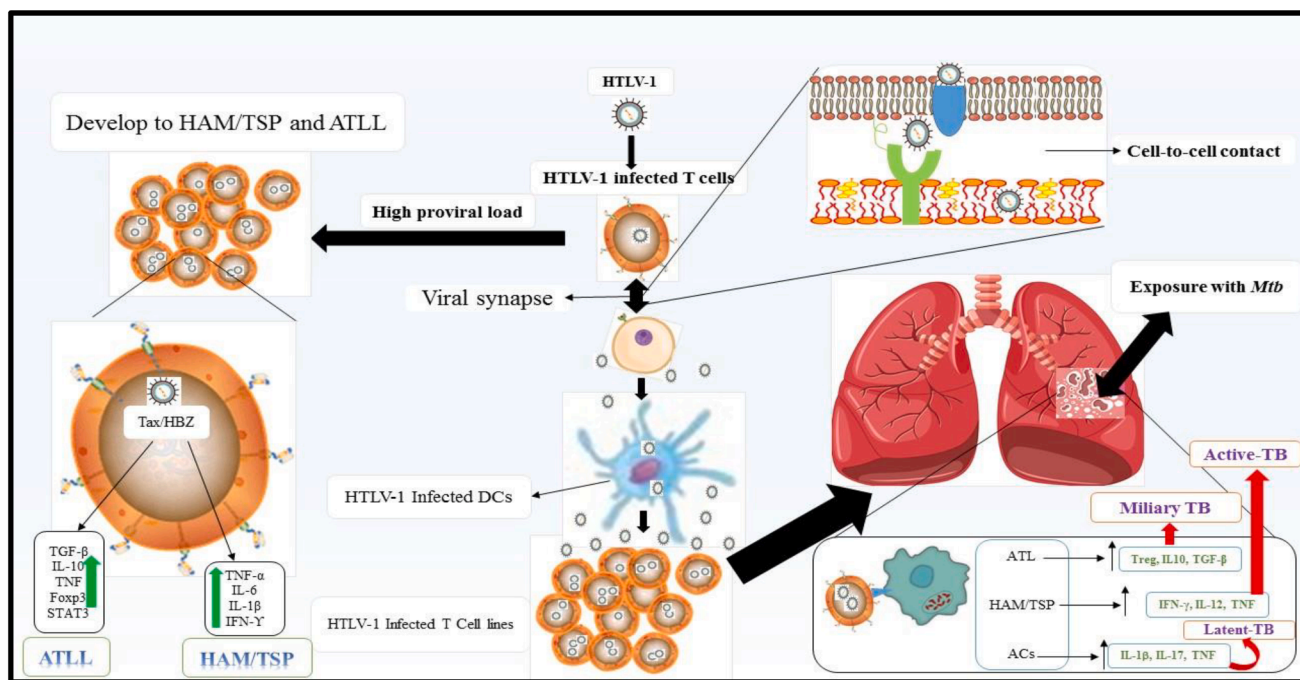


Fig. 2. The role of immune system for the pathogenesis of HTLV-1/Tuberculosis coinfection. This figure was inferred from Dias et al. studies.

Table 1  
Possible mechanisms for TB among –1-infected subjects.

HTLV-1 infection	Immune-response	Significant change	TB outcome	Computed tomography	Ref
HAM/TSPs	IFN-γ, IL-2, IL-12, IP-10 and MIP-1α and CTLs	Exaggerate Immune-response and damage tissue	Active TB	Granuloma formation, Cavitation, irregular linear opacity, centrilobular nodules	[34]
ATLLs	IL-10, TGF-β and CD25 + T regulatory cells	Suppression of immune-response against TB	Miliary TB Active TB Opportunistic infections	Varies from cavitation to no visible symptoms	[38]
ACs	TNF-α, IL-1β, Th17 and Th17	No significant symptoms, and dependent on epigenetic events	Active TB Latent TB	Granuloma formation, nodular patch	[39]

In addition, chest radiographic findings show similarities in the histopathological features of lung infection in both HTLV-1 and *Mtb* pathogens. According to related studies, these histopathological damages include parenchymal destruction, lymphatic infiltration, centrilobular nodules, bronchovascular patches, irregular linear opacities, cavity, and bronchiectasis [33,36,37].

Almost 40 years after the discovery of the virus, there is no effective and selective treatment for HTLV-1 infections [6,40]. Currently, one of the major concerns about HTLV-1 infection is the lack of selective anti-HTLV-1 drugs [18]. Typically, HTLV-1-infected patients are treated with zidovudine (AZT) plus IFN-α [41]. Nucleoside/nucleotide reverse transcriptase inhibitors (NRTIs) against HTLV-1 include zidovudine, (AZT), emtricitabine (FTC), didanosine (ddI), lamivudine (3TC), stavudine (d4T), abacavir (ABC), zalcitabine (ddC), and tenofovir (TDF); because rifampin interferes with NRTI, it is not recommended for cases of retrovirus infection [18,42]. Therefore, the management or treatment of pulmonary TB in patients infected with HTLV-1 is associated with many challenges. Therefore, it is necessary to establish programs to control HTLV-1 infections, such as screening blood products for HTLV-1, preventing breastfeeding of HTLV-1-infected mothers, and safe sexual contact [43].

#### 4. Conclusion

TB is a predictable disease among people infected with HTLV-1, and the main study during clinical trials should be conducted in developing countries where the prevalence of both infections is high. Importantly, this coinfection can be associated with high mortality. Therefore, careful monitoring, especially in cases of negative PPD, should be considered as prevention with isoniazid. However, the best solutions to this problem should be low cost and possible for TB in endemic areas.

#### Ethical statement

This manuscript is a mini review, and based on scientific databases such as Google Scholar, PubMed, Scopus, tec.

#### Declaration of Competing Interest

The authors declare that they have no known competing financial interests or personal relationships that could have appeared to influence the work reported in this paper.

#### References

[1] Organization WH. Global tuberculosis report 2020. Global tuberculosis report 2020.2020.

- [2] Keikha M, Soleimanpour S, Eslami M, Yousefi B, Karbalaei M. The mystery of tuberculosis pathogenesis from the perspective of T regulatory cells. *Meta Gene* 2020;23:100632. <https://doi.org/10.1016/j.mgene.2019.100632>.
- [3] Organization WH. Latent tuberculosis infection: updated and consolidated guidelines for programmatic management. World Health Organization; 2018.
- [4] Khademi F, Derakhshan M, Yousefi-Avarvand A, Tafaghodi M, Soleimanpour S. Multi-stage subunit vaccines against Mycobacterium tuberculosis: an alternative to the BCG vaccine or a BCG-prime boost? *Expert Rev Vaccines* 2018;17(1):31–44.
- [5] Houben RM, Dodd PJ. The global burden of latent tuberculosis infection: a re-estimation using mathematical modelling. *PLoS Med* 2016;13:e1002152.
- [6] Mortaz E, Adcock IM, Tabarsi P, Masjedi MR, Mansouri D, Velayati AA, et al. Interaction of pattern recognition receptors with Mycobacterium tuberculosis. *J Clin Immunol* 2015;35(1):1–10.
- [7] Toulza F, Tsang L, Ottenhoff THM, Brown M, Dockrell HM. Mycobacterium tuberculosis-specific CD4+ T-cell response is increased, and Treg cells decreased, in anthelmintic-treated patients with latent TB. *Eur J Immunol* 2016;46(3):752–61.
- [8] Ahmad S. Pathogenesis, immunology, and diagnosis of latent Mycobacterium tuberculosis infection. *Clin Dev Immunol* 2011;2011:1–17.
- [9] Scordo JM, Knoell DL, Torrelles JB. Alveolar epithelial cells in Mycobacterium tuberculosis infection: active players or innocent bystanders? *J Innate Immun* 2016;8(1):3–14.
- [10] Marinho J, Galvao-Castro B, Rodrigues LC, Barreto ML. Increased risk of tuberculosis with human T-lymphotropic virus-1 infection: a case-control study. *JAIDS J Acquired Immun Def Syndromes* 2005;40:625–8.
- [11] Montes M, Sanchez C, Verdonck K, Lake JE, Gonzalez E, Lopez G, et al. Regulatory T cell expansion in HTLV-1 and strongyloidiasis co-infection is associated with reduced IL-5 responses to Strongyloides stercoralis antigen. *PLoS Negl Trop Dis* 2009;3:e456.
- [12] Azakami K, Sato T, Araya N, Utsunomiya A, Kubota R, Suzuki K, et al. Severe loss of invariant NKT cells exhibiting anti-HTLV-1 activity in patients with HTLV-1-associated disorders. *Blood J Am Soc Hematol* 2009;114:3208–15.
- [13] Paquin-Proulx D, Greenspun BC, Costa EA, Segurado AC, Kallas EG, Nixon DF, et al. MAIT cells are reduced in frequency and functionally impaired in human T lymphotropic virus type 1 infection: Potential clinical implications. *PLoS One* 2017;12:e0175345.
- [14] Grassi MFR, dos Santos NP, Lírio M, Kritski AL, Chagas Almeida MdC, Santana LP, et al. Tuberculosis incidence in a cohort of individuals infected with human T-lymphotropic virus type 1 (HTLV-1) in Salvador, Brazil. *BMC Infect Dis* 2016;16(1). <https://doi.org/10.1186/s12879-016-1428-z>.
- [15] Keikha M, Shabani M, Navid S, Sadegh Ehdaei B, Karbalaei Zadeh Babaki M. What is the role of "T reg Cells" in tuberculosis pathogenesis? *Ind J Tuberculosis* 2018;65(4):360–2.
- [16] Poesz BJ, Ruscetti FW, Gazdar AF, Bunn PA, Minna JD, Gallo RC. Detection and isolation of type C retrovirus particles from fresh and cultured lymphocytes of a patient with cutaneous T-cell lymphoma. *Proc Natl Acad Sci* 1980;77(12):7415–9.
- [17] Rafatpanah H, Rezaee A, Etemadi MM, Hosseini RF, Khorram B, Afsahr L, et al. The impact of interferon-alpha treatment on clinical and immunovirological aspects of HTLV-1-associated myelopathy in northeast of Iran. *J Neuroimmunol* 2012;250(1–2):87–93.
- [18] Soltani A, Hashemy SI, Zahedi Avval F, Soleimani A, Rafatpanah H, Rezaee SA, et al. Molecular targeting for treatment of human T-lymphotropic virus type 1 infection. *Biomed Pharmacother* 2019;109:770–8.
- [19] Bertazzoni U, Ciminale V, Romanelli MG. Molecular pathology of HTLV-1. *Front Microbiol* 2018;9:3069.
- [20] Bangham CRM. Human T cell leukemia virus type 1: persistence and pathogenesis. *Annu Rev Immunol* 2018;36(1):43–71.
- [21] Gross C, Thoma-Kress A. Molecular mechanisms of HTLV-1 cell-to-cell transmission. *Viruses* 2016;8(3):74. <https://doi.org/10.3390/v8030074>.
- [22] Pedral-Sampaio DB, Martins NE, Pedrosa C, Brites C, Duarte M, Harrington Jr W. Co-infection of tuberculosis and HIV/HTLV retroviruses: frequency and prognosis among patients admitted in a Brazilian Hospital. *Braz J Infect Dis Official Publ Braz Soc Infect Dis* 1997;1:31.
- [23] Bastos MdL, Santos SB, Souza A, Finkmoore B, Bispo O, Barreto T, et al. Influence of HTLV-1 on the clinical, microbiologic and immunologic presentation of tuberculosis. *BMC Infect Dis* 2012;12(1). <https://doi.org/10.1186/1471-2334-12-199>.
- [24] Verdonck K, Gonzalez E, Henostroza G, Nabeta P, Llanos F, Cornejo H, et al. HTLV-1 infection is frequent among out-patients with pulmonary tuberculosis in northern Lima, Peru. *Int J Tuberc Lung Dis* 2007;11:1066–72.
- [25] Tachibana N, Okayama A, Ishizaki J, Yokota T, Shishime E, Murai K, et al. Suppression of tuberculin skin reaction in healthy HTLV-I carriers from Japan. *Int J Cancer* 1988;42(6):829–31.
- [26] Mascarenhas RE, Brodskyn Cláudia, Barbosa G, Cláudio J, Andrade-Filho AS, Figueiroa F, et al. Peripheral blood mononuclear cells from individuals infected with human T-cell lymphotropic virus type 1 have a reduced capacity to respond to recall antigens. *Clin Vaccine Immunol* 2006;13(5):547–52.
- [27] Carvalho NB, de Lourdes Bastos M, Souza AS, Netto EM, Arruda S, Santos SB, et al. Impaired TNF, IL-1 $\beta$ , and IL-17 production and increased susceptibility to Mycobacterium tuberculosis infection in HTLV-1 infected individuals. *Tuberculosis* 2018;108:35–40.
- [28] Futsch N, Prates G, Mahieux R, Casse J, Dutartre H. Cytokine networks dysregulation during HTLV-1 infection and associated diseases. *Viruses* 2018;10(12):691. <https://doi.org/10.3390/v10120691>.
- [29] Yamagishi M, Watanabe T. Molecular hallmarks of adult T cell leukemia. *Front Microbiol* 2012;3:334.
- [30] Souza A, Carvalho N, Neves Y, Braga Santos S, Bastos MdL, Arruda S, et al. Association of tuberculosis status with neurologic disease and immune response in HTLV-1 infection. *AIDS Res Hum Retroviruses* 2017;33(11):1126–33.
- [31] Kawabata T, Higashimoto I, Takashima H, Izumo S, Kubota R. Human T-lymphotropic virus type I (HTLV-I)-specific CD8+ cells accumulate in the lungs of patients infected with HTLV-I with pulmonary involvement. *J Med Virol* 2012;84(7):1120–7.
- [32] Sugimoto M, Nakashima H, Watanabe S, Uyama E, Tanaka F, Ando M, et al. T-lymphocyte alveolitis in HTLV-I-associated myelopathy. *Lancet* 1987;330(8569):1220. [https://doi.org/10.1016/S0140-6736\(87\)91362-6](https://doi.org/10.1016/S0140-6736(87)91362-6).
- [33] Dias A, Falcão LF, Falcão AS, Normando VM, Quaresma JA. Human T lymphotropic virus and pulmonary diseases. *Front Microbiol* 2018;9:1879.
- [34] Teruya H, Tomita M, Senba M, Ishikawa C, Tamayose M, Miyazato A, et al. Human T-cell leukemia virus type I infects human lung epithelial cells and induces gene expression of cytokines, chemokines and cell adhesion molecules. *Retrovirology* 2008;5(1):86. <https://doi.org/10.1186/1742-4690-5-86>.
- [35] de Lourdes BM, Osterbauer B, Mesquita DL, Carrera CA, Albuquerque MJ, Silva L, et al. Prevalence of human T-cell lymphotropic virus type 1 infection in hospitalized patients with tuberculosis. *Int J Tuberc Lung Dis* 2009;13:1519–23.
- [36] Tateishi U, Nishihara H, Miyasaka K. HTLV-1-associated bronchopneumopathy (HAB): CT-pathological correlation. *Clin Radiol* 2001;56(8):664–6.
- [37] Honarbakhsh S, Taylor GP. High prevalence of bronchiectasis is linked to HTLV-1-associated inflammatory disease. *BMC Infect Dis* 2015;15:258.
- [38] Taylor GP, Matsuoka M. Natural history of adult T-cell leukemia/lymphoma and approaches to therapy. *Oncogene* 2005;24(39):6047–57.
- [39] Starling ALB, Coelho-dos-Reis JGA, Peruhype-Magalhães V, Pascoal-Xavier MA, Gonçalves DU, Béla SR, et al. Immunological signature of the different clinical stages of the HTLV-1 infection: establishing serum biomarkers for HTLV-1-associated disease morbidity. *Biomarkers* 2015;20(6-7):502–12.
- [40] Tagaya Y. A-109 A novel multi-cytokine inhibitory strategy in treating HTLV-1 diseases. *JAIDS J Acquired Immun Deficiency Syndromes* 2019;81:35.
- [41] Marino-Merlo F, Balestrieri E, Matteucci C, Mastino A, Grelli S, Macchi B. Antiretroviral therapy in HTLV-1 Infection: an updated overview. *Pathogens* 2020;9(5):342. <https://doi.org/10.3390/pathogens9050342>.
- [42] Pedral-Sampaio DB, Alves CR, Netto EM, Brites C, Oliveira AS, Badaro R. Efficacy and safety of efavirenz in HIV patients on rifampin for tuberculosis. *Braz J Infect Dis* 2004;8(3):211–6.
- [43] Gonçalves DU, Proietti FA, Ribas JGR, Araújo MG, Pinheiro SR, Guedes AC, et al. Epidemiology, treatment, and prevention of human T-cell leukemia virus type 1-associated diseases. *Clin Microbiol Rev* 2010;23:577–89.