

Meta-analysis of the effect of posterior mucosal flap anastomosis in primary external dacryocystorhinostomy

Amal A Bukhari

Ophthalmology Department,
King Abdulaziz University Hospital,
Jeddah, Saudi Arabia

Purpose: We aimed to compare the outcomes of primary external dacryocystorhinostomy and silicone tube with anterior and posterior mucosal flap anastomosis, versus dacryocystorhinostomy and silicone intubation with anterior mucosal flap anastomosis.

Methods: We utilized the electronic databases PubMed, EMBASE, Ovid, Cochrane Central Register of Controlled Trials, and MEDLINE® to find articles related to external dacryocystorhinostomy. For inclusion in this meta-analysis, we isolated prospective and retrospective comparative studies of adult patients with acquired nasolacrimal duct obstruction, or chronic dacryocystitis, who had undergone primary external dacryocystorhinostomy and silicone intubation with anterior and posterior flap anastomosis; versus primary dacryocystorhinostomy and silicone intubation with anterior flap anastomosis. The minimum follow-up period for each study was 4 months.

Results: We identified and analyzed seven studies. Overall, dacryocystorhinostomy with anterior and posterior flap anastomosis was performed on 368 eyes, while primary external dacryocystorhinostomy with anterior flap anastomosis was performed on 397 eyes. There was no significant difference in the success rates of both techniques (risk ratio: 0.987; 95% confidence interval 0.946–1.030).

Conclusion: For patients with acquired nasolacrimal duct obstruction or chronic dacryocystitis, there was no significant difference in the resolution of epiphora, and patency of the lacrimal system, between those who underwent external dacryocystorhinostomy with anterior and posterior mucosal flap anastomosis, and those who had dacryocystorhinostomy with anterior flap anastomosis.

Keywords: dacryocystorhinostomy, external, mucosal flap, osium, success rate

Introduction

External dacryocystorhinostomy (DCR) is the “gold standard” technique for treatment of acquired nasolacrimal duct obstruction. Scarring within the anastomosis is known to be the main reason for failure, in both primary and reoperative cases.^{1–5} Healing with primary intention, from careful end-to-end anastomoses of both anterior and posterior flaps, is considered a vital step in preventing massive granulation and fibrosis, one of the causes of failure of the procedure.⁶ However, because it can be technically difficult and time-consuming to suture the flaps, researchers have investigated the validity of the procedure, and its effect on final success rates. Several flap designs have been proposed during the last decade;^{7–10} the most commonly-studied design is total excision of the posterior flaps, and suturing of the anterior flaps. Given that statistical power increases when the results of many trials are combined through meta-analysis, this study was

Correspondence: Amal A Bukhari
Ophthalmology Department, King
Abdulaziz University Hospital,
PO Box 80215, Jeddah 21589,
Saudi Arabia
Tel +966 2640 2888
Fax +966 2640 8349
Email aabukhari@kau.edu.sa

conducted to compare the outcomes of primary external DCR and silicone tube with anterior and posterior flap mucosal anastomosis, versus DCR dacryocystorhinostomy and silicone intubation with anterior mucosal flap anastomosis.

Method

Literature search

The electronic databases PubMed, EMBASE, Ovid, Cochrane Central Register of Controlled Trials, and MEDLINE® were searched for articles related to external DCR that were published between January 1960 and June 2013. Search terms included: dacryocystorhinostomy, DCR, nasolacrimal duct obstruction, dacryocystitis, anterior flaps, posterior flaps, and mucosal flaps. The search included only studies published in the English language. Two raters independently read the titles of all articles, and relevant abstracts were evaluated. The full article was retrieved if the title, abstract, or both met the objective of this review. Reference lists, obtained from the original reports and review articles that were retrieved through the search, were reviewed, to identify additional studies not yet included in the databases. Only studies that were agreed relevant by both raters were included in this meta-analysis.

Study inclusion criteria

1. **Design:** Prospective, and retrospective, comparative studies.
2. **Population:** Adult patients with confirmed diagnoses of acquired nasolacrimal duct obstruction, or chronic dacryocystitis.
3. **Intervention:** Primary external DCR and silicone intubation with anterior and posterior mucosal flap anastomosis, versus primary DCR and silicone intubation with anterior flap anastomosis.
4. **Follow up duration:** 4 months, minimum.
5. **Outcome measure:** Success rates of each group, based on subjective report of resolution of epiphora and lacrimal drainage system patency, confirmed by lacrimal irrigation.

Quality assessment of retrieved articles

We assessed the included studies for allocation concealment, randomization methods, masking during outcome measurement, completeness of follow-up, and detailed information on study dropouts.

Statistical analysis

Statistical analysis was carried out using Comprehensive Meta-Analysis Version 2 software (Biostat Inc,

Englewood, NJ, USA). A pooled risk ratio was calculated, with 95% confidence interval. A random effects model was used for analysis. A *P*-value <0.05 was considered statistically significant. A funnel plot was also constructed, to determine publication bias.

Surgical technique

The surgical techniques were generally consistent, with minor variation in different studies. A blunt dissection was performed through the orbicularis oculi muscle, down to the periosteum, shortly after making a skin incision. Periosteal incision is done anterior to the anterior lacrimal crest, and elevated with a periosteal elevator, to expose the lacrimal sac fossa. An osteotomy of approximately 15 mm × 15 mm is performed with a Kerrison punch, and then horizontal and vertical incisions are made, to create an anterior and posterior lacrimal sac and nasal mucosal flaps, or an anterior flap only. Next, a bicanalicular silicone tube is inserted.

Patients were randomized into two groups. In Group A, posterior and anterior flaps were separately sutured, with two interrupted polyglycolic acid sutures. In Group B, both posterior flaps were fashioned by total excision, and the anterior flaps were sutured with interrupted sutures. In patients who had only anterior flap anastomosis, the anastomoses were fashioned with interrupted sutures of the edges of both anterior flaps, followed by closure of the orbicularis and skin. All patients received postoperative steroid/antibiotic drops, and were followed-up for a minimum of 4 months. Surgical success was defined as resolution of epiphora and patent lacrimal irrigation.

Results

The literature search yielded 143 articles. Of these, we excluded 136 articles, after review, because they were either not relevant to the subject, or did not meet the inclusion criteria. The seven studies which fulfilled the inclusion criteria were single-centered studies, conducted with the intention of comparing success rates between primary external DCR with silicone intubation in patients who had anterior and posterior flap anastomosis, against DCR with silicone intubation in those who had anterior flap anastomosis and posterior flap excision.

The studies included a total of 780 patients. Of these, 368 had undergone DCR with anterior and posterior flap anastomosis, while 397 had undergone DCR with posterior and anterior flap anastomosis. Table 1 summarizes the characteristics of the studies.

Table 1 Summary of characteristics of included studies

Author	Country	Study design	Mean age (years)	Sample size			Mean follow up (months)	Outcome N (%)		
				Total	Both flaps	Ant only		Both flaps	Ant only	P-value
Katuwal et al ¹¹	Nepal	Prospective comparative study	44.2	83	43	40	13.5	39/43 (90.7)	35/40 (87.5)	0.73
Pandya et al ¹²	Australia	Retrospective chart review	NA	260	104	138	11	76/104 (73)	109/138 (79)	0.51
Elwan ⁹	Egypt	Prospective randomized comparative study	54.9	80	40	40	11.05	34/40 (85)	36/40 (90)	0.676
Turkcu et al ¹³	Turkey	Prospective comparative randomized	NA	160	79	85	12	71/79 (89.8)	76/85 (89.4)	<0.05
Khan et al ¹⁴	Pakistan	Prospective comparative study	NA	70	35	35	4	34/35 (97.1)	33/35 (94.3)	0.555
Baldeschi et al ⁸	The Netherlands	Prospective consecutive case series	46.8	64	35	29	11	34/35 (98)	29/29 (100)	0.429
Serin et al ¹⁵	Turkey	Randomized comparative	53.9	63	32	30	10.87	30/32 (93.75)	29/30 (96.67)	

Abbreviations: Ant, anterior; NA, not applicable.

Using the random effects model with “both: anterior only”, we found a risk ratio of 0.987 ($P=0.561$) (Figure 1). In addition, the funnel plot did not show asymmetry, thus excluding publication bias (Figure 2).

Discussion

The success of DCR depends on a properly sized and located patent, and mucosa-lined anastomosis between the lacrimal sac and the nose. Classically, this is achieved by creating an H-shaped incision in both the lacrimal sac and nasal mucosa, with end-to-end anastomosis of the anterior and posterior mucosal flaps. This step can be time-consuming, even among experienced surgeons, due to the deep location of the posterior flaps. As feasibility and surgical time are among essential factors determining the choice of the surgical approach, researchers have investigated the role of the posterior flaps in final success rates of DCR. Many of the

patients evaluated underwent DCR with total posterior flap excision.^{9,11–14}

Baldeschi et al⁸ studied the effect of the length of the unsutured mucosal margins on the success rate of external DCR; they did not detect any significant difference in success rates between patients who had a U-shaped anterior flap, followed by suturing of the anterior flaps and the posterior edge of the anteriorly-hinged mucosal flaps, patients who had an H-shaped flap with suturing of both flaps, and patients who had a U-shaped flap, with suturing of the anterior flaps (at 6-month follow-up). They concluded that the success rate of external DCR was not influenced by the length of the unsutured mucosal margins.

On the other hand, Pandya et al¹² compared the success rates of three different techniques, namely: external DCR with anterior flap anastomosis, with both anterior and posterior flap anastomosis, and with neither anterior nor

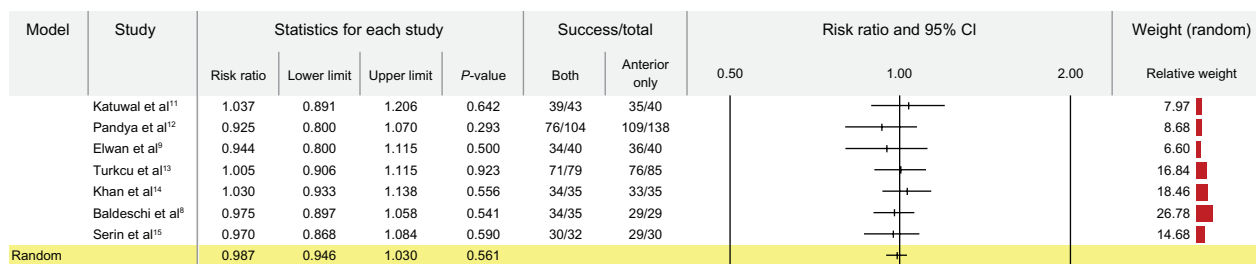


Figure 1 Random effect model for the success rate of dacryocystorhinostomy with anterior and posterior mucosal flap anastomosis versus dacryocystorhinostomy with anterior flap anastomosis only.

Abbreviation: CI, confidence interval.

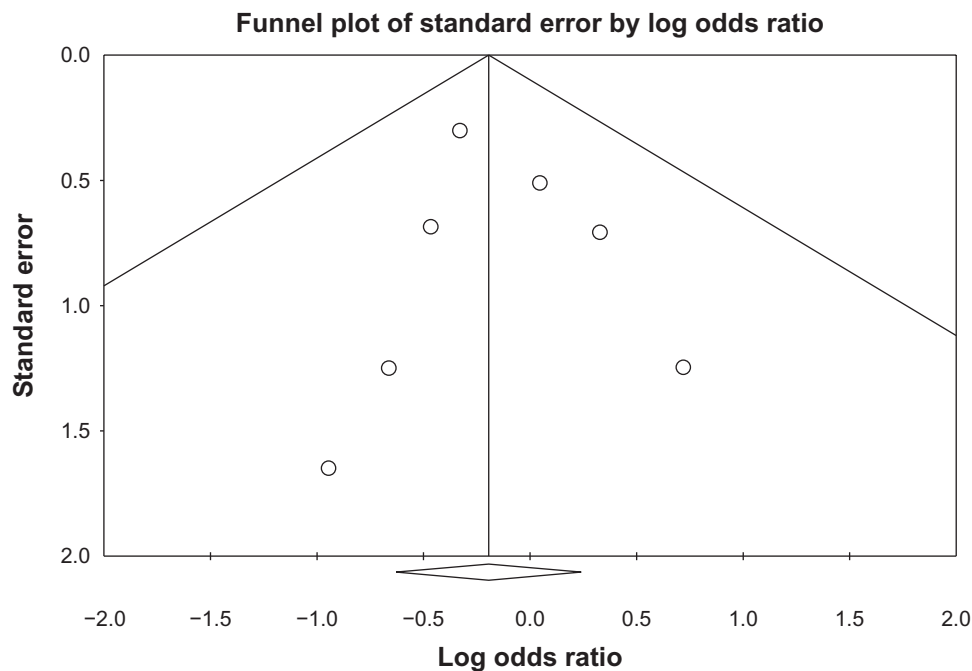


Figure 2 Funnel plot of standard error by log odds ratio for publication bias.

posterior mucosal flap anastomosis. The authors did not find any significant difference in success rates between the three techniques. Similar findings were reported by Yazici et al,⁷ who used digital subtraction macrodacryocystography to evaluate the nasolacrimal ostium, 6 months after successful external DCR. They found that the lacrimal sac reforms after surgery, and the final ostium develops at the inferior part of the regenerated sac, which confirms the irrelevance to final ostium size of suturing the posterior and anterior flaps.

To the best of our knowledge, this is the first meta-analysis to compare the outcomes of external DCR with anastomosis of both flaps, and DCR with posterior flap excision and anterior flap anastomosis. Our results reveal that the success rates were comparable between both techniques, and that the posterior mucosal flap has no role in the final outcome of external DCR ($P=0.561$). This also shows that, by simplifying the procedure to single flap anastomosis, external DCR can be implemented as a standard technique, without significantly compromising the final success rate.

The main limitation of this study is the paucity of studies that fulfilled the inclusion criteria. Although the number of patients in the studies combined was relatively large (780), only seven studies were eligible for inclusion.

It is recommended that further studies be conducted, to evaluate success rate of DCR with no flap anastomosis,

and whether the excision of both flaps will affect the final lacrimal ostium size.

Acknowledgment

The author acknowledges the help of Dr Karim Haj in the literature search and rating of papers.

Disclosure

The author has no conflicts of interest to disclose.

References

1. McPherson SD Jr, Egleston D. Dacryocystorhinostomy; a review of 106 operations. *Am J Ophthalmol.* 1959;47:328–331.
2. Iliff C. A simplified dacryocystorhinostomy. 1954–1970. *Arch Ophthalmol.* 1971;85:586–591.
3. Pico G. A modified technique of external dacryocystorhinostomy. *Am J Ophthalmol.* 1971;72:679–690.
4. McLachlan DL, Shanon GM, Flanagan JC. Results of dacryocystorhinostomy: analysis of the reoperations. *Ophthalmic Surg.* 1980;11:427–430.
5. Welham RA, Henderson PH. Results of dacryocystorhinostomy analysis of causes for failure. *Trans Ophthalmol Soc U K.* 1973;93:601–609.
6. Welham RA, Wulc AE. Management of unsuccessful lacrimal surgery. *Br J Ophthalmol.* 1987;71:152–157.
7. Yazici B, Yazici Z. Final nasolacrimal osteium external dacryocystorhinostomy. *Arch Ophthalmol.* 2003;121:76–80.
8. Baldeschi L, Macandie K, Hintschich CR. The length of unsutured mucosal margins in external dacryocystorhinostomy. *Am J Ophthalmol.* 2004;138:840–844.
9. Elwan S. A randomized study comparing DCR with and without excision of the posterior mucosal flap. *Orbit.* 2003;22(1):7–13.

10. Deka A, Saikia SP, Bhuyan SK. Combined posterior flap and anterior suspended flap dacryocystorhinostomy: A modification of external dacryocystorhinostomy. *Oman J Ophthalmol.* 2010;3(1):18–20.
11. Katuwal S, Aujla JS, Limbu B, Saiju R, Ruit S. External dacryocystorhinostomy: do we really need to repair the posterior flaps? *Orbit.* 2013;32(2):102–106.
12. Pandya VB, Lee S, Bengler R, et al. The role of mucosal flaps in external dacryocystorhinostomy. *Orbit.* 2010;29(6):324–327.
13. Turkcu FM, Oner V, Tas M, Alakus S, Iscan Y. Anastomosis of both posterior and anterior flaps or only anterior flaps in external dacryocystorhinostomy. *Orbit.* 2012;31(6):383–385.
14. Khan FA, Yaqub MA, Fayyaz M. The importance of excising or suturing the posterior mucosal flaps in external dacryocystorhinostomy. *Pak J Ophthalmol.* 2010;26(2):69–73.
15. Serin D, Alagoz G, Karslioglu S, Celebi S, Kukner S. External dacryocystorhinostomy: double-flap anastomosis or excision of the posterior flaps? *Ophthal Plast Reconstr Surg.* 2007;23(1):28–31.

Clinical Ophthalmology

Publish your work in this journal

Clinical Ophthalmology is an international, peer-reviewed journal covering all subspecialties within ophthalmology. Key topics include: Optometry; Visual science; Pharmacology and drug therapy in eye diseases; Basic Sciences; Primary and Secondary eye care; Patient Safety and Quality of Care Improvements. This journal is indexed on

Submit your manuscript here: <http://www.dovepress.com/clinical-ophthalmology-journal>

Dovepress

PubMed Central and CAS, and is the official journal of The Society of Clinical Ophthalmology (SCO). The manuscript management system is completely online and includes a very quick and fair peer-review system, which is all easy to use. Visit <http://www.dovepress.com/testimonials.php> to read real quotes from published authors.