

Anakinra in the treatment of protracted paradoxical inflammatory reactions in HIV-associated tuberculosis in the United Kingdom: a report of two cases

International Journal of STD & AIDS

2020, Vol. 31(8) 808–812

© The Author(s) 2020



Article reuse guidelines:

sagepub.com/journals-permissions

DOI: 10.1177/0956462420915394

journals.sagepub.com/home/std

Alexander J Keeley¹ , Vivak Parkash², Anne Tunbridge²,
Julia Greig², Paul Collini¹ , William McKane³ and
Rachel S Tattersall⁴

Abstract

Paradoxical reactions, including immune reconstitution inflammatory syndrome (IRIS), are common in patients co-infected with human immunodeficiency virus (HIV) and tuberculosis (TB). Paradoxical reactions may confer substantial morbidity and mortality, especially in cases of central nervous system (CNS) TB, or through protracted usage of corticosteroids. No high-quality evidence is available to guide management in this scenario. Interleukin-1-mediated inflammation has been implicated in the pathophysiology of TB–IRIS. We describe two cases where anakinra (human recombinant interleukin-1 receptor antagonist) was used as steroid-sparing therapy for life-threatening protracted paradoxical inflammation in HIV-associated TB. In the first case of disseminated TB with lymphadenitis, protracted TB–IRIS led to amyloid A amyloidosis and nephrotic syndrome. In the second case of disseminated TB with cerebral tuberculomata, paradoxical inflammation caused unstable tuberculomata leading to profound neuro-disability. In both cases, paradoxical inflammation persisted for over a year. Protracted high-dose corticosteroid use led to adverse events yet failed to control inflammatory pathology. In both patients, anakinra successfully controlled paradoxical inflammation and facilitated withdrawal of corticosteroid therapy. Following anakinra therapy, nephrotic syndrome and neuro-disability resolved, respectively. Anakinra therapy for protracted paradoxical inflammation in HIV-associated TB may be a viable therapeutic option and warrants further research.

Keywords

Tuberculosis, human immunodeficiency virus, anakinra, paradoxical inflammatory reactions, immune reconstitution inflammatory syndrome

Date received: 19 November 2019; accepted: 25 February 2020

Introduction

Paradoxical inflammatory reactions in tuberculosis (TB) are well described, characterised by disordered inflammation to antigen of live or dead bacilli. Patients (2–23%) with TB, develop worsening or new inflammatory lesions despite anti-TB therapy.¹ A paradoxical reaction in patients commencing antiretroviral therapy (ART) for human immunodeficiency virus (HIV) is termed TB-associated immune reconstitution inflammatory syndrome (TB–IRIS), occurring with a frequency of 5–57%.²

Modulating the immune response with corticosteroids improves survival in patients with

¹Department of Infection, Immunity and Cardiovascular Disease and Florey Institute, University of Sheffield, Sheffield, UK

²Department of Infection and Tropical Medicine, Sheffield Teaching Hospitals NHS Foundation Trust, Sheffield, UK

³Sheffield Kidney Institute, Sheffield Teaching Hospitals NHS Foundation Trust, Sheffield, UK

⁴Department of Rheumatology, Sheffield Teaching Hospitals NHS Foundation Trust and Sheffield Children's Hospital NHS Foundation Trust, Sheffield, UK

Corresponding author:

Alexander J Keeley, Department of Infection, Immunity and Cardiovascular Disease, University of Sheffield, Sheffield, UK.
Email: a.keeley@sheffield.ac.uk

TB-meningitis and reduces the frequency of TB-IRIS in immunosuppressed patients with HIV and TB co-infection.^{3,4} However, some patients experience paradoxical reactions for months and even years, despite appropriate TB therapy, and may require protracted use of corticosteroids with significant treatment morbidity. Successful use of several alternative agents including thalidomide, interferon gamma, montelukast and infliximab has been reported in case reports and small case series.⁵

Interleukin-1 (IL-1) has been implicated as a key mediator of the excessive immune responses in TB-IRIS. IL-1 is a potent inflammatory mediator that potentiates cell-mediated immune responses, upregulates other inflammatory cytokines and promotes auto-inflammation.⁶ IL-1 exists in alpha and beta forms, although their activity is similar. In patients with HIV and TB, those with IRIS, when compared to non-IRIS controls, have an increased IL-1-mediated cytokine profile that can be reduced by blocking IL-1 receptor signalling.⁷ Compared to non-IRIS patients and HIV controls without TB, patients with TB-meningitis and IRIS have higher levels of the IL-1 β activator, caspase 1, in their CSF and peripheral transcriptomes associated with both IL-1- and neutrophil-mediated inflammation.⁸ IL-1 receptor antagonist has a physiological role in regulating IL-1-mediated inflammation.

Anakinra is a recombinant IL-1 receptor antagonist which is licenced for the treatment of rheumatoid arthritis, the auto-inflammatory syndrome cryopyrin-associated periodic syndrome, systemic juvenile idiopathic arthritis and its counterpart adult onset Still's disease. The licenced dose of anakinra is 100 mg once daily by subcutaneous (SC) injection. Clearance of anakinra is directly related to renal function.⁹ Anakinra is well tolerated although skin reactions at the site of injection are not uncommon. There is increasing evidence of safety even in severely immunocompromised and/or septic patients.¹⁰⁻¹² Anakinra has no significant interactions with HIV or TB treatments. Furthermore, from extensive data, TB reactivation attributed to anakinra usage is extremely rare.¹³ We describe the successful treatment with anakinra of two patients with protracted paradoxical reactions in HIV-associated TB.

Case 1

A 33-year-old Ethiopian female patient presented in 2009 with a two-week history of fever, myalgia, night sweats and weight loss. On examination, the patient had widespread lymphadenopathy. She was diagnosed with HIV with a baseline CD4 cell count of 60 cells/mm³. Pus aspirated from a cervical lymph

node was acid-alcohol fast bacilli (AFB) smear positive and grew fully-sensitive *Mycobacterium tuberculosis* on culture. Cross-sectional imaging revealed cervical, mediastinal and abdominal lymphadenopathy and splenic microabscesses, consistent with disseminated TB. She responded well to standard anti-TB therapy. After two weeks of anti-TB therapy, she was commenced on ART with tenofovir, emtricitabine and efavirenz. Four weeks after ART initiation, the patient developed pyrexia (39.2°C) with abdominal pain, nausea and vomiting. Following extensive investigation to exclude alternative opportunistic infections, malignancy and autoimmune disease, TB-IRIS was diagnosed with persistent large cervical and iliopsoas cold abscesses requiring recurrent aspiration. Pus samples were persistently positive for AFB and *M. tuberculosis* by polymerase chain-reaction but mycobacterial cultures were negative, consistent with protracted TB-IRIS. She commenced 60 mg prednisolone once daily. However, over the next three years, she was unable to tolerate a dose of less than 20 mg prednisolone daily, due to relapsing fever, malaise, abdominal pain and lymphadenopathy on each attempt to wean steroids. She received two courses (12 months and 9 months) of anti-TB therapy and developed multiple steroid-associated adverse effects including diabetes, cataracts, recurrent urinary tract infections and osteoporotic fractures. Therapy with montelukast 10 mg daily was used to attempt suppression of IRIS, but with limited effect. Two and a half years after her initial presentation, she developed nephrotic syndrome: low serum albumin (21 g/L), significant proteinuria (10.5 g/day) and peripheral oedema with preserved renal function. A diagnosis of amyloid A (AA) amyloidosis was made on renal biopsy, which showed mesangial and vascular amyloid deposition on sirius red staining, dichroic birefringence under polarised light and 10 nm mesangial fibrils. Immunofluorescence for amyloid P demonstrated glomerular staining and no evidence of Kappa/Lambda clonality. She had a tenfold rise in serum amyloid A to C-reactive protein (CRP) ratio, with a moderate renal and splenic amyloid load on scintigraphy with radiolabelled serum amyloid P. Positron emission tomography demonstrated highly metabolically active cervical, mediastinal and abdominal lymph nodes. Histology from a supraclavicular lymph node showed non-specific chronic inflammatory changes only and no evidence of malignancy or Castleman disease. Pus from this lymph node remained AFB positive, with no mycobacterial growth on culture. She was referred to the National Amyloid Centre UK, where she was assessed as being in the worst prognostic octile for AA amyloidosis. Anakinra was proposed as a potential steroid sparing agent to control her pro-inflammatory process, due to its biological plausibility for both AA

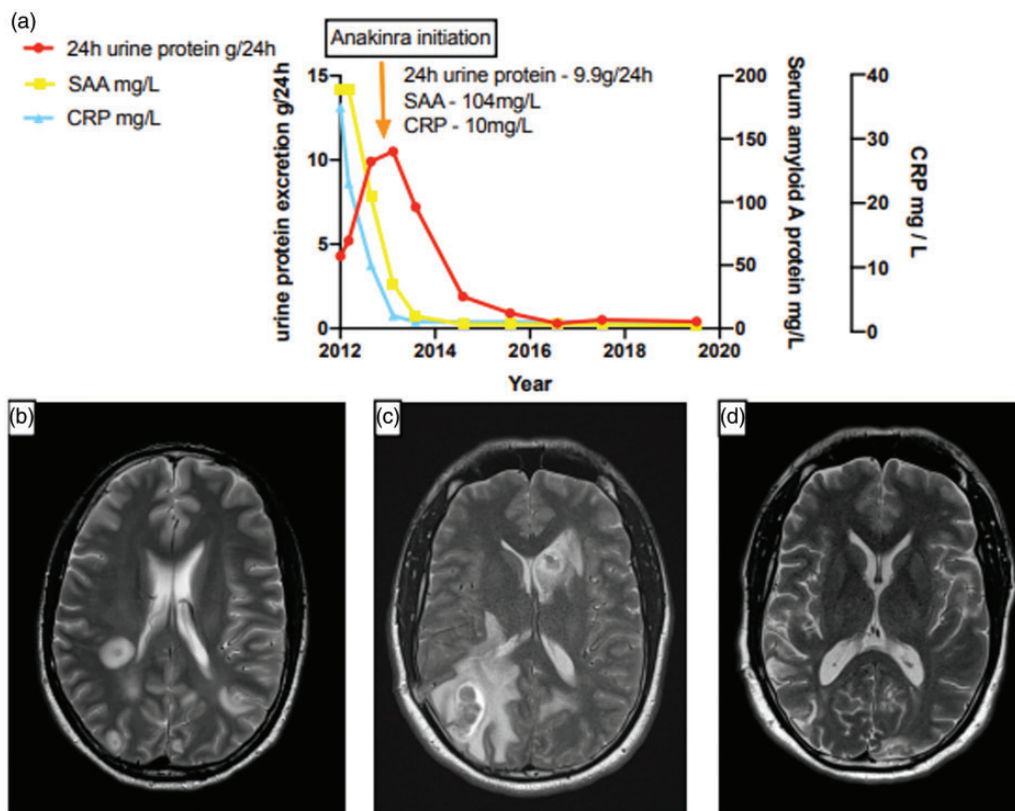


Figure 1. (a) Case 1 – Graph demonstrating progress of 24-h urine protein excretion, serum amyloid A (SAA) protein and serum C-reactive protein (CRP) before and after initiation of anakinra therapy. Case 2 – Serial T2 weighted MRI brain scans at baseline (b), 18 months (c) and three years (d) into illness, demonstrating progressive and unstable tuberculomata throughout both hemispheres until 18 months, with subsequent resolution following anakinra therapy.

amyloidosis and IRIS and its rapid onset of action. In conjunction with the local multidisciplinary team including regional HIV, rheumatology and nephrology specialists, she was commenced on anakinra in June 2013, at a dose of 100 mg SC daily. Within three months of starting anakinra, there was a discernible improvement in her malaise, widespread painful lymphadenopathy and quality of life. Her inflammatory markers and proteinuria normalised (Figure 1(a)). Steroids were successfully weaned off over a year. After six years of anakinra therapy (subsequently reduced to 100 mg on alternate days at five years), and with stable calcified lymph node disease on cross-sectional imaging, an attempt was made to stop anakinra. However, 72 h after cessation, there was a rapid recurrence of abdominal pain, fever and malaise with associated rise in CRP (from 0.5 to 34 mg/L) and erythrocyte sedimentation rate (to 43 mm/h). Anakinra was re-initiated initially at 100 mg daily for two weeks, achieving control of symptoms and normalisation of inflammatory markers (Figure 2). She will remain on 100 mg anakinra on alternate days lifelong.

Case 2

A 41-year-old male teacher from Zimbabwe presented in 2016 with one month of fever, sweats and headache. Medical history included pulmonary TB (2005) and HIV with an undetectable viral load and a CD4 cell count of 275 cells/mm³ on tenofovir, emtricitabine and efavirenz ART. He was haemodynamically stable with unremarkable examination and no neurological deficit. Isoniazid mono-resistant TB was diagnosed via culture from bronchoalveolar lavage, with multiple miliary nodules throughout both lung fields on cross-sectional imaging. Magnetic resonance imaging (MRI) of his brain revealed numerous foci of parenchymal high T2 signal in the right posterior and left medulla, the pons bilaterally and both cerebellar hemispheres, consistent with tuberculomata (Figure 1(b)). Lumbar puncture was acellular with mild protein rise of 0.61 g/L and normal glucose. He had been commenced empirically on rifampicin, isoniazid, ethambutol, pyrazinamide, moxifloxacin, capreomycin and cycloserine (given a history of TB treated in South Africa), alongside dexamethasone 18 mg (0.3 mg/kg)

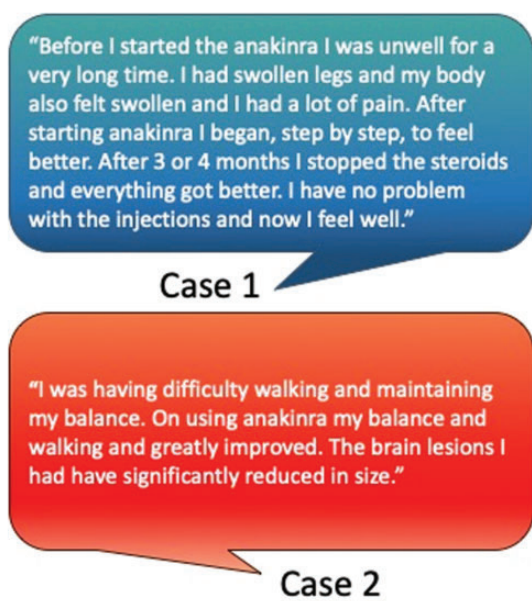


Figure 2. Patient perspectives; each patient was asked to describe their experience with anakinra.

daily with a standard wean (reducing by 0.1 mg/kg per week).¹⁴ Two weeks into treatment, his headache worsened and he developed new left-sided weakness and paraesthesia. MRI brain confirmed an increase in number and size of the lesions present requiring adjustment of dexamethasone back to 18 mg daily. Brain biopsy demonstrated a necrotising granuloma; AFB were visualised but there was no mycobacterial growth, consistent with a paradoxical reaction. Following TB culture and sensitivity results, his TB regimen was rationalised to rifampicin, pyrazinamide, moxifloxacin and ethambutol. After four months, he was discharged with a dose of 8 mg dexamethasone daily, with a plan to wean by 1 mg monthly. At month 9 and at month 17, he required readmission for ataxia, left hemiplegia and expressive dysphasia, with significant functional and cognitive impairment. He was unable to live independently. On both occasions, MRI demonstrated worsening oedema and unstable tuberculomata throughout both hemispheres, brain stem and cerebellum (Figure 1(c)), prompting recommencement of dexamethasone, 10 mg daily. Over this period, he developed Cushingoid appearance and low mood. Thalidomide was trialled at month 17; however, it was withdrawn one month later due to peripheral neuropathy. Anakinra, 100 mg SC, was then initiated at 18 months as a steroid sparing agent. He remained on anakinra and weaned off corticosteroids over the next 18 months (36 months total duration) while he completed two years of anti-TB therapy with rifampicin, pyrazinamide, moxifloxacin and

ethambutol. Since initiation of anakinra, there have been no new tuberculomata and the existing lesions have resolved (Figure 1(d)). Furthermore, his level of function and cognition has improved significantly. He lives independently and can mobilise with a stick with only mild expressive language deficits (Figure 2). Anakinra has been reduced to 100 mg on alternate days after two years.

Discussion

We have described two cases of paradoxical inflammation in TB that were insufficiently controlled by corticosteroid therapy and led to significant morbidity until the introduction of the IL-1 receptor antagonist, anakinra. Paradoxical reactions and IRIS are the cause of substantial morbidity and occasional mortality in HIV/TB co-infection, especially in TB of the CNS, if prolonged corticosteroid is required, or if uncontrolled inflammation leads to AA amyloidosis.¹⁵ IL-1-mediated inflammation has been implicated in the pathogenesis of TB-IRIS in HIV in both CNS and non-CNS disease.^{7,8} In the two cases presented here, anakinra was used to achieve control of inflammation and to reduce and stop steroids in patients at risk of death or serious morbidity (in part due to high steroid requirements) with protracted paradoxical reactions to TB. We suggest that through down-regulating IL-1-mediated inflammation, anakinra presents a viable treatment option for refractory paradoxical inflammation in TB. Further research to evaluate the therapeutic role of anakinra, particularly in less well-resourced health systems with a high burden of HIV/TB co-infection is required.

Acknowledgements

The authors would like to acknowledge both patients for their perseverance in the face of such an adverse journey, and for consenting to share their story; the UK National Amyloidosis Centre, particularly Dr Helen Lachmann, for their outstanding clinical management and guidance in case 1.

Declaration of conflicting interests

The authors declared no potential conflicts of interest with respect to the research, authorship, and/or publication of this article.

Funding

The authors received no financial support for the research, authorship, and/or publication of this article.

ORCID iDs

Alexander J Keeley  <https://orcid.org/0000-0001-9386-1157>
Paul Collini  <https://orcid.org/0000-0001-6696-6826>

References

1. Bell LC, Breen R, Miller RF, et al. Paradoxical reactions and immune reconstitution inflammatory syndrome in tuberculosis. *Int J Infect Dis* 2015; 32: 39–45.
2. Namale PE, Abdullahi LH, Fine S, et al. Paradoxical TB-IRIS in HIV-infected adults: a systematic review and meta-analysis. *Future Microbiol* 2015; 10: 1077–1099.
3. Prasad K, Singh MB and Ryan H. Corticosteroids for managing tuberculous meningitis. *Cochrane Database of Syst Rev* 2016; 1–64.
4. Meintjes G, Stek C, Blumenthal L, et al. Prednisone for the prevention of paradoxical tuberculosis-associated IRIS. *N Engl J Med* 2018; 379: 1915–1925.
5. Davis A, Meintjes G and Wilkinson RJ. Treatment of tuberculous meningitis and its complications in adults. *Curr Treat Options Neurol* 2018; 20: 5.
6. Sims JE and Smith DE. The IL-1 family: regulators of immunity. *Nat Rev Immunol* 2010; 10: 89–102.
7. Lai RPJ, Meintjes G, Wilkinson KA, et al. HIV-tuberculosis-associated immune reconstitution inflammatory syndrome is characterized by Toll-like receptor and inflammasome signalling. *Nat Commun* 2015; 6: 8451.
8. Marais S, Lai RPJ, Wilkinson KA, et al. Inflammasome activation underlying central nervous system deterioration in HIV-associated tuberculosis. *J Infect Dis* 2017; 215: 677–686.
9. Yang BB, Baughman S and Sullivan JT. Pharmacokinetics of anakinra in subjects with different levels of renal function. *Clin Pharmacol Ther* 2003; 74: 85–94.
10. Kyriazopoulou E, Leventogiannis K, Norrby-Teglund A, et al. Macrophage activation-like syndrome: an immunological entity associated with rapid progression to death in sepsis. *BMC Med* 2017; 15: 172.
11. Shakoory B, Carcillo JA, Chatham WW, et al. Interleukin-1 receptor blockade is associated with reduced mortality in sepsis patients with features of macrophage activation syndrome: reanalysis of a prior phase III trial. *Crit Care Med* 2016; 44: 275–281.
12. Eloseily EM, Weiser P, Crayne CB, et al. Benefit of anakinra in treating pediatric secondary hemophagocytic lymphohistiocytosis. *Arthritis Rheumatol* 2020; 72: 326–334.
13. Winthrop KL, Mariette X, Silva JT, et al. ESCMID study group for infections in compromised hosts (ESGICH) consensus document on the safety of targeted and biological therapies: an infectious diseases perspective (Soluble immune effector molecules [II]: agents targeting interleukins, immunoglobulins and complement factors). *Clin Microbiol Infect* 2018; 24: S21–S40.
14. Thwaites GE, Bang ND, Dung NH, et al. Dexamethasone for the treatment of tuberculous meningitis in adolescents and adults. *N Engl J Med* 2004; 351: 1741–1751.
15. Brown CS, Smith CJ, Breen RA, et al. Determinants of treatment-related paradoxical reactions during anti-tuberculosis therapy: a case control study. *BMC Infect Dis* 2016; 16: 479.