

Clinical evaluation of improved MyoSure hysteroscopic tissue removal system for the resection of type II submucosal myomas

Yufei Liang, BS, Yuefang Ren, MD, Zeqiu Wan, BS, Lihua Guo, BS, Jie Dong, MS, Yun Chen, BS, Liping Lv, BS*

Abstract

This study aims to determine whether clinical evaluation of improved MyoSure hysteroscopic tissue removal system can remove type II submucosal myomas with safety and high success rate of the first operation.

Fifty-three patients with type II submucosal myomas hospitalized in the Huzhou Maternity and Child Care Hospital were enrolled in this study. The submucosal myomas were with the diameter of >2 cm and ≤ 5 cm. All patients have surgical indications.

Fifty-one of 53 hysteromyomas were successfully resected through 1-time operation. The average time was 37.92 ± 18.57 minutes, average amount of bleeding: 24.80 ± 12.12 mL, average length of stay: 2.02 ± 0.14 days. One patient had a transient postoperative fever and one patient had slight fluid overload with hyponatremia.

The success rate of the first operation for resecting type II submucosal myomas showed an increase using improved MyoSure hysteroscopic tissue removal system, which can be a new, safer, and more efficient operation for treating type II submucosal myomas.

Abbreviations: FDA = The US Food and Drug Administration, FMM = The Free Myometrial Margin, GnRH-a = gonadotropin-releasing hormone agonist, MA = morcellator, SPSS = Statistic Package for Social Science, USA = The United States of America, XL = extra large.

Keywords: Hysteroscopy, leiomyoma, MyoSure

1. Introduction

Operative resection is a therapeutic option for submucosal myomas. Resection of hysteromyomas instead of hysterectomy is a more commonly adopted therapy. The classic operative option for type II submucosal myomas is the warm soapsuds enema with electric resection, which requires skilled operators who have undergone massive training.^[1] Therefore, the hysteroscopic electric resection cannot be performed in the low-grade hospitals. Meanwhile, the risk of electrothermal damage by electric resection is another concern. Hysteroscopic morcellator is a mechanical tissue removal system with the advantages of shorter operation time and less operative damage.^[2,3] In 2005, the US Food and Drug Administration (FDA) approved the TRUCLEAR hysteroscopic morcellator (Smith & Nephew, MA) as the first

mechanical morcellator for resecting intrauterine disease.^[4] The MyoSure tissue removal system (Hologic, MA) was approved by FDA in 2009 and is more suitable as a hysteroscopic morcellator for treating intrauterine pathological lesions including submucosal myomas with the merits of rapid and easy operation and less complications. The operation of MyoSure is easier to be mastered compared with hysteroscopic electric resection. It was reported that the hysteroscopic morcellator was more rapid and easier compared with conventional electric resection.^[2] No difference in terms of completeness was found between interns and senior surgeons,^[4] which confirmed that the MyoSure system was easy to operate and suitable for the outpatient department and low-grade hospitals. Moreover, Rajesh and Guyer^[5] reported that the MyoSure system could be safely used for removing submucosal myomas in an outpatient hysteroscopy setting, with satisfactory tolerance and nearly no complications. Also, the MyoSure system was successfully used for resecting endometrial polyps and types 0 and I submucosal myomas. However, the type II submucosal myomas were excluded in some previous studies,^[1,2,6] and the MyoSure system could not be used for type II submucosal myomas, as reported by Sardo et al.^[7] Sardo et al reported some limitations for treating type II submucosal myomas using the MyoSure system: the success rate of the first operation was low, indicating the need for multiple operations or improved operation mode and the operative difficulty was high because 50% hysteromyomas were embedded in the muscular layer leading to the risk of increased bleeding and liquid absorption.^[8] The hysteromyomas in the muscular layer could be resected efficiently and safely if the hysteromyomas could be stripped off from the muscular layer and morcellated within the capsule using a new technique.^[9] An apparatus was developed through clinical experience, which could accomplish incising, separating, and

Editor: Somchai Amornyoitin.

The authors report no conflicts of interest.

Gynaecology and Obstetrics, Huzhou Maternity and Child Care Hospital, Huzhou, Zhejiang, China.

* Correspondence: Liping Lv, Gynaecology and Obstetrics, Huzhou Maternity and Child Care Hospital, Huzhou 313000, Zhejiang, China (e-mail: 13732396105@163.com).

Copyright © 2017 the Author(s). Published by Wolters Kluwer Health, Inc. This is an open access article distributed under the terms of the Creative Commons Attribution-Non Commercial License 4.0 (CCBY-NC), where it is permissible to download, share, remix, transform, and buildup the work provided it is properly cited. The work cannot be used commercially without permission from the journal.

Medicine (2017) 96:50(e9363)

Received: 28 June 2017 / Received in final form: 2 November 2017 / Accepted: 28 November 2017

<http://dx.doi.org/10.1097/MD.0000000000009363>

clamping using the MyoSure system. Hysteromyomas embedded in the muscular layer could be stripped off into the uterine cavity under the direct vision of a hysteroscope using a combination of the invented apparatus and the MyoSure system, without altering intrauterine pressure or promoting uterine contraction by drugs. The type II submucosal myomas could be effectively removed by continuous morcellation of the MyoSure system. Thirty-two patients with type II submucosal myomas were treated using the improved MyoSure system in the present study. The data of medical records, hysteromyomas, and surgical operation of the patients were recorded and retrospectively analyzed.

2. Material and methods

2.1. Clinical information

The patients were admitted to the hospital between June 30, 2014 and June 30, 2016. The diagnosis of type II submucosal myomas was made in accordance with the criteria suggested by “Holland Haarlem International Hysteroscopic Training School” (no pedicle extending to the muscular layer $>50\%$), and the diagnosis was confirmed by ultrasound examination, surgical operation and, pathological diagnosis. A total of 53 patients were recruited in this study. The surgeries were performed between day 3 and 7 after menstruation, and no contraindications were reported. The inclusion criteria were as follows: diagnosed as type II submucosal fibroids using preoperative ultrasound imaging with the largest diameter of fibroids ≥ 2 cm and ≤ 5 cm; the thickness of the myometrium (The Free Myometrial Margin-FMM-) between the myoma and the perimetrium had to be at least 2 mm (preoperatively by ultrasound); presence of clinical symptoms which can affect life, or fibroids is considered to be the Only reason for infertility, the patient had a clear intention to surgery, and signed informed consent; without hysteroscopic surgery and anesthesia surgery contraindications. The exclusion criteria were: preoperative ultrasound imaging of fibroids with the largest diameter < 2 cm or > 5 cm; multiple fibroids; the FMM was < 2 mm; pregnancy; the presence of female reproductive system of cancer pre-lesion or malignant disease; postmenopausal; pelvic inflammatory disease; preoperative use of GNRH-a or mifepristone; the patient refused to participate. All patients in this

Table 1

General information of patients (n=53).

Age, y*	35.06 ± 12.72
Concurrent disease	
Hypertension	1
Diabetes	1
Thyroid dysfunction	0
Psychosomatic disease	0
Child-bearing history	
Previous Pregnancy	40
Never been pregnant	13
Abnormal menstruation	
Increased menstruation	36
Prolonged menstruation	17
Previous abdominal surgery [†]	
Cesarean section	4
Myomectomy	6
Appendectomy	2
Adnexal surgery	3

* Data were presented as mean ± standard deviation.

[†] A patient may undergo ≥ 2 abdominal surgeries.

Table 2

Data regarding hysteromyomas (n=53).

Size of hysteromyomas, cm*	3.88 ± 1.39
2.0–3.0	6
3.1–4.0	23
4.1–5.0	24
Location of hysteromyomas in the uterus	
Low segment	6
Middle segment	32
Bottom	15
Ratio between hysteromyomas located at the bottom of the uterus and those located in the uterine wall	
$\leq 1/3$	36
$> 1/3$ – $2/3$	12
$> 2/3$	5
Expansion depth of the hysteromyoma into the muscular layer	
$\geq 50\%$ – 60%	32
$> 60\%$ – 70%	14
$> 70\%$	7
Distance between the margin of hysteromyomas and the uterine serosa, cm	
> 1	1
0.5–1.0	25
< 0.5 cm	27

* The size of the fibroids defaults to be the biggest diameter under B-ultrasonography.

hospital were informed before surgery; all patients in this article were informed before surgery of the need to replace the surgical program, surgical costs, and surgical risk, and there may be a chance of secondary surgery. All patients signed the informed consent form and agree to use the relevant information for article writing and public publication. The current study was approved by the ethics committee of the Huzhou Maternity and Child Care Hospital (Zhejiang, China).

The data regarding the age, child-bearing history, abnormal menstruation, a history of abdominal surgery, and complications are listed in Table 1. All the hysteromyomas were solitary; their detailed information is listed in Table 2. The operation time, success rate of the first operation, amount of bleeding, length of stay, complications, abnormal menstruation, and its improvement and recovery are listed in Table 3.

The size of hysteromyomas was described by the maximum diameter. The submucosal myomas with the diameter of < 2 cm could be removed through the uterine cervix directly after

Table 3

Operation time, success rate of the first operation, bleeding amount, complications, and menstruation recovery (n=53).

Operation time, min	37.92 ± 18.57
One-time resection	51
Liquid loss amount, mL	593.40 ± 350.21
amount of bleeding, mL	24.80 ± 12.12
Complications	
Uterine perforation	0
Fluid overload with hyponatremia	1
Massive hemorrhage	0
Transient fever	1
Cervical laceration	0
Recovered to normal*	
3 Mo postoperatively	32
6 Mo postoperatively	44
Length of stay, day	2.02 ± 0.14

* Refers to menstrual abnormalities returned to normal circumstances.

stripping off using the hysteroscope. Therefore, all the hysteromyomas selected were with a diameter of >2 cm. The operation success rate for hysteromyomas was reported to be correlated with the size and number of hysteromyomas.^[10] The hysteromyomas with a diameter of >5 cm were pretreated with gonadotropin-releasing hormone agonist (GnRH-a) before operation to reduce the difficulty and postoperative complications.^[11,12] Hence, the hysteromyomas selected in this present study were of ≤ 5 cm in diameter.

2.2. Surgical operation personnel

The operations were performed by the same chief obstetrician and gynecologist under B-ultrasound surveillance by the same chief imaging physician.

2.3. Indication of operation

The indicators of operation included hysteromyomas with menorrhagia or abnormal uterine bleeding; the size of the uterus <10 weeks' gestation and uterine cavity <12 cm; maximum diameter of hysteromyomas ≤ 5 cm; no malignant lesion; patients with strong request for uterus preservation; and hysteromyomas as the only cause of infertility or recurrent abortion.

2.4. Preoperative preparation

The patients were thoroughly informed of the potential surgical risk and intraoperative or postoperative complications. The complete preoperative examinations such as leucorrhea test, blood cell counts, and serum biochemical examinations were performed to exclude the inflammation of the genital tract. Drugs or measures to soften the cervix were not required because the cervix was expanded using a No. 6.5 cervical expander. The patients were asked to fast for 6 hours before the operation and not to drink for 4 hours before the operation.

2.5. Operative apparatus and instrument

Normal saline was used as distention media (it was reported that normal saline or lactated Ringer's solution could reduce the risk of liquid penetration) for all the patients. The automatic inflation pump (Jingrui JG200, China) and the MyoSure hysteroscopic tissue removal system (Hologic) were used; scissors, separators, and grasping forceps were shown in Figures 1 and 2.

2.6. Anesthesia

The general anaesthesia was performed.

2.7. Surgical operation

The in-house made hysteroscopy apparatus was placed using the MyoSure system and a uterus expansion pressure of 100 to 120 mm Hg, and the expansion pressure was not adjusted as long as the operative vision was clear. The endometrium and capsule of hysteromyomas were cut open using scissors. The hysteromyomas were stripped off into the uterine cavity using separators and pliers, so that the type II submucosal myomas turned into type I submucosal myomas and further morcellated within the capsule. This step was repeated a few times to remove all the hysteromyomas embedded in the muscular layer. The ultrasound surveillance and monitoring was conducted by the same physician. A complete removal surgery of tumor which the

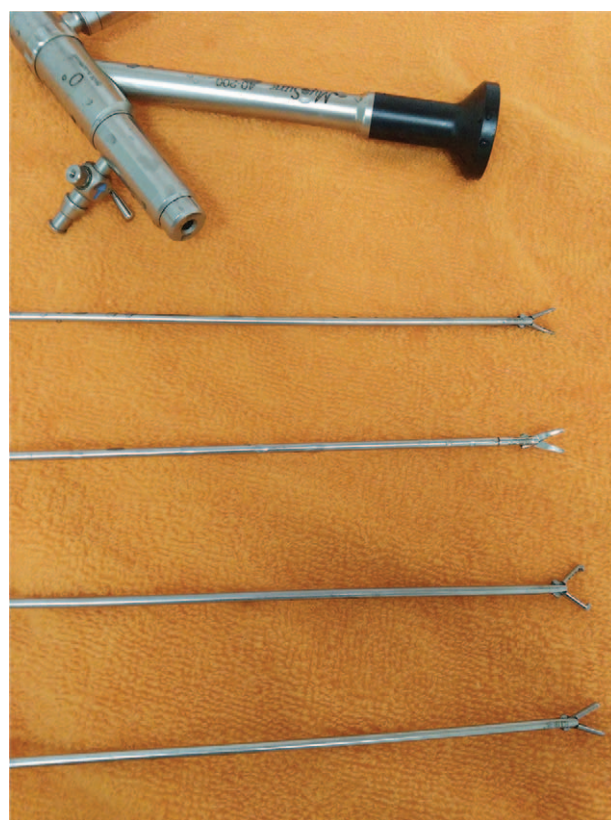


Figure 1. Complementary 4 items of invented instruments.

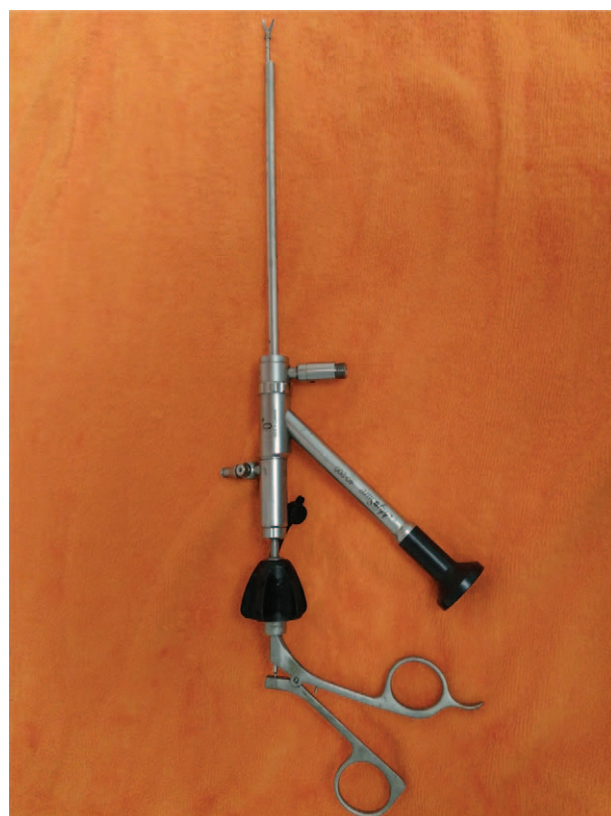

Figure 2. Grasping forceps placement into the MyoSure optical instrument.

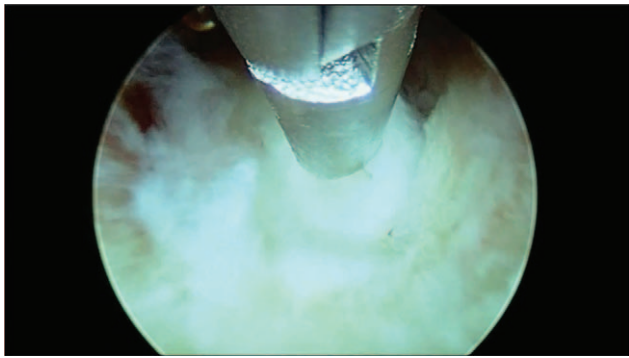


Figure 3. Hysterosmyoma was clamped using grasping forceps and stripped off into the uterine cavity.

tumor cannot be seen at original fibroids sites using B ultrasound imaging was thought to be a clean removal. The pathological examination confirmed all except one to be leiomyoma of the uterus; only one that failed to have a complete removal with 1-time operation was confirmed to be endometrioma (Fig. 3).

2.8. Observed parameters

The observed parameters included the operation time, success rate of the first operation, amount of bleedin, length of stay, complications, liquid loss amount (referred to the difference between uterine swelling liquid use, and the amount of uterine swelling liquid collected using collection bag coming out of the body), and menstruation improvement (Table 3).

2.9. Postoperative follow-up

Before discharge, patients were informed of the postoperative follow-up during 3 and 6 months after surgery, postoperative review of B-ultrasound in 3 months by the same doctor to check whether the original surgical site of tumor remains. And detailed records of patients with menstrual recovery to normal state of time were recorded.

2.10. Statistical analysis

All data were analyzed using SPSS 23 software (SPSS Inc, Chicago, IL).

3. Results

3.1. Baseline data

In this study, we included a total of 53 women with the type II submucosal myomas. Finally, 51 women completed the surgery and all the tumors were removed at one time (Fig. 4). Of the 2 patients who failed to achieve this, one was treated with GNRH-a for pathological diagnosis of adenomyosis and then Mirena Intrauterine Ring was placed and increased symptoms were observed; 1 case did not finish the surgery because of mild water poisoning, after 1-month hysteroscopic electro-surgical excision was performed to remove remaining tumor.

3.2. One-time complete resection rate

Fifty-one of 53 patients had the hysterosmyomas completely resected with 1-time operation, with the success rate of 96.226%.

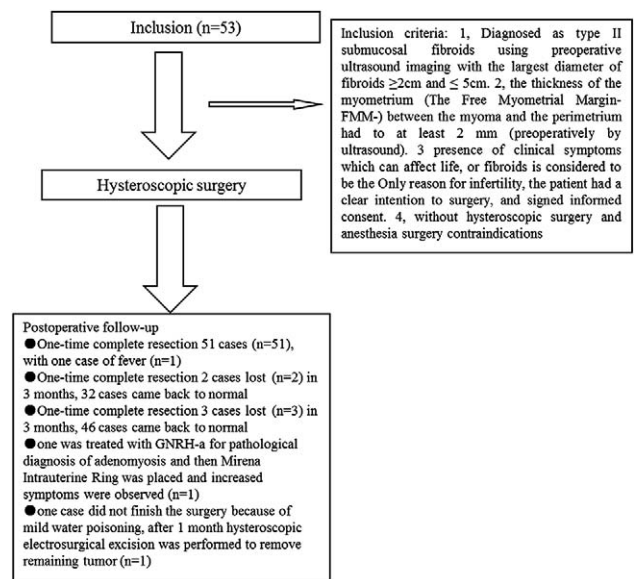


Figure 4. The flow chart.

The average weight of the fibroids after weighed resuscitation was $31.47 \pm 12.69\text{g}$ Combined with intraoperative B-ultrasound images of the situation, we believe that 51 cases of patients were all one-time removal of the tumor, whereas the postoperative review of B-ultrasound in 3 months showed that beside the 3 patients lost, the remaining 49 patients showed no tumor remaining.

3.3. Operation time

The average whole operation time of 53 patients was 37.92 ± 18.57 minutes.

3.4. Bleeding amount

The average bleeding amount was $24.80 \pm 12.12\text{mL}$ in 51 patients with successful 1-time operation. The mean hemoglobin was $93.61 \pm 9.83\text{g/L}$, whereas the average postoperative hemoglobin was $91.51 \pm 9.61\text{g/L}$. There was still some difference in hemoglobin before and after operation, but the visual field was relatively clearer and the operation could be completed successfully. Thus we thought that successful surgical bleeding amount was within the acceptable range. A typical feature in the case of a large hemorrhage is that the view is not clear, leading to a negative influence on surgical operation, increased complications, and perhaps multiple operations.

3.5. Average length of stay

The average length of stay was 2.02 ± 0.14 days. One patient in 51 patients who had a successful operation was hospitalized for 3 days because of fever. The remaining 50 patients were hospitalized for 2 days.

3.6. Complications

One patient (1/53) had a transient postoperative fever with the temperature of 37.7°C ; the patient was discharged after 2 days of observation. The retrospective analysis did not reveal the cause of

fever, although it was reported that the transient fever was commonly found in the patients with severe anemia.^[13] One patient slight fluid overload with hyponatremia, and recovered after application of furosemidum. No uterine perforation was found in all 53 patients, although complications such as uterine perforation were found in the hysteroscopic morcellation treatment^[14]; no complication was related to the limited case number.

3.7. Postoperative follow-up

Two patients failed for the follow-up examination at 3 months postoperatively, and 3 patients failed for the examination at 6 months postoperatively. Postoperative review of B-ultrasound in 3 months showed that beside the 2 lost patients, all other 49 cases showed no tumor remains. The one who failed the complete removal with the first operation was intramuscularly injected with GnRH-a 6 times, and then the Mirena was placed. Another patient who did not have an 1-time resection received hysteroscopic electro-surgical excision to remove the remaining fibroids 1 months postoperatively.

3.8. Postoperative menstrual improvement

Three months after operation, 2 cases were lost to follow-up. Of the 49 cases of successful operation, menstrual abnormalities of 32 cases disappeared and returned to normal. Six months after operation, 3 cases were lost to follow-up. Of the 48 cases of successful operation, menstrual abnormalities of 44 cases disappeared and returned to normal.

4. Discussion

The submucosal myomas usually result in abnormal uterine bleeding and are one of the major causes for organic intrauterine lesions. The endocrine therapy is not satisfactory for most submucosal myomas, and surgery is the commonly adopted treatment. The hysteroscopic electric resection is widely accepted for submucosal myomas; it has incomparable advantages over the conventional open-abdomen mode, and therefore it is regarded as a criterion standard treatment for submucosal myomas.^[15] However, hysteroscopic electric resection treatment is difficult for type II submucosal myomas among all kinds of submucosal myomas, with a higher risk of complications and need for skilled surgeons. Therefore, the hysteroscopic electric resection for type II submucosal myomas cannot be used in a low-grade hospital. Meanwhile, the endometrial damage caused by an electrothermal injury is another concern. The cold knife treatment under hysteroscopy is a currently developed therapeutic approach.^[16,17] It can maintain the anatomical and functional integrity of the myometrium without electrothermal damage.^[18] It is worthwhile to learn and master this new technology.

The MyoSure hysteroscopic tissue removal system has been recognized for treating types 0 and I submucosal myomas. However, it is not ideal for type II submucosal myomas with a lower rate of 1-time complete resection. A set of complementary hysteroscopic operating instruments was developed based on clinical experience. The low rate of 1-time complete resection for type II submucosal myomas could be improved by combining the new apparatus with the MyoSure system. Meanwhile, the advantages of the MyoSure system, including the efficiency and safety, were maintained.

More than 50% of type II submucosal fibroids were in the myometrium, and MyoSure cannot remove tumor in the muscle

layer. We improved the laparoscopic surgical instruments, together with MyoSure which can be used on the basis of MyoSure under the direct look under the shear, grasping, separation of the operation. Although the success rate of 1-time surgery reached 96.226%, but we still find some limitations, a patient suspended surgery owing to lack of liquid to 1250 mL and a slight water poisoning. One hystero-myoma had an indistinct boundary to the myometrium, and hence was difficult to strip off. The operation time was then prolonged with the liquid loss of 1000 mL. Therefore, the surgery was stopped, and the lesion was confirmed to be adenomyosis. Hence, attention should be paid to pathological types of lesion before the operation. Similarly, Arnold et al^[19] reported that morcellation with the MyoSure system was unsuccessful in one woman with a calcified leiomyoma. The pathological type of the lesion could be determined by not only conventional ultrasound but also magnetic resonance imaging.^[20] Once the major part of the hystero-myoma was removed, the residual lesion with the maximum diameter of <2.0 cm could be stripped off completely into the uterine cavity using grasping forceps and removed using hysteroscopy. It not only increased the 1-time operation rate but also decreased the liquid usage, thus to minimize the fluid overload with the risk of hyponatremia.

The major proportion of time was spent on the hystero-myoma stripping. We found that the hystero-myoma located at the bottom of the uterus was easier to be stripped off compared with that located in the lower segment of the uterus; the possible reasons were as follows: it was easier to cut open the endometrium and capsule of the hystero-myoma located at the bottom of the uterus because the scissors were positioned vertically to the surface of the hystero-myoma and hence it was convenient to exert force; it was easier to separate the hystero-myoma from the adjacent tissues after the capsule was incised open; it was easier to twist the hystero-myoma clockwise or anticlockwise using grasping forceps and exert forces from inside to outside compared with from left to right or from up to down; and it was easier to control the instrument to avoid the 1-time complete stripping off of the hystero-myoma from the myometrium. The direct stripping off of the whole hystero-myoma with 1-time operation might result in the absence of mounting points and interference with the subsequent manipulation. The MyoSure system morcellated the hystero-myoma from one side to another and spared some tissue for grasping forceps to facilitate the subsequent conduction.

The 2 major reasons which may prolong the operation time were as follows: the incision on the capsule of the hystero-myoma was not large enough for the maximum diameter of the hystero-myoma, and therefore the grasping process was difficult leading to time wastage; and the fibrous tissue was not loosened by twisting the hystero-myoma, resulting in the difficulty while directly stripping off the hystero-myoma into the uterine cavity, indicating that the whole operation time and total resection time could be improved by training and experience.

MyoSure system involved mechanical morcellation without an electrothermal injury, and the hystero-myoma morcellation within the capsule can lead to minimum damage to the endometrium ensuring rapid recovery. By eliminating the risk of thermal damage to the myometrium and surrounding tissues,^[21,22] the safety of future pregnancies is greatly improved.^[23] Two patients were pregnant 3 months after the operation and gave term birth; one was pregnant 5 months after the operation, but embryonic development stopped during second month of pregnancy. one was pregnant 8 months after

the operation. No placenta accreta or placenta adherens was reported in the former patient. However, more cases need to be explored to validate the pregnancy success after the resection of type II submucosal myomas using the improved MyoSure hysteroscopic tissue removal system.

Although the literatures reported that MyoSure hysteroscopic tissue removal system had a fast and safe advantage in resection of the intrauterine tissue, Meulenbroeks et al^[24] reported that the TRUCLEAR system was significantly superior to MyoSure extra large (XL) in removing fibroids. When the larger fibroids are removed, the reduced durability of the MyoSure XL device may have an effect on the progression of the procedure, so if possible, the surgeon may choose the appropriate surgical instrument during surgery.

A B-ultrasound monitor was the standard equipment for difficult hysteroscopic operations. The noninvasiveness and real-time surveillance using B-ultrasound monitor can accurately estimate the residual myometrium thickness to compensate for the intraoperative visual defect.

But there is still another problem which is although the modified type of MyoSure system can improve the type II submucosal fibroids 1-time resection rate, but the cost still calls for our attention. The optical mirror and the accompanying instruments can be recycled after disinfection, but the operator required is non-repetitive and expensive, and the price was about 9000 yuan (around \$1400), which certainly increased the burden of patients to a certain extent. Thus, we need to consider whether we should use modified MyoSure system to remove type II submucosal fibroids, and patient's consent should be obtained before operation.

5. Conclusions

Besides cost problem the improved MyoSure hysteroscopic tissue removal system can improve the type II submucosal fibroids 1-time resection rate. It also maintained the advantages of the MyoSure system such as efficiency and high safety. This operation could preserve the uterus, ameliorate the symptoms of menorrhagia, and improve the life quality to a great extent. Given the limited case number in the present study, the complications, operation time, bleeding amount, postoperative menstrual improvement, and pregnancy using the improved MyoSure hysteroscopic tissue removal system need further validation using a larger number of cases.

Acknowledgment

The authors thank Dr. GAO Liwei, a surgeon from the Department of Surgery, Huzhou Hospital of Zhejiang University, for guidance on the manuscript.

References

- [1] Emanuel MH, Wamsteker K. The Intra Uterine Morcellator: a new hysteroscopic operating technique to remove intrauterine polyps and myomas. *J Minim Invasive Gynecol* 2005;12:62–6.
- [2] van Dongen H, Emanuel MH, Wolterbeek R, et al. Hysteroscopic morcellator for removal of intrauterine polyps and myomas: a randomized controlled pilot study among residents in training. *J Minim Invasive Gynecol* 2008;15:466–71.
- [3] AlHilli MM, Nixon KE, Hopkins MR, et al. Long-term outcomes after intrauterine morcellation vs hysteroscopic resection of endometrial polyps. *J Minim Invasive Gynecol* 2013;20:215–21.
- [4] Arnold A, Ketheeswaran A, Bhatti M, et al. Prospective study on the use of the MyoSure(R) for hysteroscopic resection of endometrial pathology. *J Minim Invasive Gynecol* 2015;22(6s):S45–6.
- [5] Rajesh SK, Guyer C. Myosure hysteroscopic morcellation for the management of submucous fibroids in an out-patient hysteroscopy setting. *J Minim Invasive Gynecol* 2015;22(6s):S102–3.
- [6] Hamerlynck TW, Dietz V, Schoot BC. Clinical implementation of the hysteroscopic morcellator for removal of intrauterine myomas and polyps. A retrospective descriptive study. *Gynecol Surg* 2011;8:193–6.
- [7] Di Spiezio Sardo A, Mazzon I, Bramante S, et al. Hysteroscopic myomectomy: a comprehensive review of surgical techniques. *Hum Reprod Update* 2008;14:101–19.
- [8] Hallez JP. Single-stage total hysteroscopic myomectomies: indications, techniques, and results. *Fertil Steril* 1995;63:703–8.
- [9] Loffer FD. Removal of large symptomatic intrauterine growths by the hysteroscopic resectoscope. *Obstet Gynecol* 1990;76(5 pt 1):836–40.
- [10] Hart R, Molnar BG, Magos A. Long term follow up of hysteroscopic myomectomy assessed by survival analysis. *Br J Obstet Gynaecol* 1999;106:700–5.
- [11] Donnez J, Nisolle M, Grandjean P, et al. The place of GnRH agonists in the treatment of endometriosis and fibroids by advanced endoscopic techniques. *Br J Obstet Gynaecol* 1992;99(Suppl 7):31–3.
- [12] Tiufekchieva E, Nikolov A. Hysteroresection of submucous myomas after treatment with zoladex. *Akush Ginekol (Sofia)* 2006;45:19–24.
- [13] Xia EL. Transcervical resection of myoma. *J Pract Obstet Gynecol* 2005;21:387–9.
- [14] Hamerlynck TW, Blikkendaal MD, Schoot BC, et al. An alternative approach for removal of placental remnants: hysteroscopic morcellation. *J Minim Invasive Gynecol* 2013;20:796–802.
- [15] Cravello L, Agostini A, Beerli M, et al. Results of hysteroscopic myomectomy. *Gynecol Obstet Fertil* 2004;32:825–8.
- [16] Homer HA, Li TC, Cooke ID. The septate uterus: a review of management and reproductive outcome. *Fertil Steril* 2000;73:1–4.
- [17] Bradley LD. Complications in hysteroscopy: prevention, treatment and legal risk. *Curr Opin Obstet Gynecol* 2002;14:409–15.
- [18] Mazzon I, Favilli A, Grasso M, et al. Is cold loop hysteroscopic myomectomy a safe and effective technique for the treatment of submucous myomas with intramural development? A series of 1434 surgical procedures. *J Minim Invasive Gynecol* 2015;22:792–8.
- [19] Arnold A, Ketheeswaran A, Bhatti M, et al. A prospective analysis of hysteroscopic morcellation in the management of intrauterine pathologies. *J Minim Invasive Gynecol* 2016;23:435–41.
- [20] Lasmar RB, Barrozo PR, Dias R, et al. Submucous myomas: a new presurgical classification to evaluate the viability of hysteroscopic surgical treatment—preliminary report. *J Minim Invasive Gynecol* 2005;12:308–11.
- [21] Propst AM, Liberman RF, Harlow BL, et al. Complications of hysteroscopic surgery: predicting patients at risk. *Obstet Gynecol* 2000;96:517–20.
- [22] Jansen FW, Vredevoogd CB, van Ulzen K, et al. Complications of hysteroscopy: a prospective, multicenter study. *Obstet Gynecol* 2000;96:266–70.
- [23] Leone FP, Calabrese S, Marciante C, et al. Feasibility and long-term efficacy of hysteroscopic myomectomy for myomas with intramural development by the use of non-electrical “cold” loops. *Gynecol Surg* 2012;9:155–61.
- [24] Meulenbroeks D, Hamerlynck TW, Saglam-Kara S, et al. Hysteroscopic tissue removal systems: a randomized in vitro comparison. *J Minim Invasive Gynecol* 2017;24:159–64.