

# Newborn twins with perineal grooves

SAGE Open Medical Case Reports  
Volume 9: 1–4  
© The Author(s) 2021  
Article reuse guidelines:  
sagepub.com/journals-permissions  
DOI: 10.1177/2050313X211020222  
journals.sagepub.com/home/sco



Hannah M Rabinovich and Kimberly G Montez 

## Abstract

Twin girls born at term were noted to have hypertrophic and erythematous mucosal sulci extending from the posterior vaginal fourchette to the anterior ridge of the anus on their newborn exams. Pregnancy was complicated by gestational hypertension and dichorionic diamniotic twin pregnancy. No known traumas were sustained during delivery to either twin. Dermatology and obstetrics/gynecology were consulted who confirmed the diagnosis of perineal groove. Primary care follow-up was recommended, with referral to pediatric gynecology if the lesions did not epithelize by 2 years of age. Our case of perineal grooves is unique in that, to our knowledge, it is the first reported case of perineal grooves identified in both twins. Clinicians in the newborn nursery and primary care settings should perform routine genitourinary and anal examinations on all newborns to identify this benign lesion, which may limit misdiagnosis, inappropriate treatments, and invasive workups in the future.

## Keywords

Perineal groove, twins, newborn, pediatrics

Date received: 28 February 2021; accepted: 3 May 2021

## Introduction

Physical examinations are a crucial part of many medical diagnoses. Performing a thorough examination can, at times, limit additional laboratory work and imaging required which decreases unnecessary harm to patients and likely the cost of their care. In the case of perineal grooves, physical examination is the only diagnostic tool needed to confirm the diagnosis. However, perineal grooves are a commonly missed diagnosis due to medical providers' unfamiliarity with this examination finding.

A perineal groove is defined by three common features on physical examination: (a) moist appearing, erythematous midline sulcus, which generally extends from the posterior vaginal fourchette (or the scrotal raphe) to the anterior anal margin, (b) "hypertrophic minoral tails" that join posteriorly at or near the anus, and (c) normal formation of the vestibule, including the urethra and the anterior two-thirds of the vagina.<sup>1</sup> The anus itself is non-stenotic. Perineal grooves are classified in the "rare miscellaneous anorectal anomalies" group in the international classification proposed by Stephens et al.<sup>2</sup>

These grooves are midlines anomalies that occur during the development of perineal raphe. The exact origin of the perineal groove is unknown. However, current evidence suggests distorted embryological development of the urorectal septum at 5–8 weeks gestational age, which is believed to form the

perineal raphe.<sup>3,4</sup> This is concluded based on histological findings of non-keratinized stratified squamous epithelium, islands of cylindrical epithelium consistent with the colon and simple columnar or cuboidal epithelium common in rectal mucosa.<sup>5,6</sup> Other embryologic origins of the perineal groove are proposed, including a relic of an open cloacal duct or medial genital folds between the perineal raphe and the vestibule.<sup>3</sup>

We discuss a case of perineal grooves in twin females who were successfully diagnosed based on physical examination, with confirmation from obstetrics/gynecology and dermatology consultants. The routine examination of these infants by clinicians in the newborn nursery was essential to appropriate diagnosis.

## Case

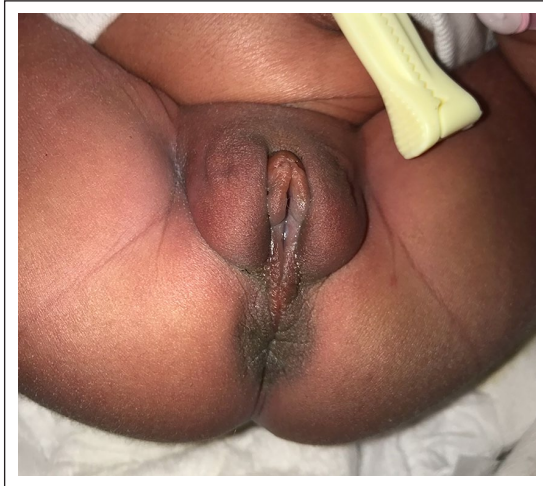
Twin girls presented to the newborn nursery after delivery. The infants were born at 37 weeks and 6 days gestation via

Department of Pediatrics, Wake Forest Baptist Medical Center, Wake Forest University Health Sciences, Winston-Salem, NC, USA

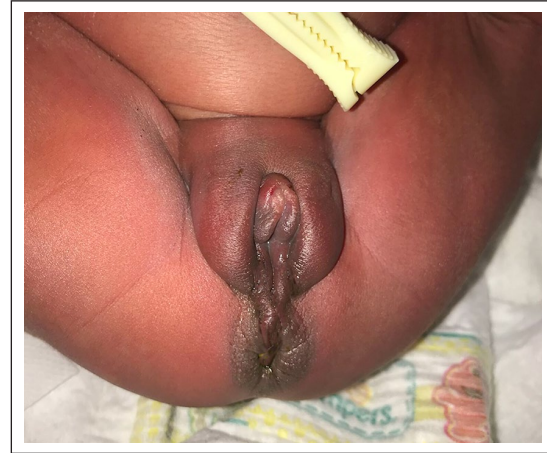### Corresponding Author:

Kimberly G Montez, Department of Pediatrics, Wake Forest Baptist Medical Center, Wake Forest University Health Sciences, One Medical Center Boulevard, Winston-Salem, NC 27157, USA.  
Email: kmontez@wakehealth.edu





**Figure 1.** Twin A has edema of the labia majora and minora as well as an erythematous, moist-appearing sulcus extending from the vaginal introitus to the anterior anus without bleeding or discharge. Anus is patent, normally placed, and centered in the sphincter.



**Figure 2.** Twin B has edema of the labia majora and minora as well as an erythematous, moist appearing, hypertrophic sulcus extending from the vaginal introitus to the anterior anus without bleeding or discharge. Anus is patent, normally placed, and centered in the sphincter.

spontaneous vaginal delivery to a 16-year-old gravida 1 mother. Screening laboratory studies were negative, including group B streptococcus, human immunodeficiency virus, hepatitis B, rapid plasma reagin, gonorrhea, and chlamydia. Complications during the pregnancy included gestational hypertension (diet controlled) and dichorionic diamniotic twin pregnancy. The mother had no significant medical history and denied taking any medications during pregnancy. She also denied tobacco, alcohol, or illicit drug use.

Delivery was complicated by a breech vaginal delivery for twin B. Apgar scores were 7 at 1 min and 8 at 5 min, respectively, for twin A, and 7 at 1 min and 8 at 5 min, respectively, for twin B.<sup>7</sup> Birthweight was 2890 g (22nd percentile) for twin A and 2800 g (16th percentile) for twin B. Neither twin sustained any trauma during delivery.

Physical examination in the newborn nursery revealed hypertrophic, erythematous and wet appearing mucosal sulci extending from the posterior vaginal fourchette to the anterior ridge of the anus in both twins (Figures 1 and 2). Anus was normally placed, centered in the sphincter, and patent with an anal wink present in both twins. Urethral and vaginal openings were present and in appropriate locations on both exams. The remainder of the newborns' exams were unremarkable. Written informed consent for patients' images to be used for medical purposes was obtained from the mother of the twins.

Consultation was made to pediatric dermatology and obstetrics/gynecology who agreed with the diagnosis and recommended no further intervention. The twin infants had benign neonatal courses in the newborn nursery without development of complications. Screening tests including critical congenital heart disease and hearing screenings were passed for both twins.

The twins were discharged home with primary care follow-up and a recommendation of referral to pediatric gynecology if the lesions did not epithelize by 2 years of age. No additional follow-up data are available regarding the twins as they are followed for primary care at a health department in a different county.

## Discussion

The incidence of perineal grooves remains unclear, with only a limited amount of published literature on the subject and most are case reports. Based on published case reports, conditions associated with perineal grooves may include maternal conditions such as gestational diabetes; other patients with perineal grooves described mothers with pre-eclampsia, placenta previa, and group-B streptococcal infections.<sup>3,8,9</sup> Maternal age is not a known associated condition, although in one case report, in addition to this case report, the mother was a teenager.<sup>10</sup>

The diagnosis of perineal groove is made clinically; the majority of patients with perineal grooves present asymptotically aside from the perineal defect. The differential diagnosis of perineal lesions varies based on age at presentation. When a perineal lesion is noted in neonates, the differential diagnosis includes trauma during birthing, perianal pyramidal protrusion, and perineal grooves. A thorough birth history and newborn physical examination will help identify the appropriate diagnosis. For perineal lesions identified in older infants and children, the clinician should consider alternative diagnoses, such as anal fissures, perineal ulcers, traumatic tears, sexual abuse, infection, contact irritant dermatitis, lichen sclerosus et atrophicus, perianal pyramidal protrusion, and perineal groove. Sexual abuse is a common concern in patients presenting with similar physical examinations beyond the neonatal period; however, patients often have additional findings such as

bruising or injuries around the thighs, vagina or anus, anal tears, lacerations with irregular edges, or dilation of the anus.<sup>11</sup> Perianal pyramidal protrusion can present congenitally or develop over time; it may present as asymptomatic, pyramidal soft tissue protrusions generally located over the perineal median raphe anterior to the anus.<sup>12</sup> Accounting for age at presentation, in addition to a thorough history and physical examination, can narrow the differential.

While comorbid conditions are rare, there have been reported cases in which perineal grooves were associated with other urologic or genital anomalies such as urinary tract abnormalities, anorectal malformations, ectopic anus, vestibular fistula, and rectal prolapse.<sup>5,13,14</sup> There have been reports of hypospadias and bifid scrotum; however, these are exceedingly uncommon as perineal grooves are rare in males.<sup>15</sup> Complications of perineal grooves are also uncommon but can include constipation, recurrent skin infections, mucus drainage, and urinary tract infections.<sup>10,16</sup> Due to the anal canal being continuous with the wet perineal sulcus, the anterior anal wall may be prone to prolapse.<sup>1</sup> It is recommended these patients be followed closely until the lesion resolves.

Perineal grooves typically do not require treatment as they most often spontaneously epithelialize, commonly at ages 1–2 years.<sup>17</sup> However, there are reports of delayed epithelialization for several years. A recent case series from a single institution found that for the 14 patients who were followed beyond 2 years of age, 71% had natural healing of their perineal groove.<sup>18</sup> Treatment attempts with topical barrier or antifungal preparations have been unsuccessful, and there are no known association with perineal grooves and bacterial or fungal infections at birth.<sup>19</sup> Therefore, current recommendations include supportive management unless complications arise. Surgical intervention may be beneficial in children over 2 years of age with repeated infections to the perineal groove or surrounding genitalia, lack of spontaneous epithelialization, or if there are cosmetic concerns.<sup>3,20</sup> Parents of children who have undergone surgical intervention should closely monitor the area as there are high rates of postoperative dehiscence secondary to frequent contamination by urine and feces in this age group.<sup>5,19</sup>

This condition is known to be significantly more common in females than males. A recent review of the literature from 2018 found only 36 cases to date of perineal grooves, one of whom was in a male.<sup>13,14</sup> An additional case series from Korea examined 26 cases of pediatric patients diagnosed with perineal grooves from 2012 to 2018 and reported only one male with associated findings.<sup>18</sup> Aside from the perineal groove, these infants tended to be healthy overall with generally no symptoms related to the anomaly. Although the true incidence of perineal grooves is unknown, it may be higher than reported for both sexes due to underdiagnosis, possibly secondary to clinicians' unfamiliarity with examination findings for perineal grooves. A retrospective cohort of 66 pediatric patients managed at 10 colorectal centers from 1999 to 2019 reported that only 9% of patients were correctly diagnosed with

perineal grooves by their primary care physician.<sup>20</sup> Often cases are not identified in the immediate newborn period, as evidenced by the age at presentation of infants in case studies. Instead, patients present to specialists such as dermatology after failed treatment for irritant diaper dermatitis, or in the emergency room as concern for sexual abuse.<sup>6,8</sup> These misdiagnoses often lead to unnecessary and invasive interventions that can potentially be avoided with increased clinical education regarding perineal grooves.

Our case of perineal grooves is unique in that, to our knowledge, this is the first reported case of perineal grooves identified in both twins. There is one case of a perineal groove in one dichorionic diamniotic twin female who was born at term; however, the other twin was unaffected.<sup>9</sup> The specific mechanism of perineal groove development in both twins is currently unknown and is an area for further research.

## Conclusion

This case represents how an appropriate and timely diagnosis of perineal grooves in the newborn nursery and primary care settings, via routine genitourinary and anal examinations may help limit misdiagnosis, inappropriate treatments, and invasive workups in the future. Further research is needed to determine the etiology of perineal grooves in twins.

## Acknowledgements

The authors thank Dr. Daniel Krowchuk for his critical review of the manuscript.

## Declaration of conflicting interests

The author(s) declared no potential conflicts of interest with respect to the research, authorship, and/or publication of this article.

## Ethical approval

Our institution does not require ethical approval for reporting individual cases or case series.


## Funding

The author(s) received no financial support for the research, authorship, and/or publication of this article.

## Informed consent

Written informed consent was obtained from a legally authorized representative(s) for anonymized patient information to be published in this article.

## ORCID iD

Kimberly G Montez  <https://orcid.org/0000-0003-0247-3664>

## References

1. Stephens FD and Smith ED. *Ano-rectal malformations in children*. 2nd ed. Chicago, IL: Year Book Medical Publishers, 1971.

2. Stephens FD, Smith ED and Paul NW. *Anorectal malformations in children: update*. New York: Alan Liss, 1988.
3. Harsono M and Pourcyrus M. Perineal groove: a rare congenital midline defect of perineum. *AJP Rep* 2016; 6(1): e30–e32.
4. Mullassery D, Turnock R and Kokai G. Perineal groove. *J Pediatr Surg* 2006; 41: e41–e43.
5. Esposito C, Giurin I, Savanelli A, et al. Current trends in the management of pediatric patients with perineal groove. *J Pediatr Adolesc Gynecol* 2011; 24(5): 263–265.
6. Granillo SF, Garone A, Molina LT, et al. Perineal groove: report of three cases. *J Dermatol* 2018; 3: 1–3.
7. American Academy of Pediatrics CoF, Newborn, American College of O, , et al. The Apgar score. *Pediatrics* 2006; 117: 1444–1447.
8. Diaz L, Levy ML, Kalajian A, et al. Perineal groove: a report of 2 cases. *JAMA Dermatol* 2014; 150: 101–103.
9. Hunt L and Srinivas G. Visual diagnosis: newborn with a perineal lesion. *Pediatr Rev* 2016; 37: e1–e3.
10. Cheng H, Wang Z, Zhao Q, et al. Perineal groove: report of two cases and review of the literature. *Front Pediatr* 2018; 6: 227.
11. Senanayake S and Tennakoon U. Perineal groove leading to a suspicion of child abuse. *Ceylon Med J* 2014; 59: 147–148.
12. Zavras N, Christianakis E, Tsamoudaki S, et al. Infantile perianal pyramidal protrusion: a report of 8 new cases and a review of the literature. *Case Rep Dermatol* 2012; 4(3): 202–206.
13. Wojciechowski M, Van Mechelen K and Van Laere D. Congenital perineal groove. *Arch Dis Child* 2019; 104: 286.
14. Chatterjee SK, Chatterjee US and Chatterjee U. Perineal groove with penoscrotal hypospadias. *Pediatr Surg Int* 2003; 19(7): 554–556.
15. Verma SB and Wollina U. Perineal groove—a case report. *Pediatr Dermatol* 2010; 27(6): 626–627.
16. Tambe S, Kerland Lang K and Saple DG. Perineal groove: a rare congenital anomaly. *Eur J Pediatr Dermatol* 2015; 25: 16–19.
17. Kadowaki H, Nkahira M, Yamada C, et al. Perieal groove and perineal canal. *Jpn J Surg* 1983; 13: 216–218.
18. Ihn K, Na Y, Ho IG, et al. Clinical characteristics and conservative treatment of perineal groove. *J Pediatr Surg* 2020; 55(8): 1507–1510.
19. Boutsikou T, Mougou V, Sokou R, et al. Four cases of perineal groove—experience of a Greek Maternity Hospital. *Medicina* 2019; 55: 488.
20. Samuk I, Amerstorfer EE, Fanjul M, et al. Perineal groove: an anorectal malformation network, consortium study. *J Pediatr* 2020; 222: 207–212.