



## Case report

## Sewing machine needle retrieval from distal airways using flexible bronchoscope under fluoroscopy



Talha Mahmud\*, Adnan Shafiq, Abdul Hafeez, Muhammad Saqib, Sidrah Farooq

Shaikh Zayed Hospital, FPGMI, Lahore, Pakistan

## ARTICLE INFO

## Article history:

Received 29 May 2016

Accepted 24 June 2016

## Keywords:

Bronchoscopy

Fluoroscopy

Metallic foreign body

Sewing machine needle

## ABSTRACT

18-year-old lady was admitted through emergency department after she accidentally aspirated a long sewing machine needle into her airways. Upon examination, she was anxious with normal vital signs and without any respiratory distress with SpO<sub>2</sub> of 98% on air. Systemic examination was normal except slightly reduced breath sounds intensity on right lower side of chest. Her chest radiograph revealed needle in right lower lobe but it was not visualized on bronchoscopic examination of airways up to sub segmental level. Using flexible bronchoscope under fluoroscope guidance, needle was retrieved successfully from posterior basal sub segment of right lower lobe utilizing alligator biopsy forceps, without any noticeable complication.

© 2016 Published by Elsevier Ltd. This is an open access article under the CC BY-NC-ND license (<http://creativecommons.org/licenses/by-nc-nd/4.0/>).

## 1. Introduction

Tracheobronchial foreign body aspiration (FBA) is uncommon in adults compared to children [1]. In pediatric population, organic material like nuts or toy parts account for majority of FBA; in young or middle-aged adults nail or pin aspiration occurs especially during do-it-yourself activities while in elderly population, aspiration of dental debris, appliances, or prostheses are mainly responsible for FBA [2]. Although rigid bronchoscopy is the standard of care, flexible bronchoscopy is the cornerstone for the diagnostic evaluation of FBA in adults and should be the first procedure for FB extraction in adults only if the operator is skilled in the extraction technique, and the appropriate resuscitative equipment and personnel and back up thoracic surgical services are available [1,2].

## 1.1. Case report

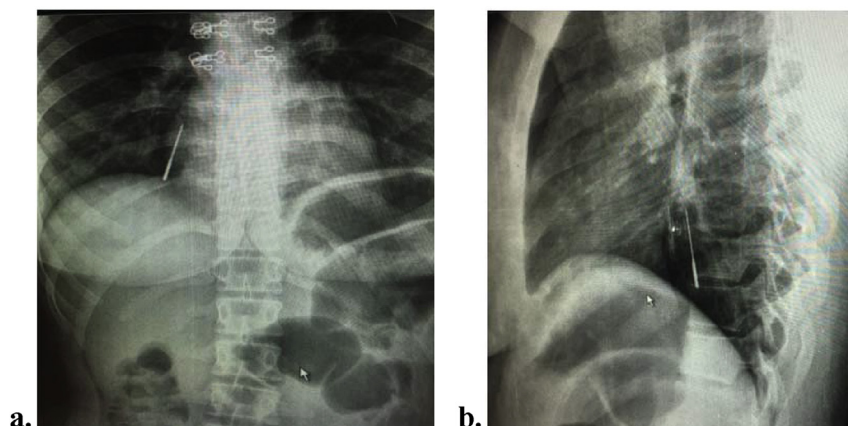
18-year-old unmarried never smoker house lady was evaluated in emergency department due to ingestion/aspiration of a sewing machine needle. Her past, family, personal, and treatment history details were not contributory. According to her, she was holding the sewing machine needle in her lips during her working on the machine when she was poked by her sister and during laughter the needle went into her body through the mouth. It was followed by a bout of cough and retching. She was brought to emergency

department and was found to be anxious with a pulse of 90/m, blood pressure 110/75 mmHg, temperature 37 °C, respiratory rate 18 and SpO<sub>2</sub> of 98% on ambient air. There was mild tenderness in epigastrium and slight reduced breath sounds intensity in right lower part of chest while remaining general and systemic examination was unremarkable. She was evaluated by the gastroenterology team who performed her upper gastrointestinal endoscopy in search of the lost needle which was not seen in esophagus or the stomach.

She was admitted under care of pulmonology department after her chest radiographs postero-anterior and lateral views (Fig. 1a and b) revealed needle with its sharp stitching/cutting end facing cranially and lodged in right lower lobe. Next day she underwent flexible fiberoptic bronchoscopy (first by bronchoscope with 2.8 mm diameter working channel followed by scope of 2.2 mm channel) and surprisingly the needle was not visualized on bronchoscopic examination of right sided airways up to sub segmental level, because of dislodgement of needle into distal small airways/lung parenchyma. Thoracic surgeon advised bronchotomy under general anesthesia but prior to that repeat bronchoscopy was planned under fluoroscope guidance to retrieve the lost needle from the distal airways. Using boluses of procedural sedation (midazolam 4 mg total) and analgesia (fentanyl 75 mcg total), she underwent bronchoscopy under fluoroscope guidance. Bronchoscope (nasal insertion) was passed as distally as it could enter the posterior basal segment of right lower lobe and was finally wedged when it came head-on with the needle's sharper end. After repeated attempts of grasping and slipping away (55 min), sewing machine needle (3.8 cm) was finally grasped through its sharper end using alligator/

\* Corresponding author.

E-mail address: [drmtalha72@gmail.com](mailto:drmtalha72@gmail.com) (T. Mahmud).



**Fig. 1.** (a) PA view chest radiograph and (b) lateral view showing sewing machine needle in right lower lobe.

toothed biopsy forceps and was mobilized by slight to and fro movements followed by its successful retrieval (Fig. 2a and b). The bronchoscope, needle and biopsy forceps were withdrawn en masse from bronchi, trachea, larynx and very slowly rotating through nose without any harm to the tract. There was mild oozing of blood through the involved segment that was controlled by topical epinephrine spray with ice cold saline flushing. Follow up post procedural and 12 hours later chest radiographs showed no complication and patient was safely discharged from hospital.

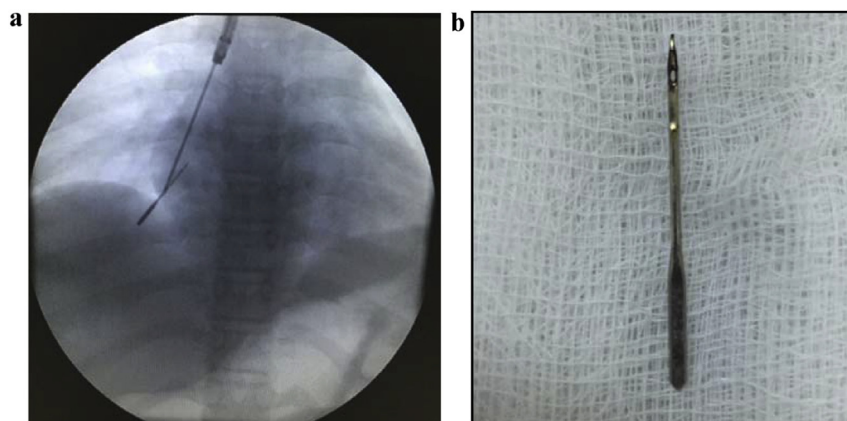
## 2. Discussion

Following FBA, acute presentation is rare in adults, since the FB usually is wedged distally in lower lobe bronchi or the bronchus intermedius [1]. Cough is the commonest symptom (80%), dyspnea is uncommon (25%) and other associated symptoms include fever, hemoptysis, wheeze, or chest pain [1,3]. Cyanosis, subcostal retraction, reduction of breath sounds, stridor and high fever due to superadded lung infections or sudden death may occur [1].

The diagnosis of FBA in adults is straight forward if it is witnessed by the patient followed by choking or coughing episode and/or the opaque FB is clearly visible on chest radiograph/computed tomography [2,4]. However, special imaging techniques may be needed to localize radiolucent organic materials both in children and adults [1]. In forgotten FBA or when a radiolucent foreign body is aspirated, diagnosis can be overlooked and may be noted unexpectedly during flexible bronchoscopy performed for

symptoms of endobronchial disease, such as chronic cough, hemoptysis, asthma not responding to therapy, or recurrent/non-resolving pneumonia [1,4].

Our patient although had a precise history of aspiration and metallic FB (sewing machine needle) was clearly visible on chest radiograph with lower lobe hyperinflation, even then there was initial diagnostic confusion that lead to upper gastrointestinal endoscopy. In a similar reported case from Iran, a female aspirated a turban pin into right main bronchus that was removed using rigid bronchoscope under general anesthesia [5]. The success rates of flexible fibreoptic bronchoscopic extraction of FBs in adults range from 60 to 90% [6]. In the index case, initial diagnostic bronchoscopy could not find the lost needle in the respiratory tract and it was only possible when flouroscope guidance was used that also provides a potentially newer diagnostic avenue for the interventional pulmonologists to remove FBs. This case is also unique because it prevented thoracotomy and lead to successful removal of distally placed needle in the smaller airways whose grasping by the biopsy forceps, was another challenge and took 55 min because of repeated grasping and slipping attempts. In a large case series of scarf pins aspirations, diagnostic flexible bronchoscopy when performed in first intention in 61 cases lead to the extraction in 83.6% of cases and rigid bronchoscopy and thoracotomy was required in 4.9% of cases each modality respectively [6]. We could not find a similar case where sewing machine needle was aspirated, dislodged in distal smaller airways/parenchyma and required flexible bronchoscopy using conscious sedation under flouroscope guidance for its successful removal.



**Fig. 2.** (a) grasping of needle with biopsy forceps through bronchoscope under fluoroscopy and (b) retrieved needle (3.8 cm).

### 3. Conclusion

Distally placed sewing machine needle/sharp metallic FB removal by flexible bronchoscope using conscious sedation and analgesia under flouroscope is potentially a safe procedure and should be attempted before considering the patient for surgical bronchotomy. Further studies are required to utilize flouroscope guidance in diagnostic bronchoscopy in similar cases.

### References

- [1] F. Baharloo, F. Veyckemans, C. Francis, M.P. Bieltlot, D.O. Rodenstein, Tracheobronchial foreign bodies: presentation and management in children and adults, *Chest* 115 (1999) 1357.
- [2] S.M. Weber, M.S. Chesnutt, R. Barton, J.I. Cohen, Extraction of dental crowns from the airway: a multidisciplinary approach, *Laryngoscope* 115 (2005) 687.
- [3] A.L. Rafanan, A.C. Mehta, Adult airway foreign body removal. What's new? *Clin. Chest Med.* 22 (2001) 319.
- [4] K. Mise, A. Jurcev Savicevic, N. Pavlov, S. Jankovic, Removal of tracheobronchial foreign bodies in adults using flexible bronchoscopy: experience 1995–2006, *Surg. Endosc.* 23 (2009) 1360–1364.
- [5] H. Gonullu, Y. Ozturk, S. Akay, M. Boncu, N. Erkan, Turban pin: an unusual cause of foreign body aspiration in young islamic adult, Iran. *Red. Crescent Med. J.* 16 (2014) e2975.
- [6] A. Hebbazi, W.E. Khatabi, R. Bopaka, H. Jabri, H. Afif, Inhalation of scarf pin: emerging respiratory emergency, *Pan Afr. Med. J.* 22 (2015) 277.

[1] F. Baharloo, F. Veyckemans, C. Francis, M.P. Bieltlot, D.O. Rodenstein,