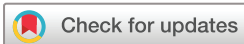

The natural course of IgG4-related ophthalmic disease after debulking surgery: a single-centre retrospective study

Jun Ominato,¹ Tokuhide Oyama,^{1,2} Hiroyuki Cho,¹ Naoya Shiozaki,¹ Hajime Umezu,³ Jun Takizawa,⁴ Takeo Fukuchi¹

To cite: Ominato J, Oyama T, Cho H, *et al*. The natural course of IgG4-related ophthalmic disease after debulking surgery: a single-centre retrospective study. *BMJ Open Ophthalmology* 2019;4:e000295. doi:10.1136/bmjophth-2019-000295

Received 4 March 2019
Revised 22 May 2019
Accepted 11 June 2019



© Author(s) (or their employer(s)) 2019. Re-use permitted under CC BY-NC. No commercial re-use. See rights and permissions. Published by BMJ.

¹Division of Ophthalmology and Visual Science, Niigata University Graduate School of Medical and Dental Sciences, Niigata, Japan

²Uonuma Eye Clinic, Uonuma, Japan

³Department of Pathology, Niigata University Medical and Dental Hospital, Niigata, Japan

⁴Department of Hematology, Endocrinology and Metabolism, Niigata University Faculty of Medicine, Niigata, Japan

Correspondence to

Dr Jun Ominato; menlove@med.niigata-u.ac.jp

ABSTRACT

Objective This study aimed to examine the natural course and relapse rate of IgG4-related ophthalmic disease (IgG4-ROD) after debulking surgery in Japanese patients.

Methods and analysis This retrospective review included patients with IgG4-ROD who did not undergo further treatment following debulking surgery. The patients were diagnosed between January 2009 and December 2018 at the Department of Ophthalmology and Pathology, Niigata University Medical and Dental Hospital. The main outcome measures included postoperative IgG4-ROD recurrence rate and differences between patients with and without recurrent disease.

Results Fifteen patients (six male, 9 female; 61.8±16.2 years) were included. Twelve patients (80.0%) had dacryoadenitis disease and three patients (20.0%) had orbital fat tissue disease. About 70%–100% of the lesion was resected in the debulking surgery and the pathological diagnosis was rendered. A definitive diagnosis was made in 13 cases (86.7%) and a probable diagnosis in 2 cases (13.3%). Patients were followed up for 39.0±25.5 months following operation. All patients had lesion volume reduction and patients with dacryoadenitis had eyelid swelling improvement after surgery. Two patients (13.3%) had disease recurrence and six patients (40.0%) had extraocular lesions. There was no statistically significant difference in clinical features between relapsed and non-relapsed cases.

Conclusion We observed a 13.3% relapse rate following debulking surgery in patients with IgG4-ROD who did not undergo further treatment. This rate is lower than the documented relapse rate of 30%–70% following oral prednisolone therapy. Therefore, debulking surgery may be a treatment option for IgG4-ROD.

INTRODUCTION

IgG4-related diseases (IgG4-RDs) are newly classified, immune-mediated, fibroinflammatory conditions that are characterised by affected organ enlargement, lymph plasma cell infiltration (determined with IgG4-positive plasma cells) and serum IgG4 level elevation.¹ Essentially, any organ can be affected by IgG4-RD, but the most commonly affected tissues include the pancreas, salivary

Key messages

What is already known about this subject?

- ▶ The first choice of treatment for IgG4-related ophthalmic disease (IgG4-ROD) is oral steroid administration. However, the relapse rate is approximately 30%–70% following this treatment.

What are the new findings?

- ▶ The relapse rate of IgG4-ROD following debulking surgery with no systemic therapy was 13.3%.

How might these results change the focus of research or clinical practice?

- ▶ The relapse rate after debulking surgery was lower than that after oral steroid treatment; therefore, debulking surgery is a viable treatment option for IgG4-ROD.

glands, kidneys, retroperitoneum, periorbital tissue and lymph nodes.^{2–3} When IgG4-RD affects the periocular tissues, the condition is called IgG4-related ophthalmic disease (IgG4-ROD). IgG4-ROD includes Mikulicz's disease and some of the diseases formerly referred to as idiopathic orbital inflammatory conditions or reactive lymphoid hyperplasia.^{4–5} Goto *et al* proposed the diagnostic criteria for IgG4-RODs in 2015.⁶

Oral steroid administration is the first-line therapy for IgG4-ROD and patients generally exhibit a good treatment response. However, recurrence occurs in more than half of the patients during oral steroid dose tapering, prolonging treatment and subsequently increasing the risk of steroid-related complications.^{7–9} Therefore, alternative therapies, including immunosuppressive drugs and rituximab, have been examined and validated.^{10–11} However, few studies have investigated the efficacy of IgG4-RD lesion resection alone.¹² The current study examines the natural course and recurrence rate of IgG4-ROD in patients who underwent a

diagnostic debulking surgery and no additional systemic steroid therapy.

Patients and methods

Because of this study's retrospective nature, a formal consent process was replaced with a written opt out form. None of the included patients signed and returned the opt out form. The study conduct adhered to the tenets of the Declaration of Helsinki.

Study patients

This retrospective records review included data of patients diagnosed with IgG4-ROD using surgical biopsy. All patients were diagnosed at the Department of Ophthalmology and Pathology, Niigata University Medical and Dental Hospital (Niigata, Japan) between January 2009 and December 2018 and did not undergo further treatment after surgery. Patients with a postoperative observation period of less than 6 months were excluded from this study. Biopsy surgery was based on debulking surgery and resectable lesions were removed as much as possible within a safe range. The IgG4-ROD diagnosis was based on the criteria proposed by Goto *et al.*⁶ This study included cases of both definite and probable disease.

Data collection and analyses

Data were collected from patient medical records and included age, sex, postbiopsy follow-up period and orbital lesion type.¹³ Preoperative serum levels of IgG4, IgG, IgE and soluble interleukin-2 receptor (sIL-2R) were recorded, along with data on the presence/absence of immunoglobulin heavy chain (IgH) rearrangement, extraocular lesions and relapse. IgH rearrangement was examined using Southern blotting or PCR. The data on the extent of removal of the lesion in the operation were extracted from the operation records. Recurrence was defined as the return of symptoms (eg, eyelid swelling) or an increase in lesion size as confirmed using CT. The period between biopsy and relapse was noted in patients with recurrent disease. The collected data were used to determine recurrence rates following debulking surgery and clinical differences between the recurrent and non-recurrent groups.

Data are presented as mean±SD where applicable. Unpaired Student's t-test, Welch test and Mann-Whitney U test were used to examine the between-group differences in continuous data. Fisher's exact test was used to examine differences in categorical data. All statistical analyses were performed using SPSS statistical software (V.23.0) and statistical significance was defined as $p < 0.05$.

RESULTS

A total of 15 patients (6 male, 9 female) were included in this study. The average patient age was 61.8±16.2 years, and the average postoperative follow-up period was 39.0±25.5 months. Twelve cases (80.0%) were classified as dacryoadenitis IgG4-ROD and three cases (20.0%)

Table 1 Clinical characteristics of patients with IgG4-related ophthalmic disease who underwent debulking surgery

Patients, n	15
Age, years	61.8±16.2
Men	6 (40.0)
Postoperative observation period, months	39.0±25.5
Orbital lesion type	
Dacryoadenitis	12 (80.0)
Orbital fat tissue	3 (20.0)
IgG4-ROD diagnosis	
Definite	13 (86.7)
Probable	2 (13.3)
Lesion laterality	
Unilateral	8 (53.3)
Bilateral	7 (46.7)
Relapse	2 (13.3)
Extraocular lesions	6 (40.0)

Data are presented as mean±SD deviation and n (%) as applicable.

IgG4-ROD, IgG4-related ophthalmic disease.

were classified as orbital fat tissue IgG4-ROD. Seven out of 12 cases of the dacryoadenitis type were bilateral in nature. Six out of the seven bilateral cases involved operation on the bilateral lesions in the same surgery. One bilaterally affected case involved the operation of only the unilateral lesions. The diagnosis was definite in 13 cases (86.7%) and probable in 2 cases (13.3%, table 1). Debulking surgery reduced the lesion volume in all cases and improved eyelid swelling in all 12 dacryoadenitis cases (figure 1). In three cases involving the orbital fat tissue, it was possible to completely extirpate the lesion. In 12 operated dacryoadenitis cases involving 18 sides, 90% or more of the lesions could be removed from 17 sides; only 70% of the lesions was resected on the remaining one side. Seven patients with dacryoadenitis developed dry eyes after surgery; however, it was possible to control this using eyedrops, and the quality of vision was not impaired in any of the cases. Three cases involving the orbital fat tissue did not cause complications.

Two cases of relapse after biopsy (13.3%) were noted during the follow-up period. Serum IgG4, sIL-2R and IgE levels were not significantly different between patients with and without recurrence (table 2). Among the relapsed patients, 90% or more of the lesions were resected in the unilateral dacryoadenitis type in both the cases. In case 1, ipsilateral eyelid swelling occurred 6 months after debulking surgery, and the CT showed an increase of the lacrimal gland lesion. Re-resection of the lesion was performed; however, it recurred again. The pathological diagnosis was IgG4-ROD, same as diagnosed previously, and IgH rearrangement was also not detected. In case 2, the ipsilateral lacrimal gland swelling was

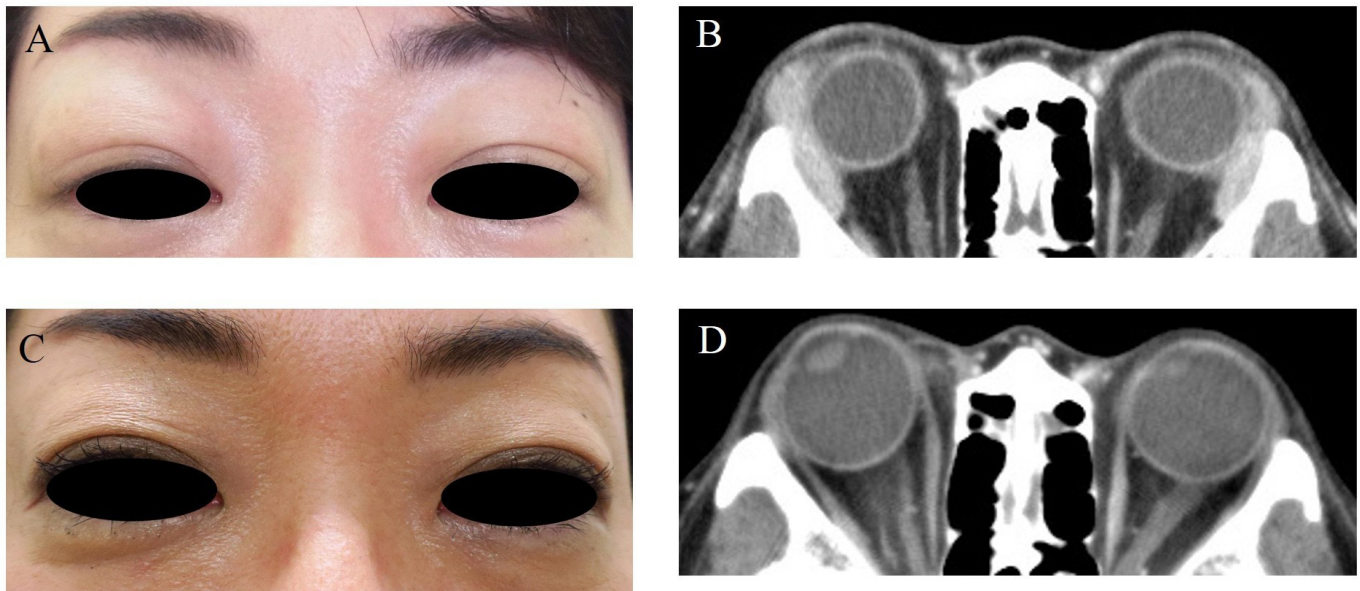


Figure 1 External ophthalmic photographs and enhanced CT images of a 40-year-old woman with dacryoadenitis IgG4-related ophthalmic disease. (A) Eyelid swelling and palpable masses on the orbital rim were present prior to debulking surgery. (B) An enhanced CT image shows bilateral enlargement of the lacrimal glands prior to debulking surgery. (C) Eyelid swelling had markedly improved 3 months after debulking surgery. (D) An enhanced CT image obtained 30 months after debulking surgery shows resolution of lacrimal gland enlargement.

confirmed with a follow-up CT 17 months after debulking surgery. However, the patient did not have swelling of the eyelids and was followed up, and then the swelling of the lacrimal gland regressed spontaneously (table 3).

We compared nine cases with only ophthalmic lesions and six cases with extraophthalmic lesions. Serum IgG4 and sIL-2R levels were significantly higher in patients with extraophthalmic lesions than in those with localised ophthalmic disease ($p=0.02$ and 0.03 , respectively). There was no significant difference between the groups in terms of serum IgG or IgE levels (table 4). All six cases with extraophthalmic lesions exhibited enlarged salivary glands. There were two cases with swelling of the pelvic lymph nodes in addition to swelling of the salivary glands. In another case, autoimmune pancreatitis was suspected

in addition to salivary gland and pelvic lymph node enlargement. Except for one patient who was treated with dry mouth associated with salivary adenitis, the patient was followed up without any symptoms. None of the all 15 cases tested positive for IgH rearrangement.

DISCUSSION

This study examined 15 Japanese patients with IgG4-ROD who underwent debulking surgery with no further treatment during the follow-up period. We found a relapse rate of 13.3% in these patients over an average postoperative follow-up period of 39 months.

The standard treatment for both IgG4-RD and IgG4-ROD is oral steroids,^{7 14 15} but the disease has a high recurrence rate. Ebbo *et al* reported that 13 of 19 cases

Table 2 Clinical characteristics of IgG4-related ophthalmic disease patients with and without recurrent disease

	Recurrent disease	Non-recurrent disease	P values
Patients, n	2 (13.3)	13 (86.7)	–
Age, years	65.0±4.2	61.3±17.4	0.78*
Follow-up period, months	58 (44/72)	34 (6/84)	0.17†
Serum levels			
IgG4, mg/dL	143.0±14.1	315.0±181.7	0.22*
sIL-2R, U/mL	368.0 (±8.5)	556.3 (±282.1)	0.38*
IgG, mg/dL	1248.5 (±94.0)	1708 (±303.9)	0.06*
IgE, IU/mL	186.0 (±99.0)	716.9 (±646.8)	0.23†

Data presented as mean±SD deviation or median (minimum /maximum) or n (%) as applicable.

*Calculated using Student's t-test.

†Calculated using Mann-Whitney U test.

sIL-2R, soluble interleukin-2 receptor.

Table 3 Relapsed cases of IgG4-related ophthalmic disease after debulking surgery

	Sex	Age (years)	Type of lesion	Diagnosis of IgG4-ROD	Period until relapse (months)	Relapse lesion	Treatment for relapsed lesion	Course after treatment
Case 1	F	68	Unilateral DA	Probable	6	Ipsilateral LG	Resection	Relapse and observation
Case 2	F	62	Unilateral DA	Definite	24	Ipsilateral LG	Observation	Spontaneous regression

DA, dacryoadenitis; F, female; IgG4-ROD, IgG4-related ophthalmic disease; LG, lacrimal gland; M, male.

(68.4%) of IgG4-ROD relapsed after the first course of oral steroids.¹⁶ Suimon *et al* reported that 5 of 15 cases (33%) of IgG4-ROD treated with systemic corticosteroids showed recurrence.¹⁷ Karim *et al* reported the relapse rate as 62% for IgG4-ROD, including IgG4-ROD.¹² Additionally, the required systemic steroid course may be long, for example, some clinicians recommend the use of low-dose oral steroid maintenance therapy for up to 3 years in autoimmune pancreatitis.¹⁴ The results of the current study showed that lesion volume decreased after excisional biopsy and the relapse rate was approximately 13%, much lower than the 33%–68% documented for systemic steroid therapy.^{9 12 16 17} In patients with dacryoadenitis disease, lesion debulking surgery improved eyelid swelling without severe complications. These results suggest that debulking surgery is an effective treatment option for IgG4-ROD. This is especially true for both the dacryoadenitis and orbital fat tissue type lesions, which are often clear masses that can be partially or completely removed at the time of biopsy. IgG4-ROD is characterised by high lymphocytic infiltration and fibrosis, infiltration of a number of IgG4-positive plasma cells and formation of mass lesions in the target organs.¹⁶ As debulking surgery resects the lesions and the target organs involved in the disease simultaneously, it can be inferred that the recurrence rate with this treatment modality may be

lower compared with steroid therapy, where the target organs are preserved. However, extraocular muscle and trigeminal nerve enlargement IgG4-ROD¹⁸ may not be best treated with debulking surgery because lesion debulking is difficult in these cases in view of complexity of the surgery. When surgical excision is difficult, treatment with corticosteroids or immunosuppressants is likely necessary.¹³

In the current study, patients with and without recurrence were examined and compared. No significant differences in serum IgG4, sIL-2R, IgG or IgE levels were found between the two groups. Suimon *et al* compared IgG4-ROD cases treated with systemic corticosteroids in recurrence and non-recurrence groups.¹⁷ There was no significant difference in the clinicopathological features, including serological examination results, between the two groups. There was also no difference between the recurrence and non-recurrence groups after surgical treatment in the present study, and it is still considered difficult to predict cases of recurrence of IgG4-ROD on the basis of clinical data.

This study compared IgG4-ROD patients with and without extraocular lesions. More specifically, serum IgG4, sIL-2R, IgG and IgE levels were examined. Serum IgG4 and sIL-2R levels were significantly higher in patients with extraocular lesions. This finding is in agreement with that of the study by Kubota *et al*. They reported that there was a significant incidence of extraocular lesions in Japanese patients with IgG4-ROD with a serum IgG 4 level of ≥ 900 mg/dL than in those with a serum IgG4 level of < 900 mg/dL, and the level of serum sIL-2R was also significantly higher in the high IgG4 group.¹⁹ Park *et al* also examined risk factors for extraocular progression in Korean patients with IgG4-ROD. They found that an elevated serum IgG4 level plays an important role in extraocular progression.¹³ Given the results of the current study and previous reports, IgG4 and sIL-2R have the potential to be indicators of extraocular lesions in IgG4-ROD.

This study had several limitations. First, this study was based on a non-controlled survey and non-controlled treatment protocol. Second, our study focused on follow-up observations that were made after IgG4-ROD resection, which likely introduced a selection bias. Patient follow-up period also widely varied between 6 and 84 months, which may have influenced our recurrence rates. Therefore, further studies with a uniform follow-up

Table 4 Clinical features of IgG4-related ophthalmic disease patients with and without extraophthalmic lesions

	Extraophthalmic lesions	Ophthalmic lesion only	P values
Patients, n	6 (40.0)	9 (60.0)	
Age, years	55.8 \pm 22.9	65.8 \pm 9.2	0.26‡
Serum levels			
IgG4, mg/dL	421.5 \pm 196.2	205.7 \pm 104.4	0.02*
sIL-2R, U/mL	712.8.0 \pm 327.2	410.1 \pm 137.6	0.03‡
IgG, mg/dL	1807.2 \pm 257.4	1540.1 \pm 334.5	0.12*
IgE, IU/mL	560.8 \pm 485.3	703.0 \pm 730.4	0.56§
Relapsed cases	0/6 (0)	2/9 (22.2)	0.49†

Data presented as mean \pm SD deviation or n (%) as applicable.

Bolded p values indicate statistical significance.

*Calculated using Student's t-test.

†Calculated using Fisher's exact test.

‡Calculated using Welch test.

§Calculated using Mann-Whitney U test.

sIL-2R, soluble interleukin-2 receptor.

period are needed. Our results suggest that IgG4-ROD relapse rates may be lower when patients are treated with surgical therapy alone, but further prospective studies that directly compare resection alone and resection plus steroid therapy are needed to confirm our findings.

In conclusion, patients with resectable IgG4-ROD lesions should consider treatment with debulking surgery because relapse rates may be lower than when treated with oral steroids. Further studies are needed to confirm that surgical treatment is superior to steroid therapy for treating patients with IgG4-ROD.

Contributors JO and TO designed the study. JO, TO, HC, NS and JT collected clinical data and treated patients. HU made the pathological diagnosis. JT helped with the clinical and pathological diagnosis. JO wrote the first draft of the manuscript. TO, JT and TF reviewed the manuscript. All authors have read and approved the final manuscript. The manuscript was edited for English language by Editage.

Funding The authors have not declared a specific grant for this research from any funding agency in the public, commercial or not-for-profit sectors.

Competing interests None declared.

Patient consent for publication Obtained.

Ethics approval This study was reviewed and approved by the Ethics Committee of Niigata University (Niigata, Japan; approval number: 2018-0049).

Provenance and peer review Not commissioned; externally peer reviewed.

Open access This is an open access article distributed in accordance with the Creative Commons Attribution Non Commercial (CC BY-NC 4.0) license, which permits others to distribute, remix, adapt, build upon this work non-commercially, and license their derivative works on different terms, provided the original work is properly cited, appropriate credit is given, any changes made indicated, and the use is non-commercial. See: <http://creativecommons.org/licenses/by-nc/4.0/>.

REFERENCES

1. Stone JH, Zen Y, Deshpande V. Igg4-Related disease. *N Engl J Med Overseas Ed* 2012;366:539–51.
2. Cheuk W, Chan JK. Igg4-Related sclerosing disease: a critical appraisal of an evolving clinicopathologic entity. *Adv Anat Pathol* 2010;17:303–32.
3. Kamisawa T, Zen Y, Pillai S, et al. Igg4-Related disease. *The Lancet* 2015;385:1460–71.
4. HS S, Lee JH, Woo KI, et al. Igg4-Related disease in idiopathic sclerosing orbital inflammation. *Br J Ophthalmol* 2015;99:1493–7.
5. Andrew NH, Sladden N, Kearney DJ, et al. An analysis of IgG4-related disease (IgG4-RD) among idiopathic orbital inflammations and benign lymphoid hyperplasias using two consensus-based diagnostic criteria for IgG4-RD. *Br J Ophthalmol* 2015;99:376–81.
6. Goto H, Takahira M, Azumi A, et al. Diagnostic criteria for IgG4-related ophthalmic disease. *Jpn J Ophthalmol* 2015;59:1–7.
7. Glass LRD, Freitag SK. Management of orbital IgG4-related disease. *Curr Opin Ophthalmol* 2015;26:491–7.
8. Yamamoto M, Yajima H, Takahashi H, et al. Everyday clinical practice in IgG4-related Dacryoadenitis and/or sialadenitis: results from the smart database. *Mod Rheumatol* 2015;25:199–204.
9. Andrew N, Kearney D, Selva D, et al. Igg4-Related orbital disease: a meta-analysis and review. *Acta Ophthalmol* 2013;91:694–700.
10. Carruthers MN, Topazian MD, Khosroshahi A, et al. Rituximab for IgG4-related disease: a prospective, open-label trial. *Ann Rheum Dis* 2015;74:1171–7.
11. Wu A, Andrew NH, Tsirbas A, et al. Rituximab for the treatment of IgG4-related orbital disease: experience from five cases. *Eye* 2015;29:122–8.
12. Karim AF, Bansie RD, Rombach SM, et al. The treatment outcomes in IgG4-related disease. *Neth J Med* 2018;76:275–85.
13. Park J, Lee MJ, Kim N, et al. Risk factors for extraophthalmic involvement and treatment outcomes in patients with IgG4-related ophthalmic disease. *Br J Ophthalmol* 2018;102:736–41.
14. Kamisawa T, Okazaki K, Kawa S, et al. Amendment of the Japanese consensus guidelines for autoimmune pancreatitis, 2013 III. treatment and prognosis of autoimmune pancreatitis. *J Gastroenterol* 2014;49:961–70.
15. Masaki Y, Kurose N, Umehara H. IgG4-Related Disease : A Novel Lymphoproliferative Disorder Discovered and Established in Japan in the 21st Century. *J Clin Exp Hematop* 2011;51:13–20.
16. Ebbo M, Patient M, Grados A, et al. Ophthalmic manifestations in IgG4-related disease: clinical presentation and response to treatment in a French case-series. *Medicine* 2017;96:e6205.
17. Suimon Y, Kase S, Ishijima K, et al. A clinicopathological study on IgG4-related ophthalmic disease. *Int J Ophthalmol* 2018;11:1539–44.
18. Sogabe Y, Ohshima K-ichi, Azumi A, et al. Location and frequency of lesions in patients with IgG4-related ophthalmic diseases. *Graefes Arch Clin Exp Ophthalmol* 2014;52:531–8.
19. Kubota T, Katayama M, Moritani S, et al. Serologic factors in early relapse of IgG4-related orbital inflammation after steroid treatment. *Am J Ophthalmol* 2013;155:373–9.