

Surgical Intervention for Behcet's Disease with Aorta Aneurysm and Pseudoaneurysm: Opposite Outcomes in Two Cases

Yong Chen¹, Jia-Shen Cui², Jian-Fei Cai¹, Jun Zou¹, Jian-Long Guan¹

¹Department of Rheumatology and Immunology, Huadong Hospital Affiliated with Fudan University, Shanghai 200040, China

²Department of Vascular Surgery, Huadong Hospital Affiliated with Fudan University, Shanghai 200040, China

Key words: Aorta Aneurysm; Behcet's Disease; Pseudoaneurysm; Surgery

Behcet's disease (BD) is a chronic, relapsing autoimmune disorder characterized by oral and genital ulcerations with uveitis, and additional clinical manifestations in multiple organ systems. The occurrence of vascular involvement in BD is reported to be in the range of 5–30%.^[1] Vascular BD (VBD) is divided into three subtypes, characterized by venous occlusions, arterial occlusions, or arterial aneurysms. Optimal treatments for VBD, especially for aneurysms or pseudoaneurysms, remain controversial. Lack of experience with VBD due to its rarity often makes treatment decisions difficult, despite the life-threatening potential of arterial aneurysms and pseudoaneurysms.^[2] In this manuscript, we reported opposite outcomes for two BD cases with aorta aneurysm and pseudoaneurysm to cast light on difficulties related to therapeutic decision-making and symptom management in this condition.

A 74-year-old man was diagnosed with BD 9 years ago at age of 65 years. Five years ago, the patient complained of abdominal pain, and computed tomography indicated the presence of an abdominal aortic aneurysm. Based on these observations, the patient underwent successful stent implantation for the repair of the abdominal aorta [Figure 1a and 1b] at Qilu Hospital, Shandong province. Glucocorticoid and disease-modifying antirheumatic drugs (DMARDs) were prescribed to control BD symptoms, and warfarin was prescribed to prevent postsurgery thrombosis. Symptoms of the disease were satisfactorily controlled during the following 5 years. Recently, the patient was admitted to our department due to the complaints of blurred vision, thought to be related

to BD. Ophthalmology consultation revealed the presence of cataracts. Moderate changes in liver, kidney, and lipid serum levels were not clinically significant; however, the patient's D-dimer level was 10.50 mg/L (normal range of 0–0.55 mg/L) and his platelet aggregation rate was 88.8% (normal range of 36–75%). In response, the warfarin dosage was increased and plavix (an antithrombotic) and atorvastatin (a statin) were added to the treatments. Through regular clinical checkups and improved drug therapy, the patient survived and is in a stable condition.

A second case was a 44-year-old patient with a 12-year history of BD, who was discovered to have an aortic arch pseudoaneurysm 8 months before admission to our hospital. The patient had experienced occasional chest pain and manifested a hoarse voice for about 2 weeks before diagnosis. The patient had not been receiving regular treatments, and the onset of erythema nodosum was accompanied by a C-reactive protein level of 16 mg/L, suggesting an active state of the disease. His D-dimer level was 2.15 mg/L and platelet aggregation rate was 91.3%. Computed tomography imaging coupled with aortography revealed a partial rupture on the right posterolateral wall of aortic arch and formation of a pseudoaneurysm [Figure 1c-1f]. A consulted vascular

Address for correspondence: Prof. Jian-Long Guan,
Department of Rheumatology and Immunology, Huadong
Hospital Affiliated to Fudan University, Shanghai 200040, China
E-Mail: guanjianlong@medmail.com.cn

This is an open access article distributed under the terms of the Creative Commons Attribution-NonCommercial-ShareAlike 3.0 License, which allows others to remix, tweak, and build upon the work non-commercially, as long as the author is credited and the new creations are licensed under the identical terms.

For reprints contact: reprints@medknow.com

© 2017 Chinese Medical Journal | Produced by Wolters Kluwer - Medknow

Received: 06-07-2017 **Edited by:** Yuan-Yuan Ji

How to cite this article: Chen Y, Cui JS, Cai JF, Zou J, Guan JL. Surgical Intervention for Behcet's Disease with Aorta Aneurysm and Pseudoaneurysm: Opposite Outcomes in Two Cases. *Chin Med J* 2017;130:2503-5.

Access this article online

Quick Response Code:



Website:
www.cmj.org

DOI:
10.4103/0366-6999.216414

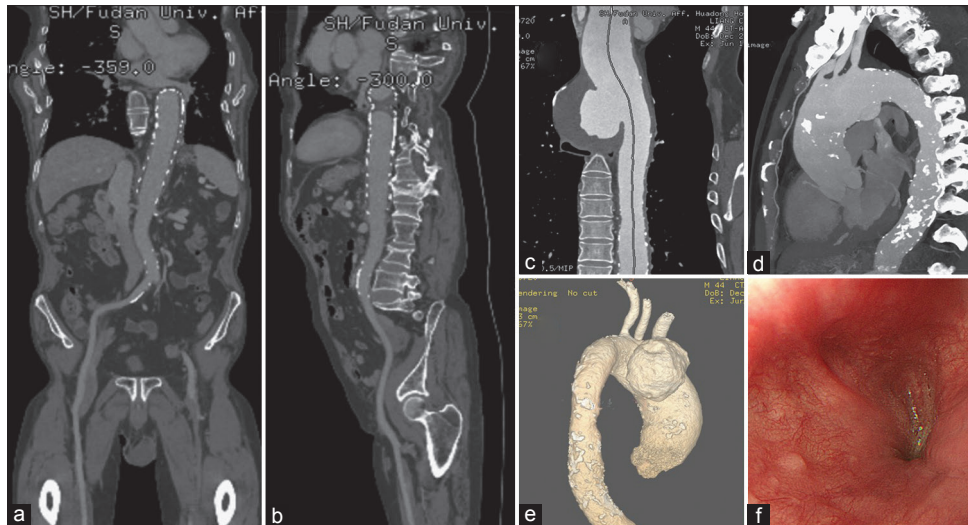


Figure 1: Representative images of the two patients. (a) Coronal section and (b) vertical plane images of the abdominal aortic aneurysm in the 74-year-old patient with Behcet's disease after stent implantation. (c-e) Computed tomography image coupled to aortography showing partial rupture on the right posterolateral wall of the aortic arch accompanied by formation of a pseudoaneurysm in the 44-year-old patient. (f) Endoscope image revealing an esophageal submucosal protuberance, impression caused by the aortic arch aneurysm.

surgery specialist recommended endovascular aneurysm repair, but the patient was reluctant to undergo this procedure based on economic concerns. For this reason, enhanced drug therapy, including glucocorticoid, thalidomide, and DEMARDs combined with infliximab, and additional symptomatic and supportive treatments, was provided. The patient reported feeling no chest pain and blood test results gradually improved. Based on these improvements, the attending physicians did not actively attempt to persuade the patient to undergo corrective surgery. Tragically, however, a family member recently informed us of the sudden death of the patient due to the rupture of the pseudoaneurysm 1 month after discharge from the hospital.

Currently, there is little firm evidence to guide the management of VBD. With the exceptions of clinical studies describing a small number of cases and a few individual case reports, there is no strong statistical evidence supporting surgical intervention for BD patients with aorta aneurysm or pseudoaneurysm. For patients diagnosed with aorta aneurysm or pseudoaneurysm alone, both open surgical repair (practiced since 1951) and minimally invasive endovascular aneurysm repair (first reported in 1986) have clearly showed benefits to patients. In 2005, the American College of Cardiology and the American Heart Association established guidelines for management of peripheral arterial disease that included recommendations for management of abdominal aortic aneurysm. The guidelines gave a Class IIa recommendation for endovascular repair for patients at a high surgical risk and a Class IIb recommendation for endovascular repair (for which usefulness or efficacy is less well established by evidence or opinion) for patients at a low or average surgical risk.^[3] For cases of aorta aneurysm or pseudoaneurysm occurring in patients with rheumatological diseases such as BD, there is agreement that it is important to control baseline inflammation before surgery.^[4]

Kwon *et al.*^[3] reported surgical treatment results for abdominal aortic aneurysms in 12 BD patients for 21 procedures. Six patients received graft interpositions, six patients received patch closures, and one patient received a stent-graft insertion (one patient received a graft interposition and a patch closure for treatment of a double abdominal aortic aneurysms). Eight recurrent aneurysms were observed among six (50%) patients. Four stent-graft insertions, two patch closures, one graft interposition, and one exploratory thoracotomy were performed for these recurrent aneurysms. The overall recurrence rate for the 21 procedures was 38.1%: 14.3% for graft interpositions, 62.5% for patch closures, and 40% for stent-graft insertions. The authors noted that although resection and graft interposition are technically difficult in many cases, they should currently be considered as the procedures of choice for abdominal aortic aneurysms in BD. In the future, endovascular interventions might be considered first-line for treatment modality, but further long-term follow-up studies are still needed.^[3]

In conclusion, aorta aneurysms and pseudoaneurysms are life-threatening conditions for some BD patients. Based on the opposite outcomes for the two cases described in this report, we consider it prudent to recommend surgical intervention for aorta aneurysms or pseudoaneurysms for BD patients with controlled base-line inflammation. Failure to do so may lead to unacceptably high levels of morbidity and mortality.^[3] Consultation with multiple medical disciplines is also highly recommended to assist in choosing the best therapeutic options for VBD patients.

Declaration of patient consent

The authors certify that they have obtained all appropriate patient consent forms. In the form, the patient(s) has/have given his/her/their consent for his/her/their images and other clinical information to be reported in the journal. The patients

understand that their names and initials will not be published and due efforts will be made to conceal their identity, but anonymity cannot be guaranteed.

Financial support and sponsorship

This work was supported by grants from Shanghai Health System Key Joint Research Project on Important Diseases of the Second Allocation (No. 2014ZYJB0010), Shanghai Municipal Commission of Health and Family Planning, key developing disciplines (No. 2015ZB0501), and Shanghai Key Laboratory of Clinical Geriatric Medicine (No. 13dz2260700).

Conflicts of interest

There are no conflicts of interest.

REFERENCES

1. Ambrose NL, Haskard DO. Differential diagnosis and management of Behçet syndrome. *Nat Rev Rheumatol* 2013;9:79-89. doi: 10.1038/nrrheum.2012.156.
2. Tsuda K, Ohkura K, Shintani T, Saito T, Shiiya N. Endovascular treatment of a ruptured innominate artery aneurysm in Behçet disease. *Ann Vasc Surg* 2016;33:230.e1-4. doi: 10.1016/j.avsg.2015.11.024.
3. Kwon TW, Park SJ, Kim HK, Yoon HK, Kim GE, Yu B. Surgical treatment result of abdominal aortic aneurysm in Behçet's disease. *Eur J Vasc Endovasc Surg* 2008;35:173-80. doi: 10.1016/j.ejvs.2007.08.013.
4. Hatemi G, Silman A, Bang D, Bodaghi B, Chamberlain AM, Gul A, *et al.* Management of Behçet disease: A systematic literature review for the European League against Rheumatism evidence-based recommendations for the management of Behçet disease. *Ann Rheum Dis* 2009;68:1528-34. doi: 10.1136/ard.2008.087957.