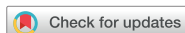

Case Report



Pyoderma Gangrenosum Mimicking Wound Infection after Breast Cancer Surgery

Dabin Kim ¹, Sung-Mo Hur ¹, Jae Seok Lee ¹, Susie Chin ², Cheol Wan Lim ¹, Zisun Kim ¹

¹Department of Surgery, Soonchunhyang University Bucheon Hospital, Soonchunhyang University College of Medicine, Bucheon, Korea

²Department of Pathology, Soonchunhyang University Bucheon Hospital, Soonchunhyang University College of Medicine, Bucheon, Korea

OPEN ACCESS

Received: Jan 22, 2021

Revised: Mar 6, 2021

Accepted: Apr 3, 2021

Correspondence to

Zisun Kim

Department of Surgery, Soonchunhyang University Bucheon Hospital, 170 Jomaru-ro, Bucheon 14584, Korea.

E-mail: sk4091@hanmail.net

© 2021 Korean Breast Cancer Society

This is an Open Access article distributed under the terms of the Creative Commons Attribution Non-Commercial License (<https://creativecommons.org/licenses/by-nc/4.0/>) which permits unrestricted non-commercial use, distribution, and reproduction in any medium, provided the original work is properly cited.

ORCID iDs

Dabin Kim

<https://orcid.org/0000-0002-8091-6398>

Sung-Mo Hur

<https://orcid.org/0000-0001-8547-5635>

Jae Seok Lee

<https://orcid.org/0000-0001-6596-8010>

Susie Chin

<https://orcid.org/0000-0003-2754-1483>

Cheol Wan Lim

<https://orcid.org/0000-0001-9490-4964>

Zisun Kim

<https://orcid.org/0000-0002-1413-2800>

Funding

This work was supported by the Soonchunhyang University Research Fund.

Conflict of Interest

The authors declare that they have no competing interests.

ABSTRACT

Postoperative pyoderma gangrenosum (PPG) is rare, and its diagnosis is often delayed because of its wound infection-mimicking course. A 53-year-old breast cancer patient who underwent breast-conserving surgery of the right breast presented with fever, leukocytosis, C-reactive protein elevation, and redness of the right breast on postoperative day (POD) 3. The breast wound showed desquamation with painful ulcerative changes from POD 6, and fever was sustained under antibiotic administration. Wound irrigation was attempted; however, inflammatory skin damage progressed to involvement of the entire skin overlying the breast. With clinical suspicion of PPG, skin biopsy and systemic corticosteroid initiation were performed on POD 12. Wound damage progression ceased, and the systemic inflammation subsided. The patient underwent split-thickness skin grafting under intravenous corticosteroid administration, and the wound healed after 30 days. PPG is a rare clinical scenario. Early diagnosis is critical to avoid unnecessary treatment and aggravation of the surgical wound.

Keywords: Breast; Breast neoplasms; Pyoderma gangrenosum

INTRODUCTION

Pyoderma gangrenosum is a rare neutrophilic dermatosis that manifests as skin inflammation and ulceration with signs of systemic inflammation. The estimated incidence is 3–10 cases per million people per year [1], and more than half of the cases are thought to be associated with underlying systemic diseases such as inflammatory bowel disease, hematologic disorders, and arthritis [2]. The precise pathogenesis is unclear, but neutrophil dysfunction, genetic variations, and systemic autoinflammatory disorder have been considered [3]. Postoperative pyoderma gangrenosum (PPG) involves pyoderma gangrenosum at the surgical incision site with clinical manifestations such as wound dehiscence, skin ulceration, fever, and postoperative wound infection. Misdiagnosis leads to mistreatment using antibiotics and surgical debridement, which results in unnecessary treatment and aggravation of the clinical course due to pathergy. However, accurate and early diagnosis of PPG is usually difficult because the clinical course, laboratory test results, and histopathologic findings are not pathognomonic, and the exclusion of other possible diseases

Author Contributions

Conceptualization: Hur SM, Lim CW, Kim Z; Data curation: Hur SM, Kim Z; Formal analysis: Kim Z; Investigation: Kim D, Lee JS; Methodology: Kim D, Lee JS, Chin S, Lim CW; Project administration: Lee JS, Kim Z; Resources: Hur SM, Chin S, Lim CW; Supervision: Chin S, Lim CW, Kim Z; Writing - original draft: Kim D; Writing - review & editing: Kim Z.

is critical. Herein, we reported a case of PPG after breast cancer surgery. Informed consent was obtained from the patient. This study was approved by the Institutional Review Board of Soonchunhyang University Bucheon Hospital (No. 2021-01-004).

CASE REPORT

A 53-year-old woman was diagnosed with right breast cancer with axillary lymph node metastasis. The patient had a history of hypertension and daily use of amlodipine 5 mg. She underwent breast-conserving surgery with a circumareolar skin incision (round block technique) and axillary lymph node dissection (**Figure 1**). Preoperative antibiotics (first-generation cephalosporin) were administered 30 min before skin incision. At the time of surgery, parenchymal remodeling was performed using Polysorb 3-0 (glycolide/lactide copolymer; Covidien, Minneapolis, USA) sutures. The surgical wound was closed using PDS 4-0 (polydioxanone; Ethicon, Cincinnati, USA) for subcutaneous sutures and Ethilon 6-0 (nylon; Ethicon) for skin sutures. Hemostatic agents were not administered. Postoperatively, the patient received 1,000 mL of normal saline and intravenous (IV) painkillers (ketorolac, a non-steroidal anti-inflammatory drug). The pathologic results were as follows: infiltrating ductal carcinoma, pT1c (17 mm) N1a (1/10) M0, and estrogen receptor/progesterone receptor/human epidermal growth factor receptor 2 8/8/1+. On postoperative day (POD) 3, fever (peaked at 38.7°C), leukocytosis (12,960/ μ L), and C-reactive protein (CRP) elevation (9.39 mg/dL) were noted. The breast wound showed mild redness with clear drainage fluid. After chest radiography and blood, urine, and drainage fluid cultures, empirical antimicrobial agents were started. All culture results were negative; however, the fever remained. The fever (peak, 39.7°C) persisted until POD 6, and the patient started experiencing severe wound pain with bullae and bruise formation at the right lower breast (**Figure 2**). Breast ultrasound-guided seroma aspiration was attempted; the aspirate showed negative culture results. Under suspicion of wound infection caused by *Streptococcus pyogenes*, methicillin-resistant *Staphylococcus aureus*, or *Pseudomonas spp.*, the antibiotic agents were changed to meropenem and vancomycin; however, skin ulceration and desquamation progressed rapidly (POD 8, **Figure 3**). Chest computed tomography suggested no evidence of other sources of infection, and she underwent surgical exploration (POD 9) to identify and treat the infective focus of the breast that was irresponsive to conventional clinical supportive management. In the operation field, a broad range of epithelial ulcerations and skin inflammation were identified,

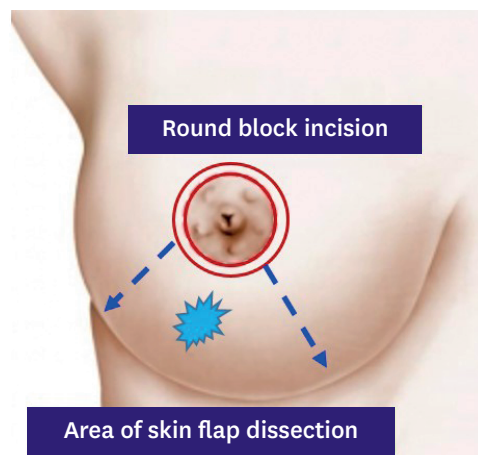


Figure 1. A circumareolar skin incision (round block technique) and creation of a skin flap around the tumor.

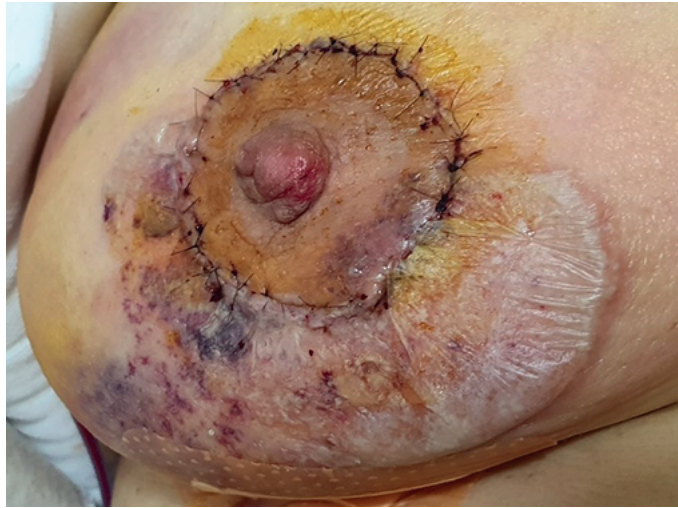

Figure 2. Development of skin bullae with pain on postoperative day 6.

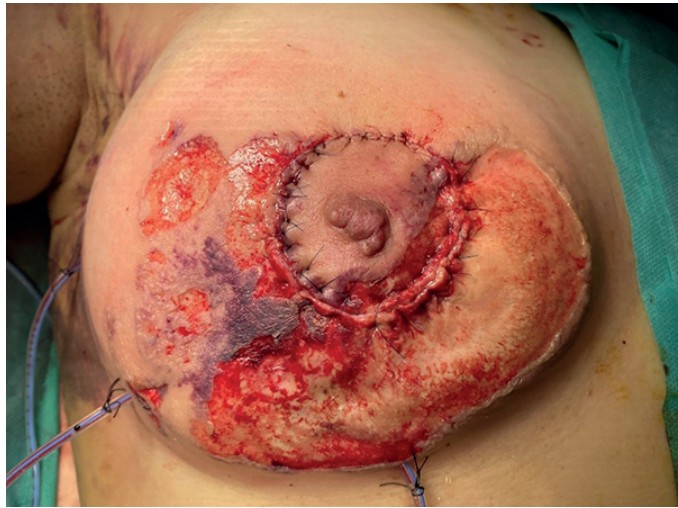


Figure 3. Progression of skin desquamation with ulceration on postoperative day 8.

and the breast parenchyma and subcutaneous fat were relatively spared. Irrigation and tissue culture were performed, and the tissue culture did not demonstrate microorganisms. Fever, leukocytosis (peak, 28.810/ μ L), and CRP elevation (peak, 19.84 mg/dL) persisted even after wound irrigation, and breast skin ulceration spread through the entire unilateral breast. The nipple remained intact, and the breast skin necrosis progressed (**Figure 4**). Additional physical examinations and laboratory studies, including those for anti-nuclear antibodies, antineutrophil cytoplasmic autoantibodies, and anti-double-stranded DNA antibodies, were performed to identify underlying autoimmune diseases, revealing non-specific findings.

Because of the unusual progression of the clinical course, a skin biopsy was performed, which revealed an ulcer and abscess involving the deep dermis and subcutis with leukocytoclastic vasculitis, suggestive of pyoderma gangrenosum (**Figure 5**). We initiated IV methylprednisolone (40 mg/day) and topical corticosteroids, and systemic inflammation, fever, leukocytosis, and CRP elevation dramatically subsided; the progression of breast wound dehiscence also ceased.

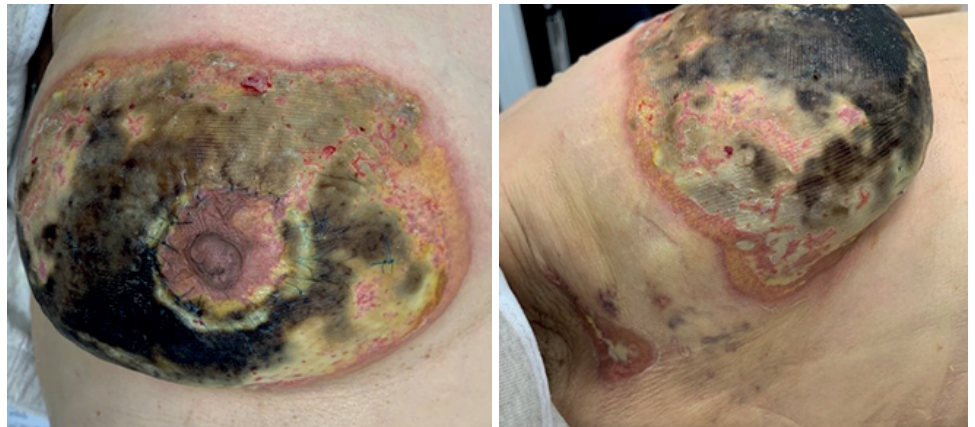

Figure 4. Necrotic changes in the entire breast skin and axillary wound disruption with an intact nipple-areolar complex (postoperative day 14).

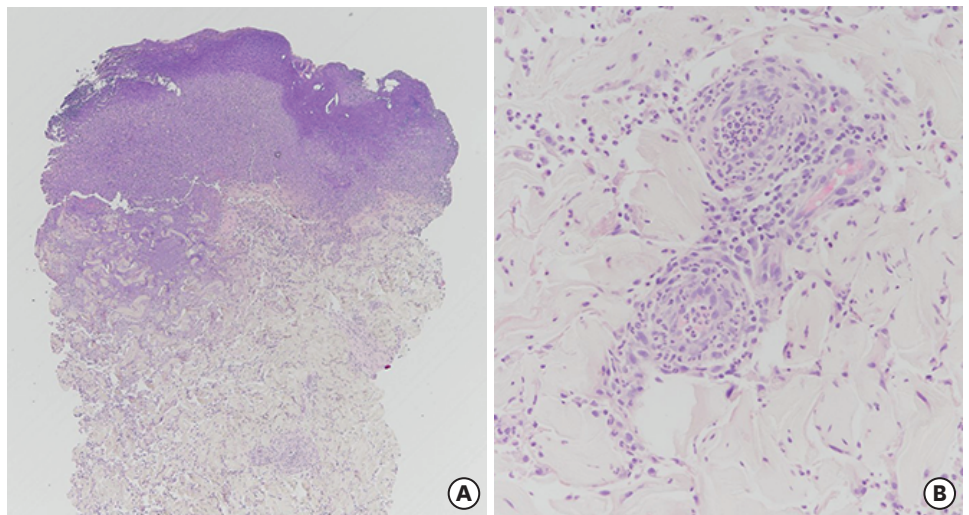


Figure 5. Microscopic findings. Skin biopsy specimen revealing epidermal ulceration with abscess formation (A, H&E stain, $\times 40$). Leukocytoclastic vasculitis is identified in the dermis (B, H&E stain, $\times 200$). H&E = hematoxylin and eosin.

The patient was transferred to the plastic surgery department and underwent debridement and vacuum-assisted closure. Ten days after vacuum-assisted closure, the wound began to heal. Several additional laboratory studies and physical examinations were performed to identify other underlying autoimmune diseases, which showed non-specific findings. Under systemic steroid administration, she underwent the application of a split-thickness skin graft (STSG) at the right breast (**Figure 6**). IV methylprednisolone was tapered off for the 10 days after wound healing, and the duration of corticosteroid therapy was 6 weeks. The patient was discharged 18 days after STSG application (**Figure 7**).

DISCUSSION

Since it was first described by Cullen in 1924, several case reports and reviews have described PPG. Nevertheless, many clinicians are not aware of PPG, and delayed diagnosis results in treatment delay, unnecessary prolongation of treatment, and distrust of physicians.

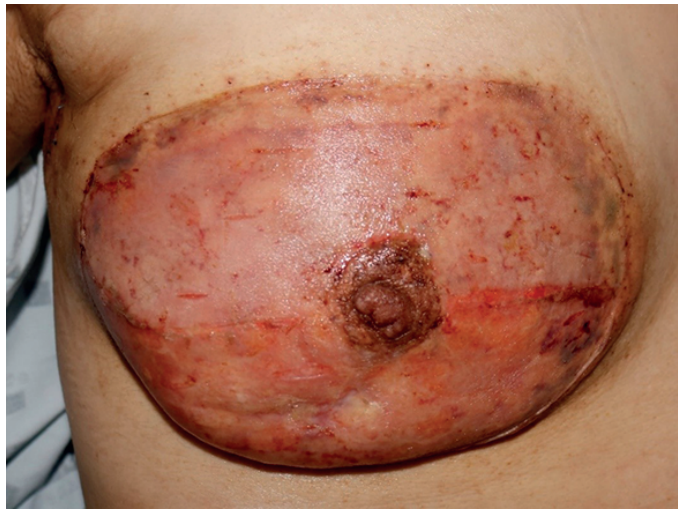

Figure 6. Eleven days after split-thickness skin graft.

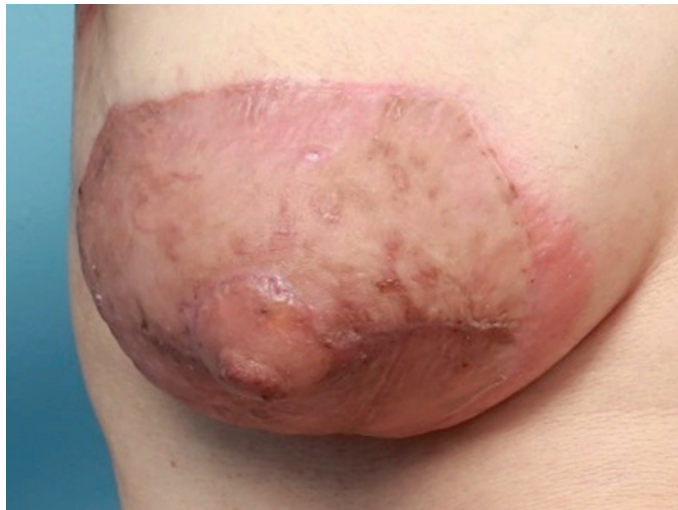

Figure 7. Completion of breast wound healing after the application of a split-thickness skin graft.

The clinical course of PPG started with painful skin ulceration and systemic signs of inflammation on POD 7 in our case. Usually, patients experience extreme pain that overshadows other symptoms [4]. Fever and leukocytosis are seen in half of the patients, and most patients show negative results on microbiological studies. According to a recent systematic review [5], 77% of breast PPGs are nipple-sparing, which could be a specific sign of PPG at the breast wound.

The diagnosis and treatment of PPG are challenging because other diseases with similar clinical manifestations, such as wound infection, are much more frequent than PPG. Clinicians mistake PPG for wound infection, which might lead to prolonged use of unnecessary and ineffective antibiotic therapy or surgical debridement. Skin biopsy, which demonstrates an ulcer edge with neutrophilic infiltrates, is necessary; however, this finding is non-specific. Therefore, clinical presentation, response to immunosuppressive therapy, and exclusion of other possible diseases are decisive in the diagnosis of PPG. Wound infection (necrotizing fasciitis) was the first disease to be excluded in our case. Necrotizing

fasciitis tends to affect the deeper fascia and subcutaneous layer, but PPG is centered in the cutaneous layer. Additionally, a superior response to broad-spectrum antibiotics and extreme pain with rapid wound breakdown could be essential for diagnosing necrotizing fasciitis [4]. Sweet syndrome should also be excluded to diagnose PPG. Sweet syndrome is an acute febrile neutrophilic dermatosis that is similar to PPG, but Sweet syndrome is generally not associated with ulceration and shows more prominent karyorrhexis relative to neutrophil counts [6].

To clarify the diagnosis of pyoderma gangrenosum, diagnostic criteria were suggested in the Delphi consensus, including one major criterion (biopsy of the ulcer edge demonstrating a neutrophilic infiltrate) and eight other minor criteria (exclusion of infection, pathergy, underlying systemic diseases, and cribriform scars at healed ulcer sites) [7]. However, it takes approximately 1 week to confirm the pathological and microbiological results, and the fulfillment of other criteria could be confirmed retrospectively. For this reason, initiating treatment for PPG should not be delayed until pathological and microbiological confirmation because timely initiation of therapy is critical.

The patient in the present case did not have a family history of PPG or underlying systemic disorders. More than half of the patients with pyoderma gangrenosum are known to have underlying systemic disorders such as inflammatory bowel disease and rheumatoid arthritis [8], but a clinical review of published cases of PPG of the breast showed less association with systemic diseases compared to those of other types of pyoderma gangrenosum [4]. Moreover, a systematic review of breast PPG reported that the major underlying disorder was breast cancer. Other underlying systemic diseases accounted for only 22% of cases, and none of the patients had a familial history of PPG [5]. Therefore, PPG should not be excluded in patients without underlying systemic inflammatory disorders or a familial history.

Previous studies have mostly reported cases of PPG [9] after breast surgery with a wide range of breast skin flap development and donor site flap dissection followed by reconstruction. The present case is different from other reported cases in that the area of skin flap development was relatively small (approximately 1/4 of the breast); however, the PPG invaded the whole breast, although the nipple-areolar complex was preserved.

The mainstream medical treatment for PPG is immunosuppressive therapy. Local, topical corticosteroid treatment with calcineurin inhibitors at the ulcer's inflamed periphery is effective in cases of mild, localized PPG. Systemic immunosuppressive therapy is required for extensive disease. The typical initial treatment involves systemic glucocorticoids, oral prednisone (1 mg/kg/day), or IV methylprednisolone (0.5–1 mg/kg/day). The response to systemic glucocorticoids is usually rapid, and systemic signs, including pain, evidently resolve within 1 week [10]. However, since complete ulcer healing takes months, glucocorticoid tapering is needed when disease progression stops and improvement in pain or inflammation is noted to avoid the systemic adverse effects of steroid therapy. For those who cannot tolerate glucocorticoids due to uncontrolled hyperglycemia or due to the presence of refractory disease, cyclosporine (5 mg/kg/day) [11], infliximab, tacrolimus, or other immunosuppressive agents could be considered as treatment options.

In addition to medical treatment, dressing and surgical treatment can be considered for wound management. Because pathergy is considered a major pathogenesis of PPG, unnecessary trauma to the PPG wound could lead to painful aggravation. Therefore, exposure to deleterious agents or dressing materials that adhere to the wound should be

avoided. Surgical debridement of PPG wounds should also be kept to a minimum because debridement could also lead to pathergy. After the stabilization of PPG with medical treatment, surgical procedures such as skin grafting and flap coverage can be performed in selected cases. To minimize pathergy, these surgical procedures should be performed under the maintenance of immunosuppressive therapy [12].

Studies on the long-term prognosis of patients with PPG are scarce. The patient described in the present report needed adjuvant chemotherapy followed by radiation therapy; however, this was impossible because of the wound issue. She is currently taking letrozole (an aromatase inhibitor), and adjuvant radiation therapy has been scheduled after the completion of wound healing. Proper cancer surveillance and long-term follow-up after radiation therapy are required for patients with PPG of the breast, because there are published reports of recurrent pyoderma gangrenosum 17 years after surgery and radiation therapy [13].

In conclusion, in cases of unusual inflammatory clinical scenarios after breast surgery, early diagnosis and initiation of proper immunosuppressive therapy are critical for the treatment of PPG. It is important to suspect PPG in patients with wound dehiscence with systemic inflammation because effective diagnostic tools are lacking. Further studies are needed to determine the long-term prognosis of PPG and the optimal adjuvant therapies in patients with cancer.

REFERENCES

1. Ruocco E, Sangiuliano S, Gravina AG, Miranda A, Nicoletti G. Pyoderma gangrenosum: an updated review. *J Eur Acad Dermatol Venereol* 2009;23:1008-17.
[PUBMED](#) | [CROSSREF](#)
2. von den Driesch P. Pyoderma gangrenosum: a report of 44 cases with follow-up. *Br J Dermatol* 1997;137:1000-5.
[PUBMED](#) | [CROSSREF](#)
3. Ahronowitz I, Harp J, Shinkai K. Etiology and management of pyoderma gangrenosum: a comprehensive review. *Am J Clin Dermatol* 2012;13:191-211.
[PUBMED](#) | [CROSSREF](#)
4. Tolkachjov SN, Fahy AS, Cerci FB, Wetter DA, Cha SS, Camilleri MJ. Postoperative pyoderma gangrenosum: a clinical review of published cases. *Mayo Clin Proc* 2016;91:1267-79.
[PUBMED](#) | [CROSSREF](#)
5. Ehrl DC, Heidekrueger PI, Broer PN. Pyoderma gangrenosum after breast surgery: a systematic review. *J Plast Reconstr Aesthet Surg* 2018;71:1023-32.
[PUBMED](#) | [CROSSREF](#)
6. Wallach D, Vignon-Pennamen MD. Pyoderma gangrenosum and Sweet syndrome: the prototypic neutrophilic dermatoses. *Br J Dermatol* 2018;178:595-602.
[PUBMED](#) | [CROSSREF](#)
7. Maverakis E, Ma C, Shinkai K, Fiorentino D, Callen JP, Wollina U, et al. Diagnostic criteria of ulcerative pyoderma gangrenosum: a Delphi consensus of international experts. *JAMA Dermatol* 2018;154:461-6.
[PUBMED](#) | [CROSSREF](#)
8. Binus AM, Qureshi AA, Li VW, Winterfield LS. Pyoderma gangrenosum: a retrospective review of patient characteristics, comorbidities and therapy in 103 patients. *Br J Dermatol* 2011;165:1244-50.
[PUBMED](#) | [CROSSREF](#)
9. Li WY, Andersen JC, Jung J, Andersen JS. Pyoderma gangrenosum after abdominal free tissue transfer for breast reconstruction: case series and management guidelines. *Ann Plast Surg* 2019;83:63-8.
[PUBMED](#) | [CROSSREF](#)
10. Chow RK, Ho VC. Treatment of pyoderma gangrenosum. *J Am Acad Dermatol* 1996;34:1047-60.
[PUBMED](#) | [CROSSREF](#)
11. Schöfer H, Baur S. Successful treatment of postoperative pyoderma gangrenosum with cyclosporin. *J Eur Acad Dermatol Venereol* 2002;16:148-51.
[PUBMED](#) | [CROSSREF](#)

12. Grillo MA, Cavalheiro TT, da Silva Mulazani M, Rocha JL, Semchechen D, da Cunha CA. Postsurgical pyoderma gangrenosum complicating reduction mammoplasty. *Aesthetic Plast Surg* 2012;36:1347-52.
[PUBMED](#) | [CROSSREF](#)
13. Pellegrino SA, Cham A, Pitcher M. Pyoderma gangrenosum of the breast 17 years after breast cancer treatment. *BMJ Case Rep* 2020;13:e232983.
[PUBMED](#) | [CROSSREF](#)