

Recurrent Metastatic Penile Cancer Patient with Positive PD-L1 Expression Obtained Significant Benefit from Immunotherapy: A Case Report and Literature Review

This article was published in the following Dove Press journal:
OncoTargets and Therapy

Xiangyu Su¹
Jing Zhang²
Chenchun Fu¹ 
Mingzhe Xiao³
Cailian Wang¹

¹Department of Oncology, Zhongda Hospital, School of Medicine, Southeast University, Nanjing, Jiangsu, People's Republic of China; ²Department of Oncology, The Second People's Hospital of Taizhou City, Taizhou, Zhejiang, People's Republic of China; ³The Medical Department, 3D Medicines Inc., Shanghai, People's Republic of China

Background: Penile squamous cell carcinoma (PSCC) bears poor prognosis due to its rarity and limited treatment options, especially after failure of standard treatments. Effective therapeutic options were desperately needed.

Case Presentation: We report a recurrent metastatic PSCC patient with positive programmed death ligand 1 (PD-L1) expression ($\geq 10\%$) and tumor mutation burden (TMB) of 8.87 (Muts/Mb) who obtained significant response to immunotherapy, with progression-free survival (PFS) exceeding 10 months.

Conclusion: This is the first case presenting remarkable response to immunotherapy in a Chinese PSCC patient. The remarkable response might be associated with PD-L1 expression, indicating that PD-L1 expression could be a promising biomarker for immunotherapy in PSCC. TMB ranking may also contribute to patient selection. However, large clinical trials are needed to validate these notions.

Keywords: immunotherapy, PD-L1, biomarker, Penile squamous cell carcinoma, PSCC

Background

Penile cancer is a rare disease representing 0.4–0.6% of all male malignant cancers, and more than 95% of patients were histologically classified as penile squamous cell carcinoma (PSCC).¹ Due to its rarity, it is difficult to perform clinical trials, and standard therapeutic options are extremely limited, especially for patients with recurrence and metastasis. Progression on standard treatment usually indicates poor prognosis. The median overall survival (OS) was less than 6 months for patients with recurrence,² and the prognosis was even worse for stage IV patients whose 5-year survival rate was only 0%.³ Therefore, new treatment options are desperately needed for recurrent and metastatic PSCC patients with multiline progressions.

Immune checkpoint inhibitors (ICI), a type of immunotherapy, have achieved outstanding progression in various types of cancers. Because the objective response rate (ORR) was less than 20% in unselected patients, several biomarkers such as TMB, PD-L1 expression and microsatellite instability high/mismatch repair deficient (MSI-H/dMMR) have been explored to distinguish the ICI sensitive population.⁴ Patients with positive biomarkers might obtain better responses to ICI treatment compared to

Correspondence: Cailian Wang
Department of Oncology, Zhongda Hospital, School of Medicine, Southeast University, 87 Dingjiaqiao, Nanjing, Jiangsu, People's Republic of China
Email clwang_zhongda@126.com

the biomarker-negative population.⁴ Although pembrolizumab was approved by FDA for treatment of MSI-H/dMMR PSCC, it was rarely used due to the low prevalence of MSI-H/dMMR in PSCC. Currently, data of clinical trials of immunotherapy in PSCC are insufficient, despite the tardily ongoing Phase II trials of avelumab (NCT03391479), pembrolizumab (NCT02837042) and atezolizumab (NCT03686332). There is an urgent need to explore the efficacy and biomarkers of immunotherapy in PSCC.

Here we report a recurrent metastatic PSCC patient who obtained partial response (PR) from immunotherapy after failing multiple lines of treatment, with a PFS exceeding 6 months.

Case Presentation

A 46-year-old man was administrated to the Institute of Dermatology, Chinese Academy of Sciences with complaints of a cauliflower-like neoplasm accompanied with purulent secretion on the glans. Computed tomography (CT) revealed uneven thickening and intensification of penile skin. The patient then received radical resection and lymphadenectomy on November 6, 2017. Postoperative pathological results indicated PSCC (Figure 1). No metastasis was observed in bilateral inguinal lymph nodes and the margin of incision was negative.

In November 2018, bilateral inguinal lymph node enlargement was revealed by CT in Jiangsu Cancer Hospital. Lymph node metastasis was thus considered. The patient then received chemotherapy (liposome paclitaxel 120 mg iv d1/8+ cisplatin 50 mg iv d1/8, 21 d) in Zhongda Hospital. However, the disease was not under control. In December 2018, ulceration was observed in the right inguinal sinus. The patient thus received radiotherapy (60 Gy/3 Gy/

20 F) on the right inguinal lesions. Unfortunately, multiple small pulmonary nodules were observed by enhanced CT in both lungs soon afterwards, indicating metastasis and disease progression (Figure 3).

To seek potential therapeutic options, the patient received next generation sequencing (NGS) and immunohistochemistry (IHC) analysis. The NGS analysis and TMB evaluation were conveyed as previously described.⁵ TMB was defined as the total non-silent somatic mutation counts in coding regions. SNV include both synonymous and non-synonymous mutations, as well as stopgain, stoploss, and splicing variants. Indel variants include both the frameshift or non-frameshift insertions and deletions. Non-coding alterations were not counted. The raw data are available at Sequence Read Archive (SRA) database with SRA accession: PRJNA612189. Results indicated positive PD-L1 expression ($\geq 10\%$) (Figure 1), microsatellite stable (MSS), and a tumor mutation burden (TMB) of 8.87 (Muts/Mb). Several mutations were found: PIK3CA p. G106V, CDKN2A p.R80*, TERT c.-124C>T and HRAS p. G12V. However, no therapies were available for these mutations in PSCC. The patient was then administered with toripalimab (240 mg iv d2, 21 d/cycle), an immune check point inhibitor (ICI), since February 27, 2019 on top of the chemotherapy regimen. Partial response was soon observed on April 15, 2019 and confirmed on June 5, 2019 by CT (Figure 2). The patient then received ICI treatment instead of chemotherapy. During the course of treatment, the patient had grade 2 granulocytopenia and grade 1 liver function damage, which disappeared after symptomatic treatments. To the date of submission, the patient reached a PFS exceeding 6 months since immunotherapy (Figure 2), and lesions were still under control by January 2020 whereas the PFS

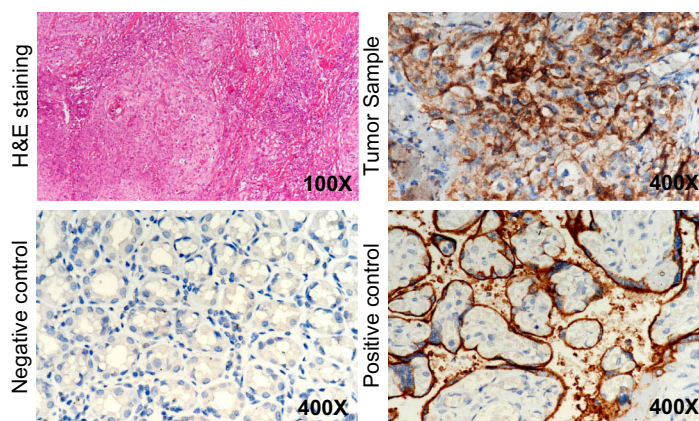


Figure 1 H&E staining of postoperative tumor sample indicating PSCC, PD-L1 staining of tumor sample, negative control and positive control by Ventana SP263 PD-L1 staining kit. Tumor sample was PD-L1 positive ($\geq 10\%$).

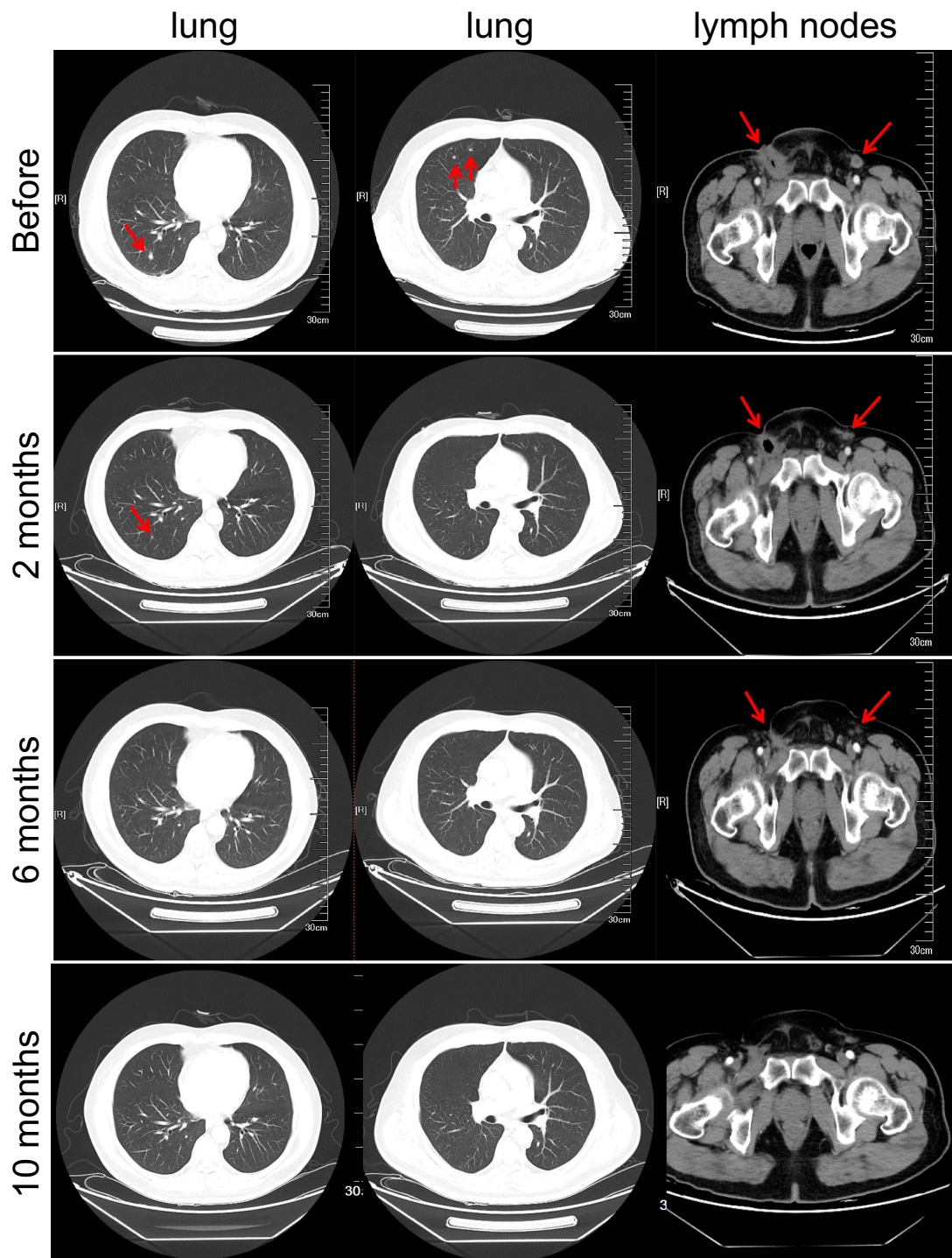


Figure 2 CT. result of tumor lesions in lung and lymph nodes before, or after 2 months, 6 months and 10 months of immunotherapy as indicated by arrows. Lesions continued recessing.

exceeded 10.5 months. The patient was still alive and under treatment (Figure 3).

Discussion and Conclusions

In this case, the PSCC patient responded well to immunotherapy after multiline obtaining a PFS exceeding 10 months, and

we could expect a much longer OS. This benefit was considerable given that progression of PSCC after primary chemotherapy had been noted to have a median OS of less than 6 months.² To our knowledge this was the first case in China.

Prognosis of metastatic penile cancer was poor and the therapeutic options were limited. Therefore, it is necessary

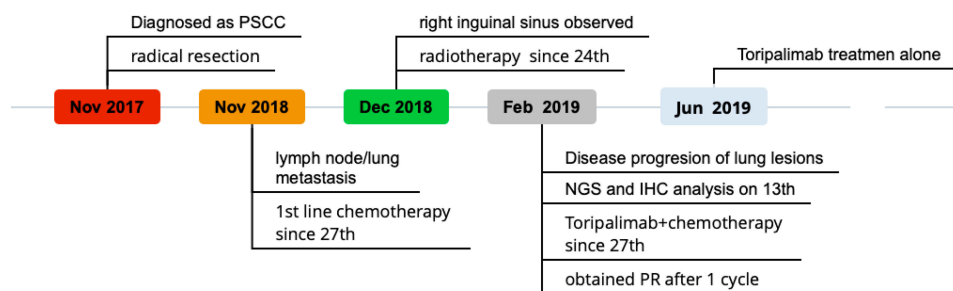


Figure 3 Schematic picture showing the time line of treatment procedure.

to find appropriate treatment for advanced PSCC patients with multiline progression. Immunotherapy is a promising option, given its efficacy in various types of cancers.⁶

PD-L1 is a key target of immune checkpoint inhibitors. It was reported that 62% of penile cancer patients were PD-L1 positive ($\geq 5\%$) and were associated with metastasis and poor clinical outcome, especially worse survival (hazard ratio, HR= 2.58).⁷ In China, it was reported that PD-L1 was positive in 53.4% PSCC patients.⁸ This provided rational support for application of immunotherapy in PSCC. There are several ongoing clinical trials exploring immunotherapy in PSCC, although most of them are basket trials that included multiple solid tumors (for example NCT03333616, NCT02721732 and NCT, 02824013). Two trials exclusively targeting PSCC are NCT02837042 (pembrolizumab) and NCT03391479 (avelumab), both are phase II trials with ORR as primary endpoint. Another trial of atezolizumab (NCT03686332) was also ongoing. However, these trials progressed slowly due to the low incidence of PSCC and their data are as yet unavailable. In our case this PD-L1 positive patient responded well to immunotherapy, suggesting that immunotherapy could be a promising option for recurrent metastatic PSCC treatment, especially after chemotherapy failure.

The ORR of immunotherapy in unselected patients was only around 20%, and biomarkers are vital for distinguishing the ICI sensitive population.⁴ The microenvironment of PSCC was very complicated.⁹ The tumor immune microenvironment (TIME), CD8+ T cell infiltration and several other immune factors, including expression of PD-L1, were considered to harbor great prognostic value.¹⁰ PD-L1 expression was also associated with HPV status; it was expressed in 48% of penile carcinomas and mainly in high risk HPV negative tumors.¹¹ PD-L1 expression was considered as a biomarker for ICI in various solid tumors including lung cancer and melanoma, and was associated with efficacy.^{6,12} For example, in KEYNOTE-010,

KEYNOTE-189 and OAK studies, PD-L1 positive populations all obtained a better response.^{12–14} Due to insufficient data, biomarkers for immunotherapy of PSCC are an unmet need. In this case, the patient was PD-L1 positive and obtained a significant response from immunotherapy. This would provide evidence that PD-L1 could be considered as potential biomarker for ICI treatment in PSCC. We believe future studies would reveal more valuable biomarkers in the PSCC microenvironment.

Another promising biomarker for immunotherapy was TMB. The TMB-high population received better outcomes from ICI treatments in CHECKMATE 026 and CHECKMATE 227 trials in lung cancer.^{15,16} However, the numeric cutoff of TMB in different cancers is not universal¹⁷ due to the wild range of median TMB among cancers (from 0.8 Muts/Mb to 45.2 Muts/Mb).¹⁸ It was also indicated that patients with high TMB ranking (top 20%) in individualized cancer types all obtained improved survival. In our case the patient harbored a TMB of 8.87 Muts/Mb, which was much higher than the median TMB (4.5 Muts/Mb) in PSCC.¹⁸ This would indicate that PSCC patients with high TMB might respond better to immunotherapy; however, conclusions should not be made based on this single case, and large trials are needed.

To our knowledge, this is the first case in China describing an advanced PSCC patient with positive PD-L1 and high TMB who obtained remarkable response to immunotherapy. An earlier publication in the USA described one T2N3M0 patient who obtained stable disease from nivolumab and a T2N2M0 patient who responded to atezolizumab.¹⁹ This may provide clinical insights into immunotherapy as a therapeutic option for advanced patients who failed multiline standard therapies. Also, PD-L1 expression and high TMB may serve as potential biomarkers to select sensitive PSCC patients for ICI treatment. However, evidence for this single case report is limited. More large clinical trials are

needed to explore the application of immunotherapy and their biomarkers in PSCC.

Abbreviations

PSCC, penile squamous cell carcinoma; PD-L1, programmed death ligand 1; TMB, tumor mutation burden; PFS, progression-free survival; OS, overall survival; ICI, immune checkpoint inhibitors; ORR, objective response rate; MSI-H/dMMR, microsatellite instability high/mismatch repair deficient; PR, partial response; CT, computed tomography; NGS, next generation sequencing; IHC, immunohistochemistry; HR, hazard ratio.

Consent for Publication

Written informed consent for publication of the clinical details and images was obtained from the patient.

Ethics and Consent Statement

This research was approved by the research ethics committee of Zhongda Hospital, and written informed consent for participate of the clinical details and images was obtained from the patient.

Data Sharing Statement

All data generated or analyzed during this study are included in this published article.

Author Contributions

All authors made substantial contributions to conception and design, acquisition of data, or analysis and interpretation of data; took part in drafting the article or revising it critically for important intellectual content; gave final approval of the version to be published; and agree to be accountable for all aspects of the work.

Funding

This work was supported by the Postgraduate Research & Practice Innovation Program of Jiangsu Province [grant number KYCX18_0180]. The funding sources had no role in the study design, data collection, data analysis, data interpretation, or writing of the report.

Disclosure

The authors declare that they have no competing interests in this work.

References

- Hakenberg OW, Dräger DL, Erbersdobler A, Naumann CM, Junemann KP, Protzel C. The diagnosis and treatment of penile cancer. *Dtsch Arztebl Int.* 2018;115(39):646–652. doi:10.3238/arztebl.2018.0646
- Wang J, Pettaway CA, Pagliaro LC. Treatment for metastatic penile cancer after first-line chemotherapy failure: analysis of response and survival outcomes. *Urology.* 2015;85(5):1104–1110. doi:10.1016/j.urology.2014.12.049
- Mistretta FA, Palumbo C, Knipper S, et al. Conditional survival of patients with stage I-III squamous cell carcinoma of the penis: temporal changes in cancer-specific mortality. *World J Urol.* 2019; 1–8.
- Yarchoan M, Hopkins A, Jaffee EM. Tumor mutational burden and response rate to PD-1 inhibition. *N Engl J Med.* 2017;377(25):2500–2501. doi:10.1056/NEJM1713444
- Zhuang W, Ma J, Chen X, et al. The tumor mutational burden of chinese advanced cancer patients estimated by a 381-cancer-gene panel. *J Cancer.* 2018;9(13):2302–2307. doi:10.7150/jca.24932
- Teng F, Meng X, Kong L, Yu J. Progress and challenges of predictive biomarkers of anti PD-1/PD-L1 immunotherapy: a systematic review. *Cancer Lett.* 2018;414:166–173. doi:10.1016/j.canlet.2017.11.014
- Udager AM, Liu TY, Skala SL, et al. Frequent PD-L1 expression in primary and metastatic penile squamous cell carcinoma: potential opportunities for immunotherapeutic approaches. *Ann Oncol.* 2016;27(9):1706–1712. doi:10.1093/annonc/mdw216
- Deng C, Li Z, Guo S, et al. Tumor PD-L1 expression is correlated with increased TILs and poor prognosis in penile squamous cell carcinoma. *Oncoimmunology.* 2017;6(2):e1269047. doi:10.1080/2162402X.2016.1269047
- de Vries HM, Ottenhof SR, Horenblas S, van der Heijden MS, Jordanova ES. Defining the tumor microenvironment of penile cancer by means of the cancer immunogram. *Eur Urol Focus.* 2019;5(5):718–721. doi:10.1016/j.euf.2019.02.019
- Ottenhof SR, Djajadiningrat RS, Thygesen HH, et al. The prognostic value of immune factors in the tumor microenvironment of penile squamous cell carcinoma. *Front Immunol.* 2018;9:1253. doi:10.3389/fimmu.2018.01253
- Ottenhof SR, Djajadiningrat RS, de Jong J, Thygesen HH, Horenblas S, Jordanova ES. Expression of programmed death ligand 1 in penile cancer is of prognostic value and associated with HPV status. *J Urol.* 2017;197(3 Pt 1):690–697. doi:10.1016/j.juro.2016.09.088
- Herbst RS, Baas P, Kim D-W, et al. Pembrolizumab versus docetaxel for previously treated, PD-L1-positive, advanced non-small-cell lung cancer (KEYNOTE-010): a randomised controlled trial. *Lancet.* 2016;387(10027):1540–1550. doi:10.1016/S0140-6736(15)01281-7
- Gandhi L, Rodriguez-Abreu D, Gadgeel S, et al. Pembrolizumab plus chemotherapy in metastatic non-small-cell lung cancer. *N Engl J Med.* 2018;378(22):2078–2092. doi:10.1056/NEJMoa1801005
- Rittmeyer A, Barlesi F, Waterkamp D, et al. Atezolizumab versus docetaxel in patients with previously treated non-small-cell lung cancer (OAK): a Phase 3, open-label, multicentre randomised controlled trial. *Lancet.* 2017;389(10066):255–265. doi:10.1016/S0140-6736(16)32517-X
- Hellmann MD, Ciuleanu TE, Pluzanski A, et al. Nivolumab plus ipilimumab in lung cancer with a high tumor mutational burden. *N Engl J Med.* 2018;378(22):2093–2104. doi:10.1056/NEJMoa1801946
- Carbone DP, Reck M, Paz-Ares L, et al. First-line nivolumab in stage IV or recurrent non-small-cell lung cancer. *N Engl J Med.* 2017;377(25):2415–2426. doi:10.1056/NEJMoa1613493
- Samstein RM, Lee CH, Shoushtari AN, et al. Tumor mutational load predicts survival after immunotherapy across multiple cancer types. *Nat Genet.* 2019;51(2):202–206. doi:10.1038/s41588-018-0312-8

18. Chalmers ZR, Connelly CF, Fabrizio D, et al. Analysis of 100,000 human cancer genomes reveals the landscape of tumor mutational burden. *Genome Med.* 2017;9(1):34. doi:10.1186/s13073-017-0424-2
19. Hui G, Ghafouri SN, Shen J, Liu S, Drakaki A. Treating Penile cancer in the immunotherapy and targeted therapy Era. *Case Rep Oncol Med.* 2019;2019:8349793.

OncoTargets and Therapy

Dovepress

Publish your work in this journal

OncoTargets and Therapy is an international, peer-reviewed, open access journal focusing on the pathological basis of all cancers, potential targets for therapy and treatment protocols employed to improve the management of cancer patients. The journal also focuses on the impact of management programs and new therapeutic

agents and protocols on patient perspectives such as quality of life, adherence and satisfaction. The manuscript management system is completely online and includes a very quick and fair peer-review system, which is all easy to use. Visit <http://www.dovepress.com/testimonials.php> to read real quotes from published authors.

Submit your manuscript here: <https://www.dovepress.com/oncotargets-and-therapy-journal>