

Primary hydatid cyst of brain: Two cases report

Satya Bhusan Senapati, Deepak Kumar Parida, A. S. Pattajoshi, Amiya Kumar Gouda, Ashis Patnaik

Department of Neurosurgery, SCB Medical College and Hospital, Cuttack, Odisha, India

ABSTRACT

Brain involvement with hydatid disease occurs in 1–2% of all *Echinococcus granulosus* infections. Isolated cerebral hydatid disease is a rare manifestation of it. In this report, we analyze two cases of isolated cerebral hydatid cysts and discuss their mode of presentation, radiological features, operative procedure and outcome. In our two cases, radiological features and surgical approaches were different from one another. The literature concerning isolated cerebral hydatid disease is reviewed.

Key words: Dowling-Orlando technique, *Echinococcus*, isolated cerebral hydatid cyst

Introduction

Hydatid disease is caused by the infestation of the larvae of *Taenia echinococcus*. The definite hosts of *Echinococcus* are various carnivores, the common being the dog. All mammals (more often being sheep and cattle) are intermittent hosts. Humans get infected through the feco-oral route by ingestion of food contaminated by dog feces containing ova of the parasite or by direct contact with dogs.

Case Report

Case 1

A 22-year-old male presented to us with complaints of headache for last 4 months, vomiting intermittently for 4 days and disorientation for 2 days. On physical examination, he was disoriented with bilateral papilledema and right sided hemiparesis. Computed tomography (CT) scan and magnetic resonance (MR) imaging of the brain [Figure 1a and b] were suggestive of a large multi-cystic lesion in parieto-occipital region. Lesion was removed by a large left parieto-occipital craniotomy. Due to large size, in toto removal was not possible. Cyst wall was punctured; multiple

daughter cysts removed one by one [Figure 1c]. After intracystic decompression, laminated membrane was removed by irrigating warm saline between cyst wall and brain interface. Pathological examination confirmed it as hydatid cysts. X-ray chest and USG of abdomen failed to show any lung or liver lesions. Five years after surgery, he remained well and free of disease.

Case 2

A 40-year-old male presented to us with complains of headache, generalised tonic clonic seizure, right-sided hemiparesis and intermittent vomiting for last 4 months. On Physical examinations, he was disoriented with bilateral papilledema. Brain CT scan revealed a large, well-defined cystic lesion in the left fronto-parietal region with mass effect. There was no surrounding edema or contrast enhancement [Figure 2a]. Radiological investigations of thorax and abdomen disclosed no evidence of hydatid disease. The lesion was removed in toto by irrigating saline between cyst wall and brain interface [Figure 2b and c]. Pathological examination confirmed hydatid cysts [Figure 2d]. One year after surgery, he is well and free of disease.

Discussion

Intracranial hydatid cyst may be classified as primary or secondary.^[1] Primary cysts are formed as a result of direct infestation of the larvae in the brain without demonstrable involvement of other organs. Lack of effective immune system in the brain, special architecture of brain tissue, patent ducts arteriosus and patent foramen ovale have been the proposed factors for isolated cerebral hydatid disease. In our two cases, echocardiography revealed no abnormality.

Magnetic resonance and CT scans characteristically show a spherical, well defined, non-enhancing cystic lesion without peripheral edema.^[2,3] The fluid density is generally equal

Access this article online	
Quick Response Code:	Website: www.asianjns.org
	DOI: 10.4103/1793-5482.152109

Address for correspondence:

Dr. Satya Bhusan Senapati, Department of Neurosurgery, SCB Medical College and Hospital, Cuttack - 753 007, Odisha, India.
E-mail: satya.bhusan.senapati@gmail.com

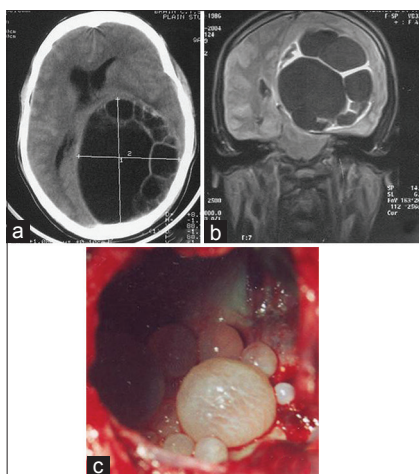


Figure 1: (a) Plain computed tomography scan of brain, axial view: Showing a large multi-cystic lesion in left parieto-occipital region with mass effect. (b) Plain magnetic resonance imaging scan of brain T1, coronal view: Showing a large multi-cystic lesion in left parieto-occipital region with mass effect. (c) Intraoperative findings confirm multiple daughter cysts inside a large cyst

to that of cerebro spinal fluid on both CT and MR scan. MR spectroscopy studies show pyruvate peaks besides lactate, alanine and acetate.^[4]

The treatment of hydatid cyst is surgical, and the aim of surgery is to excise the cyst in toto without rupture to prevent recurrence and anaphylactic reaction. Dowling-Orlando technique remains the preferred method, in which the cyst can be delivered by lowering the head of the operating table and instilling warm saline between the cyst and the surrounding brain parenchyma. This is possible because of minimal adhesions around the cyst wall.^[5]

Isolated case reports showed complete disappearance of multiple intracranial hydatid cysts with albendazole therapy in a daily dose of 10 mg/kg, taken three times a day for 4 months.^[6,7]

Conclusion

Incidence of primary hydatid cyst of brain is very rare. Patent ductus arteriosus and patent foramen ovale have been the proposed factors. In our cases, larvae might have passed through the capillary filter of the liver and lungs, entered into the systemic circulation and reached the brain. Aim should be in toto removal of the cyst. Sometimes because of large size, it is not possible, in that case intracystic decompression followed by removal of cyst wall by gentle traction and

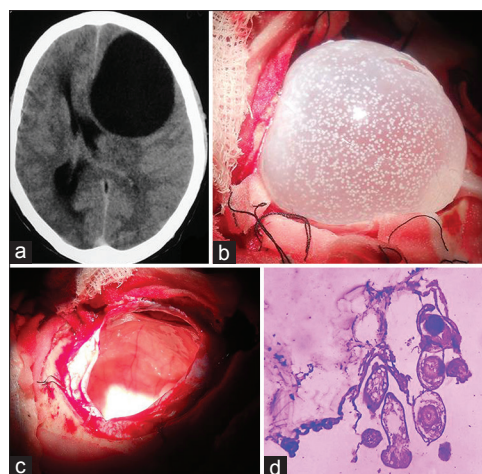


Figure 2: (a) Plain computed tomography scan of brain, axial view: Showing a large isolated cystic lesion in left frontal region with mass effect and midline shift. (b) Cyst was removed in toto by irrigating saline between cyst wall and brain interface. Cyst wall is also showing hydatid sand. (c) Cyst cavity and thin rim of cerebral cortex can be seen after removal of cyst wall. (d) Histo pathological study (H and E) of cyst wall showing germinal epithelium and scolices attached to it

saline irrigation between cyst wall brain interfaces is a better option.

References

1. Nurchi G, Floris F, Montaldo C, Mastio F, Peltz T, Coraddu M. Multiple cerebral hydatid disease: Case report with magnetic resonance imaging study. *Neurosurgery* 1992;30:436-8.
2. Coates R, von Sinner W, Rahm B. MR imaging of an intracerebral hydatid cyst. *AJNR Am J Neuroradiol* 1990;11:1249-50.
3. Karak PK, Mittal M, Bhatia S, Mukhopadhyay S, Berry M. Isolated cerebral hydatid cyst with pathognomonic CT sign. *Neuroradiology* 1992;34:9-10.
4. Kohli A, Gupta RK, Poptani H, Roy R. *In vivo* proton magnetic resonance spectroscopy in a case of intracranial hydatid cyst. *Neurology* 1995;45:562-4.
5. Arana Iniguez R. *Echinococcus*. Infection of the nervous system. In: Vinken PJ, Bruyn GW, editors. *Hand Book of Clinical Neurology, Part III*. Amsterdam: Elsevier/North Holland Biomedical Press; 1978. p. 175-208.
6. Singounas EG, Leventis AS, Sakas DE, Hadley DM, Lampadarios DA, Karvounis PC. Successful treatment of intracerebral hydatid cysts with albendazole: Case report and review of the literature. *Neurosurgery* 1992;31:571-4.
7. Todorov T, Vutova K, Petkov D, Balkanski G. Albendazole treatment of multiple cerebral hydatid cysts: Case report. *Trans R Soc Trop Med Hyg* 1988;82:150-2.

How to cite this article: Senapati SB, Parida DK, Pattajoshi AS, Gouda AK, Patnaik A. Primary hydatid cyst of brain: Two cases report. *Asian J Neurosurg* 2015;10:175-6.

Source of Support: Nil, **Conflict of Interest:** None declared.