



Featured Operative Technique

Masculinized Male Chest Contouring: Creating the Armor Plate

Arian Mowlavi, MD[✉]; Waleed Rashid, BS; Mariam Berri, BS; and Armin Talle, BS

Aesthetic Surgery Journal Open Forum 2019, 1–7

© 2019 The American Society for Aesthetic Plastic Surgery, Inc.

This is an Open Access article distributed under the terms of the Creative Commons Attribution-NonCommercial-NoDerivs licence (<http://creativecommons.org/licenses/by-nc-nd/4.0/>), which permits

non-commercial reproduction and distribution of the work, in any medium, provided the original work is not altered or transformed in any way, and that the work is properly cited. For commercial re-use, please contact journals.permissions@oup.com

DOI: 10.1093/asjof/ojz023
www.asjopenforum.com

OXFORD
UNIVERSITY PRESS

Abstract

Male patients are routinely consulted regarding dislike of their chest appearance. To date, majority of patients have desired elimination of their feminine-appearing breast, termed gynecomastia. These patients have associated their overweight body image, with the femininity of their breasts as presented by fullness and roundedness of their breasts and subsequently have desired maximal flattening of their breast. We present a new set of patients who desire a more muscular-appearing chest than a gynecomastia repair that is interposed on a chiseled abdominal contour. In contrast to the former set of patients, these patients desire bulking of their breasts with a bolder-appearing armor plate look. We present an alternative to traditional gynecomastia repair which involves a novel approach to chest contouring creating a flat, yet bold, pentagonal-shaped breast with linear borders utilizing both fat and gland removal as well as strategic fat grafting back into the chest. We present a novel protocol to create an armor plate male chest appearance as an alternative to traditional gynecomastia contouring. All patients treated to date demonstrate a muscular-appearing chest that is harmonious on an interposed masculine-appearing abdomen.

Editorial Decision date: July 10, 2019; online publish-ahead-of-print August 14, 2019.

Male patients are routinely consulted in our office regarding improving their chest contour. To date, patients have desired global debulking of chest prominence associating their bulky chest with a feminine and overweight appearance.^{1,2} Successful contouring of these patients, coined gynecomastia repair, required removal of both the peri-areolar glandular component and debulking of the peripheral adipose tissues^{3,4} (Figure 1). Although gynecomastia repair defeminized the chest, it was clearly not masculinized. In contrast, we present an alternative male chest contouring paradigm that provides for a bold and bulky masculine chest that is interposed on a chiseled, etched more masculinized abdomen. The initiative to create a more masculine chest contour protocol developed following observation that abdominal etching performed for males

was disharmonious with the traditionally flattened chest appearance following gynecomastia repair^{5,6} (Figure 2). As a result, a novel protocol was designed to allow for a stronger armor plate appearing chest to be created that would be more aligned with a masculinized abdomen. It became clear that although the chest needed to be flattened, it had to be bold and armor plate in appearance. As such,

Dr Mowlavi is a plastic surgeon in private practice in Laguna Beach, CA. Mr Rashid, Ms Berri, and Mr Talle are Researchers, University of California, Irvine, Irvine, CA.

Corresponding Author:

Dr Arian Mowlavi, Cosmetic Plastic Surgery Institute, 32406 South Coast Highway, Laguna Beach, CA 92651.
E-mail: drmowlavi@gmail.com

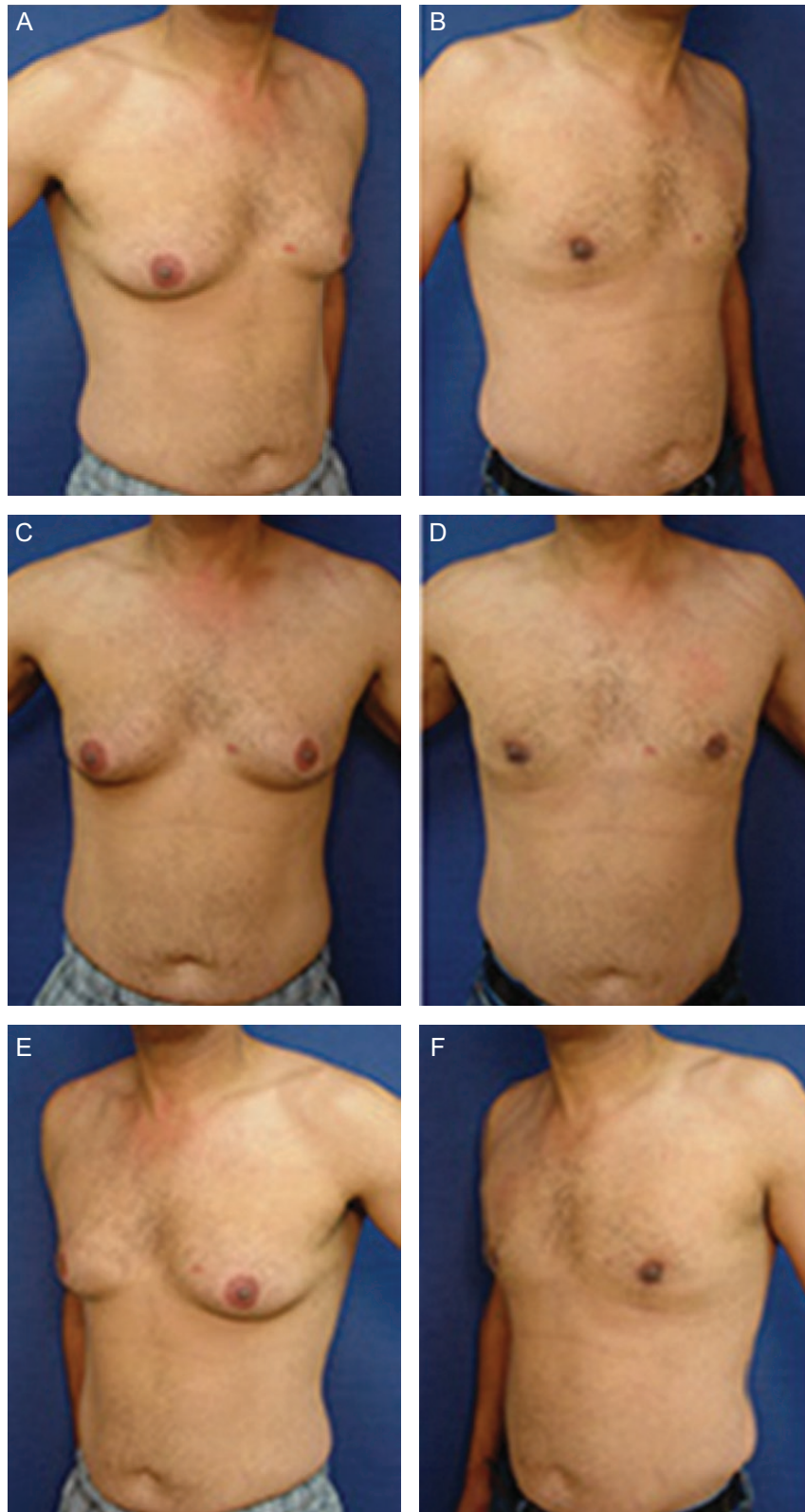


Figure 1. Flattening and debulking of chest to treat gynecomastia shown above is a 38-year-old male (A, C, E) before and (B, D, F) 3 months following a bilateral gynecomastia repair. Periareolar glandular component has been removed and excess adiposity of the chest has been debulked. Postoperative results show defeminization of the chest, but the patient lacks a masculinized chest appearance.

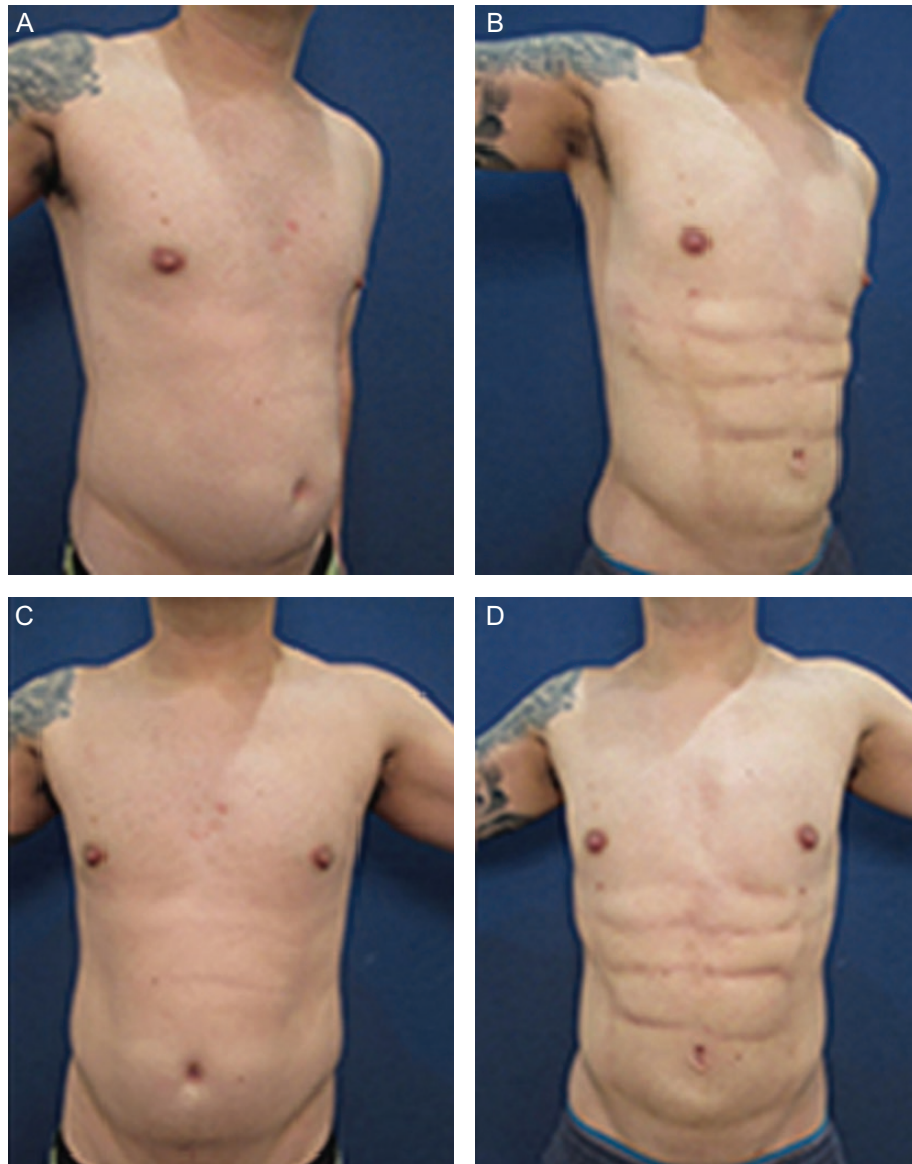
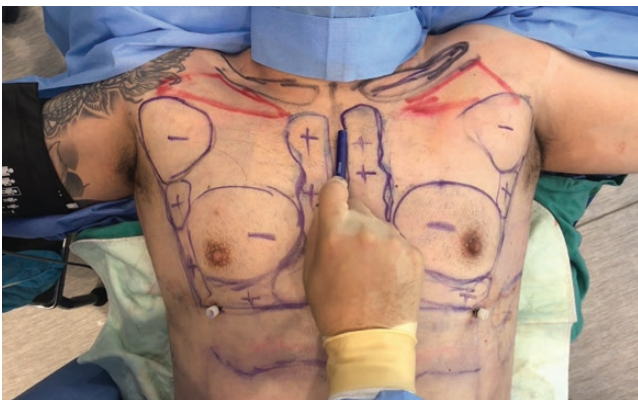
Figure 2. Abdominal etching procedure disharmonious with flattened chest appearance. A 37-year-old male (A, C) before and (B, D) 3 months following ultrasound-assisted liposuction of the abdomen to achieve masculine abdominal etching which is disharmonious with a maximally flattened chest following traditional gynecomastia repair.



Video 1. Watch now at <https://academic.oup.com/asjof/article-lookup/doi/10.1093/asjof/ojz023>

a flat, yet pentagonal-shaped chest appearance with linear lines was designed in order to mimic an armored plate look.

When the degree of fat/fibrous tissue excess is associated with minimal to moderate skin redundancy, you are an ideal candidate for the limited incision gynecomastia repair. Infrequently, patients with severe breast skin redundancy will be recommended to undergo en-block resection of the breast skin.

METHODS

This study reviews the technique of chest optimization on a cohort of 38 males with ages ranging from 21 to 62 years old (average, 37.5 years old).

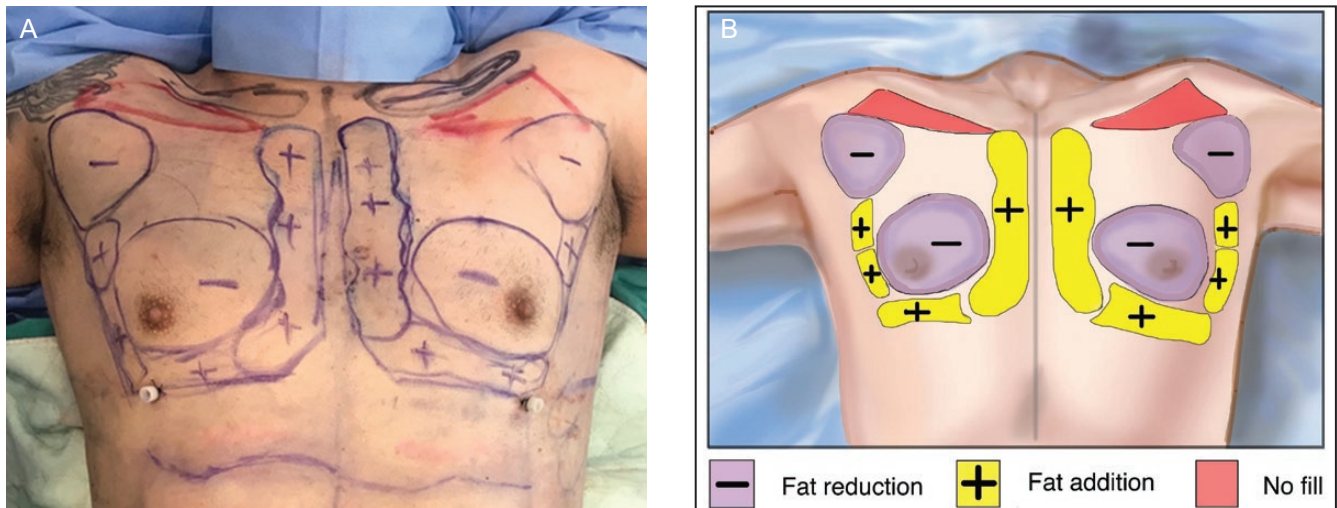


Figure 3. (A) Preoperative markings of chest masculinization protocol. A 37-year-old male demonstrating markings where plus signs indicate regions where fat is added, whereas minus signs indicate regions fat will be subtracted. This strategic placement of fat helps us to create a pentagonal-shaped chest with bold and linear borders. (B) Illustration of the markings.

We demonstrate alternative technique to traditional gynecomastia repair for male chest contouring by creating the armor plate look (Video, available online as [Supplementary Material](#)). Preoperative markings, the surgical markings shown in [Figure 3](#), illustrate the male chest appropriate markings. An accurate understanding of the male superficial anatomy and topography is mandatory for precision in each individual examination.

This look provides a more masculine outcome than the prior technique and is more aligned with patients who are desiring simultaneous abdominal etching. Patient's chests are treated with ultrasound-assisted liposuction to remove the periareolar glandular and adipose tissues as well as any adiposity in the anterior axillary region. In addition, patients are treated with a combination of intramuscular and subcutaneous fat grafting strategically to create a pentagonal-shaped chest with bold and linear borders ([Figure 3](#)). Intramuscular pectoralis muscle injection is performed along the vertical medial line. This injection of fat into the pectoralis muscle performed simultaneously with gynecomastia repair allows for an aesthetically pleasing, as well as a masculine, appearance of the chest.⁷ Subcutaneous fat is injected to create the medial oblique line, the inferior horizontal line, and the lateral oblique line when mid-lateral concavity is present. The upper central and intraclavicular triangle is not altered. This comprehensive approach to chest contouring creates a flat yet bold contour that is made to mimic an armor plate.

Management of fat grafting is optimized by techniques utilizing ultrasound-assisted liposuction. Ultrasound-assisted liposuction has gained considerable attention for fat grafting, with similar techniques

published previously.⁷ Variability in harvest and processing technique may affect the success of fat grafting. Unique to each case, fat grafting volume and liposuction volume vary. Fat graft amount ranges between 60 and 350 cc injected to each chest side (average, 150 cc). Tumescient solution is used to infiltrate and aspirate (roughly 2–4 mL of solution for each milliliter of aspirated volume). Average infiltration varies between 100–300 (right) and 100–280 (left) with an average of 150 (both right and left). Dependent on small or large volume liposuction being performed, it is recommended to not exceed 5000 mL of volume aspirated, with cases averaging 3,500 for total aspiration. Fat graft is collected using sterile technique and grafted into the pectorals (10 cc injected into single prominent inscription). No complications were found in all cases.

Performance with this technology enables for both superficial and deep fat layer removal with cannulas, optimizing the male chest contour, and requires a skilled, experienced surgeon. Postoperative follow-up time is required every day for the first week, then weekly for the first 2 months, and then on a PRN basis. Photographs are taken at the 3- to 4-month mark for each patient.

RESULTS

Below, we have demonstrated three cases of an armor male chest contour interposed on a harmonious masculinized abdominal contour. All patients, 6-month postsurgery, demonstrate a pentagonal shaped chest with bold and linear borders ([Figures 4–6](#)). Patients were monitored, and no complications were experienced.

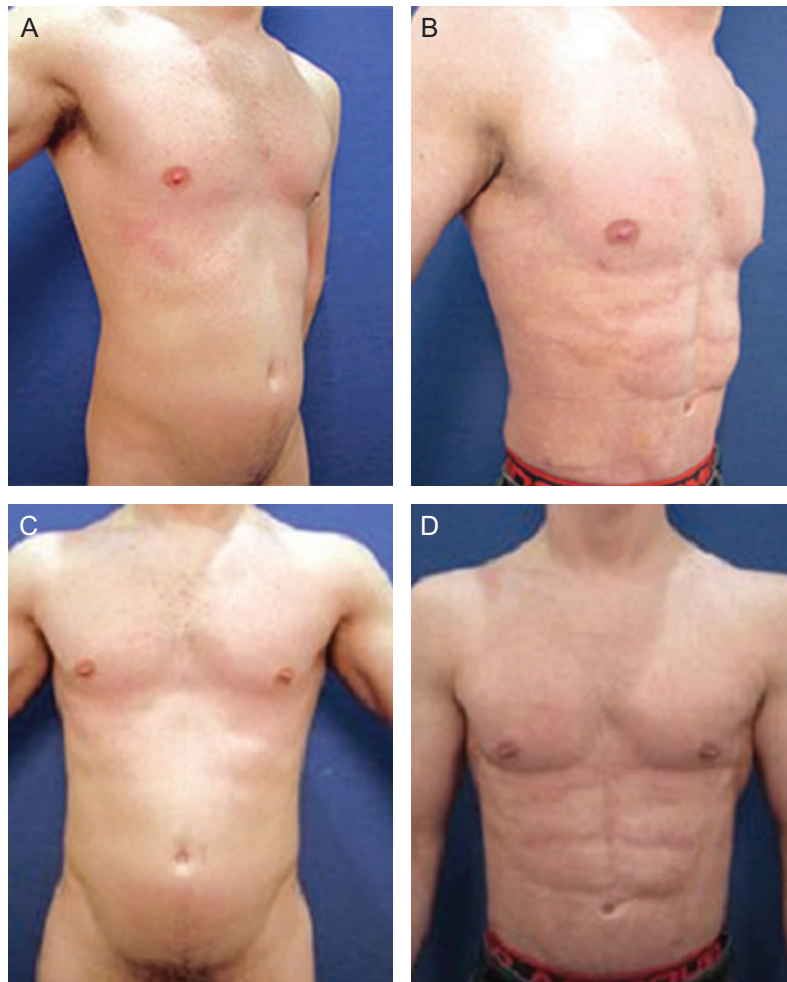


Figure 4. Male chest contouring to create a masculinized armor plate appearance. A 34-year-old male (A, C) before and (B, D) 3 months following ultrasound-assisted liposuction of the abdomen, lateral chest, pubic region, and fat grafting to the chest. Patient demonstrates linear chest borders postoperation creating a more masculinized appearance.

DISCUSSION

Creation of a masculinized breast contour allows for an armor plate look as observed in a depiction of medieval fighting suits. As pectoral etching techniques including silicone implants⁸ have been published, we find that the use of fat grafting in creating the armor chest plate is best suited for enhanced musculature profiles of the pectoral muscle. Previous research has sought a trapezoidal chest approach,⁷ although the creation of a pentagonal shape achieves a well-defined masculine chest. This armor plate appearance provides a more harmonious appearance when interposed on an etched abdomen. By using comprehensive glandular and fat removal and addition of fat strategically, this masculinized male breast contour can be consistently created.^{8,9} Several modifications to traditional contouring techniques have been made. First, in order to allow for both liposuction and fat grafting with a single

port, separate subcutaneous tunnelings are used in order to avoid connection between liposuctioned regions and fat transferred regions, so transfer of fat does not occur between these two regions. In addition, the traditional liposuction port used to treat the chest and torso has been altered from the infra-areolar region to a lower inframammary crease position. This allows for the creation of the pentagonal shape as well as bold and linear borders. Furthermore, liposuction of the lateral chest and axilla are used to create a more defined lateral chest and lateral linear border. Finally, liposuction of the sternal line is used to enhance the vertical medial linear border.

CONCLUSION

The armor plate chest appearance provides a more masculine male chest appearance. We represent this alternative approach to traditional gynecomastia repair technique since

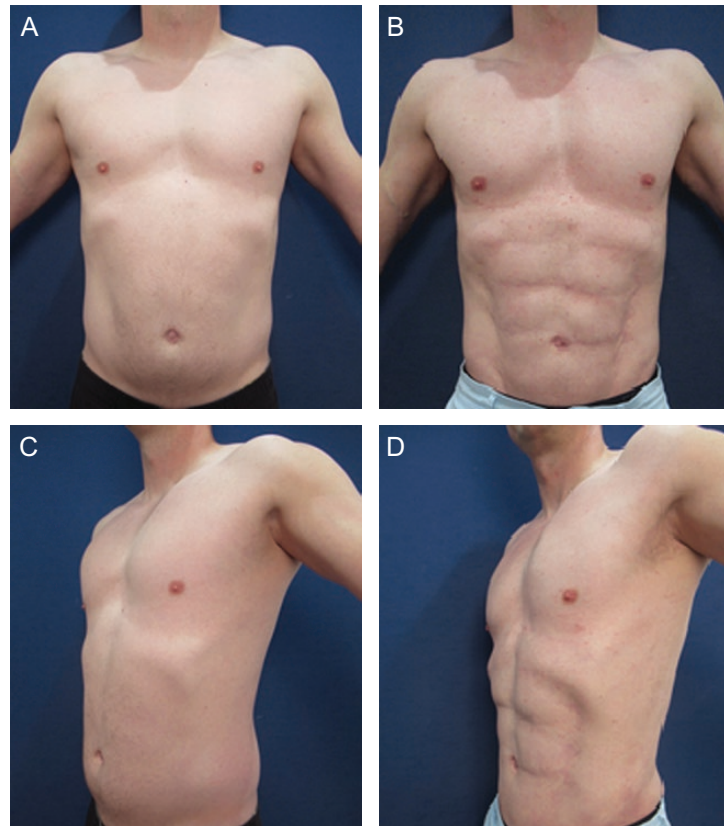


Figure 5. Male chest contouring to create a masculinized armor plate appearance. A 37-year-old male (A, C) before and (B, D) 4 months following ultrasound-assisted liposuction of the abdomen, back, lateral chest, neck, and fat grafting to the chest. Patients demonstrates defined chest borders and a more masculinized chest postoperation.

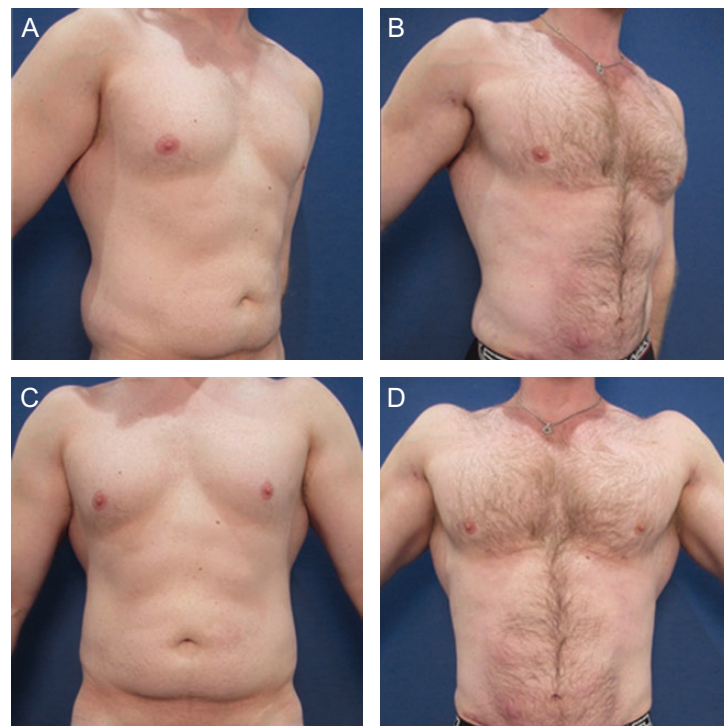

Figure 6. Male chest contouring to create a masculinized armor plate appearance. A 30-year-old male (A, C) before and (B, D) 3 months following ultrasound-assisted liposuction of the abdomen, thighs, flanks, lower back, and lateral chest, and fat grafting to the chest. Patient demonstrates a more rigid and masculinized chest postoperation.

it achieves a more muscular-appearing chest contour that is more harmonious on a male patient undergoing abdominal etching. Further monitoring and precise evaluation of patients will expand on the evaluation of fat-cell survival and needed to determine the efficaciousness of this technique.

Supplementary Material

This article contains supplementary material located online at <http://www.asjopenforum.com>.

Disclosures

Dr Mowlavi is a paid trainer for VASER (Valeant Pharma) and Bovie Medical. The other authors declared no potential conflicts of interest with respect to the research, authorship, and publication of this article.

Funding

The authors received no financial support for the research, authorship, and publication of this article.

REFERENCES

1. Blau M, Hazani R, Hekmat D. Anatomy of the gynecomastia tissue and its clinical significance. *Plast Reconstr Surg Glob Open*. 2016;4(8):e854.
2. Innocenti A, Melita D, Mori F, Innocenti M, Ciancio F. Discussion on "Gynecomastia surgery-impact on life quality: a prospective case-control study". *Ann Plast Surg*. 2018;80(2):193-194.
3. Yu P, Yang X, Qi Z. Management of gynecomastia in patients with different body types: considerations on 312 consecutive treated cases. *Ann Plast Surg*. 2017;79(2):226.
4. Cuhaci N, Polat SB, Evranos B, Ersoy R, Cakir B. Gynecomastia: clinical evaluation and management. *Indian J Endocrinol Metab*. 2014;18(2):150-8.
5. Hurwitz D. Enhancing masculine features after massive weight loss. *Aesthetic Plast Surg*. 2016;40(2):245-55.
6. Blau M, Hazani R. Correction of gynecomastia in body builders and patients with good physique. *Plast Reconstr Surg*. 2015;135(2):425-32.
7. Monarca C, Rizzo MI. Gynecomastia: tips and tricks-classification and surgical approach. *Plast Reconstr Surg*. 2013;131(5):863e-5e.
8. Mentz HA, Ruiz-Razura A, Newall G, Patronella CK, Miniel LA. Pectoral etching: a method for augmentation, delineation, and contouring the thoracic musculature in men. *Plast Reconstr Surg*. 2007;120(7):2051-5.
9. Pilanci O, Basaran K, Aydin HU, Cortuk O, Kuvat SV. Autologous fat injection into the pectoralis major as an adjunct to surgical correction of gynecomastia. *Aesthet Surg J*. 2015;35(3):NP54-61.