


Surgical treatment of non-tuberculous mycobacterial lymphadenitis in children: Our experience and a narrative review

International Journal of
Immunopathology and Pharmacology
Volume 32: 1–5
© The Author(s) 2018
Article reuse guidelines:
sagepub.com/journals-permissions
DOI: 10.1177/2058738418806413
journals.sagepub.com/home/iji


Sara Torretta^{1,2} , Michele Gaffuri², Tullio Ibba², Pasquale Capaccio^{2,3}, Paola Marchisio^{2,4}, Antonella Maruca², Samantha Bosis² and Lorenzo Pignataro^{1,2}

Abstract

Non-tuberculous mycobacterial lymphadenitis (NTML) accounts for about 95% of the cases of head-and-neck mycobacterial lymphadenitis, and its prevalence has been increasing in the Western world. The diagnostic work-up can be challenging, and differential diagnoses such as tuberculous and suppurative lymphadenitis need to be considered. It may, therefore, not be diagnosed until the disease is in a late stage, by which time it becomes locally destructive and is characterized by a chronically discharging sinus. The treatment options include a medical approach, a wait-and-see policy, and surgery, with the last being considered the treatment of choice despite the high risk of iatrogenic nerve lesions. The aim of this article is to provide an overview of pediatric, head-and-neck NTML based on the literature and our own experience, with particular emphasis on the impact and limitations of surgery.

Keywords

children, head and neck, lymphadenitis, non-tuberculous mycobacteria

Date received: 20 April 2018; accepted: 19 September 2018

Introduction

Non-tuberculous mycobacterial lymphadenitis (NTML) accounts for about 95% of the cases of head-and-neck mycobacterial lymphadenitis.¹ It typically presents as a painless, slowly progressive, and unilateral mass mainly located at the parotid/pre-auricular or submandibular loggia (stage I), and not associated with systemic symptoms or signs. Untreated infections evolve to colliquative necrosis with lymph node tenderness (stage II), and subsequent cutaneous involvement leading to a violaceous discoloration of the overlying skin (stage III). In the latter stages (stage IV), the disease becomes locally destructive with the creation of a chronically discharging sinus. Spontaneous healing usually occurs within 6 months, but the clinical course may also be longer

and is often associated with unesthetic sequelae due to scarring.

The differential diagnoses include tuberculous (TB) and suppurative lymphadenitis. The former generally affects older children with positive risk factors for TB disease; pulmonary and

¹Department of Clinical Sciences and Community Health, Università Degli Studi Di Milano, Milan, Italy

²Fondazione IRCCS Ca' Granda Ospedale Maggiore Policlinico, Milan, Italy

³Department of Biomedical, Surgical and Odontoiatric Sciences, Università Degli Studi Di Milano, Milan, Italy

⁴Department of Pathophysiology and Transplantation, Università Degli Studi Di Milano, Milan, Italy

Corresponding author:

Sara Torretta, Fondazione IRCCS Ca' Granda Ospedale Maggiore Policlinico, Via Francesco Sforza 35, 20122 Milan, Italy.
Email: sara.torretta@gmail.com



constitutional symptoms are generally present in TB but not NTML, whereas skin discoloration is typical of NTML and generally not present in TB lymphadenitis.² Increased inflammatory markers may be detected in the case of TB lymphadenitis but not NTML; an interferon gamma release assay (IGRA) is positive in 70%–80% of the cases of TB lymphadenitis cases and generally negative in NTML.^{2,3} The diagnostic work-up may be challenging as a final diagnosis follows the isolation and identification of the causative organism. A tuberculin skin test may give false-positive results due to cross-reactivity or previous *Bacillus Calmette–Guérin* (BCG) vaccination;⁴ however, it is generally assumed that skin induration of ≥ 15 mm would more likely suggest *Mycobacterium tuberculosis*, and a reaction of 5–9 mm would more likely be related to NTML.⁵

The treatment options include a medical approach, a wait-and-see policy, and surgery. Antibiotic treatment generally consists of multi-agent regimens, but NTML is frequently multi-drug resistant; furthermore, a medical approach may lead to untoward events in up to 74% of patients.⁶ Surgical excision may be complicated by the fact that most of the patients present late-disease and, above all, by the fact that iatrogenic nerve dysfunction should be considered a possible sequela as NTML is mainly located near a branch of the facial nerve.

The aim of this review of the literature and our own experience is to describe the impact and limitations of surgery in the management of children with NTML.

Methods

Pertinent studies published between January 2000 and January 2018 were selected by S.T. in February 2018 by means of a Medline search accessed via PubMed and the Cochrane Library of titles and abstracts using the standard Boolean system linking category domains and determinants; the words “non-tuberculous mycobacterial lymphadenitis AND children” were used as search string.

The papers were screened for relevance by S.T. and included for critical appraisal. We only considered fully accessible English language papers published in peer-reviewed journals, and specifically dealing with the surgical management of NTML in

children. The exclusion criteria were, therefore, inaccessibility, papers in languages other than English, non-peer-reviewed papers, papers published before January 2000 or after February 2018, and papers not specifically dealing with the surgical management of NTML in children. The reference lists were subsequently reviewed in order to ensure that all of the selected papers were truly relevant and identify any possibly overlooked papers.

Results

On the basis of the exclusion criteria, 8 of the 21 initially selected papers were included in this review, corresponding to 571 patients.^{2,6–13} Table 1 shows their main characteristics and surgical results.

Our experience

Between January 2015 and December 2017, 10 patients with NTML (four males; mean age of 27.0 months, range of 4–77 months) underwent surgical excisions at the ENT Unit of Fondazione IRCCS Ca' Granda Ospedale Maggiore Policlinico in Milan, Italy. At the time they were first seen at our hospital, four (40%) were in stage III, four (40.0%) in stage II, and two (20.0%) in stage IV (Figure 1). Submandibular involvement was detected in three patients (30.0%), a jugo-digastric location in six (60.0%), and the mass was located at the lower third of the internal jugular vein chain in one child (10%).

The patients received multi-drug antibiotic treatment (intravenous vancomycin at a dose of 40 mg/kg/day and intravenous piperacillin plus tazobactam at a dose of 150 mg/kg/day) for 14 days before surgery, which proved to be ineffective. The antibiotic treatment was stopped in two cases (20.0%) because of adverse events (cutaneous rash in one and hepatitis in the other).

All of the patients underwent the complete surgical excision of the diseased lymph nodes under general anesthesia using a modified neck dissection technique. In the case of the patients with stage IV disease, the involved overlying skin and discharging sinus were removed en bloc with the lymph node. At the end of the surgical procedure, a surgical drain was placed (to be removed 2 days later), and the wound was closed with resorbable sutures.

Table 1. Results of the included studies.

Authors (year)	No. of patients	Mean age (range)	Site	Stage	Treatment	Cure rate	Complications
Flint et al. (2000) ⁷	57	26.7 m (12 m–4 y)	SM = 47% Submental = 5% P = 16% Neck ^a = 28%	–	Excision = 19% Non-excisional surgery ^b = 5%	Excision = 91% Non-excisional surgery = 35%	MM nerve dysfunction = 8% (after excision)
Lindeboom et al. (2007) ⁸	100	45.5 m (9–168 m)		I = 18% II–III = IV = 82%	Excision = 50% Medical treatment = 50%	Excision = 96% Medical treatment = 66% 100%	MM nerve dysfunction = 14% Wound infection = 12% Hematoma = 2% (after excision) Temporary MM dysfunction = 18%; Hypertrophic scar = 18%
Harris et al. (2009) ⁹	11	43 m (17 m–13 y)	SM = 82% P = 9% P + SM = 9% (all superficial)	III	Excision		
Claesson et al. (2010) ¹⁰	126	2.7 y (0.6–13 y)	Neck = 97% (groin = 3%)	–	Excision = 53% Incision and debridement = 35% No surgery = 13%	94%	Retropharyngeal abscess = 2% Parotid fistula = 2% Permanent accessory nerve dysfunction = 1% MM dysfunction = 10% (after surgery) Hypertrophic scar = 9% Prolonged healing time = 3% (after extirpation)
Scott et al. (2012) ¹¹	43	33 m (11–130 m)	SM = 40% P = 16% Neck ^a = 28% Other sites = 6%	I–II = 37% III = 47% IV = 16%	Excision = 47% Incision and drainage = 40% Aspiration = 2% No surgery = 2%	Excision = 70% Incisional interventions = 23%	Facial nerve dysfunction = 15% (after incision) Discharging sinus = 16% Wound infection = 14%
Mahadevan et al. (2016) ¹²	97	27 m (8 m–15 y)	SM = 46% P = 17% Submental = 4% Neck ^a = 38% SM = 53% P = 23% Neck ^a = 17% Parapharyngeal = 4% Outer ear = 3%	–	Excision = 37% Incision and drainage = 35% Incision and curettage = 32% Aspiration = 2% Surgery = 27% Medical treatment = 73%	Excision = 81% Incisional interventions = 44%	MM dysfunction = 7% (permanent = 4%, temporary = 3%) Hypertrophic scar = 7% Discharging sinus = 5% (after incision)
Rives et al. (2016) ¹³	30	4.5 y (2–28 y)		I = 35% II = 42% IV = 10%		Surgery = 75% Medical treatment = 90%	–
Tebruegge et al. (2016) ²	107	2.6 y (2.1–3.8 y)	SM/neck ^a = 86% P = 7%	III = 15% IV = 2%	Excision = 97% Incisional biopsy = 2%	–	Facial nerve dysfunction = 7%

M: months; y: years; SM: submandibular; P: parotid; MM: marginalis mandibulae.

^aNeck sites other than submandibular and parotid.^bIncision and drainage/incision and curettage/aspiration.

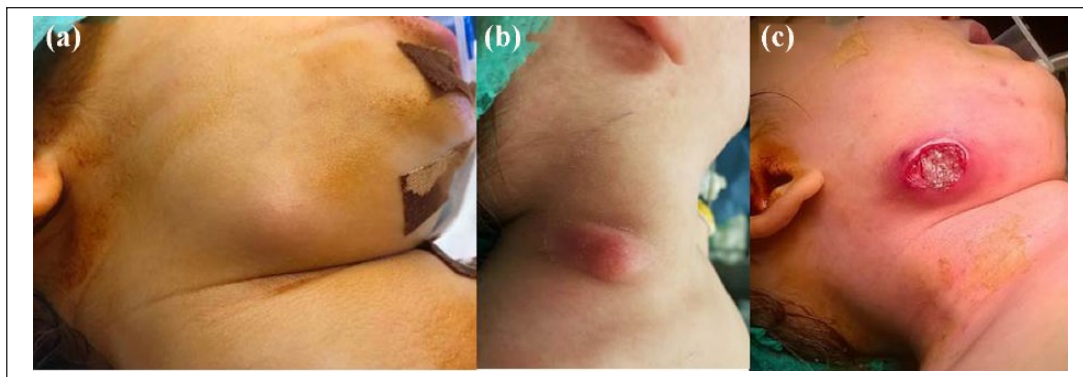

Figure 1. Non-tuberculous mycobacterial lymphadenitis of the head and neck: stage II (a), stage III (b), and stage IV (c).

A nerve stimulator was used in all of the cases in order to evaluate the preserved functional integrity of the *marginalis mandibulae* or the accessory spinal nerve. Permanent marginal mandibular nerve palsy occurred in one patient (10.0%), but there were no other complications and no recurrences before the end of the follow-up period, which ranged from 3 to 39 months.

The diagnoses were made on the basis of positive culture (30%) or polymerase chain reaction (PCR) results (40%) obtained upon the microbiological analysis of a portion of the removed lymph node, or the finding of an epithelial and giant-cell granuloma and acid-alcohol-resistant bacilli upon during the pathological examination. *Mycobacterium avium* complex was detected in three cases (30.0%), and acid-fast bacilli were identified during the microbiological assessment of a fourth; histopathological evaluations documented the presence of granulomatous inflammation suggesting NTML in all of the cases.

Discussion and practical recommendations

The management of children with cervico-facial NTML is challenging: medical protocols consist of long-term anti-mycobacterial treatment with a clarithromycin-based multi-drug regimen, but the infection may progress and untoward events may be responsible for treatment discontinuation.¹² A watchful waiting strategy has been advocated by some authors on the grounds that NTML is essentially a self-limiting disease and complications unrelated to cosmetic appearance are extremely rare in immunocompetent children.⁹ Surgical strategies include complete excision, incision and

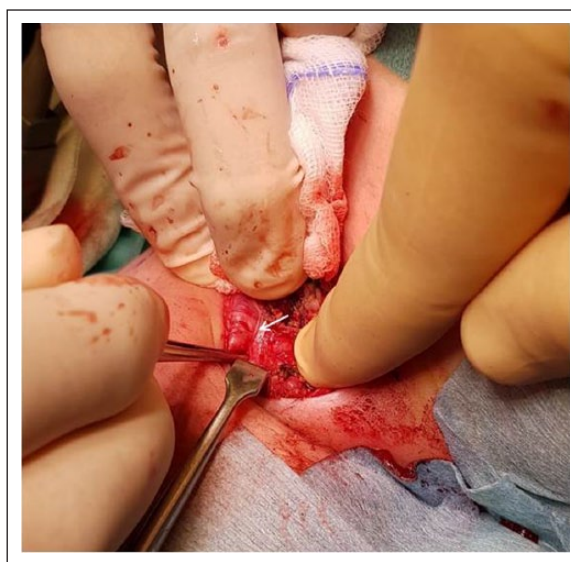

Figure 2. Intra-operative view of the strict anatomical relationship between stage IV non-tuberculous mycobacterial lymphadenitis and the adjacent spinal accessory nerve (arrow).

drainage, incision and curettage, incisional biopsy, and aspiration.

On the basis of our literature review, surgical treatment leads to recovery rates ranging from 35% to 100%, with higher rates after excisional (70%–100%) than non-excisional surgery (23%–44%) (Table 1). However, given the strict anatomical relationship between diseased lymph nodes and important nerves (Figure 2) unpleasant complications such as nerve dysfunction have been reported in 1%–18% of cases (Table 1), and these are more frequent after excisional surgery. However, discharging sinuses, prolonged healing times, hypertrophic scars, and persistent disease requiring further surgery occur more frequently in patients undergoing non-excisional procedures.

Complete surgical excision can, therefore, be considered the treatment of choice and should be performed as soon as possible in order to reduce the risk of esthetic and functional sequelae that are more frequent in later disease stages. Furthermore, the benign nature of the disease means that smaller surrounding reactive lymph nodes and bordering inflammatory tissue can be preserved, which, in our experience, reduces the risk of iatrogenic lesions without increasing the risk of recurrences. In the case of extra-nodal involvement (skin involvement or the formation of sinuses), one-stage surgery should be used with the en bloc removal of the lymph node and the adjacent soft tissue. Early detection and intervention are important in order to reduce the risk of iatrogenic nerve lesions and unesthetic sequelae mainly occurring in advanced disease.

Surgical approaches that do not involve the complete removal of diseased lymph nodes should be avoided because of the high risk of recurrences, impaired healing, and discharging sinuses. A conservative approach (medical treatment or a wait-and-see policy) can be considered in selected cases when a complete surgical excision is difficult or impossible, such as in the case of deep neck involvement or a high risk of nerve dysfunction.

Declaration of conflicting interests

The author(s) declared no potential conflicts of interest with respect to the research, authorship, and/or publication of this article.

Funding

The author(s) received no financial support for the research, authorship, and/or publication of this article.

ORCID iD

Sara Torretta  <https://orcid.org/0000-0002-8461-6042>

References

- Albright JT and Pransky SM (2003) Nontuberculous mycobacterial infections of the head and neck. *Pediatric Clinics of North America* 50: 503–514.
- Tebruegge M, Pantazidou A, MacGregor D, et al. (2016) Nontuberculous mycobacterial disease in children: Epidemiology, diagnosis & management at a tertiary center. *PLoS ONE* 11: e0147513.
- Zimmermann P, Curtis N and Tebruegge M (2017) Nontuberculous mycobacterial disease in childhood: Update on diagnostic approaches and treatment. *The Journal of Infection* 74(Suppl. 1): S136–S142.
- Detjen AK, Keil T, Roll S, et al. (2007) Interferon-gamma release assays improve the diagnosis of tuberculosis and nontuberculous mycobacterial disease in children in a country with a low incidence of tuberculosis. *Clinical Infectious Disease* 45: 322–328.
- Lindeboom JA, Kuijper EJ, Prins JM, et al. (2006) Tuberculin skin testing is useful in the screening for nontuberculous mycobacterial cervicofacial lymphadenitis in children. *Clinical Infectious Disease* 43: 1547–1551.
- Timmerman MK, Morley AD and Buwalda J (2008) Treatment of non-tuberculous mycobacterial cervicofacial lymphadenitis in children: Critical appraisal of the literature. *Clinical Otolaryngology* 33: 546–552.
- Flint D, Mahadevan M, Barber C, et al. (2000) Cervical lymphadenitis due to non-tuberculous mycobacteria: Surgical treatment and review. *International Journal of Pediatric Otorhinolaryngology* 53: 187–194.
- Lindeboom JA, Kuijper EJ, Bruijnesteijn van Coppenraet ES, et al. (2007) Surgical excision versus antibiotic treatment for nontuberculous mycobacterial cervicofacial lymphadenitis in children: A multicenter, randomized, controlled trial. *Clinical Infectious Disease* 2007; 44: 1057–1064.
- Harris RL, Modayil P, Adam J, et al. (2009) Cervicofacial nontuberculous mycobacterium lymphadenitis in children: Is surgery always necessary? *International Journal of Pediatric Otorhinolaryngology* 73: 1297–1301.
- Claesson G, Bennet R, Eriksson M, et al. (2011) Nerve dysfunction following surgical treatment of cervical non-tuberculous mycobacterial lymphadenitis in children. *Acta Paediatrica* 100: 299–302.
- Scott CA, Atkinson SH, Sodha A, et al. (2012) Management of lymphadenitis due to non-tuberculous mycobacterial infection in children. *Pediatric Surgery International* 28: 461–466.
- Mahadevan M, Neeff M, Van Der Meer G, et al. (2016) Non-tuberculous mycobacterial head and neck infections in children: Analysis of results and complications for various treatment modalities. *International Journal of Pediatric Otorhinolaryngology* 82: 102–106.
- Rives P, Joubert M, Launay E, et al. (2016) Cervicofacial non-tuberculous mycobacteria: A report of 30 cases. *European Annals of Otorhinolaryngology, Head and Neck Diseases* 133: 107–111.