



The Efficacy of the Graft Materials after Sinus Elevation: Retrospective Comparative Study Using Panoramic Radiography

Tae Min Jeong, Jeong Keun Lee

Division of Oral and Maxillofacial Surgery, Department of Dentistry, Ajou University School of Medicine

Abstract

Purpose: This study compares and evaluates the efficacy of graft materials after maxillary sinus bone grafts with autogenous tooth bone graft material (AutoBT), demineralized freeze-dried bone allograft (DFDBA) and deproteinized bovine bone mineral (DBBM).

Methods: The study involved 30 sinuses in 26 patients who visited the Division of Oral and Maxillofacial Surgery, Department of Dentistry in Ajou University Hospital and received either AutoBT, DFDBA or DBBM with sinus elevation using the lateral window technique. Sinus graft height was measured before, immediately after, and six months after bone graft with panoramic radiography and the height changes of the sinus floor was compared according to the graft materials.

Results: After six months, the decrease ratio of graft heights were 13.57% for AutoBT group, 14.30% for DFDBA group, and 11.92% for DBBM group. There was no statistically significant difference.

Conclusion: The new maxillary sinus floor formed by the upper border of bone graft material, can repneumatize after the maxillary sinus elevation. Thus, long-term stability of sinus graft height represents an important factor for implant success. We found that the three graft materials for sinus elevation do not differ significantly and all three graft materials showed excellent resistance to maxillary sinus repneumatization. However, due to the special circumstances of the maxillary sinus and small sample, the actual difference between the three graft materials may not have been detectable. Therefore further study needs to be conducted for more reliable study results.

Key words: Efficacy, Sinus floor augmentation, Bone substitutes, Comparative study, Panoramic radiography

Introduction

Implant procedure is a widely accepted prosthodontic treatment and surgical method for edentulous areas, based on osseointegration between the organic bone and the artificial implant fixture. Host factors such as the residual

amount of the bone, quality of the bone, patient's overall condition, local environment or anatomical factors of the implant site, smoking, patient's educational background, and the will for health can affect implant success. In this regard, the anatomically limited maxillary posterior area's pneumatization progresses with alveolar bone absorption

RECEIVED May 5, 2014, REVISED May 26, 2014, ACCEPTED July 15, 2014

Correspondence to Jeong Keun Lee

Division of Oral and Maxillofacial Surgery, Department of Dentistry, Ajou University School of Medicine
164 WorldCup-ro, Yeongtong-gu, Suwon 443-380, Korea
Tel: 82-31-219-5328, Fax: 82-31-219-5329, E-mail: arcady@ajou.ac.kr

Copyright © 2014 by The Korean Association of Maxillofacial Plastic and Reconstructive Surgeons. All rights reserved.

© This is an open access article distributed under the terms of the Creative Commons Attribution Non-Commercial License (<http://creativecommons.org/licenses/by-nc/3.0>) which permits unrestricted non-commercial use, distribution, and reproduction in any medium, provided the original work is properly cited.

due to loss of teeth. The resulting inadequate residual bone is problematic for implantation. Many methods have been suggested to overcome this condition. Currently the most efficacious surgical method is maxillary sinus floor elevation, which in almost all cases can resolve vertical dimension, and enables implantation in a prosthetically ideal location[1].

The newly formed floor after the maxillary sinus elevation repneumatizes from the upper border of grafted material over an extended period[2,3]. Repneumatization is caused by the pressure of maxillary sinus or blood clot absorption immediately after surgery in the short term, and in the long term by revascularization and absorption of the grafted material through the positive pressure formed inside the maxillary sinus due to respiration[4,5]. The grafted material is absorbed by repneumatization of the maxillary sinus, as the apical portion of implant fixture may contact the mucosa of the maxillary sinus instead of bone[6], leading to implant failure[7].

The gold standard of maxillary sinus bone graft is autograft[8,9], but it is not considered optimum graft material because it requires additional surgery on the donor site, the collection amount is limited, there is patient discomfort, and risk of complications. Therefore alternatives such as allogenic bone, xenogenic bone and synthetic bone are being explored. Most of these found no difference in implant success rate comparing autograft with non-autograft, leading to the current trend of using non-autograft material [10-12]. Two studies conducted long-term prospective controlled studies of implant materials related to maxillary sinus bone graft: deproteinized bovine bone mineral (DBBM) and β -tricalcium phosphate[12,13]. However, these materials are less than optimum material because of risks including lack of osteoinductive capability, the potential to spread infection, and foreign body reaction. Therefore, ongoing research on types of bone graft material is needed.

Table 1. Classification of patients and sinuses

Graft materials	Patients (n)	Sinuses (n)
AutoBT	6	8
DFDBA	11	13
DBBM	9	9

AutoBT, autogenous tooth bone graft; DFDBA, demineralized freeze-dried bone allograft; DBBM, deproteinized bovine bone mineral.

In maxillary sinus bone graft, we compare DBBM, autogenous tooth bone graft material (AutoBT), and demineralized freeze-dried bone allograft (DFDBA). DBBM is one of the most reliable bone graft materials today, AutoBT is actively researched nowadays, and DFDBA has osteoinductive capability. We examine each material's effectiveness by comparing the degree of repneumatization of maxillary sinus by using panoramic radiography.

Materials and Methods

In this study, the patients who received maxillary sinus bone graft in Division of Oral and Maxillofacial Surgery, Department of Dentistry in Ajou University Hospital from April 2010 to July 2013 were recruited. The patients underwent surgery through a lateral window technique with either AutoBT graft, DFDBA, or DBBM graft. Patients with diabetes, hypertension, osteoporosis, acute maxillary sinusitis, cysts or tumors, progressive chronic periodontal disease or chronic sinusitis were excluded from the study. As a result, the AutoBT group had eight maxillary sinuses, the DFDBA group had 13 maxillary sinuses, and the DBBM group had nine maxillary sinuses (Table 1).

Panoramic radiographs were taken before, immediately after, and six months after surgery by the same device. For the measurement of grafted material height, two observers blinded to the graft material used conducted the procedure, and measured the height twice each using a digital caliper. The median value was selected. If there was more than 1 mm difference between the two examiners' measurement values, it was remeasured, and if the second measurement still had more than 1 mm difference, the median value was used. Groups were assigned by the graft material type for measurement (Table 2~4) and the

Table 2. Radiologic evaluation of AutoBT group

Patient No.	Sinuses	A (mm)	B (mm)	C (mm)
1	Left	4.4	17.3	16.0
2	Right	3.8	8.5	7.9
2	Left	9.4	16.9	16.9
3	Left	6.3	17.3	13.6
4	Left	3.5	12.5	11.0
5	Right	3.3	12.5	11.5
5	Left	3.7	16.0	14.8
6	Right	10.0	16.0	15.1

AutoBT, autogenous tooth bone graft; A, before surgery; B, immediately after surgery; C, 6 months after surgery.

difference value between before-surgery and immediately after surgery was calculated to measure the initial height of the graft material (Fig. 1; D). The mean and standard deviation of each graft material were calculated. The absorption height of the graft material was calculated as the difference immediately after surgery and six months later (Fig. 1; B, C), and the mean and standard deviation for each graft type were determined. Finally, the degree of absorption of the initial graft material height in relation to absorption ratio (Fig. 1; repneumatization ratio) was calculated, and the mean and standard deviation were determined for each graft material. Kruskal-Wallis test was used to assess the role of chance in differences among the three measurement values. PASW Statistics ver. 18.0

Table 3. Radiologic evaluation of DFDBA group

Patients No.	Sinuses	A (mm)	B (mm)	C (mm)
1	Left	2.3	16.2	15.3
2	Right	2.5	13.8	11.3
2	Left	3.5	12.9	12.0
3	Right	10.6	19.0	18.0
4	Left	7.0	15.0	13.0
5	Left	5.0	17.0	15.7
6	Left	7.3	15.3	13.6
7	Right	4.8	19.0	17.8
8	Right	8.5	16.7	15.3
9	Left	5.5	16.4	15.0
9	Right	3.0	15.0	13.3
10	Right	8.3	17.7	17.0
11	Left	1.7	18.4	15.2

DFDBA, demineralized freeze-dried bone allograft; A, before surgery; B, immediately after surgery; C, 6 months after surgery.

statistical package (IBM Co., Armonk, NY, USA) was used for all statistical analysis. We rejected null hypotheses of no difference if *P*-values were less than 0.05.

This study was reviewed and approved by the Institutional Review Board at the Ajou University Hospital (AJIRB-MED-MDB-14-103).

Results

The average elevated height of bone graft material was 9.07 ± 2.92 mm in AutoBT group, 10.95 ± 2.75 mm in DFDBA group, 11.83 ± 2.81 mm in DBBM group, and there was no significant difference among the three graft groups (Fig. 2). When the radiographic images taken six months after surgery were compared, there was an average height decrease of 1.27 ± 1.06 mm in the AutoBT group, 1.53 ± 0.71 mm in the DFDBA group, 1.37 ± 1.09 mm in

Table 4. Radiologic evaluation of DBBM group

Patients No.	Sinuses	A (mm)	B (mm)	C (mm)
1	Right	5.4	19.9	18.5
2	Right	5.7	15.3	13.7
3	Left	5.7	21.0	19.8
4	Right	10.3	20.3	19.1
5	Right	9.5	20.1	19.8
6	Right	5.4	21.0	20.0
7	Left	6.4	19.2	15.3
8	Right	6.5	16.3	16.3
9	Right	4.9	13.0	11.2

DBBM, deproteinized bovine bone mineral; A, before surgery; B, immediately after surgery; C, 6 months after surgery.

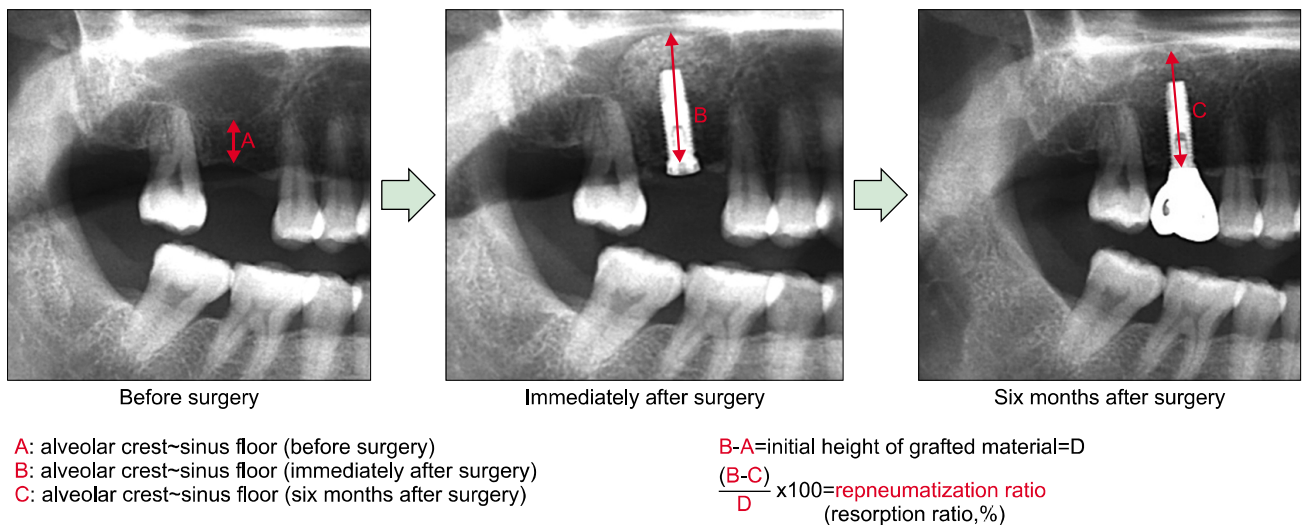


Fig. 1. A 55-year-old female who received sinus elevation and implant placement with autogenous tooth bone graft. Panoramic radiography was conducted before, immediately after, and six months after surgery by the same device.

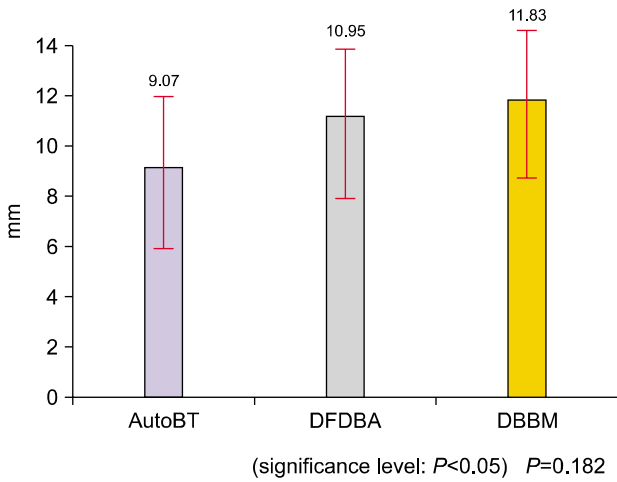


Fig. 2. Average elevated height of grafted material. AutoBT, autogenous tooth bone graft; DFDBA, demineralized freeze-dried bone allograft; DBBM, deproteinized bovine bone mineral.

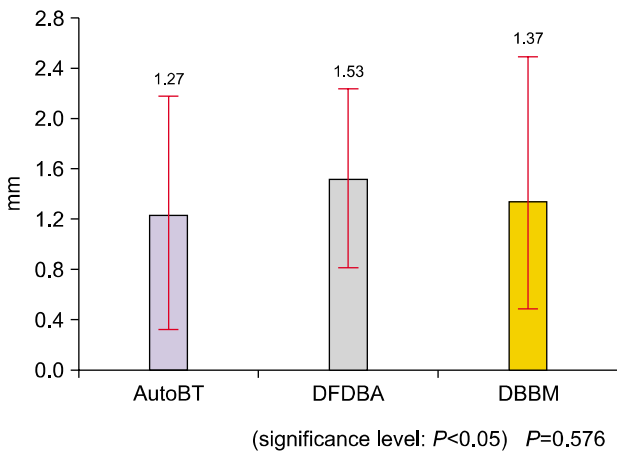


Fig. 3. Average resorption height of grafted material after 6 months. AutoBT, autogenous tooth bone graft; DFDBA, demineralized freeze-dried bone allograft; DBBM, deproteinized bovine bone mineral.

the DBBM group, with no significant difference among groups (Fig. 3). Lastly, when the decreased amount of graft material was compared relative to the initial amount of elevated height, not the absolute value, it was $13.57\% \pm 9.39\%$ in the AutoBT group, $14.30\% \pm 6.09\%$ in the DFDBA group, and $11.92\% \pm 9.51\%$ in the DBBM group, with no significant difference among groups (Fig. 4).

Discussion

When the maxillary posterior teeth are lost, the residual alveolar bone is resorbed, and the maxillary sinus begins

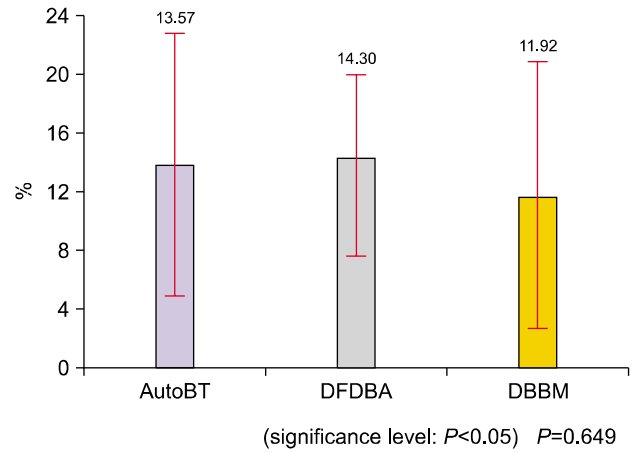


Fig. 4. Average resorption ratio of grafted material after 6 months. AutoBT, autogenous tooth bone graft; DFDBA, demineralized freeze-dried bone allograft; DBBM, deproteinized bovine bone mineral.

pneumatization. In addition, the maxillary posterior area often has poor bone quality, and gets high loading. When the amount of residual alveolar bone is insufficient, implant placement is difficult[14]. Therefore, when the resorption of alveolar bone in the maxillary posterior area is severe, an additional bone graft is often necessary to increase the amount of residual alveolar bone.

To overcome the problems of an edentulous maxillary posterior area, methods used include improving the implant surface preparation[15], improving the implant form[16], and improving the implant placement area with an osteotome[17]. In addition, a short implant can solve insufficient vertical dimension[18], oblique implantation[19], use of zygoma implant[20], and maxillary sinus elevation[10,11]. To solve the lack of vertical dimension, maxillary sinus elevation can be applied in almost all cases. The technique is relatively simple, is recognized as the most predictable surgical method, and for that reason is currently the most widely used[1].

The new maxillary sinus floor, formed by the upper border of bone graft material, repneumatizes after maxillary sinus elevation[2,3]. Hatano *et al.*[7] stated that there is a possibility of repneumatization in the first two to three years. To avert this, gradually absorbing or non-absorbable grafted materials need to be used. As the bone graft is absorbed through the repneumatization of the maxillary sinus, the apical portion of the implant fixture can be in contact with the maxillary sinus mucosa instead of osseous

tissue[6], leading to eventual implant failure[7]. However, repneumatization of maxillary sinus is not permanent, but stops when the implant in the maxillary sinus starts to function. Thus, repneumatization peaks within one year after surgery, especially within six months after the surgery[3,7], and many studies have evaluated the degree of repneumatization six months after surgery[21-24]. Therefore, this study also compared the radiographs taken immediately after surgery and six months after surgery to evaluate the degree of repneumatization.

The ideal test method to measure the difference in the volume and the degree of grafted material absorption is computed tomography (CT)[21]. However, the crucial factor to determine the prognosis of grafted material is the height decrease of the grafted material rather than its volume decrease[7], and since panoramic radiographs measure the height of grafted material accurately[25], this study used panoramic radiographs to measure the change in height of grafted material.

The resorption degree of maxillary sinus graft material differs depending on characteristics including sex, age, relationships of opposite teeth, implant prosthodontic type, timing for implant placement, general disease, smoking, and drinking. A study of factors affecting survival of maxillary sinus augmented implants[26] found no significant differences in sex, age, smoking, general disease, and the survival rate. Delayed placement of implant resulted in a significantly higher survival rate than simultaneous placement of implant. In contrast, another study[27] found similar survival rates for simultaneous (92.17%) and delayed procedure (92.93%). The author recommended simultaneous placement if residual alveolar bone volume is enough for proper initial fixation, but recommended delayed placement if residual alveolar bone volume is insufficient.

The degree of repneumatization differs depending on the type of bone graft material, and this is determined by the graft material's degree of absorption. Autogenous bone is the gold standard of bone graft: its properties include osteogenesis, osteoinduction, osteoconduction as well as no immune rejection, advantages for fast bone healing. However, its limitations of requiring additional surgery for bone sample collection, inducing secondary defects, and the limited amount of collection are problem-

atic[28,29]. Autogenous bone graft material has the best osteogenic ability, but the graft material is replaced by the newly formed bone, and gets rapidly absorbed, a phenomenon that appears even after maxillary sinus bone graft[30]. Thus, a great amount of repneumatization appears after maxillary sinus bone graft using autogenous bone. In a study that reported long-term stability of maxillary sinus height, autogenous bone decreased 1.8 ± 0.4 mm, synthetic bone decreased 0.9 ± 0.3 mm, and autogenous bone+synthetic bone decreased 0.8 ± 0.6 mm in height, showing greater repneumatization in autogenous bone than in synthetic bone[2].

DBBM used in this study was xenogenic bone obtained by removing all organic materials from the bovine bone. The structure is very similar to human bone, and binds well with human bone in the modeling and remodeling process. The porous structure takes up 75% of the entire volume, providing the optimum environment for vascularization and new bone adhesion. The surface microstructure supports the bone so that the bone-forming osteoblasts can optimally adhere, and many studies have reported its bone conduction capability[31-33]. It was first introduced as absorbent graft material, and is currently the most commonly used bone-augmenting graft material for implants, although a research study found a significant amount of residue even nine years after maxillary sinus bone graft[34]. Therefore, DBBM are not completely absorbed. After a year of using the autogenous bone and DBBM mixed in the ratio of 2:8 in 30 areas of the maxillary sinus in 20 patients, the height of grafted material decreased slightly, only 9.3%, from 15.0 mm to 13.6 mm on panoramic radiographs. In another study, when DBBM was used for maxillary sinus bone graft, the average elevation was 11.68 mm, decreased 1.67 mm six months later, an average decrease of 14.53%[24]. In this study, the average elevation was 11.83 mm in the maxillary sinus bone graft using DBBM, and reduced 1.37 mm six months later, an average 11.92% reduction. Therefore, after the maxillary sinus bone graft using the natural hydroxyapatite that contains DBBM, 9.3% to 14.53%, the height decrease is about 10%, excellent resistance to maxillary sinus repneumatization.

AutoBT contains both organic and inorganic materials, has structure and physico-chemical characteristics that are most similar to structures of alveolar bone compared to

other bone graft materials, and thus shows great bone regeneration ability. Because it is made with the patient's own tissues, it presents no risk of infection or immune response[35]. Teeth can be obtained through normal dental extraction procedure; thus the clinician can easily apply it, with reduced complications in the donor site. AutoBT is a new graft material that is being actively studied, and promising results are drawing clinical attention. In particular, maxillary sinus elevation procedure using AutoBT is showing good prognoses[36]; thus more in-depth research is needed. The Division of Oral and Maxillofacial Surgery, Department of Dentistry in Ajou University Hospital, where this study was conducted, began using AutoBT in April 2010 clinically, and is reporting related research[37]. As shown in this study, the average elevation was 9.07 mm after maxillary sinus elevation, decreased 1.27 mm six months later; an average of 13.57% height reduction. This did not differ from DBBM, and thus this material also has great repneumatization-resistance ability.

DFDBA is a bone graft material that was demineralized, frozen, and dried after being collected from human cadavers. In particular, it has greater osteoinduction ability than that of mineralized bone since the osteoinduction inducing protein called bone morphogenic protein (BMP) is exposed through demineralization process. In addition, it shows relatively good prognosis in maxillary sinus bone graft[38]. However, some researchers state that the amount of BMP is not sufficient to support osteoinduction, and further, poses a risk of disease. DFDBA has no special advantages compared to xenogenic graft and synthetic graft, and both clinical reports and research studies are decreasing. However, as shown in the results of this study, the demineralized free-driedallogeneic bone used for maxillary sinus floor elevation gave average elevation of 10.95 mm, reduced 1.53 mm six months later, an average 14.30% reduction rate. The degree of absorption was much lower than expected a priori, and the degree of height reduction was similar to that of DBBM, the grafted material that is not well absorbed within the maxillary sinus.

The results of this study, a similar degree of bone absorption rate in all of three grafted materials, can be discussed from three perspectives. First, the maxillary sinus is a contained defect, with an environment that offsets the differences among graft materials because it forms good bony

housing, surrounded as it is by the neighboring bone and mucous membranes in the upper area. A number of graft materials used in maxillary sinus bone graft that do not differ in healing, autograft, allograft, xenogenic graft, and synthetic graft can all be used safely. Thus choice of suitable material resides with the clinician's preference. Second, when only the maxillary sinus floor elevation was performed, and bone graft material was not used, limited bone formation takes place[39,40]. This possibly offsets the ingenuity of different graft materials, and is important in producing similar results in all of the three grafted materials. Finally, very small sample size limited statistical power such that we could detect only very large differences. Most of the maxillary sinus floor elevation cases that are conducted in this hospital use mixed graft materials due to lack of bone graft material amount, especially AutoBT. It was natural to have small number of subjects in this study because single graft material was used. For this reason, the number of samples was insufficient, the actual difference among the three graft materials may not have been revealed.

The limitations of this study are, as described above, the lack of absolute sample size, insufficient data due to the fundamental limitations of retrospective study, and not using various images to measure the changes in bone graft material height more accurately. A wide range of samples and systematized data need to be collected in order to have more reliable study results.

Conclusion

In this study, 26 patients who had 100% AutoBT, DFDBA, and DBBM in 30 areas of maxillary sinus were studied, and the panoramic radiography were taken before, immediately after, and six months after surgery to compare and evaluate the degree of repneumatization in the grafted materials. Results showed that the decrease ratio of graft heights were 13.57% for AutoBT group, 14.30% for DFDBA group and 11.92% for DBBM group and there was no significant difference in the repneumatization ratio between the three graft materials. All of the three graft materials showed excellent resistance to maxillary sinus repneumatization. However, due to the special circumstances of maxillary sinus and lack of absolute sample size, the actual difference

among the three graft materials may not have been revealed. Therefore further study is needed for more reliable study results.

References

1. Aghaloo TL, Moy PK. Which hard tissue augmentation techniques are the most successful in furnishing bony support for implant placement? *Int J Oral Maxillofac Implants* 2007;22 Suppl:49-70.
2. Jensen OT, Shulman LB, Block MS, Iacono VJ. Report of the Sinus Consensus Conference of 1996. *Int J Oral Maxillofac Implants* 1998;13 Suppl:11-45.
3. Nyström E, Legrell PE, Forssell A, Kahnberg KE. Combined use of bone grafts and implants in the severely resorbed maxilla. Postoperative evaluation by computed tomography. *Int J Oral Maxillofac Surg* 1995;24:20-5.
4. McAllister BS, Margolin MD, Cogan AG, Buck D, Hollinger JO, Lynch SE. Eighteen-month radiographic and histologic evaluation of sinus grafting with anorganic bovine bone in the chimpanzee. *Int J Oral Maxillofac Implants* 1999;14:361-8.
5. Hürzeler MB, Kirsch A, Ackermann KL, Quifones CR. Reconstruction of the severely resorbed maxilla with dental implants in the augmented maxillary sinus: a 5-year clinical investigation. *Int J Oral Maxillofac Implants* 1996;11:466-75.
6. GaRey DJ, Whittaker JM, James RA, Lozada JL. The histologic evaluation of the implant interface with heterograft and allograft materials--an eight-month autopsy report, part II. *J Oral Implantol* 1991;17:404-8.
7. Hatano N, Shimizu Y, Ooya K. A clinical long-term radiographic evaluation of graft height changes after maxillary sinus floor augmentation with a 2:1 autogenous bone/xenograft mixture and simultaneous placement of dental implants. *Clin Oral Implants Res* 2004;15:339-45.
8. Gamradt SC, Lieberman JR. Bone graft for revision hip arthroplasty: biology and future applications. *Clin Orthop Relat Res* 2003;(417):183-94.
9. Sailer HF, Weber FE. Bone substitutes. *Mund Kiefer Gesichtschir* 2000;4 Suppl 1:S384-91.
10. Wallace SS, Froum SJ. Effect of maxillary sinus augmentation on the survival of endosseous dental implants. A systematic review. *Ann Periodontol* 2003;8:328-43.
11. Del Fabbro M, Testori T, Francetti L, Weinstein R. Systematic review of survival rates for implants placed in the grafted maxillary sinus. *Int J Periodontics Restorative Dent* 2004;24:565-77.
12. Hong SM. The literature review on the sinus bone graft using deproteinized bovine bone mineral with lateral approach. *J Korean Assoc Oral Maxillofac Surg* 2006;32:482-7.
13. Zijdeveld SA, Zerbo IR, van den Bergh JP, Schulten EA, ten Bruggenkate CM. Maxillary sinus floor augmentation using a beta-tricalcium phosphate (Cerasorb) alone compared to autogenous bone grafts. *Int J Oral Maxillofac Implants* 2005;20:432-40.
14. Martinez H, Davarpanah M, Missika P, Celletti R, Lazzara R. Optimal implant stabilization in low density bone. *Clin Oral Implants Res* 2001;12:423-32.
15. Le Guéhennec L, Soueidan A, Layrolle P, Amouriq Y. Surface treatments of titanium dental implants for rapid osseointegration. *Dent Mater* 2007;23:844-54.
16. Akkocaoglu M, Uysal S, Tekdemir I, Akca K, Cehreli MC. Implant design and intraosseous stability of immediately placed implants: a human cadaver study. *Clin Oral Implants Res* 2005;16:202-9.
17. Strietzel FP, Nowak M, Kuchler I, Friedmann A. Peri-implant alveolar bone loss with respect to bone quality after use of the osteotome technique: results of a retrospective study. *Clin Oral Implants Res* 2002;13:508-13.
18. Nedir R, Bischof M, Briaux JM, Beyer S, Szmukler-Moncler S, Bernard JP. A 7-year life table analysis from a prospective study on ITI implants with special emphasis on the use of short implants. Results from a private practice. *Clin Oral Implants Res* 2004;15:150-7.
19. Aparicio C, Perales P, Rangert B. Tilted implants as an alternative to maxillary sinus grafting: a clinical, radiologic, and periotest study. *Clin Implant Dent Relat Res* 2001;3:39-49.
20. Landes CA. Zygoma implant-supported midfacial prosthetic rehabilitation: a 4-year follow-up study including assessment of quality of life. *Clin Oral Implants Res* 2005;16:313-25.
21. Johansson B, Grepe A, Wannfors K, Hirsch JM. A clinical study of changes in the volume of bone grafts in the atrophic maxilla. *Dentomaxillofac Radiol* 2001;30:157-61.
22. Schlegel KA, Fichtner G, Schultze-Mosgau S, Wiltfang J. Histologic findings in sinus augmentation with autogenous bone chips versus a bovine bone substitute. *Int J Oral Maxillofac Implants* 2003;18:53-8.
23. Wanschitz F, Figl M, Wagner A, Rolf E. Measurement of volume changes after sinus floor augmentation with a phylogenetic hydroxyapatite. *Int J Oral Maxillofac Implants* 2006;21:433-8.
24. Kim JS, Park TI, Seo HS, *et al.* The graft height changes after sinus augmentation procedures using deproteinized bovine bone mineral and beta-tricalcium phosphate: a retrospective comparative study using panoramic radiography. *J Korean Assoc Oral Maxillofac Surg* 2008;34:468-74.
25. Hallman M, Hedin M, Sennerby L, Lundgren S. A prospective 1-year clinical and radiographic study of implants placed after maxillary sinus floor augmentation with bovine hydroxyapatite and autogenous bone. *J Oral Maxillofac Surg* 2002;60:277-84.
26. Nkenke E, Schultze-Mosgau S, Radespiel-Tröger M, Kloss F, Neukam FW. Morbidity of harvesting of chin grafts: a prospective study. *Clin Oral Implants Res* 2001;12:495-502.
27. Nkenke E, Radespiel-Tröger M, Wiltfang J, Schultze-Mosgau S, Winkler G, Neukam FW. Morbidity of harvesting of retromolar bone grafts: a prospective study. *Clin Oral Implants Res* 2002;13:514-21.
28. Thorwarth M, Srouf S, Felszeghy E, Kessler P, Schultze-Mosgau S, Schlegel KA. Stability of autogenous bone grafts after sinus lift procedures: a comparative study between anterior and posterior aspects of the iliac crest and an intraoral donor site. *Oral Surg Oral Pathol Oral Radiol Endod* 2005;100:278-84.
29. Valentini P, Abensur D. Maxillary sinus floor elevation for implant placement with demineralized freeze-dried bone and bovine bone (Bio-Oss): a clinical study of 20 patients. *Int J Periodontics Restorative Dent* 1997;17:232-41.

30. Valentini P, Abensur D, Wenz B, Peetz M, Schenk R. Sinus grafting with porous bone mineral (Bio-Oss) for implant placement: a 5-year study on 15 patients. *Int J Periodontics Restorative Dent* 2000;20:245-53.
31. Yildirim M, Spiekermann H, Biesterfeld S, Edelhoff D. Maxillary sinus augmentation using xenogenic bone substitute material Bio-Oss in combination with venous blood. A histologic and histomorphometric study in humans. *Clin Oral Implants Res* 2000;11:217-29.
32. Traini T, Valentini P, Iezzi G, Piattelli A. A histologic and histomorphometric evaluation of anorganic bovine bone retrieved 9 years after a sinus augmentation procedure. *J Periodontol* 2007;78:955-61.
33. Kim YK, Kim SG, Byeon JH, *et al*. Development of a novel bone grafting material using autogenous teeth. *Oral Surg Oral Med Oral Pathol Oral Radiol Endod* 2010;109:496-503.
34. Jeong KI, Kim SG, Oh JS, Lim SC. Maxillary sinus augmentation using autogenous teeth: preliminary report. *J Korean Assoc Maxillofac Plast Reconstr Surg* 2011;33:256-63.
35. Han MW, Lee JK. Clinical study on the efficacy of the autogenous tooth bone graft material (AutoBT). *J Korean Assoc Maxillofac Plast Reconstr Surg* 2013;35:221-6.
36. van den Bergh JP, ten Bruggenkate CM, Krekeler G, Tuinzing DB. Maxillary sinus floor elevation and grafting with human demineralized freeze dried bone. *Clin Oral Implants Res* 2000; 11:487-93.
37. Kumar DS, Jayakumar ND, Padmalatha O, Sankari M, Varghese SS. Effect of maxillary sinus floor augmentation without bone grafts. *J Pharm Bioallied Sci* 2013;5:176-83.
38. He L, Chang X, Liu Y. Sinus floor elevation using osteotome technique without grafting materials: a 2-year retrospective study. *Clin Oral Implants Res* 2013;24 Suppl A100:63-7.
39. In YS, Park YW. Factors affecting survival of maxillary sinus augmented implants. *J Korean Assoc Maxillofac Plast Reconstr Surg* 2011;33:241-8.
40. Del Fabbro M, Testori T, Francetti L, Weinstein R. Systematic review of survival rates for implants placed in the grafted maxillary sinus. *Int J Periodontics Restorative Dent* 2004;24: 565-77.