

The Anterolateral Ligament of the Knee: Descriptive Anatomy and Clinical Correlation

Abstract

Background: The anterolateral ligament is a fibrous structure in the anterolateral aspect of the knee. Recently this ligament of the knee has gained spotlight in anatomical and imaging studies and has been designated as a new ligament of the knee joint. The anterolateral ligament (ALL) has been postulated to be a restraint against the anterolateral instability of the knee resulting in a positive pivot shift test. The purpose of this study is to provide detailed anatomical characteristics of ALL in the Indian population. **Materials and Methods:** The qualitative and quantitative characteristics of the ALL were observed in 20 embalmed cadaveric specimens. In all but one left male knee specimen (95%) ALL was observed. After isolating the ALL, its length, thickness, width, and points of attachments and dimensions of lateral collateral ligament (LCL) were determined. **Results:** The ALL was consistently present in the anterolateral region of the knee separate from the joint capsule. Its proximal attachment to the femur is anterior and distal to the attachment of the LCL. Distally the superficial fibers of the ALL inserted close to the Gerdy's tubercle at the level of the fibular head, and the deeper fibers merged with the lateral meniscus. The mean length of the ALL was 43.35 mm ± 4.04 mm in flexion and 40.38 mm ± 4.35 mm in extension. The average width of the ALL was 6.98 mm ± 0.95 mm at its origin and 9.36 mm ± 1.07 mm at its insertion. **Conclusion:** The ALL is hypothesized to affect internal tibial rotation and plays a role in the pivot shift phenomenon. ALL rupture could be responsible for rotatory laxity after isolated intraarticular reconstruction of the ACL.

Keywords: Anterolateral ligament, fibular collateral ligament, Gerdy's tubercle, Indian population, knee joint

**Shaifaly Madan Rustagi,
Parikshat Gopal,
Manish Singh Ahuja,
Naresh Chander Arora,
Nikhil Sood**

Department of Anatomy, Army College of Medical Sciences, New Delhi, India

Introduction

The knee joint is stabilized by a complex system of static and dynamic stabilizers.¹⁻⁵ There have been various studies which have tried to demonstrate the anatomy of the lateral aspect of the knee, but none have been able to demonstrate completely the structure and function of the ligamentous structures on the lateral aspect of the knee joint.

Segond¹ in 1879 was the earliest to demonstrate an avulsion fracture pattern at the anterolateral proximal tibia as a result of forced internal rotation of the knee. In 1948, Last² termed this structure the "short lateral ligament." Terry³ and LaPrade⁴ have called this structure as the "capsulo-osseous layer of the iliotibial band." LaPrade *et al.*⁴ called it the "mid-third lateral capsular ligament" and Campos *et al.*⁵ coined the term "lateral capsular ligament." The structure which

these authors are describing is the same, which is called the "anterolateral ligament of knee" (ALL).

Tear of the ALL leads to a pivot-shift phenomenon, which is an excessive anterior tibial translation and internal rotation laxity.^{6,7} However, this instability may also be caused by damage of other structures on the anterolateral aspect of knee demonstrated by Vincent *et al.*,⁸ Claes *et al.*,⁹ and Hughston *et al.*¹⁰

The aim of this study is to define the incidence and anatomical characteristics of the ALL of the knee in the Indian Population.

Materials and Methods

The qualitative and quantitative characteristic of the ALL were observed in 20 embalmed cadaveric specimens – 12 females (6 right and 6 left) and 8 males (4 right and 4 left). The specimens were obtained from the routine cadaveric

Address for correspondence:
Dr. Parikshat Gopal,
Army college of Medical Sciences, Delhi Cantt,
New Delhi - 110 018, India.
E-mail: docgopal@gmail.com

Access this article online

Website: www.ijoonline.com

DOI:
10.4103/ortho.IJOrtho_137_17

Quick Response Code:



How to cite this article: Rustagi SM, Gopal P, Ahuja MS, Arora NC, Sood N. The anterolateral ligament of the knee: Descriptive anatomy and clinical correlation. Indian J Orthop 2019;53:89-93.

This is an open access journal, and articles are distributed under the terms of the Creative Commons Attribution-NonCommercial-ShareAlike 4.0 License, which allows others to remix, tweak, and build upon the work non-commercially, as long as appropriate credit is given and the new creations are licensed under the identical terms.

For reprints contact: reprints@medknow.com

teaching of the first professional medical students. The mean age of cadavers was 80.2 years. Specimens with gross deformities and surgeries of the knee were excluded.

The dissection was performed in a standardized manner. A large rectangular area on the lateral aspect of the knee was demarcated. The skin and subcutaneous tissue were dissected. The iliotibial band (ITB), extensor apparatus and the short head of biceps were cleared of subcutaneous tissue. A tenotomy of the Quadriceps tendon was done at the myotendinous junction. The ITB was carefully separated from its tibial attachment at the Gerdy's tubercle. The retropatellar pad of fat in the region was removed. The lateral collateral ligament (LCL) and the surrounding biceps femoris tendon were isolated carefully. All soft-tissue structures were incised from the lateral condyle. The tendon of popliteus was identified and cleared.

After isolation, the capsular thickening characteristic and similar to ALL was observed. It could be well demarcated from the anterior joint capsule. The following measurements were made using a digital calipers (150 cm DC-60 western, Zhejiang, China)–ALL length in flexion, ALL length in extension, ALL width at the origin, ALL width at insertion, LCL length, and LCL width. The distance between the center of the ALL insertion and Gerdy's tubercle was also measured.

Results

The ALL was found as a distinct ligamentous structure in 19 specimens (95%) separate from the joint capsule on the anterolateral aspect of the knee. In one left knee specimen of a male, ALL was absent. In 19 of the 20 specimens, it was identified as a flat band taking origin from the lateral femoral epicondyle only anterior to the LCL, posterior to the insertion of popliteus tendon. At the origin, the posterior fibers of ALL were in continuity with the origin of the anterior fibers of LCL [Figure 1].

This band was observed to be running obliquely downward and forward to the anterolateral aspect of the proximal tibia [Figure 2]. The deeper fibers merged with the periphery of the lateral meniscus [Figure 3]. After separating the ALL from the rim of the meniscus, the lateral inferior geniculate artery and vein were seen in between the lateral meniscus and the ALL [Figure 4: Blue circle].

Distal to the attachment with the lateral meniscus the ALL seems to fan out and increase in width. The ligament is inserted into the anterolateral aspect of proximal tibia posterior to the Gerdy's tubercle [Figures 1-3]. The insertion of ITB on the Gerdy's tubercle was completely distinct with no connecting fibers to ALL.

ALL was found to tense between 30°–90° of knee flexion and forced internal rotation.

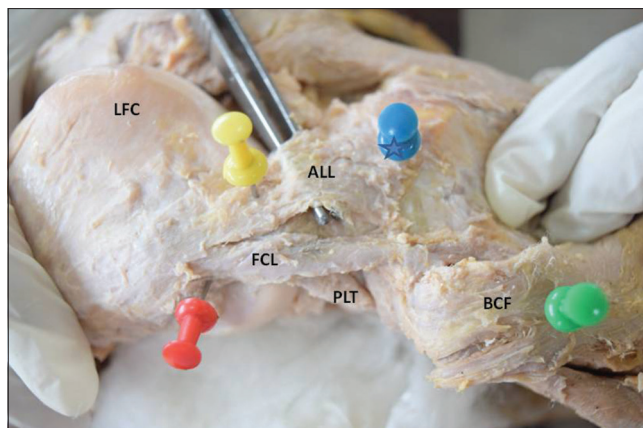


Figure 1: Right knee lateral aspect showing reflected Biceps femoris: BCF, Iliotibial tract: ITT, anterolateral ligament: ALL, Fibular collateral ligament: FCL, Tendon of popliteus: PLT Blue Star –Gerdy's tubercle

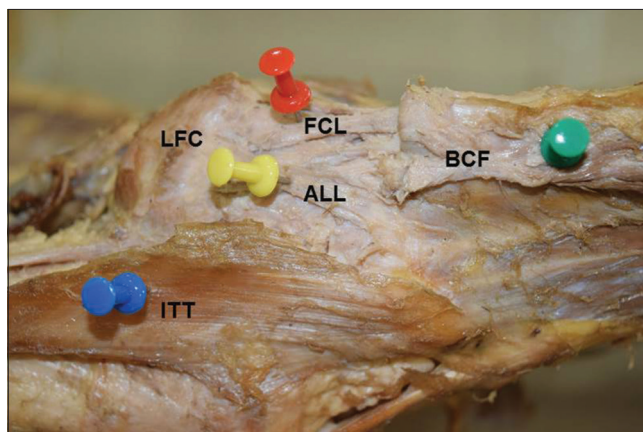


Figure 2: Left knee lateral aspect showing reflected Biceps femoris: BCF, Iliotibial tract: ITT, Anterolateral ligament: ALL, Fibular collateral ligament: FCL and Lateral femoral condyle: LFC

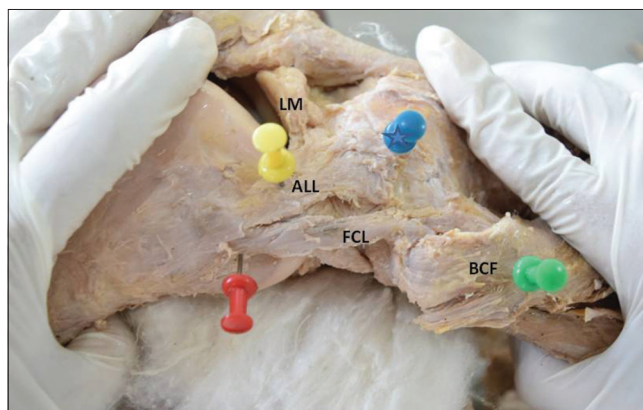


Figure 3: Right knee lateral aspect showing reflected Biceps femoris: BCF, Anterolateral ligament: ALL, Fibular collateral ligament: FCL Blue Star –Gerdy's tubercle, lateral meniscus lateral meniscus

The measurements in 19 cases the ALL was observed are mentioned in Table 1.

The mean length of the ALL was 43.35 mm ± 4.04 mm in flexion and 40.38 mm ± 4.35 mm in extension.

Table 1: Quantitative measurements of the anterolateral ligament, lateral collateral ligament, and distance from Gerdy's tubercle

Number	Sex	Left/right	ALL L (F)	ALL L (E)	ALL-W (o)	ALL width (i)	DIFG	LCL (L)	LCL (W)
1	Female	Right	42.1	36.22	6.13	9.16	16.38	59.54	6.23
2	Female	Left	41.5	36.40	5.90	8.92	16.47	59.16	6.19
3	Female	Left	43.35	48.27	8.92	12.24	23.61	52.53	5.80
4	Male	Right	45.35	41.36	7.95	9.46	23.55	59.75	6.27
5	Male	Left	47.23	45.62	7.58	9.37	22.16	61.58	6.83
6	Female	Right	39.55	36.49	7.29	9.44	21.23	62.36	7.15
7	Female	Left	41.22	38.63	8.11	10.34	20.33	63.41	7.64
8	Male	Right	43.64	39.29	8.73	10.02	18.38	64.72	7.92
9	Male	Left	40.28	38.10	6.27	8.49	17.45	65.91	6.87
10	Female	Right	38.39	35.87	5.68	7.20	20.72	60.50	6.07
11	Female	Left	37.61	34.90	6.44	9.58	23.15	55.39	6.17
12	Female	Right	51.47	47.88	7.39	9.14	19.73	62.19	7.48
13	Female	Left	39.67	36.29	6.17	8.47	21.24	64.86	6.77
14	Female	Right	39.42	37.40	6.33	8.43	23.66	63.47	6.29
15	Female	Left	43.49	41.37	6.81	9.31	24.11	64.16	6.72
16	Female	Right	44.28	42.48	6.38	9.29	23.39	65.62	6.83
17	Male	Right	48.90	40.38	7.14	10.46	24.67	71.72	7.17
18	Male	Left	50.48	47.35	7.23	10.29	25.19	72.16	7.29
19	Male	Right	45.78	42.93	6.23	8.16	22.17	61.40	6.82
Mean			43.35	40.38	6.98	9.36	21.45	62.65	6.76

ALL = Anterolateral ligament, LCL = Lateral collateral ligament, ALL-L (F) = Anterolateral ligament length in flexion, ALL-L (E) = Anterolateral ligament length in extension, ALL-W (o) = Anterolateral ligament width at origin, ALL-W (i) = Anterolateral ligament width at insertion, DIFG = Distance between center of ALL insertion and GT, LCL (L) = Lateral collateral ligament length, LCL-W = Lateral collateral ligament width at center, GT = Gerdy's tubercle

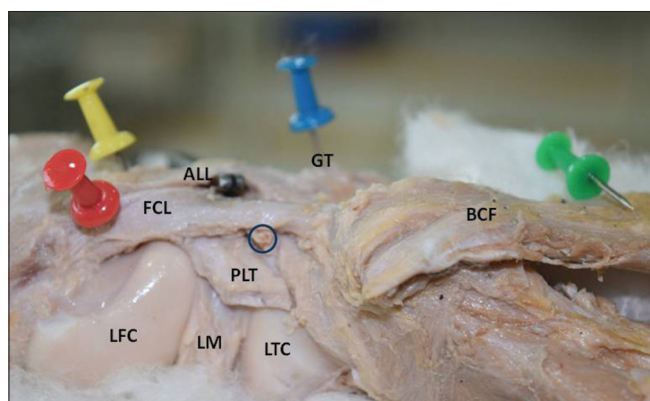


Figure 4: Right knee lateral aspect showing reflected Biceps femoris BCF, Iliotibial tract ITT, anterolateral ligament ALL, Fibular collateral ligament FCL, Lateral Meniscus LM, cut end popliteus tendon PLT, Lateral femoral condyle LFC, Lateral tibial condyle LTC, Gerdy's tubercle GT. Encircled: Lateral inferior genicular Artery and Vein

The mean width of the ALL at the origin was $6.98 \text{ mm} \pm 0.95 \text{ mm}$.

The mean width of the ALL at the insertion was $9.36 \text{ mm} \pm 1.07 \text{ mm}$.

The insertion of ALL was $21.45 \text{ mm} \pm 2.73 \text{ mm}$ posterior to Gerdy's tubercle.

The mean length of LCL was $62.65 \text{ mm} \pm 4.70 \text{ mm}$.

The mean breadth of LCL was $6.76 \text{ mm} \pm 0.58 \text{ mm}$.

Discussion

The purpose of this study was to observe the presence of a ligamentous structure in the knee region in the Indian population, describe its qualitative and quantitative characteristics and correlate clinically.

This ligament has been investigated as intraarticular reconstruction after ACL repair fails to restore normal rotation movements of the knee. Even serial sectioning studies fail to reproduce pivot phenomenon after sectioning both the bundles of ACL.¹¹ Even a well-done ACL reconstruction fails to stop the pivot phenomenon. This demonstrates the presence of another ligamentous factor which controls the pivot in the knee.

The ALL has been variably described as the anterior oblique band by Campos *et al.*⁵ or the lateral capsular ligament by Johnson.¹² Terry³ and LaPrade⁴ all have labeled it as the capsule-osseous layer of the iliotibial tract. We are in concurrence with the nomenclature by Vincent *et al.*⁸ and Claes *et al.*⁹ and call it the ALL of the knee.

In this study, the ALL was observed in 19 of the 20 specimens dissected (95%). The joint capsule was situated anterior to it. The ALL was easily demarcated from the surrounding joint capsule. It had similar length, breadth, and had comparable values to recent studies.^{8,9} However, Musahl *et al.*¹³ in their recent editorial have reported only a discrete capsular thickening in 30% of cases.

Similar to results of Claes *et al.*⁹ and Vincent *et al.*,⁸ the femoral attachment of the ALL on the lateral femoral epicondyle was anterior to and in line with the attachment of the LCL. This was in contrast to Dodds *et al.*¹⁴ who found ALL to arise 8 mm proximal and 4.2 mm posterior to lateral femoral epicondyle.

In our cadavers, distally the ligament appeared to widen and gain distal attachment close to the Gerdy's tubercle (the insertion of the ITB). The deeper and medial fibers of the ligament merged with the lateral meniscus. This observation is concurrent with the previous reports by Helito *et al.*¹⁵ Vincent *et al.*,⁸ and Claes *et al.*⁹ Claes *et al.* have named this part the meniscomfemoral part and distal to it the meniscotibial part of ALL.

The attachment of ALL to the lateral meniscus may have a role in the injuries of the lateral meniscus, especially peripheral tears. ALL may thus prevent anteroposterior translation and prevent extrusion of the meniscus during flexion. Terry³ and LaPrade⁴ documented a clear association of rupture of ALL with ACL injury.

ALL was found to get taut at between 30°–90° of knee flexion and forced internal rotation. This observation is in concurrence with Segond,¹ who described extreme amounts of tension during forced internal rotation. The bony avulsion of the ALL is often regarded as pathognomonic of ACL injuries. This bony avulsion of ALL could provide

a clue to role of ALL in rotatory knee instability patterns observed in many ACL deficient knees (i.e., pivot shift phenomenon).

Dodds *et al.*¹⁴ observed that the ALL crosses the middle of the LCL when the knee was flexed. Further similar to our observations they found that the ALL broadens out close to its tibial attachment.

The insertion of the ALL in Indians is similar to the observations by Claes *et al.*,⁹ Vincent *et al.*,⁸ Dodds *et al.*¹⁴ The tibial attachment of the ALL was constant and observed to be posterior to the Gerdy's tubercle. A summary of the measurements of ALL in our study in comparison to other authors has been done in Table 2.

The fibers of the ITB are a completely separate entity from the ALL, there being no anatomical continuity between the two.

Conclusion

The study demonstrates the existence of the ALL and defines its anatomical features and measurements in the Indian Population. Due to its attachments and tension observed in it during forced internal rotation it is hypothesized to play a role in maintaining the anterolateral stability of the knee. Further, the tear of the ALL may also be implicated in peripheral lateral meniscus tears.

Table 2: Summary of dimensions of anterolateral ligament in previous studies and our study

Authors	Number of specimens and incidence of ALL	ALL L (mm)	ALL W (mm)	ALL T (mm)	Tibial insertion
Vincent <i>et al.</i> ⁸	10 cadavers, 30 TKRs 100%	34.1±3.4	8.2±1.5	2-3	5 mm from articular margin posterior to GT
Claes <i>et al.</i> ⁹	41 cadavers, 97%	38.5±6.1 (extension) 41.5±6.7 (90° flexion)	8.3±2.1 (at origin) 6.7±3.0 (at the joint line) 11.2±2.5 (tibial insertion)	1.3±0.6 (at joint line)	6.5±1.4 mm from articular margin 21.6±4.0 mm posterior to GT 23.2±5.7 mm anterior to FH
Dodds <i>et al.</i> ¹⁴	40 cadavers, 83%	59±4	5±0		11±2 mm from joint line 18±3 mm from GT and 17±3 mm from FH
Helito <i>et al.</i> ¹⁵	20 cadavers, 100%	37.3±4.0	7.4±1.7	2.7±0.6	4.4±1.1 mm from distal articular margin
Caterine <i>et al.</i> ¹⁶	19 cadavers and 10 MRI, 100%	40.3±6.2	5.1±1.8 (above meniscus) 8.9±2.5 (below meniscus)	1.4±0.6	11.1±2.4 mm from joint line 23.4±3.4 mm from GT 23.9±5.5 mm from LCL insertion
Stijak <i>et al.</i> ¹⁷	14 cadavers 50%	41±3	4±1	1	Midway between the GT and the FH
Our study	20 cadavers, 95%	40.38±4.35 (extension) 43.35±4.04 (90° flexion)	6.98±0.95 (at origin) 9.36±1.07 (at insertion)		21.45±2.73 mm posterior to GT

ALL = Anterolateral ligament, ALL-L = Anterolateral ligament length, ALL-W = Anterolateral ligament width, ALL-T = Anterolateral ligament thickness, GT = Gerdy's tubercle, FH = Fibula head, DIFG = Distance between center of ALL insertion and GT, LCL = Lateral collateral ligament, MRI = Magnetic Resonance Imaging, TKRs = Total knee replacements

Financial support and sponsorship

Nil.

Conflicts of interest

There are no conflicts of interest.

References

1. Segond P. Clinical and experimental research of hemarthrosis in knee sprain. *Progre's Med* 1879;7:297-341
2. Last RJ. Some anatomical details of the knee joint. *J Bone Joint Surg Br* 1948;30B:683-8.
3. Terry GC, LaPrade RF. The posterolateral aspect of the knee. Anatomy and surgical approach. *Am J Sports Med* 1996;24:732-9.
4. LaPrade RF, Gilbert TJ, Bollom TS, Wentorf F, Chaljub G. The magnetic resonance imaging appearance of individual structures of the posterolateral knee. A prospective study of normal knees and knees with surgically verified grade III injuries. *Am J Sports Med* 2000;28:191-9.
5. Campos JC, Chung CB, Lektrakul N, Pedowitz R, Trudell D, Yu J, *et al.* Pathogenesis of the second fracture: Anatomic and MR imaging evidence of an iliotibial tract or anterior oblique band avulsion. *Radiology* 2001;219:381-6.
6. Galway RD, Beaupre A, MacIntosh DL. Pivot shift: A clinical sign of symptomatic anterior cruciate insufficiency. *J Bone Joint Surg Br* 1972;54B:763-4.
7. Bull AM, Andersen HN, Basso O, Targett J, Amis AA. Incidence and mechanism of the pivot shift. An *in vitro* study. *Clin Orthop Relat Res* 1999;363:219-31.
8. Vincent JP, Magnussen RA, Gezmez F, Uguen A, Jacobi M, Weppe F, *et al.* The anterolateral ligament of the human knee: An anatomic and histologic study. *Knee Surg Sports Traumatol Arthrosc* 2012;20:147-52.
9. Claes S, Vereecke E, Maes M, Victor J, Verdonk P, Bellemans J, *et al.* Anatomy of the anterolateral ligament of the knee. *J Anat* 2013;223:321-8.
10. Hughston JC, Andrews JR, Cross MJ, Moschi A. Classification of knee ligament instabilities. Part II. The lateral compartment. *J Bone Joint Surg Am* 1976;58:173-9.
11. Sonnery-Cottet B, Lutz C, Daggett M, Dalmay F, Freychet B, Niglis L, *et al.* The involvement of the anterolateral ligament in rotational control of the knee. *Am J Sports Med* 2016;44:1209-14.
12. Johnson LL. Lateral capsular ligament complex: Anatomical and surgical considerations. *Am J Sports Med* 1979;7:156-60.
13. Musahl V, Rahnama-Azar AA, van Eck CF, Guenther D, Fu FH. Anterolateral ligament of the knee, fact or fiction? *Knee Surg Sports Traumatol Arthrosc* 2016;24:2-3.
14. Dodds AL, Halewood C, Gupte CM, Williams A, Amis AA. The anterolateral ligament: Anatomy, length changes and association with the second fracture. *Bone Joint J* 2014;96-B: 325-31.
15. Helito CP, Demange MK, Bonadio MB, Tirico LE, Gobbi RG, Pécora JR, *et al.* Anatomy and histology of the knee anterolateral ligament. *Orthop J Sports Med* 2013 1;7:1-5.
16. Catherine S, Litchfield R, Johnson M, Chronik B, Getgood A. A cadaveric study of the anterolateral ligament: Re-introducing the lateral capsular ligament. *Knee Surg Sports Traumatol Arthrosc* 2015;23:3186-95.
17. Stijak L, Bumbaširević M, Radonjić V, Kadija M, Puškaš L, Milovanović D, *et al.* Anatomic description of the anterolateral ligament of the knee. *Knee Surg Sports Traumatol Arthrosc* 2016;24:2083-8.