

Accidental Pathological Findings in Asymptomatic Maxillary Sinuses in Patients Referred for Head and Neck Cone-Beam Computed Tomography: A Cross-sectional Study Analysis

Abstract

Background: The aim of the present study was to detect the prevalence of accidental pathological findings in asymptomatic maxillary sinuses in patients referred for head and neck cone-beam computed tomography (CBCT) examination for varied reasons. **Methods:** The present cross-sectional study included a detailed analysis of CBCT scans of 150 patients aged between 18 and 70 years reporting for varied dental complaints for detecting accidental pathological findings in maxillary sinuses while the patients did not have any complaint pertaining to sinuses. **Results:** The findings of the present study revealed 58% patients to have pathological findings in maxillary sinuses while they were asymptomatic for sinuses. Furthermore, the prevalence of mucosal thickening was found in 29.3% of the patients while 36.7% patients presented with polypoidal mucosal thickening. **Conclusion:** Higher prevalence of pathologies in asymptomatic maxillary sinuses found in the present study emphasized significance of a thorough examination of routine dental patients by dento-maxillofacial radiologists with necessary investigations to be advised in the form of higher imaging modalities like CBCT, if necessary.

Keywords: *Asymptomatic sinuses, cone-beam computed tomography, pathologic findings, prevalence*

Submitted: 08-Aug-2020

Revised: 09-May-2021

Accepted: 26-May-2021

Published: 12-May-2022

Introduction

The paranasal sinuses are four paired air filled cavities of craniofacial complex composed of maxillary, frontal, sphenoidal, and ethmoidal air cells.^[1] Among these, maxillary sinuses, also, called maxillary antra or, Antra of Highmore, are of clinical significance to dental professionals because of their close proximity to teeth and associated structures. In recent literature, increased risk of sinusitis has been reported due to trauma to teeth, complicated exodontias, teeth with pulpal and periodontal pathoses, extensive and persistent periapical abscesses and invasive implant therapy, especially, when the Schneiderian membrane is perforated. Consequently, diseases of maxillary sinuses may mimic odontogenic disease and conversely, odontogenic disease may spread to maxillary sinuses or, mimic sinus diseases. In this context,

close approximation of roots of teeth in maxillary posterior segments is referred to as draping of the maxillary sinuses.^[2] Complications of maxillary sinuses are related to their anatomic and pathologic variations.^[3] Pathologies of maxillary sinuses are usually categorized as intrinsic (originating primarily from within sinuses) and extrinsic (those that originate outside sinuses) diseases and include mucosal thickening, polypoidal mucosal thickening, partial opacification of sinuses, complete opacification and miscellaneous findings in the form of retention cysts, impacted teeth, root stumps, oro-antral fistulas, antraloliths, exostosis and a plethora of benign and malignant diseases and further abnormalities.^[4-6] It, thus, becomes important to study these sinuses even in situations when patients reporting for dental complaints are asymptomatic for the sinuses. Cone-beam computed tomography (CBCT) has emerged as

Ajay Chandran¹,
Manisha B. Patil²,
S. Nachiappan¹,
Pratyaksha
Singh Panwar³,
Anil Kumar
Nagarajappa⁴,
Deepak R. Kolte⁵,
J. Suresh Babu⁶,
C. Swarnalatha⁶,
Abhishek Singh
Nayyar⁷

¹Department of Oral and Maxillofacial Surgery, Sathyabama Dental College and Hospital, Chennai, Tamil Nadu,

²Department of Oral Pathology and Microbiology, Nanded Rural Dental College and Research Center, Nanded, ³Department of Oral and Maxillofacial Surgery, Bharati

Vidyapeeth (Deemed to be University) Dental College and Hospital, Navi Mumbai, ⁴Department of Oral Medicine and Radiology, Saraswati Dhanvantari Dental College and Hospital and Post-graduate Research Institute, Parbhani, Maharashtra,

⁵Department of Dentistry, Government Doon Medical College, Dehradun, Uttarakhand, India, ⁶Department of Oral and Maxillofacial Surgery and Diagnostic Sciences, College of Dentistry, Jouf University, Skaka, ⁷Division of Periodontology, Department of Preventive Dental Sciences, College of Dentistry, University of Ha'il, Ha'il, Kingdom of Saudi Arabia

Address for correspondence:
Dr. Pratyaksha Singh Panwar,
Department of Dentistry,
Government Doon Medical
College, Dehradun,
Uttarakhand, India.
E-mail: dr.pratyaksha@gmail.
com

Access this article online

Website: www.jmssjournal.net

DOI: 10.4103/jmss.jmss_96_21

Quick Response Code:



This is an open access journal, and articles are distributed under the terms of the Creative Commons Attribution-NonCommercial-ShareAlike 4.0 License, which allows others to remix, tweak, and build upon the work non-commercially, as long as appropriate credit is given and the new creations are licensed under the identical terms.

For reprints contact: WKHLRPMedknow_reprints@wolterskluwer.com

How to cite this article: Chandran A, Patil MB, Nachiappan S, Panwar PS, Nagarajappa AK, Kolte DR, *et al.* Accidental pathological findings in asymptomatic maxillary sinuses in patients referred for head and neck cone-beam computed tomography: A cross-sectional study analysis. *J Med Signals Sens* 2022;12:138-44.

the standard imaging modality for bone and soft-tissue abnormalities offering multiple views with thin sectioning. CBCT allows the clinicians to assess the relationship of dental pathologies with sinus abnormalities in patients who are asymptomatic for the sinuses by viewing the vicinity of teeth with sinus floor and resultant changes in the sinuses, if any. CBCT is, now-a-days, the imaging modality of choice for maxillofacial imaging for the diagnosis and treatment planning in relation to surgical removal of impacted teeth, visualizing canals and foramen, temporomandibular joints anatomy, facial asymmetry, placement of dental implants, orthodontic procedures, orthognathic surgeries and knowing anatomic detailing of airways, sinus pathologies and planning sinus lift procedures.^[7-11] The major advantages of CBCT include its low cost with significantly less radiation exposure than conventional computed tomography. CBCT is, thus, an integrated diagnostic and treatment planning modality to have an accurate assessment of possible risks and prognosis of treatment provided.^[12] Preoperative imaging of sinuses is highly important for the detection of variations and pathology related to maxillary sinuses.^[13-17] With advent of this convenient three-dimensional imaging, treatment plan can be modified and outcome of surgeries, especially, in relation to posterior maxilla can be predicted.^[18-21] The aim of the present study was to detect the prevalence of accidental pathological findings in asymptomatic maxillary sinuses in patients referred for head and neck CBCT examination for varied reasons.

Methods

The present cross-sectional study included a detailed analysis of CBCT scans of 150 patients aged between 18 and 70 years reporting for varied dental complaints for detecting accidental pathological findings in maxillary sinuses while the patients did not have any complaint pertaining to sinuses. All patients who fulfilled inclusion criteria and agreed to participate voluntarily with a written informed consent were considered for study while ethical clearance was obtained from Institutional Ethics Committee before the start of study via letter approval no. SDDC/IEC/02-38-2018. Out of a total of 150 patients, 73 patients were advised CBCT for planning of implant therapy (48.7%), 51 patients underwent CBCT analysis for prosthetic rehabilitations (34.0%), 16 patients underwent presurgical analysis with the help of CBCT (10.7%), 5 patients had orthodontic reasons (3.3%) while 5 patients had miscellaneous reasons for resorting to CBCT. A detailed case history of patients was taken including chief complaint, history of presenting illness, and medical and personal histories. A thorough clinical examination, including systemic and regional examination, was done. All patients were, then, referred for CBCT imaging with the help of i-CAT CBCT unit with Vision software (Imaging Sciences International). i-CAT is CBCT imaging unit which is an extended field of view model (Imaging Sciences International, Hatfield, PA, USA).

In the present study, the i-CAT CBCT unit was used while images were obtained at 120 kVp and 5 mA exposure parameters with a rotation time of 26.3 s by software addition of two different rotational scans using two different fields of view, covering the craniofacial complex and maxilla/mandible. While analyzing, images of patients with recent history of trauma, images with low resolution and those in which presence of metallic artifacts impaired sinus visualization were excluded while analysis of CBCT images for detecting pathological findings in asymptomatic sinuses was done by 3 general radiologists who were blinded for the particulars and data pertaining to patients. After recording the findings, the patients were referred to the concerned departments for seeking treatment as per their chief complaint.

Identification of intrinsic diseases of maxillary sinuses:^[4-6]

Mucosal thickening

Criteria used to detect mucosal thickening

Mucosal thickening was detected as noncorticated radiolucent bands, distinctly, more radiopaque than air filled sinuses paralleling bony walls of sinuses with sinus walls intact. Mucosal thickening of >3 mm seen on any wall of sinuses in all coronal, sagittal and axial views was considered pathologic. The thickness of mucosa was determined at maximum thickness from sinus wall using measurement tool provided in i-CAT Vision software. All measurements were made perpendicularly to underlying bone starting while thickest area was recorded [Figure 1].

Polypoidal mucosal thickening

Criteria for identification of polypoidal mucosal thickening

Presence of any dome shaped radiopacity with sinus walls intact in all coronal, sagittal and axial views was considered as polypoidal mucosal thickening. Polyps and retention cysts seen as smooth, outwardly convex soft tissue masses at imaging were, also, included as polypoidal mucosal thickening [Figure 2].

Partial opacification

Criteria for identification of partial opacification

Partial opacification resulting from accumulation of secretions appeared radiodense and occupied inferior aspect of sinuses. An air-fluid level was recognized when scans were evaluated in all coronal, sagittal and axial views. The border between radiodense fluid and relatively radiolucent air filled sinuses appeared horizontal and straight with a meniscus. The remaining walls of sinus appeared intact [Figure 3].

Complete opacification

Criteria for identification of complete opacification

Complete opacification of sinuses appeared as totally radiodense sinuses as seen in all coronal, axial and sagittal views with walls of sinus being intact [Figure 4].

Miscellaneous findings

These findings included retention cysts, impacted teeth, root stumps [Figure 5], oro-antral fistulas, antroliths and exostosis. Impacted teeth were diagnosed as unusual shapes or, sizes of teeth with difference in radiographic density of enamel, dentin and pulp located within the sinus walls. Root stumps were diagnosed by characteristic root morphology and anatomy showing root canals. Distinction between foreign body and antroliths was made based on the extent of density and consequent radiopacity seen on images while exostosis was diagnosed based on high-density structures or, radio-opacities on images.

Identification of extrinsic diseases of maxillary sinuses

Extrinsic disease of sinuses was identified as any lesion appearing to have their origin other than sinuses in form of a break in continuity of corticated walls of sinuses or, sinus floor or, extraneous pathologies infiltrating air space of sinuses.

Absence of pathologic findings

Maxillary sinuses showing no pathologic findings (intrinsic or, extrinsic diseases or, any other findings) were included in this group [Figure 6].

Statistical analysis used

The data was analyzed using SPSS version 15.0 (SPSS Inc., Chicago, IL, USA) while distribution of the overall prevalence of pathologic findings according to age and sex were calculated using Chi-square test. $P < 0.05$ was considered statistically significant.

Results

The age and sex distribution of the study sample in the present study is shown in Table 1. Out of a total of 150 patients, 73 patients were advised CBCT for planning of implant therapy (48.7%), 51 patients underwent CBCT analysis for prosthetic rehabilitations (34.0%), 16 patients underwent presurgical analysis with the help of CBCT (10.7%), 5 patients had orthodontic reasons (3.3%) while 5 patients had miscellaneous reasons for resorting

to CBCT. Pathologies of maxillary sinuses included intrinsic and extrinsic diseases such as mucosal thickening, polypoidal mucosal thickening, partial opacification, complete opacification and a plethora of other findings including retention cysts, impacted teeth, root stumps, oro-antral fistulas, antroliths and exostosis. Furthermore, right and left maxillary sinuses were evaluated differently for detection of pathologic findings wherein the findings of the present study revealed 58% patients to have pathologic findings in maxillary sinuses while they were asymptomatic for sinuses. Also, prevalence of mucosal thickening was found in 29.3% of patients while 36.7% patients presented

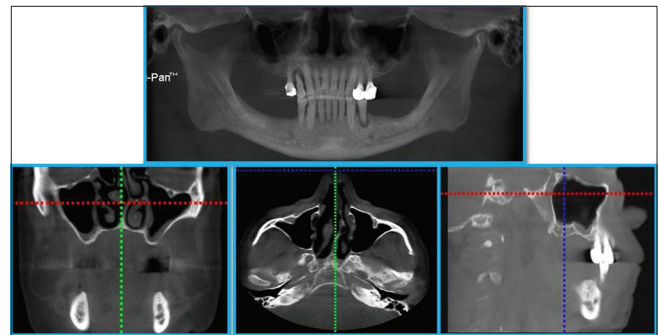


Figure 1: Orthopantomograph and cone beam computed tomography (CBCT: a-coronal view, b-axial view, c-sagittal view) image scan showing mucosal thickening of maxillary sinus

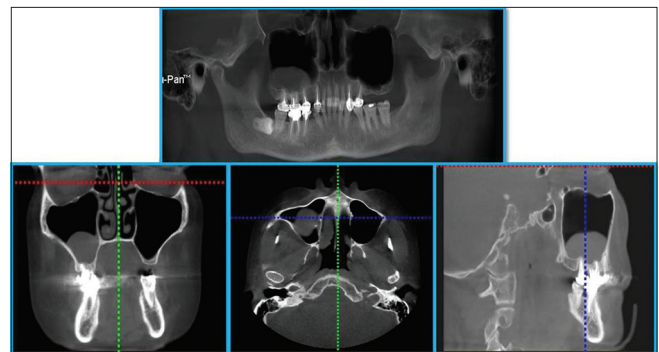


Figure 2: Orthopantomograph and cone beam computed tomography (CBCT: a-coronal view, b-axial view, c-sagittal view) image scan showing polypoidal mucosal thickening in maxillary sinus

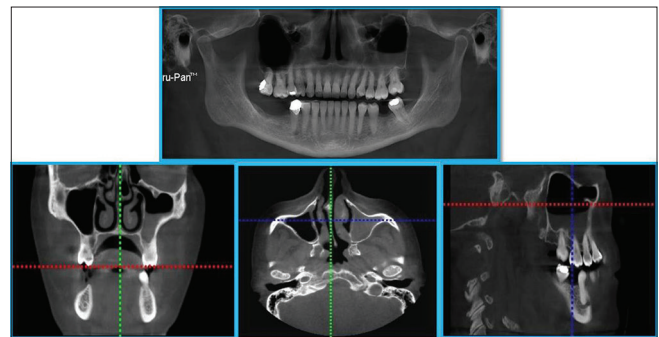


Figure 3: Orthopantomograph and cone beam computed tomography (CBCT: a-coronal view, b-axial view, c-sagittal view) image scan showing partial opacification of maxillary sinus

Table 1: Demographic profile of subjects studied

Variable	Number of subjects, n (%)
Age group (years)	
19-29	10 (6.7)
30-39	12 (8.0)
40-49	29 (19.3)
50-59	37 (24.7)
60-69	62 (41.3)
Sex	
Male	67 (44.7)
Female	83 (55.3)
Total	150 (100.0)

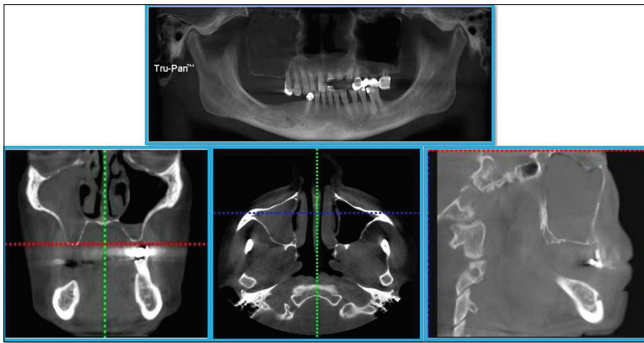


Figure 4: Orthopantomograph and cone beam computed tomography (CBCT: a-coronal view, b-axial view, c-sagittal view) image scan showing complete opacification of maxillary sinus

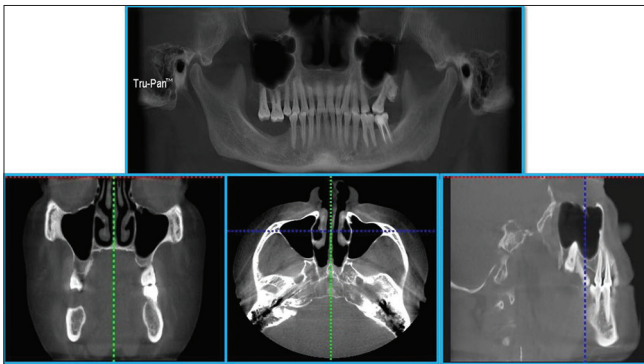


Figure 5: Orthopantomograph and cone beam computed tomography (CBCT: a-coronal view, b-axial view, c-sagittal view) image scan showing root stump in maxillary sinus

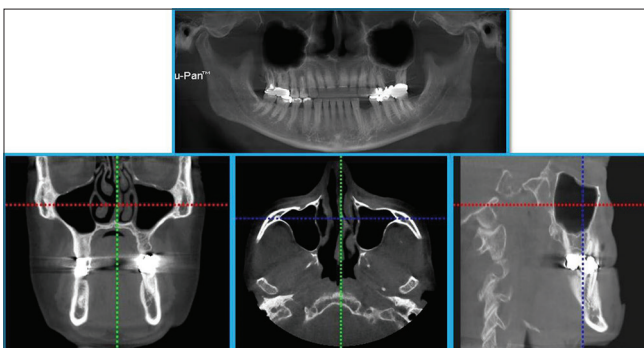


Figure 6: Orthopantomograph and cone beam computed tomography (CBCT: a-coronal view, b-axial view, c-sagittal view) image scan showing no pathologic finding in maxillary sinus

with polypoidal mucosal thickening, 2% with partial opacification of sinuses, 0.7% with complete opacification and miscellaneous findings in 0.7% of patients. Amongst these, 16% of patients revealed mucosal thickening in relation to right sinuses as against 20.7% patients who revealed mucosal thickening in relation to left sinuses. Similarly, 24% of patients revealed polypoidal mucosal thickening in relation to right and 20.7% in relation to left sinuses. Likewise, partial opacification was observed in 1.3% of left and 0.7% of right sinuses while complete opacification as well as miscellaneous findings were seen

only in 0.7% of right with zero prevalence in relation to left sinuses [Table 2]. Considering right and left maxillary sinuses, out of 150 patients, 58% of patients showed overall presence of pathologic findings as against 42% in whom no pathologic findings were observed [Table 3]. Also, another notable difference was noted in overall prevalence of pathologic findings in relation to sex wherein 65.7% of male patients revealed presence of pathologic findings as against female patients wherein prevalence was found to be 51.8%. On the contrary, 48.2% of female patients were pathology free as against 34.3% of male patients in whom no pathologic findings were observed [Table 4]. In relation to age, minimum number of patients who revealed pathologies was found in 19–29 years (30%) age group while highest prevalence was recorded in age group of 30–39 years (50%) [Table 5].

Discussion

Considering reasons for CBCT indication, maximum number of patients were advised CBCT for planning implant therapy (48.7%) similar to findings of studies conducted by Raghav *et al.*^[22] and Kihara *et al.*^[23] wherein implant therapy was the major reason for advising CBCT. Ritter *et al.*^[24] however, found trauma and implant treatment together as major reasons for indicating CBCT. Alamri *et al.*^[25] on the contrary, found presurgical analysis as major reason for advising CBCT followed by implant treatment and forensic dentistry purpose which was the least advised reason for CBCT.

The overall prevalence of accidental findings in the present study was 58% which was in accordance with study conducted by Kihara *et al.*^[23] which showed a similar prevalence of 58% in their study. The overall prevalence of accidental pathologic findings in the present study was, also, found to be in accordance with studies conducted by Raghav *et al.*^[22] showing 59.7% prevalence and Ritter *et al.*^[24] showing 56.3% prevalence. In other studies conducted by Vallo *et al.*^[26] an overall prevalence of 19%, Cha *et al.*^[27] 24.6% and Lim and Spanger,^[28] 27.5% prevalence was reported. The results of these studies have shown comparatively lower prevalence of pathologic findings than was seen in the present study. The variations in results obtained in the present study compared to these studies could be attributed to different populations addressed, variations in sample size, sample distribution and definition of abnormality considered in these studies. Rege *et al.*^[29] reported an overall prevalence of 68.2% which was quite large than the present study and other similar studies aforementioned which might be attributed to the fact that they had investigated a greater number of possible causes of alterations in maxillary sinuses including congenital and acquired lesions, bone related abnormalities and traumatic and iatrogenic lesions which were included in exclusion criteria in the present study.

The present study revealed polypoidal mucosal thickening as a major finding with a prevalence of 36.7% similar

Table 2: Distribution of pathologic findings in maxillary sinus

Presence/absence of pathologic findings	Number of subjects, n (%)		
	Right maxillary sinus	Left maxillary sinus	Overall findings
No pathologic findings	89 (59.3)	89 (59.3)	63 (42.0)
Mucosal thickening	24 (16.0)	31 (20.7)	44 (29.3)
Polypoidal mucosal thickening	36 (24.0)	31 (20.7)	55 (36.7)
Partial opacification	1 (0.7)	2 (1.3)	3 (2.0)
Complete opacification	1 (0.7)	0	1 (0.7)
Miscellaneous findings	1 (0.7)	0	1 (0.7)

Table 3: Distribution of overall prevalence of pathologic findings in maxillary sinus

Presence/absence of pathologic findings	Number of subjects, n (%)		
	Right maxillary sinus	Left maxillary sinus	Overall findings
Overall pathologic findings	61 (40.7)	61 (40.7)	87 (58.0)
No pathologic findings	89 (59.3)	89 (59.3)	63 (42.0)

$\chi^2=0.00, P=0.999$

Table 4: Distribution of overall prevalence of pathologic findings according to sex

Presence/absence of pathologic findings	Number of subjects, n (%)	
	Male	Female
Overall pathologic findings	44 (65.7)	43 (51.8)
No pathologic findings	23 (34.3)	40 (48.2)

$\chi^2=2.925, P=0.098$

to study conducted by Shiki *et al.*^[30] who reported a prevalence of 25% while contradictory results with lower prevalence were found in study conducted by Raghav *et al.*^[22] who reported 7.2% prevalence for polypoidal mucosal thickening in their study. A prevalence of 15% was reported in study conducted by Kihara *et al.*,^[23] 8% in study conducted by Lim and Spanger^[28] and 10.1% in study conducted by Rege *et al.*^[29] for polypoidal mucosal thickening. This variation in results might be due to different definitions of polypoidal mucosal thickening, different locations considered and different measurement criteria used in different studies.

In the present study, mucosal thickening was found to be the second most common finding with a reported prevalence of 29.3% in accordance with studies conducted by Raghav *et al.*^[22] who found 35.1% and Carmeli *et al.*^[31] who found 36.1% prevalence of mucosal thickening in their studies. The prevalence of mucosal thickening, though, was a little higher in studies conducted by Kihara *et al.*^[23] who found 43%, Shiki *et al.*^[30] who reported 49% and Dobelet *et al.*^[32] who found 48.5% prevalence of mucosal thickening in their studies, though, in all these studies, mucosal thickening was the second most common accidental finding reported. Contrary to findings of aforementioned studies, Vallo *et al.*^[26] found 12% and Lim and Spanger^[28] found 16.8% prevalence of mucosal thickening in their studies. Highest prevalence of mucosal thickening was found in study conducted by Rege *et al.*^[29] who reported 66% prevalence of mucosal thickening in their study. The huge variation

in overall prevalence of mucosal thickening in the present study compared to these studies might be due to differences in measurement criteria used in these studies.

In the present study, prevalence of partial opacification was found in 2% of patients which was in accordance with study conducted by Lim and Spanger^[28] who found a prevalence of 2.3% while contradictory to findings of study conducted by Shiki *et al.*^[30] who reported 0% prevalence of partial opacification in their study. The said variations might be due to difference in season or, climate during the period studies were conducted. Furthermore, complete opacification was the least found finding in the present study in accordance with studies conducted by Kihara *et al.*^[23] who found 2%, Lim and Spanger^[28] who found 2.7% and Dobelet *et al.*^[32] who found 2.9% prevalence of complete opacification in their studies. Rege *et al.*,^[29] though, found 7.8% prevalence of complete opacification in their study in accordance with studies conducted by Raghav *et al.*^[22] who found 16.6% and Shiki *et al.*^[30] who reported 18% prevalence of complete opacification in their studies. The said variations in these studies might be due to the differences in the geographic area of population and sample size studied and the criteria used to consider variations seen as pathology in these studies.

Similarly, the overall prevalence of miscellaneous findings, also, presented huge variations with an overall prevalence of 0.7% in the present study similar to studies conducted by Raghav *et al.*^[22] who reported 0.7% prevalence, Kihara *et al.*^[23] who reported 2% prevalence of foreign bodies and 13% prevalence of root protrusion into sinuses and Shiki *et al.*^[30] who reported 5% prevalence of antroliths in their studies. Furthermore, 42% of sinuses did not reveal any pathologic finding in the present study in close accordance to studies conducted by Raghav *et al.*^[22] wherein 40.2% and Ritter *et al.*^[24] wherein 43.7% of sinuses were found free from any signs of pathology while the prevalence of extrinsic diseases appeared to be 0% in the present study

Table 5: Distribution of overall prevalence of pathologic findings according to age groups

Age group (years)	Number of subjects with pathologic findings, <i>n</i> (%)	Percentage of subjects with no pathologic findings, <i>n</i> (%)
19-29	7 (70.0)	3 (30.0)
30-39	6 (50.0)	6 (50.0)
40-49	15 (51.7)	14 (48.3)
50-59	19 (51.4)	18 (48.6)
60-69	40 (64.5)	22 (35.5)
Total	87 (100.0)	63 (100.0)

$\chi^2=3.127, P=0.537$

as none of the patients' scans fulfilled criteria for extrinsic disease.

Vallo *et al.*^[26] showed a significant association between pathologic dental findings and mucosal thickening in maxillary sinuses while Maloney and Doku^[33] indicated that 10%–12% of the sinusitis cases had an odontogenic origin, however, direct comparison of other studies with the present study was inappropriate because of the different age distribution and geographic origin of sample and different imaging modalities and age and patient groups included because of which existing data varied among said studies and the present study. In addition to these, the definitions of pathological changes varied among the said studies and the present study and in some cases, were not adequately described for a clear distinction.

Conclusions and Future Research Directions

Higher prevalence of pathologies in asymptomatic maxillary sinuses found in the present study emphasized significance of a thorough examination of routine dental patients by dento-maxillofacial radiologists with necessary investigations to be advised in the form of higher imaging modalities like CBCT, if necessary. Furthermore, findings of the present study mandate need for a thorough interpretation of the whole volume scans acquired with different physical parameters of such advanced imaging modalities including radiation dose to ensure a proper differentiation of pathologic lesions from anatomic variations as it might have an impact on patient's medical status and prove of clinical relevance in planning treatment in such patients. The present study, also, highlighted clinical implications, dental pathologies might have, in relation to maxillary sinuses underlying the significance of their accurate assessment in the perspective of dental and maxillofacial and otorhinolaryngology-related problems with a multi-disciplinary approach of treatment for successful treatment outcomes.

Financial support and sponsorship

None.

Conflicts of interest

There are no conflicts of interest.

References

1. Van Cauwenberge P, Sys L, De Belder T, Watelet JB. Anatomy and physiology of the nose and the paranasal sinuses. *Immunol Allergy Clin North Am* 2004;24:1-17.
2. Kretzschmar DP, Kretzschmar JL. Rhinosinusitis: Review from a dental perspective. *Oral Surg Oral Med Oral Pathol Oral Radiol Endod* 2003;96:128-35.
3. Zijderveld SA, van den Bergh JP, Schulten EA, ten Bruggenkate CM. Anatomical and surgical findings and complications in 100 consecutive maxillary sinus floor elevation procedures. *J Oral Maxillofac Surg* 2008;66:1426-38.
4. White SC, Pharoah MJ. *Oral Radiology. Principles and Interpretation.* 5th ed. St Louis: Mosby; 2004. p. 586-94.
5. Mehra P, Murad H. Maxillary sinus disease of odontogenic origin. *Otolaryngol Clin North Am* 2004;37:347-64.
6. Leo G, Triulzi F, Incorvaia C. Diagnosis of chronic rhinosinusitis. *Pediatr Allergy Immunol* 2012;23 Suppl 22:20-6.
7. White SC. Cone-beam imaging in dentistry. *Health Phys* 2008;95:628-37.
8. Scarfe WC, Farman AG, Sukovic P. Clinical applications of cone-beam computed tomography in dental practice. *J Can Dent Assoc* 2006;72:75-80.
9. Dawood A, Patel S, Brown J. Cone beam CT in dental practice. *Br Dent J* 2009;207:23-8.
10. Tetradis S, Anstey P, Graff-Radford S. Cone beam computed tomography in the diagnosis of dental disease. *J Calif Dent Assoc* 2010;38:27-32.
11. Farman AG, Scarfe WC, van Genuchten M. Multidimensional imaging: Immediate and imminent issues. *Compend Contin Educ Dent* 2010;31:648-51.
12. De Vos W, Casselman J, Swennen GR. Cone-beam computerized tomography (CBCT) imaging of the oral and maxillofacial region: A systematic review of the literature. *Int J Oral Maxillofac Surg* 2009;38:609-25.
13. Yousem DM. Imaging of sinonasal inflammatory disease. *Radiol* 1993;188:303-14.
14. Okuyemi KS, Tsue TT. Radiologic imaging in the management of sinusitis. *Am Fam Physician* 2002;66:1882-6.
15. Mafee MF, Tran BH, Chapa AR. Imaging of rhino-sinusitis and its complications: Plain film, CT, and MRI. *Clin Rev Allergy Immunol* 2006;30:165-86.
16. Mafee MF. Imaging of paranasal sinuses and rhino-sinusitis. *Clin Allergy Immunol* 2007;20:185-226.
17. Huang BY, Senior BA, Castillo M. Current trends in sinonasal imaging. *Neuroimaging Clin N Am* 2015;25:507-25.
18. Kau CH, Bozic M, English J, Lee R, Bussa H, Ellis RK. Cone-beam computed tomography of the maxillofacial region – An update. *Int J Med Robot* 2009;5:366-80.
19. Geist JR. Cone-beam computed tomography: Strengths,

- weaknesses, and controversies. *J Mich Dent Assoc* 2011;93:48-62.
20. Miles DA. The future of dental and maxillofacial imaging. *Dent Clin North Am* 2008;52:917-28.
 21. Gaêta-Araujo H, Alzoubi T, Vasconcelos KF, Orhan K, Pauwels R, Casselman JW, *et al.* Cone beam computed tomography in dentomaxillofacial radiology: A two-decade overview. *Dentomaxillofac Radiol.* 2020;49:20200145. doi: 10.1259/dmfr.20200145.
 22. Raghav M, Karjodkar FR, Sontakke S, Sansare K. Prevalence of incidental maxillary sinus pathologies in dental patients on cone-beam computed tomographic images. *Contemp Clin Dent* 2014;5:361-5.
 23. Kihara E, Chindia M, Ocholla T, Parker M. Clinical significance of pathological and anatomical findings in cone beam CT scans of the maxillary sinus. *J Stomatol* 2014;4:285-90.
 24. Ritter L, Lutz J, Neugebauer J, Scheer M, Dreiseidler T, Zinser MJ, *et al.* Prevalence of pathologic findings in the maxillary sinus in cone-beam computerized tomography. *Oral Surg Oral Med Oral Pathol Oral Radiol Endod* 2011;111:634-40.
 25. Alamri HM, Sadrameli M, Alshalhoob MA, Sadrameli M, Alshehri MA. Applications of CBCT in dental practice: A review of the literature. *Gen Dent* 2012;60:390-400.
 26. Vallo J, Suominen-Taipale L, Huuonen S, Soikkonen K, Norblad A. Prevalence of mucosal abnormalities of the maxillary sinus and their relationship to dental disease in panoramic radiography: Results from the Health 2000 Health Examination Survey. *Oral Surg Oral Med Oral Pathol Oral Radiol Endod* 2010;109:e80-7.
 27. Cha JY, Mah J, Sinclair P. Incidental findings in the maxillofacial area with 3-dimensional cone-beam imaging. *Am J Orthod Dentofacial Orthop* 2007;132:7-14.
 28. Lim CG, Spanger M. Incidental maxillary sinus findings in patients referred for head and neck CT angiography. *Singapore Dent J* 2012;33:1-4.
 29. Rege IC, Sousa TO, Leles CR, Mendonça EF. Occurrence of maxillary sinus abnormalities detected by cone beam CT in asymptomatic patients. *BMC Oral Health* 2012;12:30.
 30. Shiki K, Tanaka T, Kito S, Wakasugi-Sato N, Matsumoto-Takeda S, Oda M, *et al.* The significance of cone beam computed tomography for the visualization of anatomical variations and lesions in the maxillary sinus for patients hoping to have dental implant-supported maxillary restorations in a private dental office in Japan. *Head Face Med* 2014;10:20.
 31. Carmeli G, Artzi Z, Kozlovsky A, Segev Y, Landsberg R. Antral computerized tomography pre-operative evaluation: Relationship between mucosal thickening and maxillary sinus function. *Clin Oral Implants Res* 2011;22:78-82.
 32. Dobele I, Kise L, Apse P, Kragis G, Bigestans A. Radiographic assessment of findings in the maxillary sinus using cone-beam computed tomography. *Stomatologija* 2013;15:119-22.
 33. Maloney PL, Doku HC. Maxillary sinusitis of odontogenic origin. *J Can Dent Assoc (Tor)* 1968;34:591-603.