

X-ray-free Ultrasound-guided Percutaneous Nephrolithotomy in Supine Position Using Alken Metal Telescoping Dilators in a Large Kidney Stone: A Case Report

This article was published in the following Dove Press journal:
Research and Reports in Urology

Ponco Birowo 
Putu Angga Risky Raharja 
Harun Wijanarko Kusuma Putra 
Reginald Rustandi
Widi Atmoko 
Nur Rasyid 

Department of Urology, Faculty of
Medicine, Universitas Indonesia, Cipto
Mangunkusumo Hospital, Jakarta 10430,
Indonesia

→ Video abstract



Point your Smartphone at the code above. If you have a QR
code reader the video abstract will appear. Or use:
<https://youtu.be/n-N4oxLXD-4>

Abstract: X-ray-free ultrasound-guided percutaneous nephrolithotomy (PCNL) has been proven to be safe, feasible, and affordable. Kidney dilatation during X-ray-free ultrasound-guided PCNL is mostly using balloon dilators. This report presents our experience of performing X-ray-free ultrasound-guided PCNL in supine position using Alken metal telescopic dilators in a patient with a large kidney stone. A 50-year-old male presented with right complete staghorn stone sized 46×30×24 mm (stone burden: 50,985 mm³ with sphere formula) and grade II hydronephrosis. The computed tomography (CT) scan showed no right ureteric stone, kinking, or stenosis. Ureteral catheter and guidewire were placed retrogradely under ultrasound guidance during cystoscopy. Normal saline was pumped via the ureteral catheter to make artificial hydronephrosis thus assisting the process. Kidney dilatation was performed with Alken metal telescoping dilators. Urine flow from the dilators confirmed that our dilator had reached the collecting system. The stone was identified and fragmented with combination of both pneumatic and shock pulse lithotripter. Double J stent and nephrostomy tubes were inserted at the end of the procedure. All of the steps were performed purely under ultrasound guidance. There was no residual stone after the procedure, confirmed by ultrasound, nephroscope, and postoperative X-ray. There was no significant complication during or after the procedure. The patient was discharged on postoperative day two. X-ray-free ultrasound-guided PCNL in supine position using Alken metal telescoping dilators seems to be a feasible, safe, and cost-effective approach in managing kidney stones, including staghorn and large stones.

Keywords: kidney stone, PCNL, supine position, ultrasound-guided, X-ray-free

Introduction

Percutaneous nephrolithotomy (PCNL) is currently accepted as the gold-standard procedure for most patients with staghorn and large kidney stones more than 20 mm.^{1,2} Fluoroscopy use during PCNL increases the ionizing radiation hazards.³ Although it is known for harmful X-ray radiation exposure to patients and urologist, fluoroscopy is still widely used for PCNL guidance.^{4,5} Currently, ultrasound emerged as a promising alternative to fluoroscopy in many countries.⁶ X-ray-free ultrasound-guided PCNL has been proven to be safe, feasible, and more affordable.^{4,7,8}

Traditional prone position for PCNL is associated with several disadvantages, such as anaesthetic, surgical, or logistical problems.⁹ Therefore, supine position has gained more popularity due to shorter operating time and less frequent circulatory

Correspondence: Ponco Birowo
Department of Urology, Faculty of
Medicine, University of Indonesia, Cipto
Mangunkusumo Hospital, Jalan
Diponegoro No. 71, Jakarta 10430,
Indonesia
Tel +62 213923631
Fax +62 81 21 3145592
Email ponco.birowo@gmail.com

or ventilatory complications.^{10,11} Although supine position had lower rate of complication, a meta-analysis found that supine position had a lower stone-free rate.¹¹

During PCNL, kidney puncture and tract dilatation with access sheath insertion are the most important steps.¹² Currently, there are three commonly used methods for kidney dilatation; sequential fascial dilators (Amplatz), one-step balloon dilatation, and metal telescoping dilators (Alken).¹² Metal telescopic dilators are more economical due to their reusable properties.¹² Metal telescopic dilators also sustain a tamponade effect during the kidney dilatation.¹² However, X-ray-free ultrasound-guided PCNL are mostly using balloon dilators. To our knowledge, Alken metal telescoping dilators are never reported by other centers to be used for dilatation during supine X-ray-free ultrasound-guided PCNL. However, we have performed this technique for neglected double J (DJ) stent case.¹³ The aim of this report is to present our experience of performing X-ray-free ultrasound-guided PCNL in supine position using Alken metal telescopic dilators in a patient with a large kidney stone.

Case Presentation

A 50-year-old male visited the outpatient urology clinic with chief complaint of worsening bilateral flank pain during the last three months. The pain was dull and not radiating. There was history of passing stones. The patient also had history of hypertension and type 2 diabetes mellitus, currently controlled with oral medication. Physical examination did not reveal any pathology. Laboratory examination showed increased creatinine level of 3.4 mg/dL. Noncontrast computerized tomography (CT) scan revealed right complete staghorn stone sized 46x30x24 mm (stone burden: 50,985 mm³ with sphere formula)¹⁴ with grade II hydronephrosis and left proximal

ureteral stone sized 31x16x13 mm with grade IV hydronephrosis (Figure 1). Left nephrostomy was then performed. However the daily production of nephrostomy was minimal. Renogram showed diminished function of left kidney with glomerular filtration rate (GFR) of 3.95 mL/minute and split function of 11.2%. We elected to perform right PCNL first and left laparoscopic nephrectomy in another setting (not discussed) for this patient. One gram of intravenous cefoperazone was given as prophylactic antibiotic before the PCNL procedure.

Evaluation of the Ureter from the CT Scan

Before the procedure, we made thorough evaluation of the ureter from the CT scan. We made sure that there was no ureteric stone, kinking, or stenosis in the right side (Figure 2). Insertion of guidewire and ureteral catheter with cystoscopy under ultrasound guidance was then planned. If there was any abnormality in the ureter, the insertion of guidewire and ureteral catheter can be performed under ureteroscopy guidance to avoid fluoroscopy usage.

Placement of Guidewire and Ureteral Catheter

The patient was placed in a modified-lithotomy position with maximal abduction of the right leg (Figure 3). A custom-built cushions were placed on the right flank and leg to make the flank approximately 15 degrees relative to the operating table. A (5 Fr/70 cm) open-end ureteral catheter was inserted into the right ureteral orifice during cystoscopy (22.5 Fr/70° lens). We confirmed that ureteral catheter had reached the collecting system in three ways. First, appearance of ureteral catheter in ultrasound images during insertion (Figure 4A). Second, there was flow of

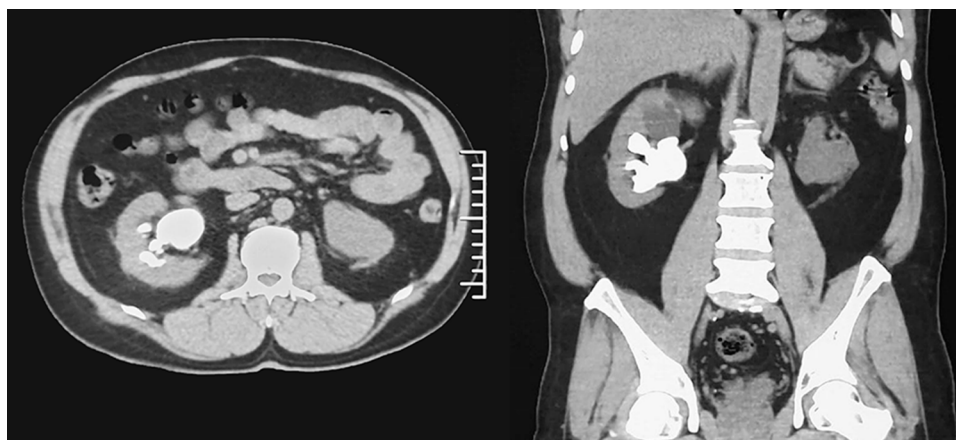


Figure 1 CT scan showed right complete staghorn stone with left proximal ureteral stone.

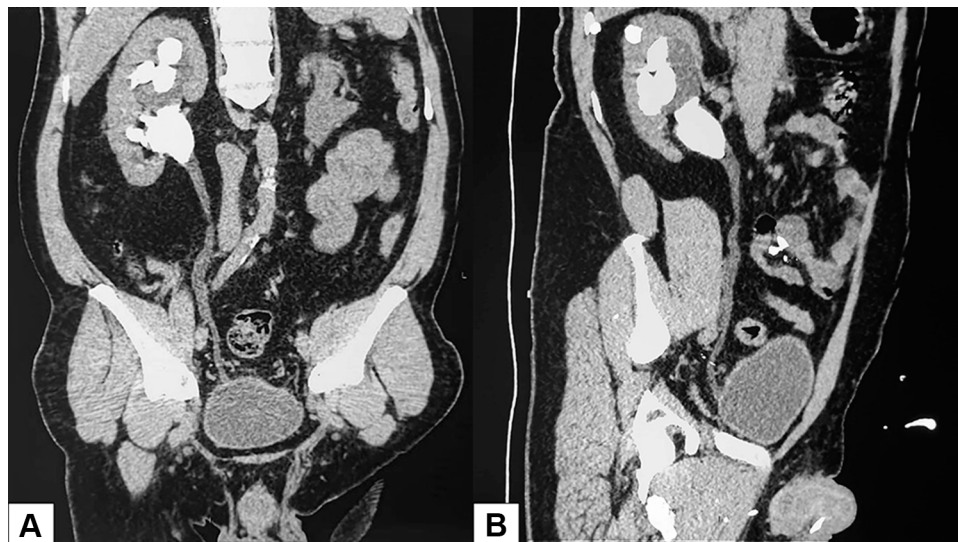

Figure 2 Coronal (A) and sagittal (B) plane view of the right ureter reconstruction showed no ureteric stone, kinking, or stenosis.

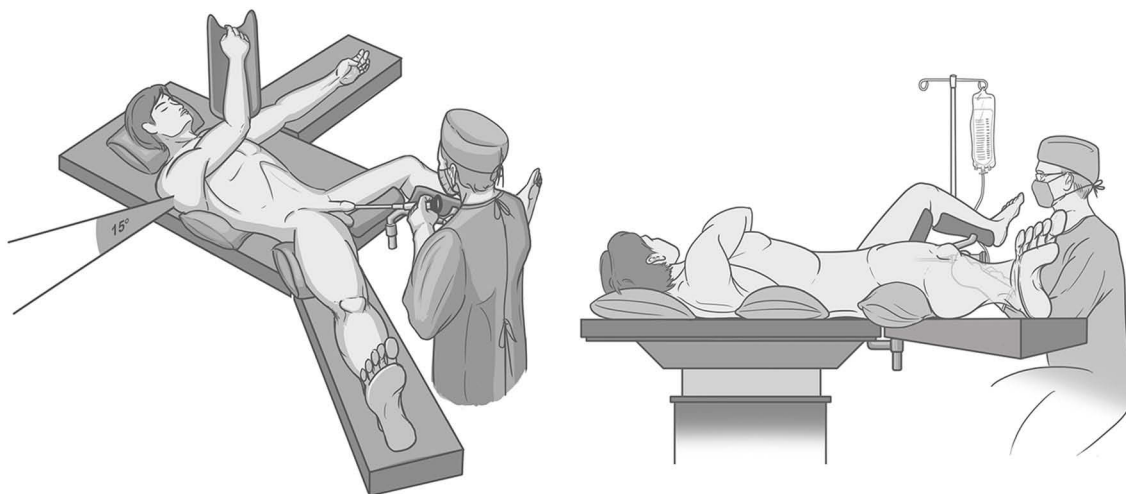


Figure 3 The patient was placed in modified-lithotomy position. The left leg was in lithotomy position, while the right leg was abducted as laterally as possible.

urine from the ureteral catheter. Third, there was water-jet appearance on the ultrasound when normal saline was flushed from the ureteral catheter (Figure 4B). We also inserted second guidewire (zebra nitinol guidewire, 3 cm angled-tip, size 0.035 in x 150 cm) to the right collecting system after placement of the ureteral catheter also with ultrasound guidance.

Ultrasound-guided Kidney Puncture

After the cystoscopy procedure, the right leg was moved back medially to avoid disturbance of puncture site and limitation of nephroscope movement (Figure 5). Important landmarks, such as the iliac crest, anterior and posterior axillary line, the eleventh and twelfth ribs were marked. During kidney puncture, normal saline was pumped into the collecting system via the previously

inserted ureteral catheter to make artificial hydronephrosis thus assisting the process. The ultrasound probe (BK medical falcon 2101 EXL ultrasound machine) was placed on the right mid-axillary line, parallel to the eleventh rib to identify the right kidney and its surrounding structures. The ultrasound probe was swept back and forth to visualize the important structures, such as cortex, collecting system, stone, and target calyx. The measured skin-to-stone distances were 60.7 mm. It was used to estimate the depth during kidney puncture and tract dilatation. A 20-cm puncture needle (1.3 mm/17.5 G) was used during kidney puncture under ultrasound control. The right inferior-posterior calyx was targeted. Some adjustments of the needle were performed to identify the needle tip eventually reaching the intended calyx (Figure 6). The kidney access time (time

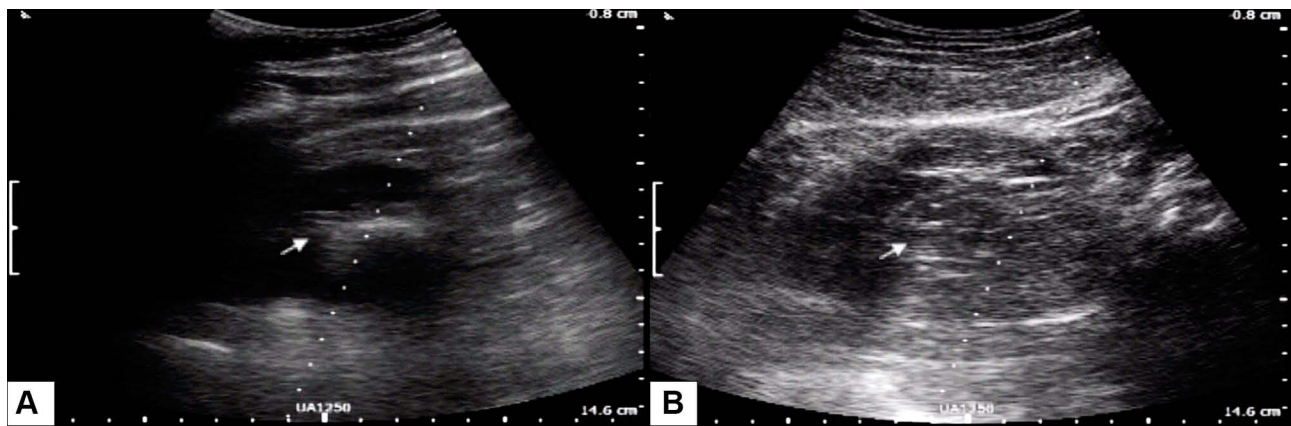


Figure 4 (A) Appearance of ureteral catheter (arrow) in collecting system during insertion; (B) Water jet appearance (arrow) when normal saline was flushed from the ureteral catheter.

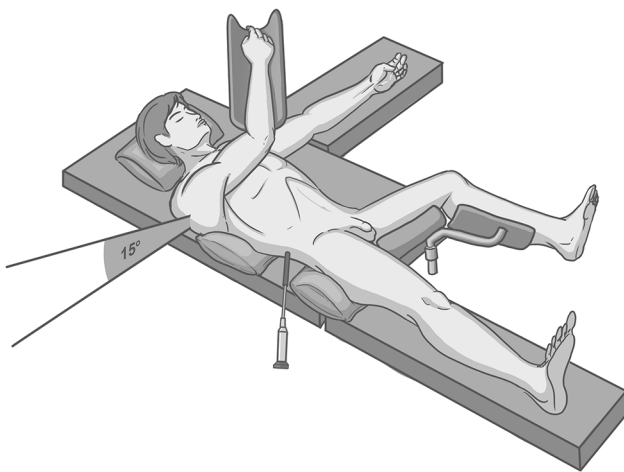


Figure 5 During puncture and stone fragmentation, the right leg was returned to the center to avoid disturbance of puncture site and limitation of nephroscope movement.

from initial kidney ultrasound imaging to successful puncture) were 2.6 minutes. Kidney puncture was attempted twice because the first attempt was unsuccessful. Successful puncture was confirmed with urine flow from the puncture needle.

Ultrasound-guided Tract Dilatation with Alken Metal Telescoping Dilators

Guidewire (0.035-inch J-shaped stiff guidewire) was advanced through the puncture needle under ultrasound guidance. The puncture needle was then removed. Additional 1 cm transverse incision was performed to allow insertion of 30 Fr Amplatz sheath. Fascial dilatation was performed with 8 Fr, 10 Fr, and 12 Fr fascial dilator under ultrasound guidance. Kidney dilatation was performed with Alken metal telescoping dilators (6 Fr x 30 Fr) under ultrasound guidance. The Alken metal telescoping dilators had reusable properties thus

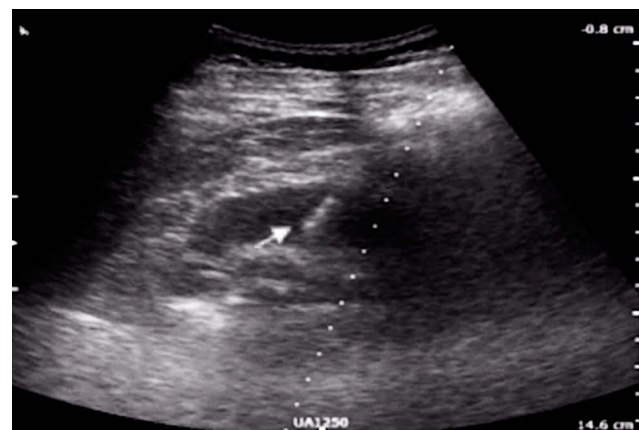

Figure 6 Ultrasound showed the tip of puncture needle (arrow) had reached the target calyx.

more cost-effective for PCNL procedure in our center. Urine flow from the metal telescoping dilators confirmed that our dilator had reached the right collecting system. A 30 Fr/17 cm Amplatz sheath was placed under ultrasound guidance. The total tract dilatation times (time from insertion of the guidewire to advancement of the Amplatz sheath) were 3.7 minutes.

Stone Fragmentation and Evacuation

The 30 Fr rigid nephroscope was used during our PCNL procedure. The stone was identified and then fragmented with combination of 3.4 Fr pneumatic and 3.78 Fr shock pulse lithotripters. Previously inserted guidewire during cystoscopy was identified and taken out with forceps for safety reason. Normal saline that was pumped from the ureteral catheter prevented the migration of stone fragments into the ureter and increased the collecting system visualization (Figure 7). The

stone fragments were evacuated with stone forceps. During this procedure, there was no residual stone, confirmed with both ultrasound and nephroscope (Figure 8).

Placement of DJ Stent and Nephrostomy Tube

There was infundibular laceration noted during this procedure. We decided to insert 6 Fr DJ stent and 8 Fr nephrostomy tube antegradely. The DJ stent was inserted with guidewire guidance under direct visualization with nephroscope. Ultrasound confirmed the position of distal-coil of DJ stent in the bladder. The

nephrostomy tube was inserted with guidewire guidance and confirmed by using ultrasound.

The total surgery time was 175 minutes. Blood loss during the procedure was 500 mL and the patient had packed red cell transfusion of 252 mL after the procedure. Evacuated stone fragments were shown in Figure 9A. Aside from blood transfusion, there was no other significant complication during and after the procedure. Postoperative creatinine level was 3.7 mg/dL. Postoperative kidney ureter bladder (KUB) photo showed no residual stone on the right kidney (Figure 9B). The nephrostomy tube was removed on postoperative day two. The patient was also discharged on postoperative day two.

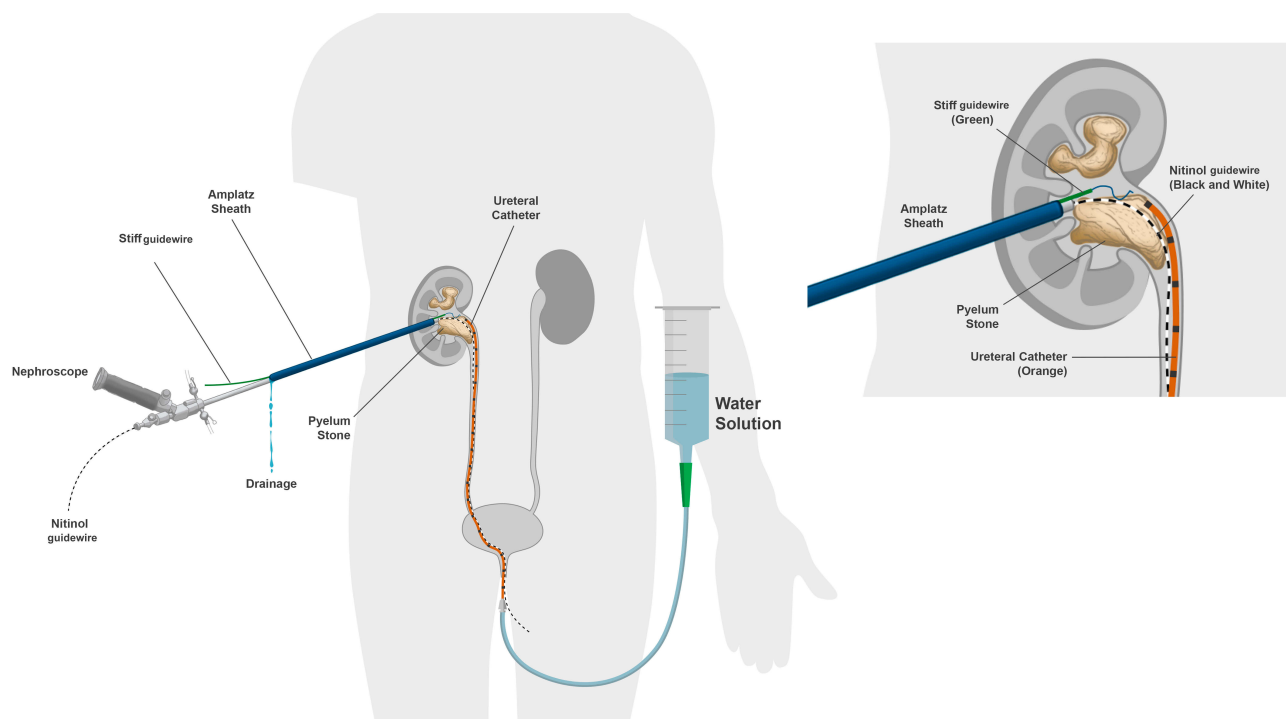


Figure 7 Irrigation solution that were pumped via the ureteral catheter increased the collecting system visualization and prevented stone fragments migration.

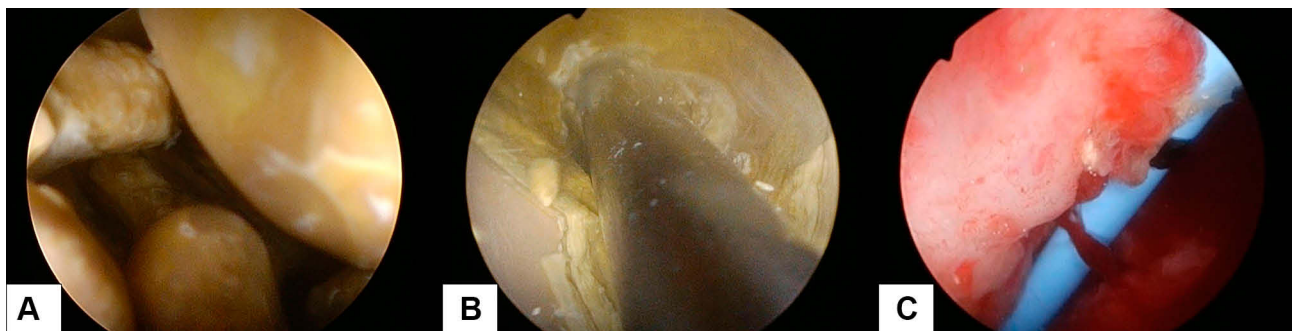


Figure 8 The stone was visualized with 30 Fr rigid nephroscope (A) and fragmented with combination of pneumatic and shock pulse lithotrippers (B). There was no residual stone after the PCNL procedure (C).

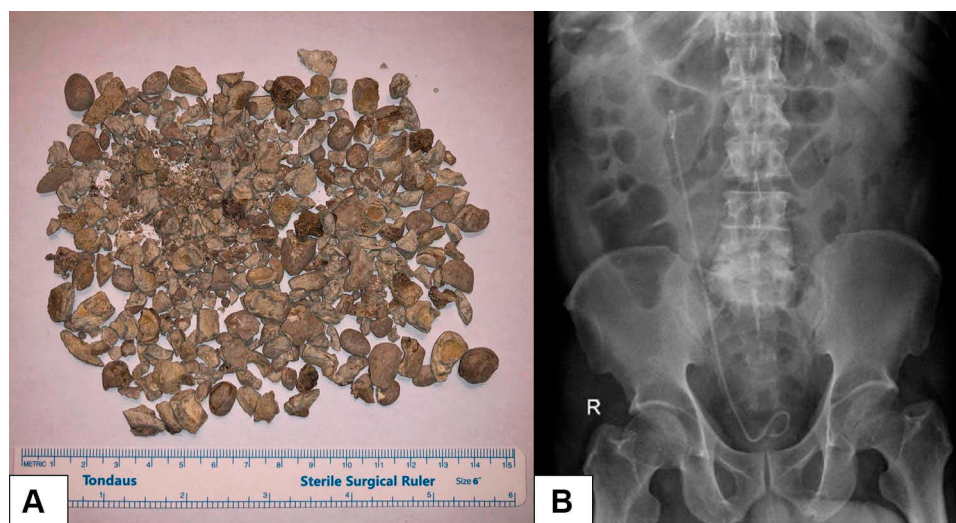


Figure 9 (A) Evacuated stone fragments during the procedure; (B) Postoperative KUB photo showed no residual stone in the right kidney with correctly positioned DJ stent.

Discussion

Approximately 86.3% of PCNL cases worldwide were performed under fluoroscopy control, as reported by the CROES (Clinical Research Office of the Endourological Society) Global PCNL study.¹⁵ However, fluoroscopy use in the PCNL will increase the hazards of radiation exposure to the patient.³ This paper would like to showcase that X-ray-free ultrasound-guided PCNL is a feasible alternative method. In our experience, we had successfully performed an X-ray-free ultrasound-guided PCNL in a patient with complete right staghorn stone using Alken metal telescoping dilators. Use of these dilators was never reported before in an X-ray-free ultrasound-guided PCNL. There was no residual stone after the PCNL procedure. A meta-analysis found a nearly identical stone-free rate between the ultrasound-guided and fluoroscopy-guided PCNL (77.3% and 78%, respectively).⁷

In our case, there was no significant complication during or after the procedure. However, the patient needed to have packed red cell transfusion of 252 mL after the procedure. Similar to what we have reported in this case, several studies found no significant difference of complication between ultrasound-guided and fluoroscopy-guided PCNL.^{16–19} Moreover, meta-analysis by Yang et al, even showed that ultrasound-guided PCNL had a significantly lower complication rate.⁷ Our result and current evidence showed positive remarks of safety in performing X-ray-free ultrasound-guided PCNL.

We performed the PCNL procedure in supine position for this case because it has lower complication rate compared to prone position.^{10,11} Although meta-analysis found

that supine position had lower stone free rate when compared to prone position,⁹ our result showed that stone-free status was attainable with supine position, even in the large complete staghorn stone case. The clinical judgment to determine the suitable position during X-ray-free ultrasound-guided PCNL should be based on each patient's profile and experience of the operating surgeon.

During PCNL procedure, both kidney puncture and tract dilatation are the important steps. Tract dilatation can be performed with several methods.^{12,20} However, X-ray-free ultrasound-guided PCNLs are mostly using balloon dilators for tract dilatation. In our experiences, we used Alken metallic telescopic dilators. These dilators are reusable and can sustain a tamponade effect throughout the dilatation process. Due to their reusable-properties, metal telescopic dilators are subjectively more cost-effective.⁹ Although all of the dilatation methods are usually safe, meta-analysis by Dehong et al found that metal telescopic dilators are associated with higher blood loss.²⁰ In this case, the blood loss was 500 mL and the patient needed a blood transfusion after the PCNL procedure. However, this also can be caused by a variety of factors, especially the high stone burden in this case.

Conclusions

As reported, the X-ray-free ultrasound-guided PCNL in supine position using Alken metal telescoping dilators for large kidney stone had shown quite good results. This could be a good alternative for urological centers with no access to fluoroscopy.

Acknowledgment

Written informed consents for publication of clinical details and any accompanying images were obtained from the patient. The Ethics Committee of the Faculty of Medicine, Universitas Indonesia also had approved the study protocol (approval number: KET-442/UN2/F1/ETIK/PPM.00.02/2020).

Funding

This study was supported and financed by International Publication Grant Research of Universitas Indonesia (NKB-1599/UN2.RST/HKP.05.00/2020).

Disclosure

The authors report no conflicts of interest in this work.

References

- Assimos D, Krambeck A, Miller NL, et al. Surgical management of stones: American Urological Association/endourological society guideline, PART I. *J Urol.* 2016;196(4):1153–1160. doi:10.1016/j.juro.2016.05.090
- Turk C, Petrik A, Sarica K, et al. EAU guidelines on interventional treatment for urolithiasis. *Eur Urol.* 2016;69(3):475–482. doi:10.1016/j.eururo.2015.07.041
- Chen TT, Wang C, Ferrandino MN, et al. Radiation exposure during the evaluation and management of nephrolithiasis. *J Urol.* 2015;194(4):878–885. doi:10.1016/j.juro.2015.04.118
- Ng FC, Yam WL, Lim TYB, Teo JK, Ng KK, Lim SK. Ultrasound-guided percutaneous nephrolithotomy: advantages and limitations. *Investig Clin Urol.* 2017;58(5):346–352. doi:10.4111/icu.2017.58.5.346
- Falahatkar S, Neiroomand H, Enshaei A, Kazemzadeh M, Allahkhah A, Jalili MF. Totally ultrasound versus fluoroscopically guided complete supine percutaneous nephrolithotripsy: a first report. *J Endourol.* 2010;24(9):1421–1426. doi:10.1089/end.2009.0407
- Beiko D, Razvi H, Bhojani N, et al. Techniques - ultrasound-guided percutaneous nephrolithotomy: how we do it. *Can Urol Assoc J.* 2020;14(3). doi:10.5489/cuaj.6076
- Yang YH, Wen YC, Chen KC, Chen C. Ultrasound-guided versus fluoroscopy-guided percutaneous nephrolithotomy: a systematic review and meta-analysis. *World J Urol.* 2019;37(5):777–788. doi:10.1007/s00345-018-2443-z
- Hudnall M, Usawachintachit M, Metzler I, et al. Ultrasound guidance reduces percutaneous nephrolithotomy cost compared to fluoroscopy. *Urology.* 2017;103:52–58. doi:10.1016/j.urology.2016.12.030
- Jones MN, Ranasinghe W, Cetti R, et al. Modified supine versus prone percutaneous nephrolithotomy: surgical outcomes from a tertiary teaching hospital. *Investig Clin Urol.* 2016;57(4):268–273. doi:10.4111/icu.2016.57.4.268
- Basiri A, Sichani MM, Hosseini SR, et al. X-ray-free percutaneous nephrolithotomy in supine position with ultrasound guidance. *World J Urol.* 2010;28(2):239–244. doi:10.1007/s00345-009-0451-8
- Birowo P, Tendi W, Widyahening IS, Rasyid N, Atmoko W. Supine versus prone position in percutaneous nephrolithotomy: a systematic review and meta-analysis. *F1000Research.* 2020;9:231. doi:10.12688/f1000research.22940.1
- Nour HH, Kamal AM, Zayed AS, Refaat H, Badawy MH, El-Leithy TR. Single-step renal dilatation in percutaneous nephrolithotomy: a prospective randomised study. *Arab J Urol.* 2014;12(3):219–222. doi:10.1016/j.aju.2014.06.001
- Birowo P, Rasyid N. The use of alken metal telescopic dilator for ‘X-ray-free’ PCNL in neglected DJ stent patient: a case report. *Urol Case Rep.* 2020;33:101239. doi:10.1016/j.eucr.2020.101239
- Merigot De Treigny O, Bou Nasr E, Almont T, et al. The cumulated stone diameter: a limited tool for stone burden estimation. *Urology.* 2015;86(3):477–481. doi:10.1016/j.urology.2015.06.018
- Andonian S, Scoffone CM, Louie MK, et al. Does imaging modality used for percutaneous renal access make a difference? A matched case analysis. *J Endourol.* 2013;27(1):24–28. doi:10.1089/end.2012.0347
- Sun W, Liu M, Yang Z, Wang Q, Xu Y. Ultrasound-guided percutaneous nephrolithotomy for the treatment in patients with kidney stones. *Medicine.* 2017;51(August).
- Agarwal M, Agrawal MS, Jaiswal A, Kumar D, Yadav H, Lavania P. Safety and efficacy of ultrasonography as an adjunct to fluoroscopy for renal access in percutaneous nephrolithotomy (PCNL). *BJU Int.* 2011;108(8):1346–1349. doi:10.1111/j.1464-410X.2010.10002.x
- Basiri A, Ziaee AM, Kianian HR, Mehrabi S, Karami H, Moghaddam SMH. Ultrasonographic versus fluoroscopic access for percutaneous nephrolithotomy: a randomized clinical trial. *J Endourol.* 2008;22(2):281–284. doi:10.1089/end.2007.0141
- Falahatkar S, Allahkhah A, Kazemzadeh M, Enshaei A, Shakiba M, Moghaddas F. Complete supine PCNL: ultrasound vs. fluoroscopic guided: a randomized clinical trial. *Int Braz J Urol.* 2016;42(4):710–716. doi:10.1590/S1677-5538.IBJU.2014.0291
- Dehong C, Liangren L, Huawei L, Qiang W. A comparison among four tract dilation methods of percutaneous nephrolithotomy: a systematic review and meta-analysis. *Urolithiasis.* 2013;41(6):523–530. doi:10.1007/s00240-013-0598-z

Research and Reports in Urology

Dovepress

Publish your work in this journal

Research and Reports in Urology is an international, peer-reviewed, open access journal publishing original research, reports, editorials, reviews and commentaries on all aspects of adult and pediatric urology in the clinic and laboratory including the following topics: Pathology, pathophysiology of urological disease; Investigation and

treatment of urological disease; Pharmacology of drugs used for the treatment of urological disease. The manuscript management system is completely online and includes a very quick and fair peer-review system, which is all easy to use. Visit <http://www.dovepress.com/testimonials.php> to read real quotes from published authors.

Submit your manuscript here: <https://www.dovepress.com/research-and-reports-in-urology-journal>