



Surgical outcomes of different approaches to dissection of lymph nodes posterior to right recurrent laryngeal nerve: a retrospective comparative cohort study of endoscopic thyroidectomy via the areolar approach and via the axillo-breast approach

Luyi Si^{1#}, Haijun Mei^{1#}, Quhui Wang¹, Feiran Wang¹, Shengnan Sha², Zhixian He¹, Jing Ke¹

¹Department of General Surgery, Affiliated Hospital of Nantong University, Medical School of Nantong University, Nantong, China; ²Department of Oncology, Affiliated Hospital of Nantong University, Medical School of Nantong University, Nantong, China

Contributions: (I) Conception and design: J Ke, Z He; (II) Administrative support: J Ke, Z He; (III) Provision of study materials or patients: L Si, H Mei, Q Wang, F Wang; (IV) Collection and assembly of data: L Si, H Mei, S Sha; (V) Data analysis and interpretation: L Si, H Mei, J Ke; (VI) Manuscript writing: All authors; (VII) Final approval of manuscript: All authors.

[#]These authors contributed equally to this work.

Correspondence to: Jing Ke. Department of General Surgery, Affiliated Hospital of Nantong University, No. 20, Xisi Road, Nantong 226000, China. Email: kjljy@163.com; Zhixian He. Department of General Surgery, Affiliated Hospital of Nantong University, No. 20, Xisi Road, Nantong 226000, China. Email: hezhixiangs@sina.com.

Background: The American Thyroid Association (ATA) points out that lymph nodes posterior to right recurrent laryngeal nerve (LN-prRLN) should be routinely dissected. Due to the high risk of nerve injury, the lymph nodes in this area are difficult to dissect thoroughly. Although there are many approaches to endoscopic thyroidectomy, no study has been conducted on which one is more suitable. The purpose of this study was to evaluate the safety, thoroughness, related trauma, and feasibility of two widely used endoscopic thyroidectomy approaches, so as to provide a basis for the surgeon to select a better surgical approach.

Methods: This retrospective study included patients who underwent ETA (n=26) and ETAB (n=36). All patients had a pathological diagnosis of papillary thyroid carcinoma (PTC) and underwent endoscopic right thyroidectomy from May 2015 to February 2022 in the Affiliated Hospital of Nantong University. The basic clinical data and surgical outcomes of the two groups were compared.

Results: There was no statistical difference between the two groups in basic clinical data and oncological characteristics, which meant that the baseline data of the two groups of patients were comparable. Significant statistical significance was observed in the operation duration (149.38±44.15 vs. 119.22±45.48 min, P=0.011), drainage volume 24 h after operation (95.54±16.79 vs. 54.46±15.11 mL, P<0.001), visual analog score (VAS) 24 h after operation (3.69±1.44 vs. 2.25±1.32, P<0.001), hospitalization duration after the operation (3.19±0.75 vs. 2.25±0.44 days, P<0.001), number of lymph node dissections after right recurrent laryngeal nerve resection (0.96±1.08 vs. 2.06±1.77, P=0.007), and number of lymph node metastases after right recurrent laryngeal nerve resection (0.12±0.33 vs. 0.58±1.00, P=0.025). Besides, there was no significant difference in the numbers of central lymph node dissections and central lymph node metastases.

Conclusions: Our study indicated that compared with ETA, ETAB may perform a more efficient dissection of the LN-prRLN based on less surgical trauma, which could provide a basis for the surgeon to select a better surgical approach.

Keywords: Thyroid cancer; endoscopic radical thyroidectomy; lymph node posterior to the right recurrent laryngeal nerve (LN-prRLN)

Submitted Oct 17, 2022. Accepted for publication Nov 29, 2022.

doi: 10.21037/gs-22-661

View this article at: <https://dx.doi.org/10.21037/gs-22-661>

Introduction

In the past 30 years, the incidence of thyroid cancer has increased rapidly, with an average of more than 500,000 new cases per year, accounting for 3% of all cancers in the world (1). As the most important pathological type of thyroid cancer, papillary thyroid carcinoma (PTC) accounts for 90% of new cases and is the only histological type with systematic growth in all countries and regions (2). PTC grows slowly and most PTCs metastasize to regional lymph node metastases, with central lymph node metastasis the most common. Among the PTC patients who present for the first time, lymph node metastasis in the central region has occurred in about 30–80% (3). However, despite its susceptibility to early lymphatic metastasis, the mortality of PTC is much lower than its morbidity, and the 10-year survival rate generally exceeds 90% (4,5). The real concern is that about 6.4–28% of PTC patients will eventually relapse (6,7). In the American Thyroid Association (ATA) guidelines, the central lymph nodes are subdivided into pre-larynx, pre-tracheal, left paratracheal, and right paratracheal lymph nodes (8). Anatomically, the right vagus nerve branches upward in front of the first segment of the subclavian artery to form the right recurrent laryngeal nerve, and since the right recurrent laryngeal nerve runs in the middle, the right paratracheal lymph node is divided into shallow and deep layers. The deep layer of the right paratracheal lymph node is also called the posterior lymph node of the right recurrent laryngeal nerve (LN-prRLN) or Area VI B, which is filled with a mixture of lymph nodes and adipose tissue, and the right lower parathyroid is often nearby. During endoscopic surgery, since the LN-prRLN is located in a deep position and abuts against the esophagus

and trachea, it is difficult to completely clean this region, which increases the difficulty of surgery and makes it easy to cause secondary injury. Surgeons are usually apt to overlook careful exploration of this area or overly conservative in the dissection of the lymph nodes in this area because of concerns about major surgical trauma. Endoscopic thyroidectomy via areola approach (ETA) and endoscopic thyroidectomy via axillo-breast approach (ETAB) are two widely used endoscopic thyroidectomy approaches in clinic. A previous study has shown that there is no significant difference between them in the duration of hospitalization, amount of drainage from the surgical sites, and occurrence of postoperative complications (9).

However, studies on the effects of endoscopic thyroidectomy via these two approaches on LN-prRLN have not been reported yet, resulting in that clinicians choose these two operation approaches based on experience or proficiency when facing the dissection of LN-prRLN, without corresponding theoretical basis. Therefore, the purpose of this study is to evaluate the safety, thoroughness, related trauma and feasibility of the two widely used endoscopic thyroidectomy, so as to provide theoretical basis for surgeons to choose a better surgical approach. We present the following article in accordance with the STROBE reporting checklist (available at <https://gs.amegroups.com/article/view/10.21037/gS-22-661/rc>).

Methods

Patients

The study was conducted in accordance with the Declaration of Helsinki (as revised in 2013). The study was approved by Ethics Committee of Affiliated Hospital of Nantong University (No. 2022-K074-01), which waived the requirement for informed consent of clinicopathologic data due to the retrospective nature of this study. According to the inclusion and exclusion criteria, we finally included 62 PTC patients who received endoscopic right-sided radical thyroidectomy from May 2015 to February 2022. All patients were informed of the advantages and disadvantages of ETAB and ETA and were free to choose the surgical approaches. We divided the patients into two groups through the operation approaches, and determined the comparability of the two groups by comparing their preoperative sex, age, tumor-related characteristics and thyroid-related hormone levels. Under the condition that the preoperative data of two groups of patients are

Highlight box

Key findings

- In comparing ETA and ETAB, the latter can effectively clean LN-prRLN with less surgical trauma and shorter operation time.

What is known and what is new?

- Lymph nodes posterior to right recurrent laryngeal nerve (LN-prRLN) should be routinely dissected.
- Compared with ETA, ETAB may perform a more efficient dissection of the LN-prRLN based on less surgical trauma.

What is the implication, and what should change now?

- We need to pay attention to the dissection of LN-prRLN while looking for more effective endoscopic or combined approaches.

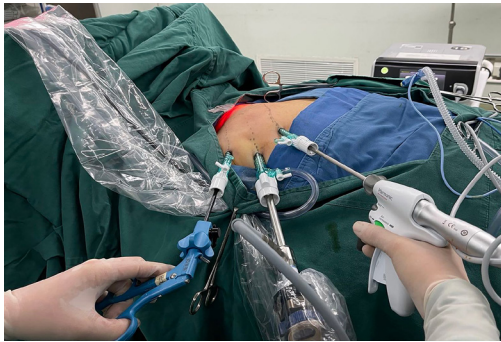

Figure 1 Schematic diagram of the ETAB. ETAB, endoscopic thyroidectomy via the axillo-breast approach.

comparable, we analyze the intraoperative and postoperative data of patients.

Preoperative assessment included ultrasonography (US), thyroid computed tomography enhanced scan, chest X-ray, and measurement of total triiodothyronine (TT3), thyroid stimulating hormone (TSH), thyroglobulin (Tg), thyroglobulin antibody (TgAb) and thyroid peroxidase antibodies (TpoAb). The clinicopathological and surgical data of the different groups were compared, including age, gender, TNM and stage of the tumor, single and multicenter lesion, operation duration, drainage volume 24 h after operation, VAS 24 h postoperatively, postoperative hospitalization, Area VI cleaning quantity, positive number of Area VI, Area VI B cleaning quantity, and positive number of Area VI B. For patients with multifocal tumors, the size and sublocation of the largest tumor were recorded for data analysis. The characteristic data of tumor were all extracted from ultrasound reports and the tumor size was extracted according to the longest diameter of the tumor.

Inclusion criteria

(I) Postoperative pathology confirmed as PTC; (II) tumor located on the right thyroid gland; (III) tumor diameter ≤ 2 cm.

Exclusion criteria

The exclusion criteria were as follows: (I) tumor diameter >2 cm, (II) other pathological types, (III) previous history of neck surgery or radiotherapy, (IV) lymph node metastasis in the lateral cervical region which is confirmed or suspected by ultrasound or enhanced CT, and (V) clinically confirmed distant lymph node metastasis or organ metastasis.

Observation indicators

Observational indicators included the following: general data (age, gender, TNM and stage of the tumor, single and multicenter lesion, preoperative thyroid function), operation-related data (operation duration, drainage volume 24 h after operation, visual analog score 24 h after operation, and hospitalization duration after operation), the number and the positive number of lymph nodes dissected (Area VI and Area VI B), and related trauma.

Surgical cavity establishment process

- (I) ETAB (*Figure 1*): A 1-cm incision was made in the right axillary front line to insert the pneumoperitoneum needle. The needle was inserted into the right sternocleidomastoid muscle along the subcutaneous route, and the needle was further inserted into the outer margin of the right sternocleidomastoid muscle after withdrawal. The swelling solution mixed with 0.1% epinephrine, 10% ropivacaine, and 9% NaCl in the ratio of 0.2 mL:20 mL:80 mL was injected along the pneumoperitoneum needle path for subcutaneous separation. After the pressure in the subcutaneous cavity was stabilized to 6 mmHg by the main trocar connected to the CO₂ machine, the endoscope was inserted. Then, 0.5 cm incisions were made at the position about 3 cm above and below the outer part of the incision, and a trocar of the corresponding size was inserted. The trocar was inserted subcutaneously at the position above the midpoint of the right clavicle and the midpoint of the sternocleidomastoid muscle, and the relevant operating instruments were inserted. The leading edge of the sternocleidomastoid muscle was freed with an ultrasonic knife, and the sternohyoid muscle and thyrohyoid muscle were opened layer by layer to expose the right thyroid gland. Finally, the cavity was successfully constructed.
- (II) ETAB (*Figure 2*): A 1-cm incision across the 3 o'clock aspect of the right areola was made and the pneumoperitoneum needle was inserted. The needle penetrated subcutaneously to the left clavicle, and the puncture was continued to the right clavicle after the needle was withdrawn. The expansion liquid mixed with 0.1% epinephrine, 10% ropivacaine, and 9% NaCl in the ratio of 0.2 mL:20 mL:80 mL was injected along the pneumoperitoneum needle path

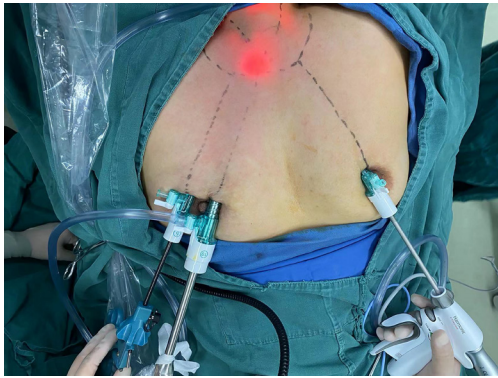


Figure 2 Schematic diagram of the ETA. ETA, endoscopic thyroidectomy via the areolar approach.

to stop bleeding and pain and facilitate subcutaneous separation. The pressure in the subcutaneous compartment was stabilized to 6 mmHg by the main trocar connected to the CO₂ machine. An 11-point transverse incision of 0.5 cm was made into both areolae and the corresponding trocar was inserted into the compartment in the middle of the sternum through a subcutaneous puncture. Then, the relevant operating instruments were inserted. An ultrasonic scalpel was used to free the suprasternal fossa from the anterior cervical subcutaneous tissue, and the anterior sides of the neck reached the medial margin of the sternocleidomastoid muscle. The right thyroid gland was exposed by opening the cervical white line with an ultrasonic knife, and the endoscopic thyroid retractor was inserted into the plane of the medial margin of the right sternocleidomastoid muscle under the supervision of endoscopy. The right thyroid gland was fully exposed, and the cavity was successfully established.

Surgical procedure

The thyroid mass was completely removed during the operation. The right thyroid lobe plus isthmus was removed after the PTC was confirmed by the intraoperative rapid frozen paraffin section. Then, central lymph node dissection was performed as follows: the recurrent laryngeal nerve was completely isolated with the aid of separation forceps and ultrasonic scalpel; after the right lower parathyroid was identified, the lateral, anterior, and medial parts of the recurrent laryngeal nerve were successively dissected from outside to inside the paratracheal lymph nodes; then, the

anterior tracheal and anterior laryngeal lymph nodes were dissected; finally, the fat and lymph node tissues posterior to the recurrent laryngeal nerve were separated with forceps and separately removed. After resection of the right recurrent laryngeal nerve, the lymph nodes were separately identified by the surgeon and examined by the pathologist. To ensure a clearer field of view and identification, the injected nanocarbon tracer was not used in both groups during the operation.

Postoperative follow-up

In this study, the outpatient follow-up and telephone follow-up were combined, and no patient loss to follow-up occurred. Each patient was observed for permanent hoarseness and hypoparathyroidism 3 months after surgery.

Statistical analysis

All data were analyzed using SPSS v. 26.0 (IBM Corp., Armonk, NY, USA) statistical software. Continuous variables were expressed as mean \pm SD. A *t*-test was used for continuous variables. Pearson's chi-square test and Fisher's exact test were used for categorical variables. A value of $P < 0.05$ indicated that the difference was statistically significant.

Results

Comparison and analysis of clinical baseline data between the ETA group and the ETAB group

In this study, there were 26 cases in the ETA group and 36 cases in the ETAB group. There was no significant difference in gender and age between the two groups ($P > 0.05$). The average tumor diameter of the two groups was 0.84 cm (0.2–2 cm). In our center, considering that thyroid cancer with a tumor diameter of more than 2 cm is prone to lymph node metastasis in the cervical region and the large tumor body readily covers the operation field resulting in difficulty or omission in dissection, we strictly stipulated for the inclusion criteria that the diameter of the thyroid tumor should be ≤ 2 cm. At the same time, there was no statistical difference between the two groups in other oncological characteristics (T, N, single multicenter lesion), preoperative thyroid function (TT₃, TSH, Tg, TgAb, and TPOAb; *Table 1*), which meant that the baseline data of the two groups of patients were comparable.

Table 1 Comparative analysis of clinical data between the ETA group and the ETAB group

Clinical data	ETA	ETAB	χ^2/t value	P value
Age (years), mean \pm SD	34.00 \pm 8.19	35.69 \pm 7.66	-0.835	0.407
Gender			3.783	0.052
Man	8	3		
Woman	18	33		
Tumor diameter (cm), mean \pm SD	0.91 \pm 0.46	0.79 \pm 0.33	1.192	0.240
T			1.643	0.200
T1a	19	31		
T1b	7	5		
N			0.911	0.340
N1	15	25		
N2	11	11		
Single/multi-center lesion				0.419
Single lesion	25	36		
Multiple lesions	1	0		
Preoperative TT3, mean \pm SD	5.27 \pm 0.42	5.40 \pm 2.30	-0.280	0.780
Preoperative TSH, mean \pm SD	2.60 \pm 1.56	2.53 \pm 1.34	0.194	0.847
Preoperative Tg, mean \pm SD	64.55 \pm 213.05	14.94 \pm 21.07	1.392	0.169
Preoperative TgAb, mean \pm SD	4.13 \pm 12.15	4.25 \pm 15.79	0.031	0.975
Preoperative TpoAb, mean \pm SD	6.20 \pm 17.43	3.57 \pm 8.61	0.709	0.483

ETA, endoscopic thyroidectomy via the areolar approach; ETAB, endoscopic thyroidectomy via the axillo-breast approach; TT3, total triiodothyronine; TSH, thyroid stimulating hormone; Tg, thyroglobulin; TgAb, thyroglobulin antibody; TpoAb, thyroid peroxidase antibodies.

Table 2 Comparative analysis of surgical data between the ETA group and the ETAB group

Variables	ETA	ETAB	T value	P value
Operation duration (min), mean \pm SD	149.38 \pm 44.15	119.22 \pm 45.48	2.608	0.011
Drainage volume (mL) 24 h after operation, mean \pm SD	95.54 \pm 16.79	54.46 \pm 15.11	10.038	<0.001
VAS 24 h postoperatively, mean \pm SD	3.69 \pm 1.44	2.25 \pm 1.32	4.039	<0.001
Postoperative hospitalization (days), mean \pm SD	3.19 \pm 0.75	2.25 \pm 0.44	6.220	<0.001

ETA, endoscopic thyroidectomy via the areolar approach; ETAB, endoscopic thyroidectomy via the axillo-breast approach; VAS, visual analog score.

Comparison and analysis of surgical data between the ETA group and the ETAB group

The difference in operation duration between the ETA group and the ETAB group was statistically significant ($P=0.011$). In addition, the drainage volume at 24 h after

operation in the ETA group was significantly greater than that in the ETAB group ($P<0.001$), and the hospitalization duration after operation in the ETA group was longer than that in the ETAB group ($P<0.001$), suggesting that the ETAB group had less surgical trauma (*Table 2*).

Table 3 Comparative analysis of surgical data between the ETA group and the ETAB group

Variables	ETA	ETAB	T value	P value
Area VI cleaning quantity	4.62±3.03	3.53±3.33	1.338	0.186
Positive number of Area VI	1.38±2.28	0.69±1.24	1.532	0.131
Area VI B cleaning quantity	0.96±1.08	2.06±1.77	-2.794	0.007
Positive number of Area VI B	0.12±0.33	0.58±1.00	-2.303	0.025

Data are shown as mean ± SD. ETA, endoscopic thyroidectomy via the areolar approach; ETAB, endoscopic thyroidectomy via the axillo-breast approach.

Comparison of lymph node dissection in Area VI and Area VI B between the ETA group and the ETAB group

Prophylactic central lymph node dissection was routinely performed in both groups during the operation. As shown in *Table 3*, there was no significant difference between the two groups in the number of Area VI cleanings and the number of positive areas ($P>0.05$). However, the number of Area VI B cleanings in the ETAB group was significantly higher than that in the ETA group ($P=0.007$), and the number of positive Area VI B in the ETAB group was also significantly higher than that in the ETA group ($P=0.025$).

Postoperative complications and recurrence

No complications such as neck hematoma, chyle leakage, permanent hoarseness, and symptomatic hypocalcemia occurred in the patients of the two groups after the operation. In the ETAB group, there was only one case of cervical emphysema complicated with infection, and the patient presented with a paroxysmal cough. The neck CT indicated local discontinuity of the tracheal wall. The working end of the ultrasonic scalpel during the operation was considered to be overheated and to have burned the tracheal wall. The patient was discharged after receiving anti-infection treatment in our hospital. No recurrence was observed in either group during the follow-up.

Discussion

PTC is the most important pathological type of thyroid cancer. However, under the background of a good prognosis, there is the potential risk of early lymphatic metastasis and even distant metastasis (10). At present, for endoscopic treatment of thyroid cancer, the main controversial point in surgery lies in whether preventive central lymph node dissection is necessary for cN0 PTC (11). Multiple studies have shown that the lymph node-positive

rate of cN0 PTC is 17.8–33% (12,13), which means that one quarter or more patients with preoperative negative imaging are likely to find pathological metastasis. Neither the 2019 Guidelines of the American Thyroid Association (ATA2019) nor the 2019 Guidelines of the National Comprehensive Cancer Network (NCCN) recommend that only patients with clinically positive lymph nodes should undergo central lymph node dissection and neither advocate overly aggressive preventive resection. In addition, unilateral lobectomy plus isthmus resection is recommended for 1–4 cm PTC (8,14). However, the Chinese guidelines advocate that lymph node dissection in the ipsilateral central region of the lesion should be performed under the condition of effective preservation of the parathyroid gland and recurrent laryngeal nerve. Considering the high metastatic rate of PTC and the early occurrence of lymphatic metastasis, we finally determined the surgical protocol as right lateral lobectomy + isthmectomy + right central lymph node dissection. In addition, although we generally adopt an observational attitude towards lesions <0.5 cm and do not recommend active surgical treatment, the smallest pathologically reported lesion in this study was only 0.2 cm. On the one hand, the tumor diameter measured by preoperative ultrasound was >0.5 cm. In the postoperative pathological report of this patient, four lymph nodes were removed from the central area, and two were metastatic lymph nodes. Therefore, the author finally included this patient in our study.

At present, thyroid cancer in China has two characteristic trends. One is the increasing trend of incidence and the second is the trend of the younger-onset population. The latest global cancer statistics show that there were more than 586,000 cases of thyroid cancer in the world in 2020. In East Asia, including China, the incidence ratio of thyroid cancer between men and women is 1:3 (15). A retrospective study from the General Hospital of the People's Liberation Army of China showed that the average age of the onset

population of thyroid cancer was 43.7 ± 11.3 years old, showing a rejuvenation trend, and the incidence of PTC in women was significantly higher than in men, with about two-thirds of the patients women (16).

The development of endoscopic surgery is a great revolution in medical technology in the 21st century, injecting fresh blood into surgery. It was in 1997 when Hüscher first improved and applied the endoscopic technique to thyroidectomy, and now endoscopic thyroidectomy has officially landed on the historical stage. After more than 20 years of exploration and innovation by surgeons, endoscopic thyroidectomy has gradually developed to include the mouth, axillary, breast, chest wall, or a combination of multiple surgical procedures (17). Endoscopic thyroidectomy successfully transfers the incision to a hidden part of the neck, and the advantage of “no scar left” on the neck satisfies people’s aesthetic demands (18). Patients who meet the inclusion criteria have the complete and independent right to choose the surgical approach, and the average age of the patients included in this study was 34.98 ± 7.87 years old, with a ratio of men to women of 1:5. This confirms the attraction of the endoscopic technique for young patients, especially for young female patients.

In this study, the operation time via the ETA was significantly longer than that in the ETAB group. On the one hand, this was due to the longer lumen establishment time in the ETA group at the beginning of surgery and the need to suture the cervical white line under endoscopy. On the other hand, it also shows that the ETAB uses a more suitable operation angle and visual field control for the lobectomy of unilateral PTC and lymph node dissection in Area VI, which the author also deeply realized during the operation. In addition, the drainage volume 24 h after operation and the duration of hospitalization after operation via the ETA were significantly higher and longer, respectively, than those in the ETAB group. Although the area of the ETAB for creating a cavity and the operation space is small, the direct view angle perpendicular to the recurrent laryngeal nerve is beneficial for the operator to perform finer operations, causing a smaller area of operation trauma and reducing postoperative pain, so the patient recovers quickly after surgery.

The posterior LN-prRLN, also known as the lymph node in Area VI B, has a similar shape to “V” and is mainly filled with fat, fiber, and lymphatic tissue. Its anterior boundary is the right recurrent laryngeal nerve, its medial side is adjacent to the esophagus and trachea, its lateral side is the common carotid artery, its upper boundary is

the place where the right recurrent laryngeal nerve enters the larynx, and its lower boundary is the junction of the common carotid artery and the trachea with the esophagus. According to previous studies, the probability of lymph node metastasis in this region ranges from 8.65% to 34.1% (19-21). In our study, the lymph node metastatic rate in Area VI B was 22.58% (14/62). The difference in metastatic rate may be due to the number of cases in multiple studies and the difference in the tumor diameter specified in the inclusion criteria. Due to the special anatomical location of this area, improper operation may lead to increased complications such as arterial hemorrhage, nerve injury, and parathyroid injury. The two surgical approaches compared in this study were both generally recognized as safe and frequently used. We believe that reliance on the advanced endoscopic machine, with its good magnification, can enable the operator to better identify structures such as blood vessels, nerves, parathyroid, trachea, and esophagus, and thus better control the bleeding and protect the parathyroid, recurrent laryngeal nerve, and other important anatomical structures to reduce possible complications during and after the operation. Therefore, in this study, no other serious complications occurred except for one case of cervical emphysema caused by a thermal burn of the tracheal wall by an ultrasonic scalpel.

In the comparison of the lymph node dissection in Area VI and Area VI B, there was no significant difference in the number of lymph node dissections in Area VI and the number of positive lymph nodes in Area VI between the two groups ($P=0.186$, $P=0.131$, respectively), suggesting that the safety aspects of surgical lymph node dissection in the central region of thyroid cancer were similar in the two groups. However, the number of lymph node dissections in Area VI B and the number of positive lymph nodes in Area VI B in the ETAB group were significantly higher than those in the ETA group ($P=0.007$, $P=0.025$, respectively). During the dissection of Area VI B, the operation via the areola approach required crossing the sternum and clavicle during cavity establishment, and placing the lens at a parallel angle with the nerve resulted in indistinct lymph nodes being positioned behind the nerve. Excessive nerve traction during lymph node dissection may cause injury or even fracture. In addition, the top-down view and the unavoidable bony structure of the area limit the working end of the ultrasonic scalpel, making it difficult to reach the lymph nodes at a deeper position around the lower tracheoesophageal junction in Area VI B. Multiple operations may increase the risk of right lower parathyroid

injury. Although neither patient experienced symptomatic hypocalcemia postoperatively because of our surgical coverage of unilateral thyroidectomy, this did not rule out the possibility that an injury to the right lower parathyroid gland had occurred. The angle of view of the ETAB perpendicular to the recurrent laryngeal nerve was not only conducive to the exposure of nerves and lymph nodes, but also conducive to picking up the tissues around the nerves and moving them away from the nerves for cleaning with the separation forceps, and thus this angle could better identify and protect the right lower parathyroid.

In essence, endoscopic thyroidectomy and open thyroidectomy are only different in terms of their surgical approaches, but there is no fundamental difference in treatment principles. Endoscopic thyroidectomy should always adhere to the “principle of radical cure of tumor” while taking into account the cosmetic effect, and the recurrence and complications of the tumor should not be ignored to pursue cosmetic treatment excessively. According to the previous literature, endoscopic thyroidectomy has a low overall recurrence rate and few complications. A retrospective study conducted by Sun *et al.* (22) included 100 cases of thyroidectomy via the oral approach, 119 cases via the areolar approach, and 189 cases via the conventional open approach. During various follow-up visits within 4–21 months after operation, there was no significant difference among the three groups in multiple aspects such as recurrent laryngeal nerve injury, parathyroid injury, and recurrence and metastasis. All three operations can safely and effectively clean the central lymph nodes. Jiang *et al.* (23) performed a long-term follow-up of tumor recurrence, complications, and adverse times for a total of 5,664 patients selected from 20 publications through meta-analysis, and the results showed that endoscopic surgery was equivalent to open surgery for thyroid cancer in terms of safety and effectiveness. However, most patients enrolled in endoscopic thyroidectomy have a papillary carcinoma limited to T1 and T2, and the probability of recurrence and metastasis is low (24). Thus, there may be a selection bias.

Endoscopic lymph node dissection in the central region has become very challenging due to the narrow surgical space and bony structure constraints (25), and dissection in Area VI B is even more difficult. However, recent studies have shown that inadequate central lymph node dissection during the primary surgery is a common cause of tumor recurrence and that Area VI B may also be the only metastatic site of PTC without the involvement of other compartments (21,26). Therefore, Area VI B dissection is

necessary for patients with right-sided thyroid cancer. In a meta-analysis, Zhou *et al.* (27) found that patients younger than or equal to 45 years old were more likely to develop Area VI B metastasis, and the number of lymph node metastasis in this region was related to the impaired survival of young patients (28). In our study, the average age of patients was not more than 35 years old. If Area VI B could not be completely cleaned in the first operation, it would be difficult to clean the residual lymph nodes in the second operation. Therefore, endoscopic resection of Area VI B is very important and necessary.

In conclusion, our study demonstrates that both approaches are safe and effective in the dissection of lymph nodes in the central region. At the same time, in comparing ETA and ETAB, the latter can effectively clean LN-prRLN with less surgical trauma and shorter operation time. Regrettably, the case with the least follow-up time in our study was less than one year. Given that tumor recurrence usually occurs over a year, the follow-up time for these cases is insufficient to observe tumor recurrence, and we must conduct continuous follow-up observation afterwards.

Conclusions

Both ETA and ETAB approaches are safe. In contrast to ETA, ETAB may perform a more efficient dissection of the LN-prRLN based on less surgical trauma, which could provide a basis for the surgeon to select a better surgical approach. Subsequently, we need more studies with longer follow-up times and observation of tumor recurrence.

Acknowledgments

Funding: None.

Footnote

Reporting Checklist: The authors have completed the STROBE reporting checklist. Available at <https://gs.amegroups.com/article/view/10.21037/gS-22-661/rc>

Data Sharing Statement: Available at <https://gs.amegroups.com/article/view/10.21037/gS-22-661/dss>

Conflicts of Interest: All authors have completed the ICMJE uniform disclosure form (available at <https://gs.amegroups.com/article/view/10.21037/gS-22-661/coif>). The authors have no conflicts of interest to declare.

Ethical Statement: The authors are accountable for all aspects of the work in ensuring that questions related to the accuracy or integrity of any part of the work are appropriately investigated and resolved. The study was conducted in accordance with the Declaration of Helsinki (as revised in 2013). The study was approved by Ethics Committee of Affiliated Hospital of Nantong University (No. 2022-K074-01), which waived the requirement for informed consent of clinicopathologic data due to the retrospective nature of this study.

Open Access Statement: This is an Open Access article distributed in accordance with the Creative Commons Attribution-NonCommercial-NoDerivs 4.0 International License (CC BY-NC-ND 4.0), which permits the non-commercial replication and distribution of the article with the strict proviso that no changes or edits are made and the original work is properly cited (including links to both the formal publication through the relevant DOI and the license). See: <https://creativecommons.org/licenses/by-nc-nd/4.0/>.

References

- Miranda-Filho A, Lortet-Tieulent J, Bray F, et al. Thyroid cancer incidence trends by histology in 25 countries: a population-based study. *Lancet Diabetes Endocrinol* 2021;9:225-34.
- Filetti S, Durante C, Hartl D, et al. Thyroid cancer: ESMO Clinical Practice Guidelines for diagnosis, treatment and follow-up†. *Ann Oncol* 2019;30:1856-83.
- Choi KY, Kim JH, Park IS, et al. Predictive gene signatures of nodal metastasis in papillary thyroid carcinoma. *Cancer Biomark* 2018;22:35-42.
- Amin MB, Edge SB, Greene F, et al. eds. *AJCC Cancer Staging Manual*, 8th ed. New York, NY: Springer International Publishing; 2017.
- Lim H, Devesa SS, Sosa JA, et al. Trends in Thyroid Cancer Incidence and Mortality in the United States, 1974-2013. *JAMA* 2017;317:1338-48.
- Chereau N, Oyekunle TO, Zambeli-Ljepović A, et al. Predicting recurrence of papillary thyroid cancer using the eighth edition of the AJCC/UICC staging system. *Br J Surg* 2019;106:889-97.
- Grogan RH, Kaplan SP, Cao H, et al. A study of recurrence and death from papillary thyroid cancer with 27 years of median follow-up. *Surgery* 2013;154:1436-46; discussion 1446-7.
- Haugen BR, Alexander EK, Bible KC, et al. 2015 American Thyroid Association Management Guidelines for Adult Patients with Thyroid Nodules and Differentiated Thyroid Cancer: The American Thyroid Association Guidelines Task Force on Thyroid Nodules and Differentiated Thyroid Cancer. *Thyroid* 2016;26:1-133.
- Hur SM, Kim SH, Lee SK, et al. New endoscopic thyroidectomy with the bilateral areolar approach: a comparison with the bilateral axillo-breast approach. *Surg Laparosc Endosc Percutan Tech* 2011;21:e219-e224.
- Shteinshnaider M, Muallem Kalmovich L, Koren S, et al. Reassessment of Differentiated Thyroid Cancer Patients Using the Eighth TNM/AJCC Classification System: A Comparative Study. *Thyroid* 2018;28:201-9.
- Medas F, Canu GL, Cappellacci F, et al. Prophylactic Central Lymph Node Dissection Improves Disease-Free Survival in Patients with Intermediate and High Risk Differentiated Thyroid Carcinoma: A Retrospective Analysis on 399 Patients. *Cancers (Basel)* 2020;12:1658.
- Wada N, Masudo K, Nakayama H, et al. Clinical outcomes in older or younger patients with papillary thyroid carcinoma: impact of lymphadenopathy and patient age. *Eur J Surg Oncol* 2008;34:202-7.
- Moo TA, McGill J, Allendorf J, et al. Impact of prophylactic central neck lymph node dissection on early recurrence in papillary thyroid carcinoma. *World J Surg* 2010;34:1187-91.
- NCCN. NCCN clinical practice guidelines in oncology, thyroid carcinoma (version 1.2019)(EB/OL). Fort Washington: NCCN, 2019 (2019-03-28).
- Sung H, Ferlay J, Siegel RL, et al. Global Cancer Statistics 2020: GLOBOCAN Estimates of Incidence and Mortality Worldwide for 36 Cancers in 185 Countries. *CA Cancer J Clin* 2021;71:209-49.
- Zhao L, Pang P, Zang L, et al. Features and trends of thyroid cancer in patients with thyroidectomies in Beijing, China between 1994 and 2015: a retrospective study. *BMJ Open* 2019;9:e023334.
- Papaspyrou G, Ferlito A, Silver CE, et al. Extracervical approaches to endoscopic thyroid surgery. *Surg Endosc* 2011;25:995-1003.
- Zhang Z, Sun B, Ouyang H, et al. Endoscopic Lateral Neck Dissection: A New Frontier in Endoscopic Thyroid Surgery. *Front Endocrinol (Lausanne)* 2021;12:796984.
- Li C, Xiang J, Wang Y. Risk Factors for Predicting Lymph Nodes Posterior to Right Recurrent Laryngeal Nerve (LN-prRLN) Metastasis in papillary thyroid carcinoma: A Meta-Analysis. *Int J Endocrinol* 2019;2019:7064328.
- Hou J, Shan H, Zhang Y, et al. Risk factors of metastasis

- to the lymph nodes posterior to the right recurrent laryngeal nerve in papillary thyroid carcinoma. *Eur Arch Otorhinolaryngol* 2020;277:881-6.
21. Wang Y, Wang D, Chen L, et al. A Comparison of Two Operation Methods Revealed the Risk Factors and the Necessity of LN-prRLN Dissection in Papillary Thyroid Carcinoma: A Retrospective Cohort Study in FUSCC. *Int J Endocrinol* 2020;2020:7162793.
 22. Sun H, Zheng H, Wang X, Zeng Q, Wang P, Wang Y. Comparison of transoral endoscopic thyroidectomy vestibular approach, total endoscopic thyroidectomy via areola approach, and conventional open thyroidectomy: a retrospective analysis of safety, trauma, and feasibility of central neck dissection in the treatment of papillary thyroid carcinoma. *Surg Endosc* 2020;34:268-74.
 23. Jiang WJ, Yan PJ, Zhao CL, et al. Comparison of total endoscopic thyroidectomy with conventional open thyroidectomy for treatment of papillary thyroid cancer: a systematic review and meta-analysis. *Surg Endosc* 2020;34:1891-903.
 24. Ze Y, Zhang X, Shao F, et al. Active surveillance of low-risk papillary thyroid carcinoma: a promising strategy requiring additional evidence. *J Cancer Res Clin Oncol* 2019;145:2751-9.
 25. Sun P, Chen W, Mak TK, et al. Right Central Lymph Node Dissection in Thyroidectomy: Can Endoscopic Chest-Breast Approach Be Used? *J Laparoendosc Adv Surg Tech A* 2020;30:308-14.
 26. Zhang P, Zhang B, Bu J, et al. Prospective analysis of the risk factors and clinical indications of dissection of lymph node posterior to right recurrent laryngeal nerve in 283 cases of papillary thyroid carcinoma. *Zhonghua Zhong Liu Za Zhi* 2014;36:109-14.
 27. Zhou T, Wu F, Zhao L, et al. A meta-analysis of risk factors for lymph node posterior to the right recurrent laryngeal nerve metastasis in papillary thyroid carcinoma. *Gland Surg* 2021;10:1841-51.
 28. Adam MA, Pura J, Goffredo P, et al. Presence and Number of Lymph Node Metastases Are Associated With Compromised Survival for Patients Younger Than Age 45 Years With Papillary Thyroid Cancer. *J Clin Oncol* 2015;33:2370-5.
- (English Language Editor: K. Gilbert)

Cite this article as: Si L, Mei H, Wang Q, Wang F, Sha S, He Z, Ke J. Surgical outcomes of different approaches to dissection of lymph nodes posterior to right recurrent laryngeal nerve: a retrospective comparative cohort study of endoscopic thyroidectomy via the areolar approach and via the axillo-breast approach. *Gland Surg* 2022;11(12):1936-1945. doi: 10.21037/gs-22-661