

EXPERIMENTS ON THE CAUSE OF THE RABBIT CARCINOMAS
DERIVED FROM VIRUS-INDUCED PAPILLOMAS*

I. PROPAGATION OF SEVERAL OF THE CANCERS IN SUCKLINGS, WITH
ETIOLOGICAL TESTS

By WILLIAM E. SMITH,† M.D., JOHN G. KIDD, M.D., AND PEYTON ROUS, M.D.

(From the Laboratories of The Rockefeller Institute for Medical Research and the
Department of Pathology, Cornell University Medical College, New York)

PLATES 24 TO 29

(Received for publication, December 14, 1951)

Many facts have appeared to indicate that variants of the virus causing rabbit papillomas (Shope) may be responsible for the carcinomas deriving from these growths (1-3), but numerous obstacles have frustrated tests of this possibility. First amongst them has been the difficulty of maintaining the cancers under conditions favorable to experimental scrutiny. In the present paper the propagation of several such growths in newborn rabbits will be reported, together with etiological tests of the malignant tissues thus provided(4).

General Procedure

The papillomas produced by the virus in its natural host, the cottontail rabbit, are well tolerated, and disappear in many instances as time goes on, but not infrequently one undergoes carcinomatous change. Extracts of the malignant tissue have proved innocuous although papillomas coexisting on the same animals, even some from which cancers had directly derived, have yielded the Shope virus (3).¹ Indeed the cancer extracts have sometimes actually proved capable of neutralizing this virus *in vitro* (3), owing to the presence in the disordered malignant tissue of antiviral antibody seeped from the blood (5, 6). This antibody reaches a high titer in cottontails and would presumably prove effective against any antigenically related, cancer-producing, variant virus, while furthermore such a variant might well call forth an antibody specific to itself. Manifestly one must test the cancers for presumptive causative viruses under conditions such that antibodies do not interfere. With this aim in view one might transfer them from their primary hosts (in which frustrating

* Reported at the 4th International Cancer Congress, St. Louis, September, 1947.

† Present address: Post-Graduate Medical School, New York University, 477 First Avenue, New York.

¹ The recent work of Syverton *et al.* has confirmed these findings. (Syverton, J. T., Dascomb, H. E., Wells, E. B., Koomen, J., Jr., and Berry, G. P., *Cancer Research*, 1950, 10, 440.)

antibodies would almost certainly have developed because of their long presence) to other rabbits so favorable to their growth as to provide sufficient neoplastic tissue for test before antibodies form.

But these are specifications difficult to fulfill. Attempts to transplant the cancers of cottontails have uniformly failed, and those arising in domestic rabbits inoculated with the Shope virus, though appearing frequently and relatively soon, have only rarely been transferred successfully. In the last 15 years more than 20 of them have been transplanted in our laboratory, often to large groups of adult individuals, frequently of the same inbred stock (Dutch belted) as their primary hosts; but only two of the tumors have grown, and one was lost before direct tests for its cause could be made (7). The other (8) is now in its 72nd tumor generation after 13 years of propagation. Extracts of its exceedingly malignant tissue have again and again been inoculated into the skin of other rabbits, always with a negative outcome, even when the epidermal cells had been rendered notably susceptible to infection with the Shope virus by various procedures (9-11). But the neutralizing action of antibodies extravasated into the malignant tissue utilized for extraction may have been responsible in many instances for this result.

There is a further difficulty, not in the least understood. Though the papillomas produced by the inoculation of domestic rabbits grow with great vigor and contain the Shope virus, as shown by the appearance in circulation, as time goes on, of an antibody specifically neutralizing the virus, little or none of the latter can be extracted from the papillomatous tissue in most instances (12), even when only a negligible quantity of antibody is present in the blood (13). A similar state of affairs might well exist in the case of variant viruses causing the derivative cancers.

Fortunately certain "strains" of the papilloma virus can be recovered from the growths they produce, even after these have existed for a long time (14); and Friedewald has shown that rabbit epidermis can be rendered much more susceptible to infection by inducing hyperplasia of it (9). Acting on this knowledge, he and Kidd found all of the many virus strains they tested to be recoverable in most instances, though only in small quantity (10).²

Taken together these facts have seemed to bring tests for presumptive cancer viruses within possibility, though with the following conditions manifestly requisite:

(a) The papillomas providing the cancers through secondary malignant alteration must have been produced with readily recoverable strains of virus, since otherwise derivative variants might not be recoverable.

(b) The cancerous tissue must be transplanted from its original host in order to get it away from antibodies elaborated by the latter.

(c) The implanted malignant tissue must proliferate so rapidly as to furnish sufficient material for test before the new host develops effective antiviral antibody. In corollary, the epidermis inoculated with the cancer extracts should have been brought, if possible, into a state rendering it especially susceptible to infection.

These needs have been largely met in the experiments now to be described.

² Using their methods, we have failed in the present work to obtain any virus from the growths due to more than half of our own "strains."

Method

Day-old domestic rabbits have been used as the new hosts whenever possible and, lacking these, the youngest sucklings available.

To obtain the cancers, extracts in Locke's or Tyrode's or 0.9 per cent salt solution of glycerinated, cottontail papillomas (paps.) known to contain Shope virus of recoverable sort have been inoculated broadcast into scarified rectangular areas several centimeters across, on each side of groups of 10 to 20 adult mongrel agouti or inbred Dutch belted rabbits. These areas had previously been rendered hyperplastic by several applications of turpentine and acetone in equal parts (9) and were dressed afterwards with paraffined gauze to prevent scabbing and hasten repair (11). Active, confluent papillomatous masses soon covered them, and generally underwent malignant change at one or more spots within 6 months to a year. Not infrequently the cancers metastasized to the regional lymph nodes, and when this had happened one of the secondary nodules was excised, a block taken for section, and some or all of the remainder was cut fine, suspended in Locke's solution or saline (to which frequently one part in 20 of normal rabbit serum had been added, for the better preservation of the cells), and injected into the muscles of both forelegs of the host and those of the anterior and posterior thighs. Thus new cancerous growths were obtained, free from the bacteria contaminating the primary tumor and from virus pap. tissue as well; and when these growths had become large enough to provide material for many implantations the rabbit was killed and transfers were made as before, but this time into the anterior thighs of sucklings (two to four litters when available, with 0.3 to 0.5 cc. of leg tumor suspension injected at each site).³ The implanted young were all either mongrels of Institute stock, or Dutch belted animals,—still somewhat mongrel despite more than 10 years of brother-to-sister mating. Many older animals were also implanted, at all of the six sites above mentioned. The skin was slit prior to thrusting in the needle, to avoid the possible introduction of normal epidermal cells together with the tumor fragments.

The cancers propagated in adults in previous years were called the V1 and V2 respectively; but these terms came to have larger meanings during the War and hence the covering designation Vx will be substituted,—the V2 becoming the Vx2; and it will be applied to every carcinoma implanted in new hosts, irrespective of whether it succeeded, a following number indicating its place in the series.

Only those animals that survived long enough for the malignant tissue to have given rise to nodules find mention in the protocols.

The Vx3 Carcinoma

The first carcinoma to be transferred was carried through four successive groups of sucklings.

The rabbit furnishing the cancer was of the same Dutch belted strain in which the Vx2 carcinoma had arisen and was first propagated. It had been inoculated on the side with recoverable virus W. R. 1-28, and 7 months later the resulting pap. mass had been almost replaced by a large, fleshy, ulcerated growth, and a metastatic nodule could be felt in a neighboring axillary gland. Fragments of this nodule were implanted in the legs of the host and grew so fast that 19 days later the rabbit was killed and transplantation done. Already more

³ Turpentine was swabbed on the nose of the mother animal before her young were returned to her so that she might not perceive by smell that they had been handled and hence kill them.

axillary nodules had formed, and one was found in the lungs. Sections showed at every situation a highly invasive, keratinizing, squamous-cell carcinoma with unusually large cells.

1st Tumor Generation (Chart 1).—A suspension of small pieces of pooled tissue from the leg nodules was injected into four normal, adult rabbits of Dutch belted stock, into 12 others which had been unsuccessfully implanted with another cancer some months before, into four normal, half-grown animals of the same stock, and six half-grown agouti rabbits. No tumors resulted save in one of the half-grown Dutch belted animals, and its growths soon retrogressed.

Three 9-day-old Dutch belted sucklings of a single litter had also received the tumor, into the anterior thighs. The results with them were very different. Two developed intramuscular tumors which rapidly became huge, surrounding the femur almost from hip to knee; and in one a subcutaneous, carcinomatous disc also formed where the injecting needle had passed, ulcerating and involving the skin secondarily (Fig. 1). This one was killed after 32 days and tissue from its intramuscular growths was transferred further.

The other suckling with tumors was killed after 43 days. Its growths had by then become even larger, and its hind legs dragged as if paralyzed; metastases were present in the iliac nodes. It weighed only 520 gm. as compared with 1350 gm. for the third suckling,—which remained negative.

The big masses in the legs were due to the coalescence of many nodules that were undergoing central necrosis with result in small cysts with ragged walls enclosing turbid, creamy, or pink fluid. The malignant tissue appeared unencapsulated in the gross and was translucent, of pinkish-cream color, with many opaque, creamy plugs. The microscope showed a markedly desmoplastic and exceedingly invasive carcinoma in the muscles (Figs. 2 and 3), whereas in the iliac metastasis (Fig. 4) the growth had the aspect of a carcinoma solidum. Much malignant tissue from each animal was cut up, pressed between dry, sterile sponges to force out the numerous plugs and any residual serum, and stored at -12 to -14°C .

2nd Generation.—Chart 1 tells the breed, age, and number of the rabbits and the outcome of the implantations. The cancer was placed in the anterior thighs of two 1-day-old litters of agouti stock and two of the Dutch belted breed. It grew in all of the latter with immense rapidity and in one animal, killed after 41 days, had largely replaced the lower end of the femur, entered the knee cavity, and extending up to the backbone, had invaded this as well. The other six were also killed when almost dead of their tumors after from 30 to 42 days. One examined after 37 days had metastases in an iliac node. The growths resembled the previous ones. Much of the malignant tissue was squeezed between sponges and stored frozen as before. Transfer was made to a third group (3rd Generation A) from an animal killed after 30 days.

The cancer also grew in five of the 10 agouti sucklings, though much less rapidly, retrogressing in three eventually. From one in which it had done well transfer was made to a new group after 57 days (3rd Generation B).

The cancer grew in none of the half-grown or adult animals.

3rd Generation. A.—The tumor material transferred from the Dutch belted suckling of the 2nd Generation formed small nodules which soon retrogressed in one individual of two 4-day-old litters of agouti stock, failing in all the others, and it failed completely in a large group of half-grown agoutis; it grew rapidly and progressively, on the other hand, in three of eight Dutch belted sucklings of two litters 10 and 11 days old respectively. Two of the three were killed after 39 days, and much material from both was stored frozen. The femur of one had been partly replaced by neoplastic tissue and its iliac nodes contained metastases. The third suckling died after 47 days, and again iliac metastases were found. Tumor material from each of the sucklings killed after 39 days was implanted in the rabbits of a new group (4th Generation),—each material into one anterior thigh of every host.

B.—Sixteen agouti rabbits 4 days old were implanted, and a large group of agoutis 5 weeks old. The tumor succeeded in two of the former only, grew slowly, and was not carried further.

4th Generation.—Four large agouti litters, 1, 7, 10, and 12 days old, were utilized as hosts together with six animals from three litters of Dutch belted rabbits 22, 29, and 35 days old. In none of these last did the tumor "take" and only in the day-old agouti litter did it grow progressively, doing so in four of seven individuals. In one of six agoutis 7 days old a retrogressing nodule was obtained. Growth was rapid in the newborn hosts, and three were killed after 31 days and their tumors transplanted anew. Again much material was saved frozen.

5th Generation, A and B.—In none of a large group of agoutis 35 days old did the tumor grow, nor in any of 47 sucklings of seven litters 3 days old. Five of the litters had received tumor material from two animals, implanted separately in the thighs (Chart 1).

The Vx3 cancer remained throughout a moderately anaplastic, metastasizing, squamous-cell carcinoma, showing no morphological sign of its derivation from a virus papilloma (Figs. 1 to 4). In its 1st, 2nd, and 3rd Generations it grew with extreme malignancy in most sucklings of the Dutch belted breed in which it had originated, quickly occupying the entire thighs, destroying the femurs almost wholly and attacking the backbone in hosts that lived long enough, metastasizing to the iliac nodes in some cases, and often killing within a few weeks. In agouti sucklings it "took" much less frequently and tended to regress (Chart 1). It failed in all adults, and though establishing itself in one half-grown Dutch belted rabbit out of many, regressed later. No sucklings of this stock were available for the 4th Generation, but the cancer did well in some day-old agoutis. Further transfer in the breed proved unsuccessful although a great number of 3 day old sucklings received the tumor.

Attempts to Procure a Causative Agent from the Vx3 Carcinoma

It seemed best in the initial tests to inoculate unfiltered tumor extracts, and to proceed to filtration, for the exclusion of tumor cells, only if the extracts produced cancers.

The domestic rabbits inoculated with the extracts in this and all subsequent tests had been recently acquired, were kept throughout in a room into which animals carrying virus paps. were never introduced, and were inoculated in another such. Sterilized clippers and sandpaper were used to bare the skin and scarify it, and every person taking part in the inoculations wore a sterilized gown and had hands previously well scrubbed with green soap. In all tests save the first with the Vx3 tumor each area receiving the inoculum had been rendered hyperplastic previously by repeated applications of turpentine, and immediately afterwards it was covered with a layer of paraffined gauze (11). This layer and the enveloping binders were not removed until the skin had healed. No bacterial infections complicated the issue.

The animals were kept for a minimum of 3 months after inoculation, a time well exceeding the greatest elapsing between the inoculation of domestic rabbits with the Shope virus and the appearance of paps.,—which in our long experience has been 49 days.

Test 1.—A 20 per cent extract was made of tumor material (Fig. 2) freshly procured from a suckling of the 1st Tumor Generation killed 42 days after implantation. The pale pink tissue was ground with quartz sand and Tyrode solution, centrifuged at low speed, and the murky supernatant fluid was taken off with Wright's pipettes and rubbed into a large rectangle (5 by 9 cm.) of scarified normal skin on each side of six adult agouti rabbits. The inoculated area on one side was dried in a warm current of air, and that on the other

was covered with paraffined gauze while still moist. A binder and many-tailed bandage were put over all for the few days until healing had been completed.

The sole growth to arise was a single punctate pap., visible after 22 days on the paraffin-covered area of one animal (rabbit A). It grew big in later weeks, became gray with melanin, and the microscope showed it to be a typical Shope pap.

Test 2.—More of the same neoplastic tissue was used, but after it had been frozen at -14°C . for 58 days. Portions of the tumors from three other sucklings were extracted as well and tested separately. A litter mate of rabbit A of Test 1 furnished one material; it had been killed 43 days after implantation, and its tissue kept frozen 47 days. The other materials,—which had been frozen for 17 and 16 days respectively,—came from 2nd Generation sucklings killed 41 and 42 days after implantation. Cloudy supernatant fluids were inoculated from 20 per cent extracts prepared as before, but this time into skin previously rendered hyperplastic with turpentine. The four scarified areas (two on each side of six adult agoutis) measured 5 by 6 or 7 cm. and each was covered with paraffined gauze after the tumor extract had been rubbed in.

Again only a single punctate pap. was obtained. It appeared after 34 days but grew so slowly as to be only 1.5 cm. across 4 months later. It was black then, had bulging sides and a peak of vertically striated keratin, and the microscope showed it to be a typical Shope pap., like the growth of Test 1. The neoplastic tissue providing it had come from the litter mate of rabbit A, the animal which had furnished the extract producing the pap. of Test 1. The new extract of tissue from rabbit A now yielded no growth, nor did those from the sucklings of the 2nd Tumor Generation.

Test 3.—The extracted materials came from two sucklings of another litter of the 2nd Generation. Both animals were killed 31 days after implantation and the neoplastic tissue was frozen overnight prior to extraction. The supernatant fluids from centrifuged 20 per cent extracts were rubbed into large turpented areas on the sides of six adult agoutis, with paraffined-gauze coverage afterwards. No growths resulted.

Test 4.—Eight materials were extracted, from two rabbits of each of the four generations in which the tumor had flourished (Chart 1). The tissues had been frozen for 2 years or more, and because of repeated slight shifts in the temperature much of the water had left them, collecting on the sides of the sealed glass tubes. Some of the materials appeared almost dry, though still cream colored as at first. Fortunately they had all been weighed prior to storage, and now enough double distilled water was added to each to restore its weight; grinding was done; and 25 per cent extracts were made in Tyrode solution and briefly centrifuged as usual. The resulting, markedly opalescent, supernatant fluids were inoculated into turpented, scarified areas ranging in size from 7 by 8 cm. to 9 by 10 cm. on the sides of 12 extra-large agouti rabbits. Every animal had had four prepared areas to a side, and six inoculations were made of every extract, each into a different rabbit, with immediate paraffined-gauze coverage afterwards. The uninoculated areas were utilized for tests in another relation which need not here be gone into. After 11 days the healed skin had regained a nearly normal appearance, and now the paintings with turpentine were renewed on two-thirds of each inoculated expanse, to maintain the epidermal hyperplasia and thus encourage the proliferation of any hidden neoplastic cells (15). The limits of the areas thus treated were marked with tattoo spots of India ink and the paintings were kept up until the animals were discarded.

On one of the six expanses receiving the extract from a tumor of the 2nd Generation A, a punctate pap. arose between the 39th and 49th days, appearing on that part of the expanse which had been turpented again. Tissue from the same growth had yielded negative results in Test 2, but the cutaneous hyperplasia of the inoculated areas had been allowed to lapse after healing had taken place. The material which now yielded a pap. (excised after 66 days of slow growth and found typical of the Shope virus) had been frozen for 2 years

and 19 days, and had lost three-fourths of its weight through drying. No other growths were got.

The results of the four tests are recorded in Chart 1. + standing alone means that an extract of fresh tissue had yielded a growth. F+ or F- means extract of frozen tissue yielded one growth or none, as the case might be. T = hyperplasia of the scarified area maintained with turpentine after the inoculation.

Transplantation of the Vx3 Carcinoma

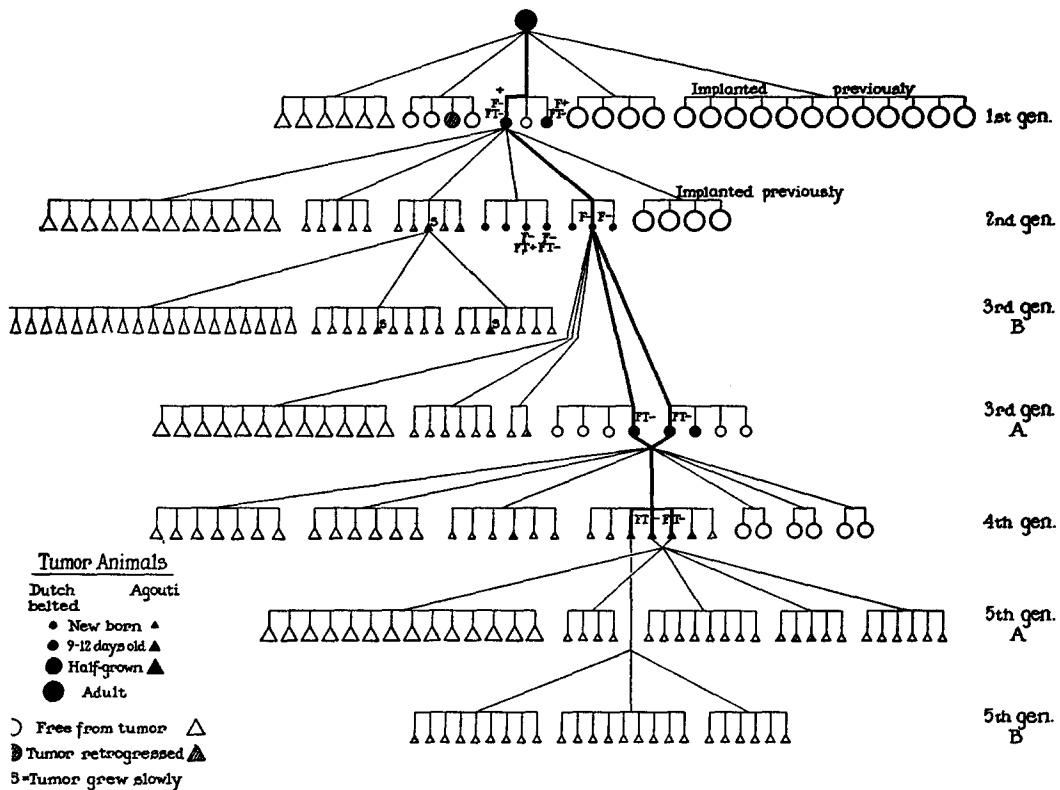


CHART 1

The conditions in these tests appeared notably favorable to the demonstration of a virus. The cancerous tissue contained but little blood when any, as shown by the fact that none of the extracts (20 and 25 per cent) was tinted with hemoglobin, and they were so briefly centrifuged prior to inoculation as to be still turbid or cloudy. They were rubbed on very large, scarified areas, and in most instances these had been treated in ways which had been found to further infection with the papilloma virus. And indeed papillomas arose in three of the four tests, in each case a solitary growth on one animal, punctate as if it had arisen through the infection of a single cell. Just such solitary,

occasional growths are frequently the sole outcome of inoculating extracts of papillomas produced by recoverable strains of the Shope virus in domestic rabbits (10). The malignant tissue from each of the two sucklings carrying the cancer in its 1st Generation yielded a papilloma when first tested, though not on subsequent test, and so did that of a 2nd Generation animal, although the material had been kept frozen more than 2 years prior to extraction, had lost three-fourths of its weight by drying,⁴ and had proved innocuous when first tested after only 17 days of storage.

The efforts made in each successive test to render the cutaneous conditions more favorable to virus demonstration would seem to have been rewarding. The papilloma of Test 1 arose on an area that had healed under paraffined gauze after inoculation, none developing on the opposite area, which had received the same inoculum but had then been allowed to dry and scab. In Test 2, which also yielded a growth, the skin was not only kept covered after inoculation but had been rendered hyperplastic beforehand. The papilloma of Test 4 arose where this hyperplasia had been maintained with turpentine after healing was completed, not on the rest of the same inoculated expanse where it had been allowed to lapse.

The Vx4 Carcinoma

The next malignant growth to be transferred was widely different. It was of a kind not infrequently arising, which appears to be the outcome of an exceedingly slight alteration in the papilloma cells. Several such tumors have been described and figured in previous papers (2, 16), but none has differed so little as the Vx4 from the growths which the Shope virus directly causes.

The Dutch belted rabbit providing the Vx4 had been inoculated on the side with an extract containing recoverable virus W. R. 1-27 (10). The resulting jagged expanse of pap. tissue was wholly replaced, between the 5th and 7th months, by a discoid, fleshy, ulcerating mass having the gross aspect of a cancer. Long subcutaneous prongs extended from it toward the axillary and inguinal regions, and a metastasis soon appeared in an axillary gland, a nodule 1.5 cm. across developing in the 9th month. It was excised and found to be a thick-walled cyst containing soft, necrotic material that could be readily wiped away from a fleshy lining of irregular, low papillae. A slice was fixed and the rest hashed and implanted in the leg muscles of the host. The implants in the legs grew fast and had formed football-shaped nodules 2 to 3 cm. in length when the rabbit was killed after 22 days.

The main growth, now 10 cm. across, was ulcerated and foul, save for a raised, fleshy ring with the overlying skin attached, which was capped with some residual pap. tissue along its posterior side. The subcutaneous prong extending from it toward the inguinal region was 5 cm. long and consisted microscopically of what appeared to be pap. tissue that had grown down through the dense corium and extended laterally along the draining lymphatics (Fig. 6). It was keratinizing like a virus pap. to form cysts (Figs. 7 and 8), and was orderly in arrangement save near its tip where small tongues were invading the adjacent reactive connective tissue (Fig. 9), as active Shope paps. sometimes do at the same situation.

⁴The ability of the Shope virus to retain its pathogenicity for many years under untoward conditions has been recognized by all workers with it.

The primary mass had been mostly destroyed by foul ulceration. Microscopically its remaining living tissue had the aspect of an actively invasive, keratinizing, squamous-cell carcinoma (Fig. 10), but its cells showed the peculiarities indicative of virus influence (17). The prong extending 3 cm. toward the axilla from the base of the ulcer had the same carcinomatous aspect near this latter, but further away became more and more like a Shope pap. and at its extreme tip (Fig. 11) wholly resembled such a pap. when following the lymphatics (2). Sections of the axillary nodule used for implantation in the legs showed what looked like invasive virus pap. tissue (Figs. 14 and 15), with the sole obvious difference from the ordinary that at some spots the cells were dying after partial differentiation instead of keratinizing. The axillary growth may well have derived from the prong.

Two spherical nodules, 2 and 1 cm. across, were found in the lungs. The larger was entirely keratinized save for a thin peripheral zone of what appeared to be virus pap. tissue devoid of papillae, and forming dense concentric layers of keratin (Fig. 16); and the same held true of the smaller except that its living tissue appeared somewhat more active. The implantation tumors in the legs consisted of multilocular cysts lined with what appeared to be Shope pap. tissue (Fig. 17), which was actively invading the abundant reactive tissue next it, like a squamous-cell carcinoma, and replacing the surrounding voluntary muscle (Fig. 18), with subsequent cyst formation. In many spots the differentiating cells were dying prior to keratinization (Figs. 17 and 19).

A suspension of minced tissue from the leg nodules was implanted in the forelegs and anterior and posterior thighs of six adult Dutch belted rabbits (in which it failed to grow) and in the anterior thighs of four agouti litters 6 or 7 days old. The 16 surviving animals of three of the litters failed to develop tumors, but growths quickly appeared in four out of seven individuals of the fourth litter and soon formed big masses. Two of the rabbits carrying them were killed after 31 days, when almost moribund, and a third after 53 days. This last animal weighed only 690 gm. as compared with 1385 and 1560 gm. for two negative litter mates; its tumors made up one-fifth of its weight. The huge growths, extending from spine to knee, had invaded the peritoneal wall, become attached to the spine, and one had produced a metastasis in an iliac node, which was still papillomatous in pattern (Fig. 20) but with cells no longer showing any morphological signs of the influence of the virus. In the fourth suckling the nodules retrogressed.

The tumor masses in the legs had big central cysts containing creamy, grumous material, and were thickly lined with neoplastic tissue showing an irregularly vertical striation, with more or less linear, opaque necroses,—markings suggestive of virus papillomatosis; and indeed microscopically the growth could not in many places have been told with certainty from a Shope pap. disordered along its invasive base and in many spots dying amidst a markedly inflamed connective tissue which was dying also (Figs. 21 and 22). But now at some spots the cells exhibited wide differences in size, shape, and capacity to stain, though at the same level of differentiation, and not a few had giant nuclei or were multinucleated, features which, taken together, marked them as malignant (1); and in the suckling host carrying the tumor for the longest time it had been superseded by a frank, squamous-cell carcinoma composed of elements that no longer showed any morphological sign of the influence of the virus.

Neoplastic tissue from the two animals killed after 31 days was hashed and implanted separately at the usual six sites in four agouti litters, of which two were 11 days old, the others 16 days, as also into ten agoutis 4 to 5 weeks old, 40 rabbits in all. In none did it grow.

In its primary host the Vx4 resembled a virus papilloma which had become malignant while retaining most, and in many places all, of its characteristic

cytological features (Figs. 6 to 11, 14 to 19, 21 and 22). More will be said of it further on. The tumor failed on transfer to adults of the inbred Dutch belted stock in which it had originated, but grew vigorously in four out of seven sucklings of a single 6-day-old litter of the same breed, metastasizing in one animal. No tumors arose in 16 individuals of three other litters of the same age. Efforts to propagate the growth further in older sucklings of agouti stock were unsuccessful. In the animals in which it did well after transplantation the Vx4 manifested cytological abnormalities not shown by ordinary virus papillomas and eventually it was supplanted in one instance by a squamous-cell carcinoma.

Attempts to Procure a Causative Agent from the Vx4 Tumor

Two tests were made to learn whether extracts of the Vx4 would produce the growth. The tissue utilized came from three of the four sucklings in which it had grown progressively.

The malignant tissue was pale pink in each instance. That taken for test was weighed, and then Locke's solution was forced through it everywhere with a fine needle in order to flush out any extravasated serum. This "needling" made it paler.

Test 1.—Portions of leg tumors from the three hosts, which had been stored after needling, at -12° to -14°C . for 53, 53, and 31 days respectively, were ground separately and 20 per cent extracts made. The supernatant fluids of a first brief centrifugation were withdrawn through Wright's pipettes of fine bore, and transferred to new centrifuge tubes after the pipette ends had been broken off above the level of immersion,—this in order to exclude any cells from the meniscus which might have adhered to the outside of the pipette as it passed through this latter. The same procedure was employed after a second brief centrifugation, also at low speed, and then the still-murky fluid was inoculated (with paraffined-gauze coverage afterwards) into large areas of hyperplastic skin on three agouti rabbits. Each animal had four such prepared areas on each side, and every extract was tested on its skin in duplicate or triplicate. No growths arose anywhere.

Test 2.—The same technical procedures were used but with two tissue materials only, procured from rabbits killed 31 and 53 days after implantation and stored frozen for 90 and 68 days respectively. The extracts (20 per cent) were inoculated as before into large areas of hyperplastic skin on the sides of two recently trapped, Western cottontail rabbits, with a paraffined-gauze dressing after. Cottontails were used because previous work had shown them to be somewhat more susceptible to inoculated Shope virus than domestic rabbits (18); but neither of those now employed developed growths during the next 3 months. Then they were inoculated with Shope virus to learn whether they might not have been immune to it, owing to infection while in the wild, and indeed one of them proved wholly resistant. The other developed paps. at all four inoculation sites.

Complement Fixation and Neutralization Tests with the Blood of Sucklings Carrying the Vx4

As already stated, rabbits carrying papillomas due to the Shope virus usually elaborate an antibody capable of specifically neutralizing the latter, and often in such strength as to render extracts of the growth innocuous. If the Vx4 tumor were due to a variant differing but slightly from the ordinary virus, as

the morphological findings in its case seemed to indicate, one might expect that it too would be affected. On this assumption tests were made to learn whether the suckling hosts of the Vx4 had formed a circulating antibody against the Shope virus. There was the more reason to make them because the Vx4 tissue extracted for inoculation had contained traces of blood, as shown by its pink hue.

The three sucklings carrying the Vx4 had been bled to death from the heart under ether anesthesia, and two of their negative litter mates as well. Complement fixation tests were carried out with the sera thus got, two reliable virus materials serving as antigens, and the sera of four adult rabbits with large paps. as controls. Two specimens of serum were available from tumor-bearing host No. 2, which lived the longer,—from bleedings 31 days after implantation, and at sacrifice on the 53rd day respectively. All were tested as “unknowns” by one of us (J. G. K.), according to a standard technique (18).

None of the normal sera or those from the young rabbits implanted with the Vx4 fixed complement at all (in serial dilutions from 1:2 to 1:32), whereas those from all of the adults carrying paps. did so strongly.

The neutralization test has a lower threshold for antiviral antibody than the complement fixation test (18), and hence resort was now had to it.

The test was made in the standard way (7) with what remained of the serum specimens. None was left from one suckling that had carried the tumor. Sera from six normal, adult agouti rabbits and from three carrying big paps. served as controls. Cottontail pap. tissue, long preserved in glycerin and known to yield virus, was twice washed in Locke's solution, a 1 per cent extract made by grinding it with sand, and the supernatant fluid from a first centrifugation was spun again at sufficiently high speed to render it water-clear. It was then drawn off through long needles, which were disconnected from the syringe while still submerged,—this in order to exclude any cellular debris present on the meniscus and adhering to the outside of the needle. The fluid thus obtained was then mixed in equal parts with the serum specimens; the mixtures were incubated for 2 hours at 38°C.; and inoculation done into large squares of hyperplastic skin on eight adult agouti rabbits. Each square, as inoculated, was covered with paraffined gauze. The later findings were recorded in terms of the following scale: \pm = 1 pap.; \pm = 2, 3, or 4 paps.; + = 5 to 15 paps.; ++ = many discrete growths, +++ = semiconfluent paps.; ++++ = confluent growth.

The results of the test are set forth in Table I. Each mixture was inoculated into only four of the eight test rabbits,—not in every case the same four, as the table makes clear; for all of the animals received specimens from other sources on some of their squares of skin. It follows that the findings cannot be directly compared in some instances. Nevertheless the table makes plain that the sera from both of the sucklings carrying the Vx4 had a very slight yet definite neutralizing effect on the virus, as shown by a brief delay in the appearance of papillomas and some reduction in their number. But it is noteworthy that the serum from the suckling which failed to develop any growths after implantation (No. 3) exhibited the same slight inhibiting power as the specimens from its litter mates with large tumors (Nos. 1 and 2). It is conceivable that a small

quantity of neutralizing antibody from the primary host of the Vx4 had been introduced into the sucklings with the numerous tumor fragments.

The Vx5 Carcinoma

The next tumor to be transplanted (the Vx5) was a markedly anaplastic, squamous-cell carcinoma which appeared after about 7 months in a confluent mass of papillomatous tissue due to the inoculation of a Dutch belted rabbit with virus W. R. 1-27. Many of the cancerous cells had multiple or giant nuclei or abnormal mitoses, and the generality died early. The growth was

Neutralization Tests with the S
(Papillomas arising in eight test rabbits inoculated)

Serum source	Rabbit				Tests rabbits								a	
	No.	Weight at death gm.	Days im- planted	Tumor size cm.	a	b	c	d	e	f	g	h		
Saline control					±	+++	+++	0	++++	+	±	++	+	-
Normal adults	66						+++	±	±	++				++
	67				++	++					0	0		++
	68				0	++					++	0		+
	69						+++	+	+++	+++				
	70							0	+	+++	++			
	71				+++	+					++	+++±		+++±
Sucklings (7 days old when im- planted)	1	380	31	5 5			0	0	++	++				
	2a		31	3 5			0	0	±	0				
	b	690	53	5 8	±	0					+	0		±
	3	1560	53	None			++±	0	±	0				
Adults with big papil- lomas	50				0	0					0	0		0
	59				0	0	0	0	0	0	0	0		0
	98						0	0	0	0				

transferred to 19 mongrel rabbits 2 days old of four litters coming from a black, a chinchilla, and two agouti mothers. In none did it "take."

The Vx6 Carcinoma

The Vx6 appeared on a Dutch belted rabbit amidst pap. tissue due to virus W. R. A, a strain which had previously proved recoverable. The nodules resulting from implantation of an axillary metastasis in the legs of the host grew so fast that after 27 days the animal was killed and transfer made to four litters of day-old mongrel agouti sucklings. The tumor succeeded in 3 of 10, 3 of 7, 5 of 5, and 4 of 4 respectively, forming such large masses within 23 days that it was then transferred to two 2-day-old agouti litters, growing fast in 2 of 5, and 5 of 5 individuals. It was carried no further.

Throughout its propagation the Vx6 was a moderately anaplastic, squamous-cell carcinoma (Fig. 5), exhibiting some cytological traits suggestive of the in-

fluence of the Shope virus; in other words its character was intermediate between that of the Vx4 and the Vx3. It grew even more rapidly in sucklings than the latter (Fig. 13), stunting them markedly (Fig. 12) as this had. By the 22nd day the rabbits in which it had done best were dragging their hind legs, because of bone destruction and nerve invasion, as later sections showed, and in the four that were killed between the 21st and 23rd days the thigh muscles and femurs had been almost totally replaced and in one instance the hip joint entered. Nevertheless the cancer did not metastasize during the few further weeks before sacrifice of the remaining animals.

its Carrying the Vx4 Carcinoma

arious mixtures. For meaning of symbols see text.)

19 days						22 days							
d	e	f	g	h		a	b	c	d	e	f	g	h
±	+±	++++	+±	+	++±	++	++++	++++	++	++++	+++	+	+++
·	+±	+±	++			+++	++++±	+++±	+±	++	+++		+++
				+	+±	+++	+++					+	+++
-	+±	+++	+++±			+++	+++	+++±	++	+++±	++++		+++
	+±	+++±	+++			+++	+++±	+++	+++±	++++	+++±		+++
				+++±	++++±	++++	++++±					+++	++++
	+±	+++	++					++	+±	+++±	+++		
	+	++	+					++	+±	++	++		
=	+	+±	++			+±	+±	+++±	++	++	++	++	+++
				0	0	0	±			±	±	0	0
	0	±	0	0	±	0	±	±?	0	±	0	±	±
	0	0	0			0	0	0	0	±	0		

Tests for a Causative Agent in the Vx6 Carcinoma

The failure to recover papilloma virus from the papillomatous Vx4 tumor, when taken with the fact that the serum of sucklings implanted with the tumor had a slight neutralizing effect on the virus, made it seem advisable to wash out all blood from the Vx6 tissue prior to extraction for test. A method was accordingly devised.

The young animals providing the neoplastic tissue were etherized and exsanguinated by cardiac aspiration; the aorta was swiftly cannulated just above the diaphragm; the coeliac axis, superior mesenteric artery, and renal vessels were tied off; and perfusion was begun with sterile Locke's solution under gravity pressure. A clamp was then put on the inferior vena cava just below the liver, the vein was slit open a little lower down, and as the fluid returning from the hind legs flowed forth these were repeatedly flexed and extended and

the tumors gently kneaded until the perfusate no longer came away blood-tinged. Now the skin of the thighs, previously clipped free of hair, was swabbed with an alcoholic solution of iodine and laid back; the lower end of each femur in turn was seized with a tenaculum forceps; the joint disconnected; and, with the bone held vertically, the tumors were dissected out of the muscles. Cyst formation had barely begun in them.

The huge growths of four sucklings, killed 21 to 23 days after implantation, were thus washed, with result that the neoplastic tissue appeared in most cases creamy as if wholly free from blood, though faintly pink in some instances. It was cut up, squeezed between sponges to force out plugs of necrotic tissue and any extravasated fluid, and stored at -12° to -14°C. , the material from each animal separately. After 2 to 4 days 20 per cent extracts were made, the supernatant fluid of a first slow centrifugation was withdrawn through a long needle (immediately disconnected as in the case of the Vx4) and this procedure was repeated after it had been spun again. The markedly opalescent fluids thus procured were inoculated into big hyperplastic areas on each side of six large adult rabbits, with paraffin coverage after. No growths resulted.

The conditions in this test seemed wholly favorable to demonstration of the papilloma virus or any near variant of it. The suckling hosts had had little more than 3 weeks at most in which to elaborate antibodies, and the neoplastic tissue extracted looked wholly free from blood in some instances, virtually free in others, while furthermore steps had been taken to rid it of any extravasated fluid. Nevertheless it proved innocuous.

A second test, to be recorded in a succeeding paper, was made with the tissue after it had been stored nearly 2 years in the cold. The particulate matter contained in extracts made then was concentrated by high speed centrifugation and inoculated, again with a negative outcome. But a sufficient reason why the Shope virus, at least, had not been demonstrable in either test was soon forthcoming. Experiments made at the time of the first test, but in another connection, with the virus material used to produce the papilloma from which the Vx6 derived, showed that though still producing active growths it had ceased to be recoverable from these.

A complement fixation test was carried out with the sera of the sucklings yielding the Vx6 for first extraction, and specimens from five other rabbits of the 1st and 2nd Generations were included in it. The test was done soon after the sera from these last were procured.

The pap. virus served as antigen, together with two extracts of the Vx2 cancer, known through previous test (by J. G. K.) to contain the antigenic substance peculiar to that growth. Six of the sucklings had big Vx6 tumors, the others none or but the tiniest, and they were bled 17 to 23 days after implantation. Sera from two adult rabbits hyperimmunized against the pap. virus (19) and from two others carrying large Vx2 tumors served as controls. Those of the first sort fixed complement strongly on test with the virus, and those of the second did so with the Vx2 antigen, whereas the specimens from the sucklings failed of any fixation whatever.

DISCUSSION

The fact that sucklings serve better than old animals as hosts for transplanted neoplasms has been known since 1908 when workers at the Imperial

Cancer Institute of England made this discovery (20), rather to their own surprise since they had taken the increased incidence of spontaneous tumors in ageing individuals to mean that these would prove the more favorable. A multitude of later papers have confirmed their findings, and embryos were found to be uniquely favorable (21).

Three out of four of the cancers of the present work flourished after transfer to suckling rabbits. An effort was made to establish one of them permanently, the Vx3, an anaplastic, squamous-cell carcinoma, but after it had been propagated in four successive groups of sucklings it was lost for lack of favorable hosts.

Chart 1 discloses that the loss of the Vx3 was determined by a genetic factor. In its 2nd Generation the tumor fared far better in sucklings of the inbred Dutch belted stock in which it had arisen than in mongrel agoutis of the same age, and in the 3rd Generation it succeeded in 11-day-old Dutch belted animals as not in 4-day-old agoutis. The only very young rabbits available for the 4th Generation were agoutis, and it did well in some of a day-old litter, as not in litters 7, 10, and 12 days old; but further transfer in this breed failed although a large number of sucklings 3 days old were implanted (Chart 1).

The Vx4, which also arose in a Dutch belted rabbit, grew on first transfer in only one of four mongrel agouti litters 6 to 7 days old, doing well in four of its seven individuals; but it could not be carried further in agoutis 11 and 16 days old. The Vx6, likewise of Dutch belted origin, grew fast in a considerable proportion of two successive groups of newborn agoutis, and was not carried further. The failure of the Vx5 to grow after transfer may have been due to the utilization of sucklings differing in breed from the original host, but more likely to the unhealthy nature of the growth; its cells, though proliferating actively, were extremely pathological and died soon. Mouse carcinomas of which this holds true often fail after transfer, even to individuals of the homogeneous strain in which they originated (22). The disordered, yet rapidly multiplying cells of such tumors may be unable to survive the metabolic deprivations following immediately upon transplantation.

Character of the Transplanted Cancers

The malignant growths which succeeded on transfer differed widely. The anaplastic Vx3 had a general resemblance to the Vx2,—though the latter became wholly anaplastic only after propagation in several successive hosts; and its aggressive destructiveness in newborn rabbits was even greater than that of this tumor, as implantations of the Vx2 in its 57th Generation have made plain.⁵ The Vx2 does not attack the femurs of such animals, whereas the Vx3 destroyed all except their ends within a few weeks, and frequently flourished in

⁵ Unpublished work of Dr. Stanfield Rogers.

the subcutaneous tissue along the track of the injecting needle, soon forming ulcerated discoid growths (Fig. 1) as very rarely happens with the Vx2.

The nature and significance of the Vx4 demand close consideration.

In its original host the tumor had the aspect in most regions of a mere virus papilloma of exceptional aggressiveness. This was notably true of the axillary and pulmonary metastases (Figs. 14 to 16) and of the long prong extending toward the inguinal region from the primary mass (Figs. 6 to 9). Such prong extensions of virus papillomas, with similar apical invasion, have been repeatedly noted previously (Figs. 7, 10, and 27 of reference 2), the growth in one instance reaching a lymph gland by direct extension and entirely replacing it. Pulmonary nodules like the metastases of the Vx4 have occasionally been found at autopsy of domestic rabbits carrying cutaneous virus papillomas which had been cut into or traumatized in other ways (2); and similar ones have been obtained experimentally by the intravenous injection of small clumps of papilloma cells, sections of the resulting nodules as they developed showing them to be consequent on the survival and proliferation of these artificial emboli (2).⁶

Implanted virus papilloma tissue, when it becomes infected with bacteria, not infrequently simulates the carcinomatous, invading the reactive connective tissue that forms about it and even replacing striated muscle fibers individually (23). Such a state of affairs might be invoked to account for the disorder and malignant activities present along the base of the ulcerated portion of the primary Vx4, as also in the prong extending from it toward the axilla (Figs. 10 and 11), and the nodules due to implantation in the legs of the host (Figs. 17-19);⁷ and it will account as well for the premature necrosis overtaking the tumor cells in sucklings. Yet though the malignant activities at these situations may have been largely factitious (2) good reasons exist to conclude that the Vx4 was the outcome of a truly carcinomatous alteration in the papilloma which preceded it. It arose from this latter only after months, as is always the case with the derivative cancers, and it had the appearance in the gross of a new neoplastic entity, destroying and replacing the ordinary papilloma tissue round about it, and ulcerating and spontaneously metastasizing. Also after transfer to sucklings it soon underwent cytological changes which further distinguished it as malignant, and in its 2nd Generation of such hosts it became a frank squamous-cell carcinoma. Its great interest lies in the fact that it was expressive of what one might term the least deviation of a virus papilloma from type that results in malignancy. No deviations of benign sort have been reported by any of the many workers studying the papilloma.

The Vx6 carcinoma requires no special notice because it was a manifest squamous-cell carcinoma, though exhibiting many morphological signs of the influence of the Shope virus. Growths of its sort frequently derive from the papillomas caused by this agent.

⁶ Pulmonary epithelium itself is not susceptible to infection with the Shope virus (23).

⁷ Wholly similar activities, under circumstances of bacterial infection, have recently been observed in virus papillomas successfully transplanted to other rabbits. (Rogers, S., *J. Exp. Med.*, in press.)

Appraisal of the Tests for Causative Agents

Earlier pages have made plain that if the cancers eventually deriving from the papillomas caused by the Shope virus are due to variants of the latter one might expect these variants now and again to be recoverable from the malignant growths. The conditions obtaining in the experiment here described have seemed to favor such recovery in several respects. The fact has been recognized ever since Metchnikoff's experiments with tetanus toxin on alligators (24) that young animals react to antigens much less effectively than adults.⁸ The cancerous tissue was procured in the present instance from sucklings only a few weeks old, and it was almost or quite blood-free. These circumstances weighed against the possibility that a presumptive virus would be neutralized by blood antibodies present in the tumor extracts under test. The inoculated skin had in most instances been rendered hyperplastic beforehand, and it was kept covered afterwards with paraffined gauze until it had healed, steps which greatly increase the liability to infection with the papilloma virus and presumably would favor that with cancer-producing variants. Most of the extracts were made with but little fluid, to minimize the effects of dilution, and filtration was not done because this might have largely held back any virus entities present. The centrifugations were at such low speed, in all save the second test of the Vx6, that the development of an occasional cancer on the skin as result of the direct transfer of living cells to the raw expanse of corium had seemed not beyond possibility.⁹ But the grinding of the tissue had been thorough and no such tumors appeared.

The sole growths obtained were three punctate virus papillomas, each from a different extract of the Vx3 tumor. Whether they were due to accidental contamination of the inoculated areas despite the means taken to exclude this,—effective means as a long negative experience with extracts of the Vx2 had shown,—or to virus freed from the cancerous tissue by extraction, or to the transfer perhaps of papilloma cells persisting unseen amidst the malignant horde, is immaterial. For the whole aim of the tests had been to learn whether anything causing the cancers could be extracted from them. And nothing was got.

The Vx3 carcinoma yielding the extracts that produced the papillomas showed no morphological sign of the influence of the Shope virus and seemed *a priori* the least likely to yield this agent of the three tumors tested; but it should be pointed out that the Vx2, also a squamous-cell carcinoma and equally anaplastic, carried during its growth in more than twenty successive

⁸ Freund has shown that 1- and 2-day-old rabbits form agglutinins only slowly and in relatively low titer against foreign erythrocytes. (Freund, J., *J. Immunol.*, 1930, 18, 315).

⁹ Fragments of the Flexner-Jobling rat carcinoma readily establish themselves when strewn on raw corium dressed with paraffined gauze. (Rous, P., *J. Exp. Med.*, 1913, 17, 494.)

groups of animals an antigen which regularly elicited the antibody indicative of the presence of the Shope virus (8, 25) or some nearly related entity.¹⁰

The Vx4 offered large promise of positive findings because it had all the appearance of a papilloma turned malignant while retaining the distinctive cytology of a growth due to the Shope virus. Yet none of the extracts made of it yielded any growth, although the strain of virus used to produce the papilloma from which it derived proved readily recoverable both before and afterwards in collateral tests, and although its implantation in suckling hosts resulted in only a negligible amount of antibody directed against the Shope virus. The Vx6 had also been produced with a strain of virus that had previously been recoverable (strain W. R. A); and it too had many traits bespeaking the influence of this agent, though it did not resemble a Shope papilloma so closely. The conditions under which its tissue was tested appeared ideal, yet no growths resulted. But concurrent tests of papillomas produced in other connections with strain W. R. A showed it to have ceased to be recoverable, and hence the negative findings with the Vx6 cancer must be written off. The nature of the "masking" of virus that so often occurs in the papillomas induced therewith in domestic rabbits is a riddle that bulks larger than ever.

Further experiments are under way with other carcinomas propagated in newborn rabbits.

SUMMARY

Three out of four carcinomas arising from virus-induced, rabbit papillomas have grown well after transplantation to sucklings. Two were propagated serially, and it seems likely that all could have been maintained indefinitely had litters been available of newborn animals of the sort in which they arose. These successes are the more worthy of note because of the well-nigh uniform failure of similar growths on transfer to adults. The tumors enlarged with great rapidity in the sucklings, were extraordinarily destructive, and two of them metastasized within a few weeks.

Many efforts were made to extract causative agents from the three carcinomas, on the assumption that these might be due to variants of the Shope virus. Highly favorable conditions for the demonstration of this latter were provided in the tests; yet their outcome was wholly negative although all of the cancers derived from papillomas caused by "recoverable" strains of virus, and although one of them appeared to be consequent upon only the slightest of alterations toward malignancy on the part of the papilloma from which it came. Extracts of another of the cancers, an anaplastic, squamous-cell carcinoma devoid of any morphological sign of the influence of the Shope virus, yielded typical virus papillomas on several occasions. The wholly negative

¹⁰ Extracts of the Vx2 procured during this period proved innocuous though tested in many, highly various ways.

results with the third cancer must be considered in the light of the fact that the "recoverable" strain of virus causing the papilloma from which it originated could no longer be recovered from such growths on collateral test.

BIBLIOGRAPHY

1. Rous, P., and Beard, J. W., *J. Exp. Med.*, 1935, **62**, 523.
2. Rous, P., Beard, J. W., and Kidd, J. G., *J. Exp. Med.*, 1936, **64**, 401.
3. Kidd, J. G., and Rous, P., *J. Exp. Med.*, 1940, **71**, 469.
4. Smith, W. E., Kidd, J. G., and Rous, P., *Acta Unio Internat. Cancrum*, 1948, **6**, 231.
5. Kidd, J. G., *J. Exp. Med.*, 1939, **70**, 583.
6. Friedewald, W. F., *J. Exp. Med.*, 1940, **72**, 175.
7. Kidd, J. G., Beard, J. W., and Rous, P., *J. Exp. Med.*, 1936, **64**, 79.
8. Kidd, J. G., and Rous, P., *J. Exp. Med.*, 1940, **71**, 813.
9. Friedewald, W. F., *J. Exp. Med.*, 1942, **75**, 197.
10. Friedewald, W. F., and Kidd, J. G., *J. Exp. Med.*, 1944, **79**, 591.
11. Friedewald, W. F., *J. Exp. Med.*, 1944, **80**, 65.
12. Shope, R. E., *J. Exp. Med.*, 1933, **58**, 607.
13. Kidd, J. G., Beard, J. W., and Rous, P., *J. Exp. Med.*, 1936, **64**, 63.
14. Shope, R. E., *Proc. Soc. Exp. Biol. and Med.*, 1935, **32**, 830.
15. Rous, P., and Kidd, J. G., *J. Exp. Med.*, 1941, **73**, 365.
16. Rous, P., and Friedewald, W. F., *J. Exp. Med.*, 1944, **79**, 511.
17. Hirst, E. W., *J. Exp. Med.*, 1933, **58**, 610. Rous, P., and Kidd, J. G., *J. Exp. Med.*, 1939, **69**, 399.
18. Kidd, J. G., *J. Exp. Med.*, 1938, **68**, 703, 725, 737.
19. Shope, R. E., *J. Exp. Med.*, 1937, **65**, 219.
20. Bashford, E. F., Murray, J. A., Haaland, M., and Bowen, W. H., Imperial Cancer Research Fund, 1908, 3rd Rep., 265.
21. Rous, P., and Murphy, J. B., *J. Am. Med. Assn.*, 1911, **56**, 741. Murphy, J. B., and Rous, P., *J. Exp. Med.*, 1912, **15**, 119. Murphy, J. B., *J. Am. Med. Assn.*, 1912, **59**, 874.
22. Rous, P., and Smith, W. E., *J. Exp. Med.*, 1945, **81**, 597, 621.
23. Rous, P., and Beard, J. W., *J. Exp. Med.*, 1934, **60**, 701.
24. Metchnikoff, E., *Ann. Inst. Pasteur*, 1897, **11**, 801.
25. Kidd, J. G., *J. Exp. Med.*, 1942, **75**, 7.

EXPLANATION OF PLATES

The photomicrographs were made by Mr. Joseph B. Haulenbeek and Mr. Julian A. Carlile.

PLATE 24

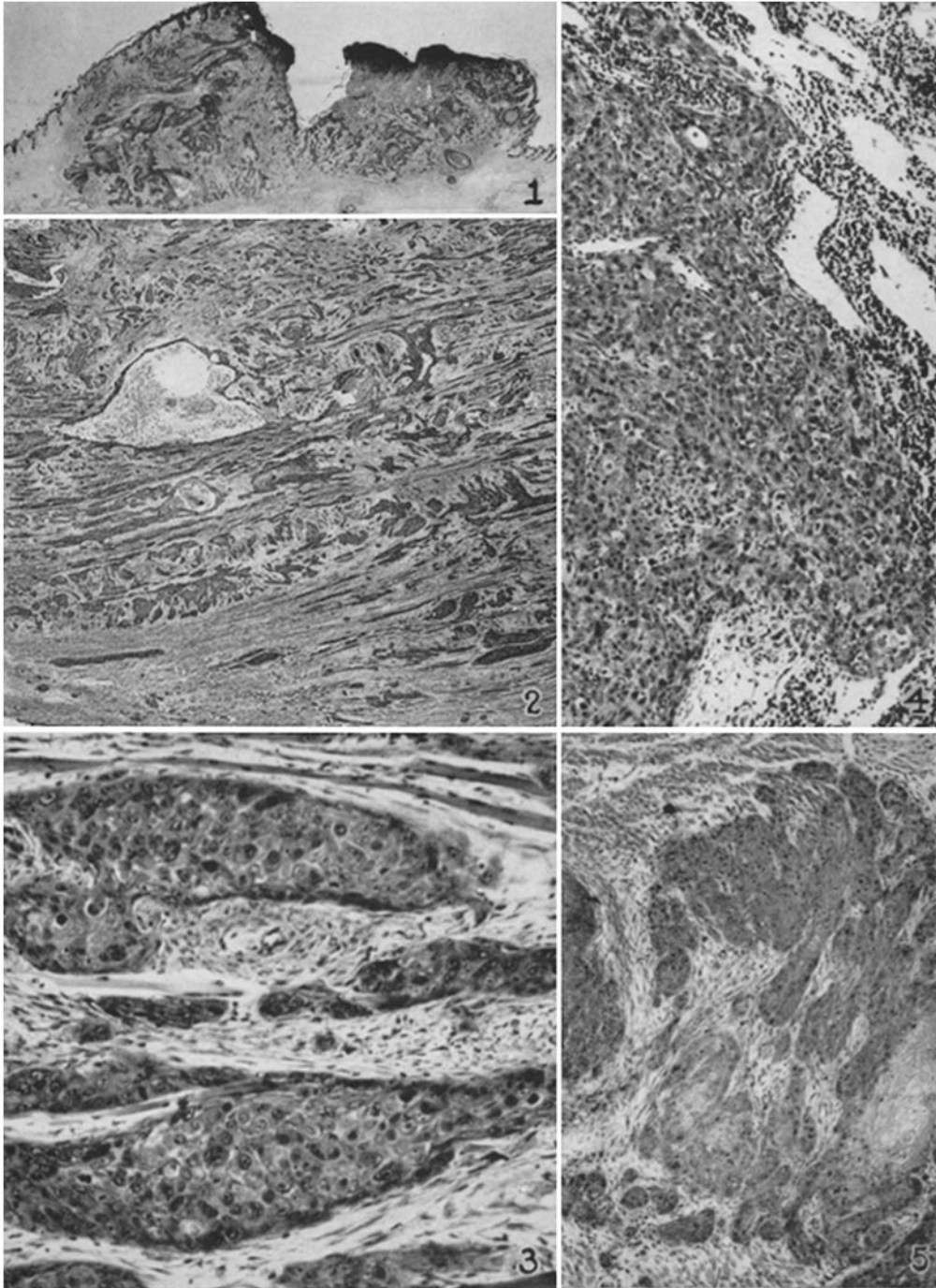
FIG. 1. Proliferation of the Vx3 carcinoma where the needle used in implanting a suckling had passed through the skin; animal of the 1st Gen., 9 days old when implanted, and killed 32 days later. The tumor is a squamous-cell carcinoma, now ulcerated. An extract of the intramuscular growths of the animal gave rise to a virus papilloma on inoculation (Test 1). $\times 5\frac{1}{2}$.

FIG. 2. The Vx3 growing in the leg muscle of another rabbit of the same litter, killed 42 days after implantation. The carcinoma is desmoplastic, exceedingly invasive, and has begun to undergo central necrosis with result in cysts. The section lies in the plane of the muscle fibers, which had been replaced individually in many instances. An extract of the growth yielded a virus papilloma (Test 2). $\times 11$.

FIG. 3. The same tumor at higher magnification. Its cells are notably large and markedly abnormal, showing few signs of differentiation and none of the influence of the papilloma virus. They are replacing the few atrophic muscle fibers remaining amidst a desmoplastic connective tissue. $\times 143$.

FIG. 4. Metastasis in an iliac node of the animal providing Figs. 2 and 3. Here the growth appears to be a carcinoma solidum. $\times 89$.

FIG. 5. The Vx6 growing in the leg muscles of a rabbit of the 1st Gen., implanted when newborn and killed 54 days later. $\times 71$.



(Smith *et al.*: Tests of cancers derived from virus papillomas. I)

PLATE 25

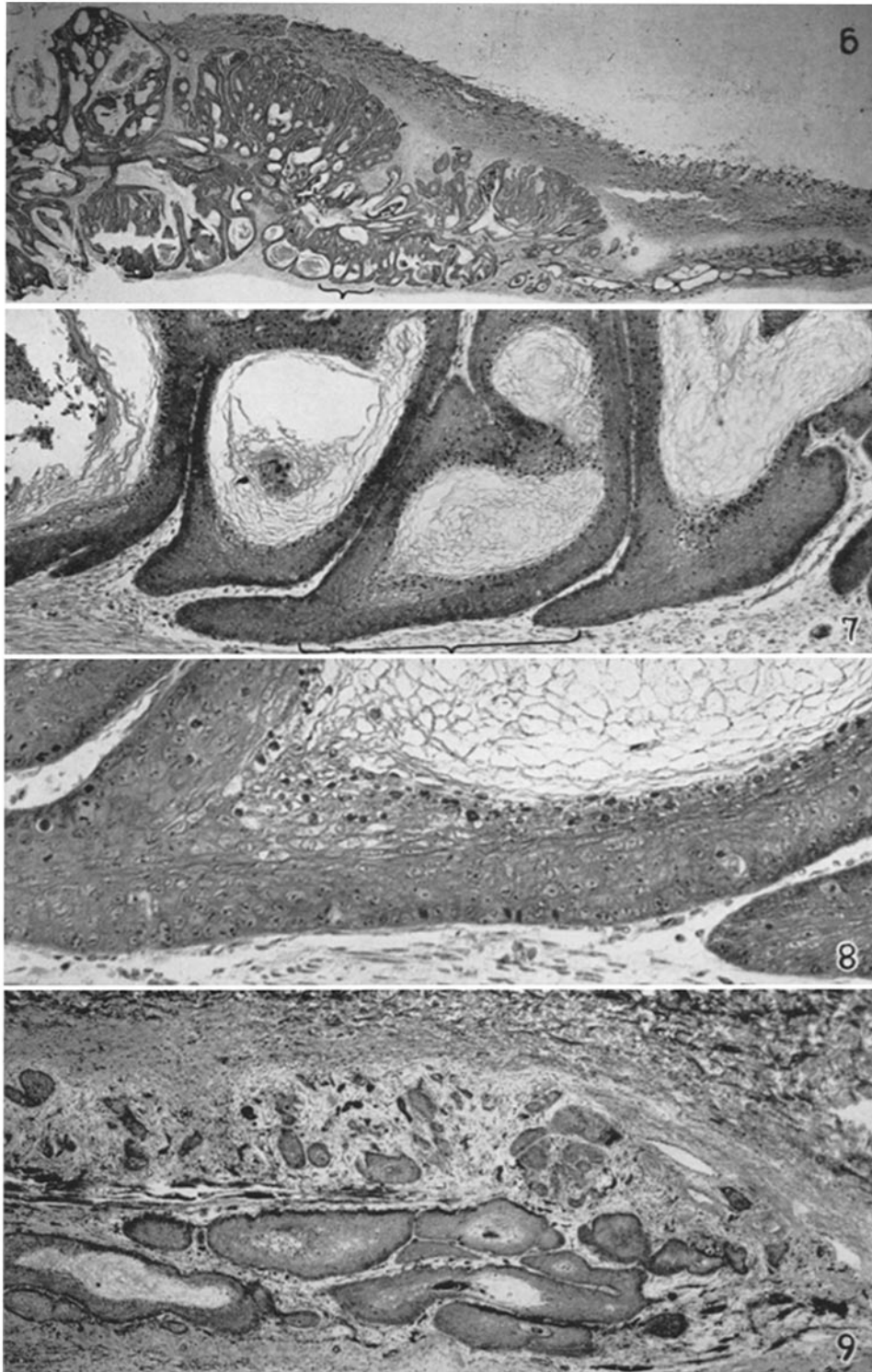
FIG. 6. Prong extending toward the inguinal region from the main mass of the Vx4 tumor. Its connection with this latter has been cut away inadvertently (top left-hand corner of the picture).

What looks like ordinary papilloma tissue has grown down through the dense corium and extended laterally along the lymphatics in the underlying, loose connective tissue. The growth is orderly everywhere save toward its tip, but here it is invading the reactive tissue in thin tongues. $\times 5\frac{1}{5}$.

FIG. 7. Section through the region bracketed in Fig. 6, to show the differentiation characteristic of virus papilloma tissue, and its orderly character. $\times 76$.

FIG. 8. Bracketed portion of Fig. 7 at higher magnification. The growth has the cytology typical of a virus papilloma. $\times 226$.

FIG. 9. Tip of the prong of Figs. 6, 7, and 8, to show invasion of the enveloping desmoplastic tissue. Dense corium overlies the growth. (Figs. 7, 10, and 27 of reference 2 show similar activities on the part of an aggressive virus papilloma.) $\times 35$.



(Smith *et al.*: Tests of cancers derived from virus papillomas. I)

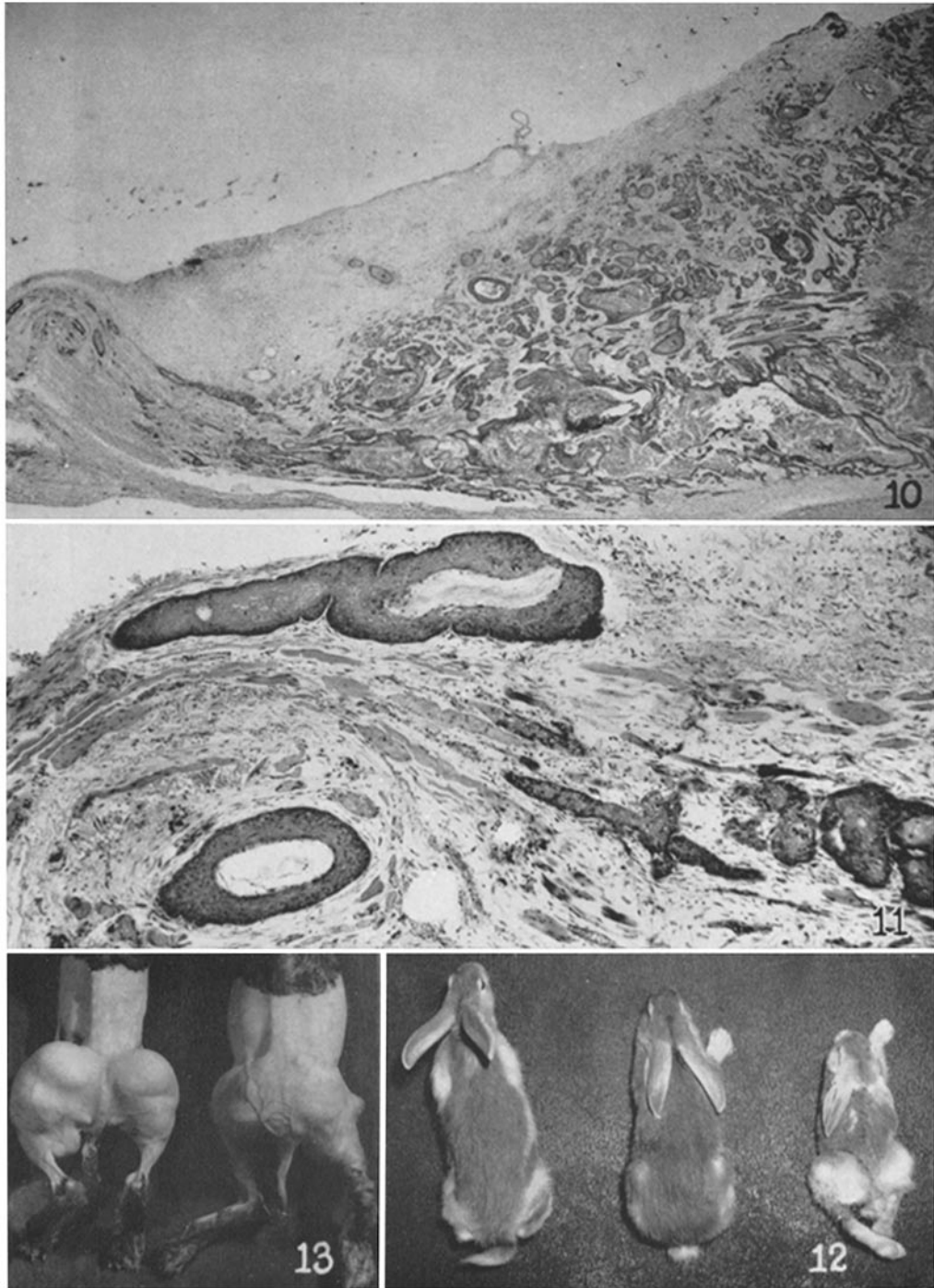
PLATE 26

FIG. 10. Prong extending toward the axilla from the ulcerated portion of the Vx4 tumor; the overlying skin has been cut away. The edge of the ulcer is at the extreme right where necrotic tissue can be seen, and more of this latter is present amidst the tumor almost all the way to the tip of the prong,—which has been bent in fixation. Most of the living tissue is disorderly, with cells dying prior to keratinization. At the low magnification shown, the growth looks like a carcinoma. $\times 9\frac{3}{10}$.

FIG. 11. Tip of the axillary prong. What appears to be keratinizing virus papilloma tissue has extended along the lymphatics, and invaded the desmoplastic tissue round about it and the adjacent voluntary muscle. (For similar activities of ordinary virus papillomas see Figs. 7, 9 to 11, and 27 of reference 2). $\times 62$.

FIG. 12. Stunting effect of the Vx6 carcinoma. The 1st Gen. animal on the right had been implanted 44 days previously, and its thighs are now wholly occupied by tumors. It was still active, though dragging its hind legs. It weighed only 375 gm. as compared with 1050 and 1060 gm. for the two litter mates shown with it. $\times \frac{1}{5}$.

FIG. 13. The Vx6 carcinoma in two hosts of the 1st Gen., killed 35 days after implantation. The growths had destroyed the hip joints in the animal on the left and nearly all of its femurs. A subcutaneous nodule, which had arisen in the track of the implantation needle, can be seen in profile on the outer side of the thigh of the animal on the right. $\times \frac{1}{2}$.



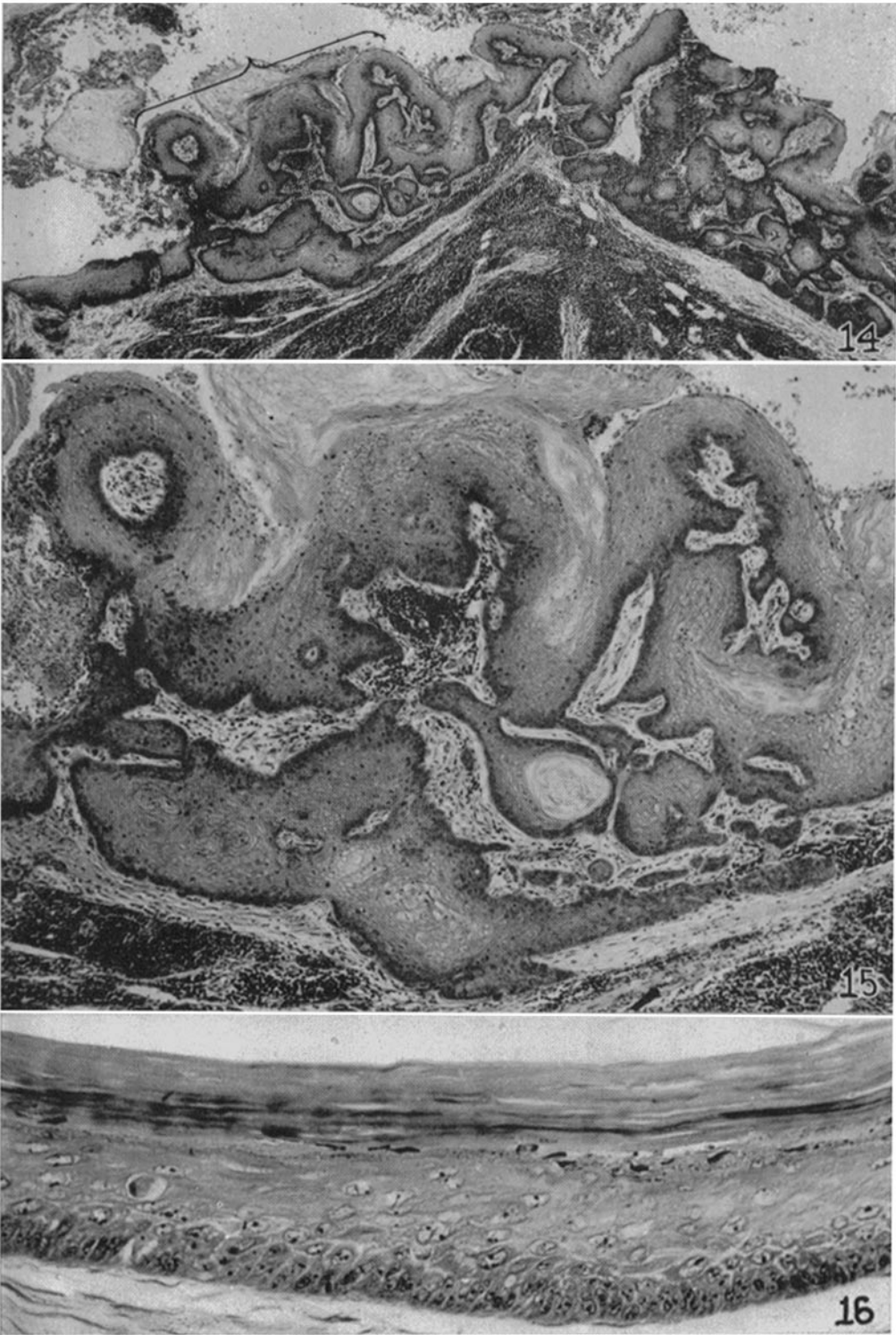
(Smith *et al.*: Tests of cancers derived from virus papillomas. I)

PLATE 27

FIG. 14. Part of the cystic metastasis in an axillary lymph node, which furnished material for the initial transfer of the Vx4. The section shows some of the remaining lymphoid tissue and the wall of the cyst, which is lined with disorderly and invasive papillomatous tissue, keratinizing in some spots and in others dying early and desquamating. $\times 28$.

FIG. 15. The bracketed region of Fig. 14 at higher magnification; the invading growth has the cytological features characteristic of virus papilloma tissue, and it is everywhere keratinizing in the ordinary way save at the extreme left where its cells are necrosing. $\times 76$.

FIG. 16. Wall of the larger pulmonary metastasis. The layer of living tissue enclosing concentric layers of keratin is obviously proliferating under pressure and hence forming no papillae. Its cells have the aspect of those infected with the Shope virus. $\times 294$.



(Smith *et al.*: Tests of cancers derived from virus papillomas. I)

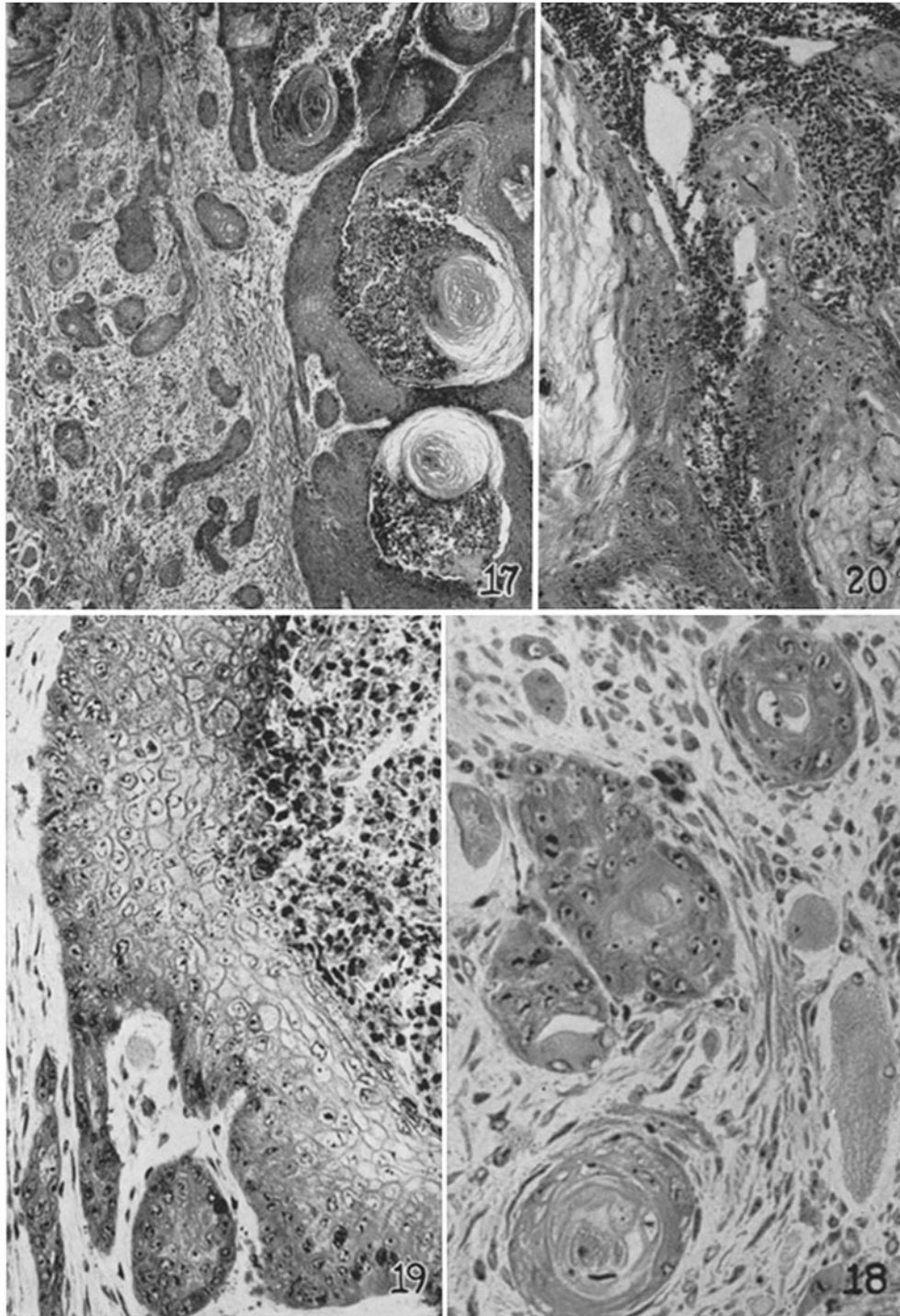
PLATE 28

FIG. 17. Periphery of a nodule of Vx4 tissue, resulting from implantation in the thigh muscles of bits of the axillary metastasis of Figs. 14 and 15. The growth lies amidst edematous reactive tissue and is extending out into this in narrow tongues. (The findings are like those at the advancing tips of the axillary and inguinal prongs, Figs. 9 and 11.) $\times 61$.

FIG. 18. Replacement of muscle fibers individually by the growth pictured in Figs. 17 and 19. (For similar activities of an ordinary virus papilloma, see Figs. 19 to 21 of reference 23.) $\times 342$.

FIG. 19. Higher magnification of the wall of one of the cysts shown in Fig. 17. The tumor cells are like those of an ordinary virus papilloma but in the region pictured are dying prior to keratinization. $\times 240$.

FIG. 20. The Vx4 in a suckling of the 1st Gen., Litter A, killed 31 days after implantation; metastasis in an iliac node. Its cells are much less like those of a virus papilloma, though still papillomatous in arrangement. $\times 56$.

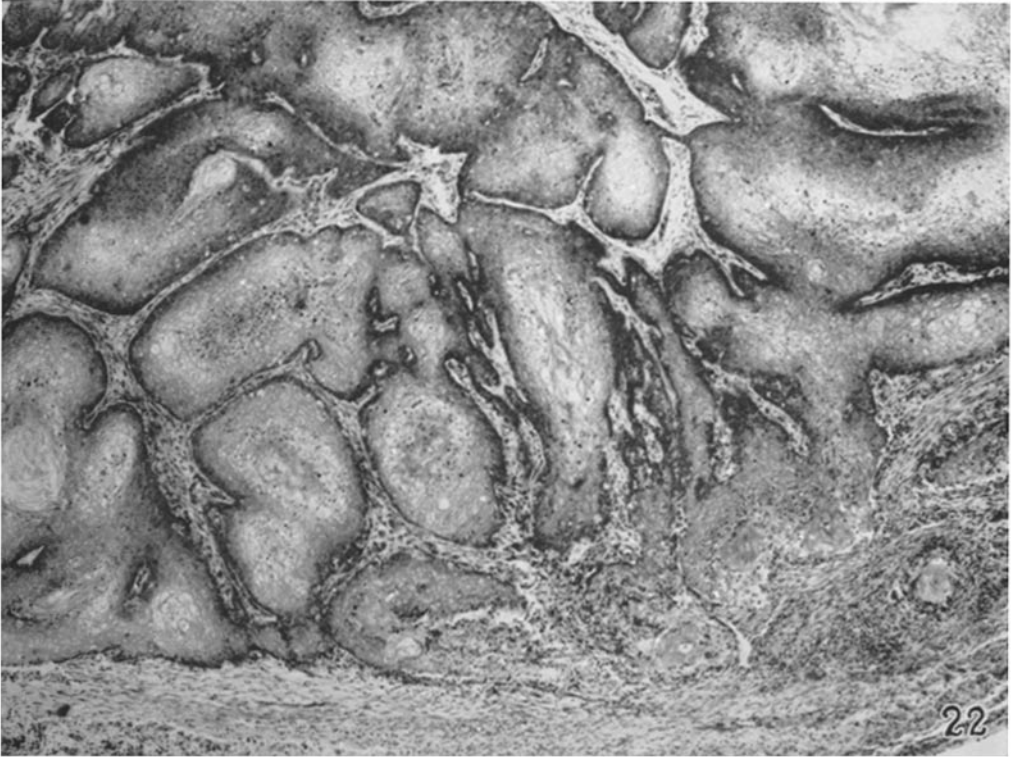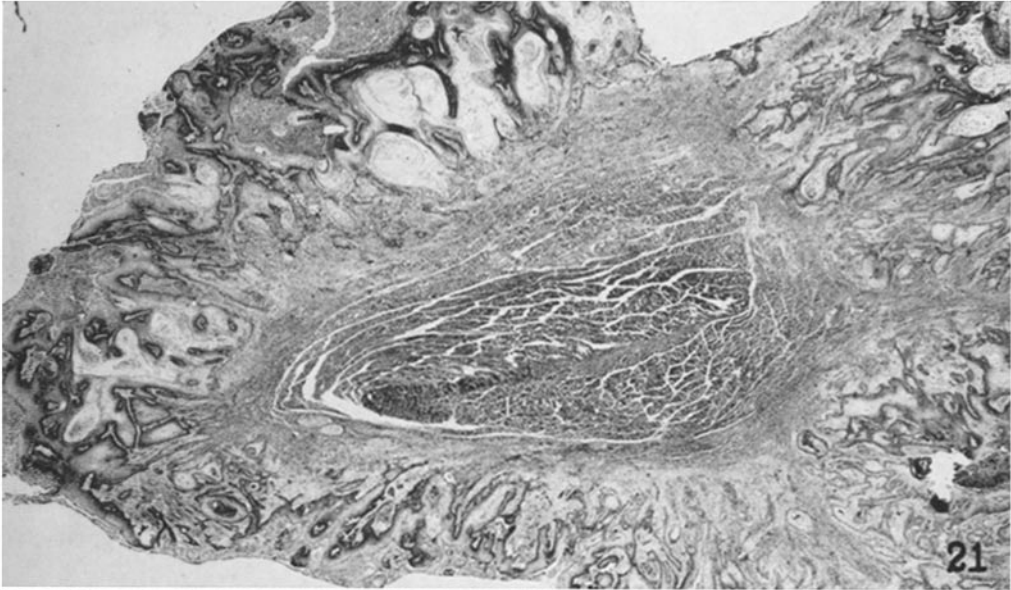


(Smith *et al.*: Tests of cancers derived from virus papillomas. I)

PLATE 29

FIG. 21. The Vx4 tumor in the thigh of another suckling of the 1st Gen., killed after the same length of time. Part of the wall of a large central cyst is shown, which had ramified and surrounded a mass of voluntary muscle. The cyst was 5 cm. across. The tissue lining it resembles that of the axillary metastasis in the primary host (Figs. 14 and 15), save that it is dying at many places along its base. $\times 12\frac{1}{2}$.

FIG. 22. Basal portion of another part of the cyst wall at higher magnification. The reactive connective tissue on the right is inflamed and dying together with the tumor, whereas on the left both are doing well. The growth has the cytology of a virus papilloma. $\times 53$.



(Smith *et al.*: Tests of cancers derived from virus papillomas. I)