

Spontaneous internal hemorrhage of a giant hepatic hemangioma with infection: a case report and literature review

Journal of International Medical Research

48(12) 1–8


© The Author(s) 2020

Article reuse guidelines:

sagepub.com/journals-permissions

DOI: 10.1177/0300060520976474

journals.sagepub.com/home/imr

Ankang Wang^{1,2,*} , Hao Chen^{1,*},
Zhiwei Huang¹, Hong Tang³, Hao Shi¹,
Jian Wen¹, Qiu Li¹, Yu Jiang¹ and
Wenguang Fu¹

Abstract

Spontaneous internal hemorrhage from a hepatic hemangioma is rare. This case describes a 59-year-old woman who was hospitalized with recurrent cough and fever for 6 months. The doctor thought that she had pneumonia, but other infectious diseases could not be ruled out. Therefore, related tests were performed and strong antibiotics were used, but the symptom of fever was persistent and recurred. Enhanced computed tomography (CT) findings showed a right hepatic giant hemangioma with hemorrhage, while tuberculosis, liver abscess, and immune disease were excluded by the physician. Because the patient's fever was associated with a large hepatic hemangioma, the patient was transferred to surgery. During treatment, the amount of bleeding increased, so she underwent a right hepatic hemangioma resection in the emergency department. Her postoperative fever symptoms subsequently resolved. Pathological examination confirmed hemorrhagic necrosis with infection in hepatic hemangioma. Follow-up showed that the patient was afebrile.

¹Department of Hepatobiliary Surgery, The Affiliated Hospital of Southwest Medical University, Sichuan, China

²Department of General Surgery, Nanchong Central Hospital, The second Clinical College of North Sichuan Medical College, Nanchong, Sichuan, China

³Department of Pathology, The Affiliated Hospital of Southwest Medical University, Sichuan, China

*Ankang Wang and Hao Chen contributed equally to this work and should be considered as co-first authors.

Corresponding author:

Wenguang Fu, Department of Hepatobiliary Surgery, The Affiliated Hospital of Southwest Medical University, Luzhou, Sichuan Province 646000, China.

Email: fuwg@swmu.edu.cn



Keywords

Hepatic hemangioma, spontaneous internal hemorrhage, fever, hemorrhagic necrosis, benign mesenchymal tumor, infection

Date received: 25 June 2020; accepted: 4 November 2020

Introduction

Hepatic hemangioma is the most common benign mesenchymal tumor with an estimated prevalence of 0.4% to 20%, and it is usually found by chance on computed tomography (CT) scan or ultrasonography during examinations for upper abdominal organs.^{1,2} Most hepatic hemangiomas are small in size and asymptomatic, and they are especially prevalent in women. Their growth may be affected by changes in female hormones.^{3–5} Lesions larger than 4 cm have been defined as giant hemangiomas, which can trigger complications such as abdominal pain, bloating, nausea, vomiting, jaundice, and spontaneous or traumatic rupture.^{6–9} There are few reports of spontaneous internal hemorrhage in hepatic hemangioma,^{10–13} and it is even rarer to have fever of unknown origin.¹⁰ In this context, we report a case of spontaneous internal hemorrhage with infection in a patient with a giant hepatic hemangioma, and we also reviewed the literature.

Case presentation

A 59-year-old woman was admitted to our hospital for treatment in July 2019 due to “recurrent cough and sputum accompanied by fever for 6 months and symptom aggravation for 3 months”. There was a small amount of white mucus sputum, but no blood in the sputum. The patient’s body temperature was intermittently elevated up to 40°C, and this was occasionally accompanied by night sweats that were

independent of chills and diurnal changes. During the period of onset, the patient lost 5 kg in body weight. The patient had no history of hypertension, diabetes, cardiovascular and cerebrovascular diseases, hepatitis, tuberculosis, malaria, surgery, trauma, abdominal discomfort, dysuria, joint pain, or other diseases. She had gone through menopause at age 50 years. An abdominal examination was performed, but no mass was touched. A chest CT showed thickening of the bronchial wall in the left upper lobe and dilatation of the left upper lobe, and it also showed mass flaky shadows in the right liver lobe (Figure 1a). After admission, the laboratory assessment showed a hemoglobin (Hb) level of 104 g/L (normal range: 115–150 g/L), a platelet count (PLT) of 376,000/mm³ (normal range: 125,000–350,000/mm³), a white blood cell (WBC) count of 15.71 × 10⁹/L (normal range: 4–10 × 10⁹/L), an erythrocyte sedimentation rate (ESR) of 90 mm/hour (normal range: 0–26 mm/hour), and a C-reactive protein (CRP) level of 40.05 mg/L (normal range: 0–5 mg/L). Biochemical assays revealed the following: an alkaline phosphatase (ALP) level of 187.4 U/L (normal range: 50–135 U/L), a gamma-glutamyltransferase (γ-GT) level of 209.3 U/L (normal range: 7–45 U/L), and a serum albumin (ALB) level of 39.1 g/L (normal range: 40–55 g/L). Levels of alanine aminotransaminase (ALT), aspartate aminotransferase (AST), and total bilirubin (TBIL) were within the normal range.

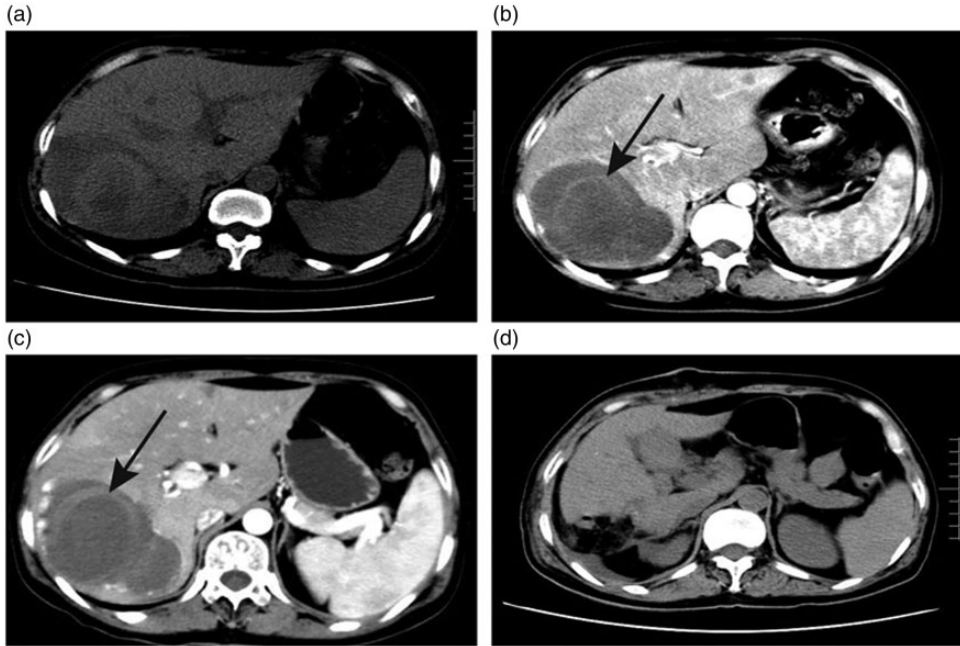


Figure 1. a. On admission, chest CT scan revealed a mass flake shadow of the right liver lobe. b. The first abdominal augmentation CT examination showed that the right liver lobe had a circular mixed density mass of about 10×9 cm, which had a clear boundary and contained a ring-shaped, strip-like slightly high-density shadow (shown by a white arrow). c. After 2 weeks, the high-density hemorrhage foci in the lesion increased compared with 2 weeks before. d. A postoperative CT scan showed a small amount of effusion. CT, computed tomography.

The abdominal enhanced CT scan revealed a $9 \times 6.6 \times 10$ -cm round mass with significant edge enhancement, mixed density, and a relatively clear boundary, which originated from the right liver lobe. The possibility of hemangioma accompanied by bleeding was considered (Figure 1b). Physicians did not rule out causes of fever such as pulmonary infection, tuberculosis, immune diseases, liver abscesses, or liver cancer with infection. Therefore, the sputum smear, repeated examination of acid-fast bacilli, routine fecal tests, routine urine tests, lymphocyte immune typing, sputum culture, myocardial injury markers, examination before blood transfusion, blood culture, alpha-fetoprotein (AFP), and other tests were

performed, but these tests showed normal results. During treatment, meropenem and other broad-spectrum antibiotics were used. Fortunately, the patient's temperature dropped slightly (fluctuated between 37.6 and 38.6°C), but her fever did not disappear. After ruling out the above diagnosis, the doctor believed that the fever was related to internal bleeding of the hepatic hemangioma. Therefore, the patient was transferred to surgery. Re-examination of the patient's abdominal CT (the interval was 2 weeks) and routine blood examination revealed an increase in internal bleeding in the right liver mass (Figure 1c), and the Hb level decreased to 87 g/L; however, the patient did not have gastrointestinal bleeding such as hematemesis and bloody

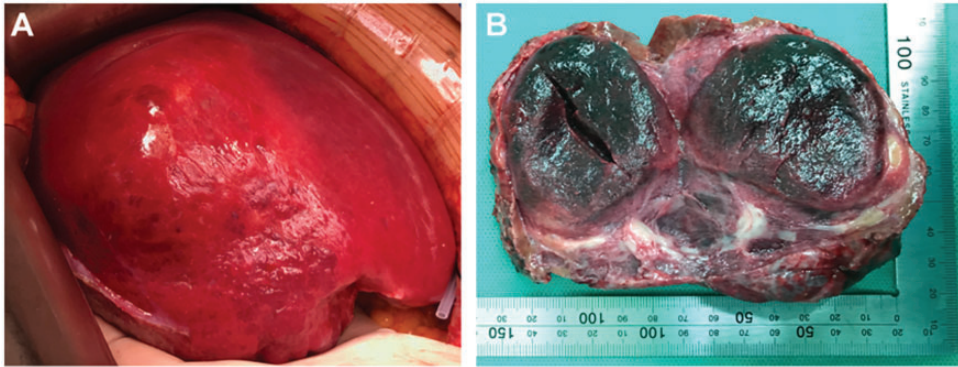


Figure 2. a. A well-encapsulated right hepatic hemangioma was observed during surgery. b. Cross-sectional examination of the mass revealed areas of necrosis within the hemangioma.

stool. The right hepatic hemangioma was excised in the emergency department after the surgeon considered that the patient's internal hemangioma bleeding was still increasing and might rupture. Intraoperatively, hemangioma was found to be located in the posterior lobe of the right liver; it had a diameter of about 10cm and a prominent surface with clear boundaries from the surrounding tissues (Figure 2a). Cross-sectional examination of the mass revealed areas of necrosis within a hemangioma (Figure 2b). Histopathological reports confirmed a cavernous hemangioma of the liver. Hematoxylin–eosin (H&E) staining of the tissue showed hemorrhage and necrosis, accompanied by a large amount of inflammatory cell infiltration (Figure 3a–d). There were no postoperative complications such as bleeding, bile leakage, or liver or kidney failure. The recurrent fever that was present before surgery resolved, and the patient was discharged from the hospital on day 10 after surgery. Follow-up showed that the patient was afebrile, and there was a small amount of effusion visible on the CT scan (Figure 1d). The patient provided consent to publish the details of this case.

Discussion

Cavernous hemangiomas are the second most common cause of liver tumors after metastatic cancer, and they are the most common benign liver tumor.^{1,14} They are reported to have a prevalence of 7.3% on autopsy.¹⁵ In clinical practice, most cases of hepatic hemangioma rarely show symptoms, mainly because of their very slow growth patterns. However, when the hemangioma growth is quite large, some patients may have symptoms such as abdominal discomfort.¹⁶ Spontaneous rupture of a large hepatic hemangioma is not a common complication, but it is a serious event,^{17,18} and the surgical mortality rate for ruptured hemangioma is reported to be about 36.5%.¹⁹ Because of the occult clinical manifestations of hepatic hemangioma, its diagnosis relies more on an imaging examination. The sensitivity of ultrasound, CT, or magnetic resonance imaging (MRI) for diagnosing hepatic hemangioma is over 90%. In ultrasound examination, hemangioma usually presents as a homogeneous hyperechoic mass with relatively clear boundaries. However, when there is internal tumor bleeding, the hemangioma often present as an internal dense

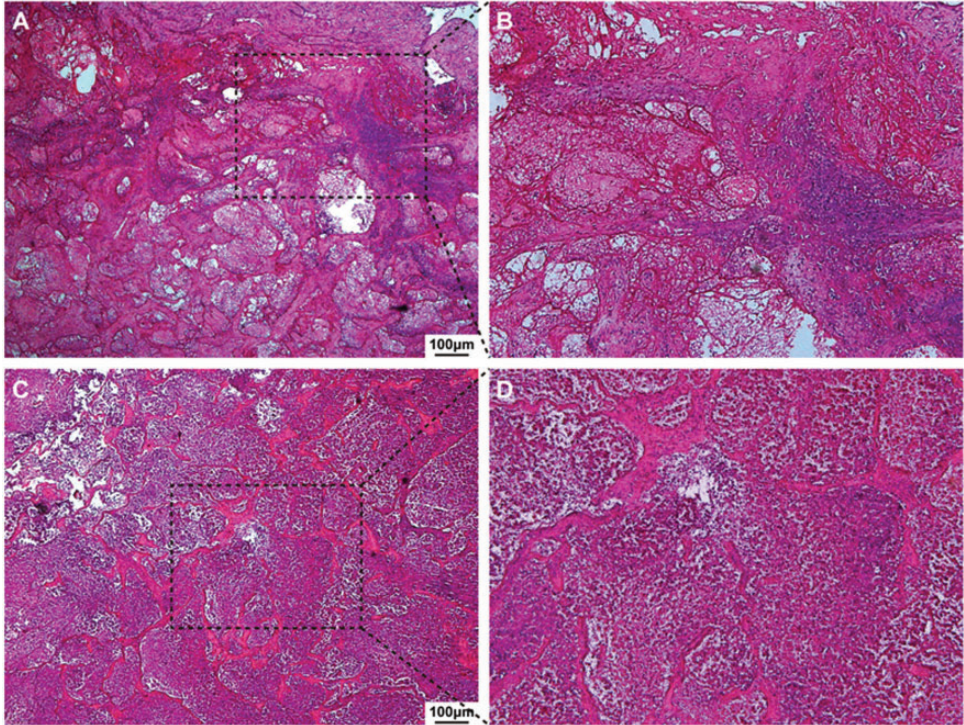


Figure 3. a. H&E staining, $\times 40$ and b. H&E staining, $\times 100$. Pathology demonstrated a cavernous hemangioma of the liver with hemorrhagic necrotic areas and inflammatory cell infiltration. c. H&E staining, $\times 40$ and d. H&E staining, $\times 100$. Numerous inflammatory cells infiltrated the cavernous hemangioma of the liver, and the hemangioma structure was destroyed. H&E, hematoxylin and eosin.

mass on CT imaging.^{11,20–22} In this case, we found a large hemangioma that was located in the posterior hepatic lobe using enhanced CT, and it contained high-density hemorrhagic foci.

Fever of unknown origin that is caused by hepatic hemangioma is an unusual presentation. We reviewed seven published reports of fever that was caused by giant hepatic hemangioma.^{10,23–27} Their characteristics and those of the current case report are summarized in Table 1. Most patients were female and the mass was located in the right liver lobe. Although the tumor size was not specifically described in three cases, it covered most of the left or right liver and was called a giant hemangioma. Six patients were

treated via surgery, and two were treated with antipyretic drugs or prednisone. For all patients, their body temperature returned to normal and they reached the clinical standard for a cure. Fever associated with hepatic hemangioma may be due to the release of endogenous pyrogens or an acute thrombosis and necrosis within the tumor, but rarely due to internal hemorrhage. Our patient's postoperative pathology showed hemorrhage and tumor necrosis, and a large number of inflammatory cells infiltrated into the tumor rather than around it. Therefore, we believe that the main cause of fever in this patient was post-necrotic inflammation, and bleeding and infection should also be taken into account.

Table 1. Review of liver hemangioma characteristics with the complication of unexplained fever.

Case No.	Gender	Age (years)	Size of hemangioma (diameter/ measurement method)	Location	Cause of fever	Management	Outcome	Reference
1	Female	37	5 cm/US	Right posterior segment	Uncertain	Antipyretic	Cured	27
2	Male	47	giant/CT	Right lobe	Thrombosis and necrosis	Resection	Cured	26
3	Male	44	giant/CT	Left lobe	Thrombosis and necrosis	Resection	Cured	26
4	Female	43	giant/US	Right lobe and Left lobe	Uncertain	Prednisone	Cured	25
5	Male	33	20 cm/US	Right lobe	Necrosis	Resection	Cured	24
6	Female	52	15 cm/US	Right lobe	Internal hemorrhage	interventional therapy and Resection	Cured	10
7	Female	49	15 cm/CT	Left lateral lobe	Necrosis	Resection	Cured	23
8	Female	59	10 cm/CT	Right posterior lobe	Infected necrosis and internal hemorrhage	Resection	Cured	Present case

US, ultrasound; CT, computed tomography.

Recognized indications for surgical treatment are mainly limited to hepatic hemangioma complications such as tumor rupture, internal hemorrhage, Kasabach–Meritt syndrome, and organ or vascular compression (e.g., limited gastric volume, Budd–Chiari syndrome).^{28–30} Schnellendorfer et al.³¹ summarized the case data from patients with hepatic hemangioma for 20 years and found that tumor size was not correlated with adverse events, health status, or quality of life between the surgery group and the observation group. They also found that even giant hepatic hemangiomas (>10 cm in diameter) were not correlated with an increased incidence of complications. Therefore, size cannot be the only indication for the surgical treatment of hepatic hemangioma. The patient's age, sex, occupation, and clinical symptoms should be comprehensively assessed, and the patient's safety should be the most important factor. In this case, internal

hemorrhage of the hepatic hemangioma combined with infection resulted in the increased body temperature, and CT examination and blood routine examination showed increased bleeding and decreased Hb. Therefore, after obtaining the patient's consent, we performed emergency surgery, and the infection symptoms and bleeding were subsequently resolved.

For fever with an unknown cause and a poor antibiotic treatment effect, the possibility of hepatic hemangioma with necrosis and infection was considered after excluding other common causes. Spontaneous intratumoral internal hemorrhage may be aggravated during treatment, so close attention should be paid to blood routine and imaging changes, and the patient should undergo surgery as early as possible.

Author contributions

All the authors participated in treating this patient. Ankan Wang, Hao Chen, and Zhiwei

Huang wrote the manuscript and provided the original images. Ankang Wang, Hong Tang, Hao Shi, and Jian Wen collected the clinical, radiological, and pathologic data. Qiu Li, Yu Jiang, and Wenguang Fu reviewed the manuscript.

Declaration of conflicting interest

The authors declare that there is no conflict of interest.

Funding

This research received no specific grant from any funding agency in the public, commercial, or not-for-profit sectors.

ORCID iD

Ankang Wang  <https://orcid.org/0000-0002-1349-2871>

References

- Choi BY and Nguyen MH. The diagnosis and management of benign hepatic tumors. *J Clin Gastroenterol* 2005; 39: 401–412.
- Ibanez VM, Zamora AS, Morote SC, et al. Pendulous hepatic hemangioma. *Surgery* 2017; 161: 1735–1736.
- Bara T Jr, Gurzu S, Jung I, et al. Giant cavernous hepatic hemangioma diagnosed incidentally in a perimenopausal obese female with endometrial adenocarcinoma: a case report. *Anticancer Res* 2016; 36: 769–772.
- El-Hashemite N, Walker V and Kwiatkowski DJ. Estrogen enhances whereas tamoxifen retards development of Tsc mouse liver hemangioma: a tumor related to renal angiomyolipoma and pulmonary lymphangioliomyomatosis. *Cancer Res* 2005; 65: 2474–2481.
- Van Malenstein H, Maleux G, Monbaliu D, et al. Giant liver hemangioma: the role of female sex hormones and treatment. *Eur J Gastroenterol Hepatol* 2011; 23: 438–443.
- Srivastava DN, Gandhi D, Seith A, et al. Transcatheter arterial embolization in the treatment of symptomatic cavernous hemangiomas of the liver: a prospective study. *Abdom Imaging* 2001; 26: 510–514.
- Giavroglou C, Economou H and Ioannidis I. Arterial embolization of giant hepatic hemangiomas. *Cardiovasc Intervent Radiol* 2003; 26: 92–96.
- Liu Y, Wei X, Wang K, et al. Enucleation versus anatomic resection for giant hepatic hemangioma: a meta-analysis. *Gastrointest Tumors* 2017; 3: 153–162.
- Abdel Wahab M, El Nakeeb A, Ali MA, et al. Surgical management of giant hepatic hemangioma: single center's experience with 144 patients. *J Gastrointest Surg* 2018; 22: 849–858.
- Hao F, Yang X, Tian Y, et al. Spontaneous internal hemorrhage of a giant hepatic hemangioma: a case report. *Medicine (Baltimore)* 2017; 96: e8702.
- Shimoji K, Shiraishi R, Kuwatsuru A, et al. Spontaneous subacute intratumoral hemorrhage of hepatic cavernous hemangioma. *Abdom Imaging* 2004; 29: 443–445.
- Feldman PA and Regev A. Atypical giant hepatic hemangiomas with intratumoral hemorrhage. *Clin Gastroenterol Hepatol* 2007; 5: A24.
- Kim JM, Chung WJ, Jang BK, et al. Hemorrhagic hemangioma in the liver: a case report. *World J Gastroenterol* 2015; 21: 7326–7330.
- Dima-Cozma LC, Bitere OR, Pantazescu AN, et al. Cavernous liver hemangioma complicated with spontaneous intratumoral hemorrhage: a case report and literature review. *Rom J Morphol Embryol* 2018; 59: 557–561.
- Ishak KG and Rabin L. Benign tumors of the liver. *Med Clin North Am* 1975; 59: 995–1013.
- Zhao W, Guo X and Dong J. Spontaneous rupture of hepatic hemangioma: a case report and literature review. *Int J Clin Exp Pathol* 2015; 8: 13426–13428.
- Doklestic K, Stefanovic B, Karamarkovic A, et al. Spontaneous rupture of giant liver hemangioma: case report. *Srp Arh Celok Lek* 2013; 141: 95–99.
- Cappellani A, Zanghi A, Di Vita M, et al. Spontaneous rupture of a giant hemangioma of the liver. *Ann Ital Chir* 2000; 71: 379–383.
- Jain V, Ramachandran V, Garg R, et al. Spontaneous rupture of a giant hepatic

- hemangioma - sequential management with transcatheter arterial embolization and resection. *Saudi J Gastroenterol* 2010; 16: 116–119.
20. Valette PJ, Pilleul F and Crombe-Ternamian A. MDCT of benign liver tumors and metastases. *Eur Radiol* 2003; 13: M31–M41.
 21. Ho HY, Wu TH, Yu MC, et al. Surgical management of giant hepatic hemangiomas: complications and review of the literature. *Chang Gung Med J* 2012; 35: 70–78.
 22. Toro A, Mahfouz AE, Ardiri A, et al. What is changing in indications and treatment of hepatic hemangiomas. A review. *Ann Hepatol* 2014; 13: 327–339.
 23. Pandit N, Awale L, Chaudhary S, et al. Fever of unknown origin: a rare presentation of giant hepatic hemangioma. *J Surg Case Rep* 2018; 2018: rjy143.
 24. Liu X, Yang Z, Tan H, et al. Fever of unknown origin caused by giant hepatic hemangioma. *J Gastrointest Surg* 2018; 22: 366–367.
 25. Fenster LF, Freeny PC and Beebe HG. Case reports. Cavernous hemangioma of the liver presenting with fever. Successful treatment with prednisone. *West J Med* 1978; 129: 138–140.
 26. Pateron D, Babany G, Belghiti J, et al. Giant hemangioma of the liver with pain, fever, and abnormal liver tests. Report of two cases. *Dig Dis Sci* 1991; 36: 524–527.
 27. Lee CW, Chung YH, Lee GC, et al. A case of giant hemangioma of the liver presenting with fever of unknown origin. *J Korean Med Sci* 1994; 9: 200–204.
 28. Terkivatan T, Vrijland WW, Den Hoed PT, et al. Size of lesion is not a criterion for resection during management of giant liver haemangioma. *Br J Surg* 2002; 89: 1240–1244.
 29. Van Rosmalen BV, Bieze M, Besselink MG, et al. Long-term outcomes of resection in patients with symptomatic benign liver tumours. *HPB (Oxford)* 2016; 18: 908–914.
 30. Brouwers MA, Peeters PM, De Jong KP, et al. Surgical treatment of giant haemangioma of the liver. *Br J Surg* 1997; 84: 314–316.
 31. Schnelldorfer T, Ware AL, Smoot R, et al. Management of giant hemangioma of the liver: resection versus observation. *J Am Coll Surg* 2010; 211: 724–730.