

# Cortical gray matter progression in idiopathic REM sleep behavior disorder and its relation to cognitive decline<sup>☆</sup>

A. Campabadal<sup>a,b,1</sup>, A. Inganzo<sup>a,b,1</sup>, B. Segura<sup>a,b,c</sup>, M. Serradell<sup>b,c,d</sup>, A. Abos<sup>a</sup>, C. Uribe<sup>a</sup>, C. Gaig<sup>b,c,d</sup>, J. Santamaria<sup>b,c,d</sup>, Y. Compta<sup>b,c,e</sup>, N. Bargallo<sup>f</sup>, C. Junque<sup>a,b,c,\*</sup>, A. Iranzo<sup>b,c,d</sup>

<sup>a</sup> Medical Psychology Unit, Department of Medicine, Institute of Neuroscience, University of Barcelona, Barcelona, Catalonia, Spain

<sup>b</sup> Institute of Biomedical Research August Pi i Sunyer (IDIBAPS), Barcelona, Catalonia, Spain

<sup>c</sup> Centro de Investigación Biomédica en Red sobre Enfermedades Neurodegenerativas (CIBERNED:CB06/05/0018-ISCI), Barcelona, Spain

<sup>d</sup> Sleep Disorders Center, Neurology Service, Hospital Clínic, Barcelona, Catalonia, Spain

<sup>e</sup> Parkinson's Disease & Movement Disorders Unit, Neurology Service, Hospital Clínic de Barcelona, Institute of Neuroscience, University of Barcelona, Barcelona, Catalonia, Spain

<sup>f</sup> Centre de Diagnòstic per la Imatge, Hospital Clínic, Barcelona, Catalonia, Spain

## ARTICLE INFO

### Keywords:

IRBD  
Cortical thickness  
Longitudinal data  
Visuospatial functions  
Parkinson's disease  
Olfactory dysfunction

## ABSTRACT

**Background:** Idiopathic Rapid eye movement sleep behavior disorder (IRBD) is recognized as the prodromal stage of the alpha-Synucleinopathies. Although some studies have addressed the characterization of brain structure in IRBD, little is known about its progression.

**Objective:** The present work aims at further characterizing gray matter progression throughout IRBD relative to normal aging and investigating how these changes are associated with cognitive decline.

**Methods:** Fourteen patients with polysomnography-confirmed IRBD and 18 age-matched healthy controls (HC) underwent neuropsychological, olfactory, motor, and T1-weighted MRI evaluation at baseline and follow-up. We compared the evolution of cortical thickness (CTh), subcortical volumes, smell, motor and cognitive performance in IRBD and HC after a mean of 1.6 years. FreeSurfer was used for CTh and volumetry preprocessing and analyses. The symmetrized percent of change (SPC) of the CTh was correlated with the SPC of motor and neuropsychological performance.

**Results:** IRBD and HC differed significantly in the cortical thinning progression in regions encompassing bilateral superior parietal and precuneus, the right cuneus, the left occipital pole and lateral orbitofrontal gyri (FWE corrected,  $p < 0.05$ ). The Visual form discrimination test showed worse progression in the IRBD relative to HC, that was associated with gray matter loss in the right superior parietal and the left precuneus. Increasing motor signs in IRBD were related to cortical thinning mainly involving frontal regions, and late-onset IRBD was associated with cortical thinning involving posterior areas (FWE corrected,  $p < 0.05$ ). Despite finding olfactory identification deficits in IRBD, results did not show decline over the disease course.

**Conclusion:** Progression in IRBD patients is characterized by parieto-occipital and orbitofrontal thinning and visuospatial loss. The cognitive decline in IRBD is associated with degeneration in parietal regions.

## 1. Introduction

There is growing evidence supporting that idiopathic Rapid eye movement (REM) sleep behavior disorder (IRBD) is a prodromal symptom of alpha-Synucleinopathies such as Parkinson's disease (PD) and dementia with Lewy bodies (DLB) as well as multiple system atrophy. A recent multicentric study involving 1280 IRBD patients

found that the overall conversion rate to an overt neurodegenerative disease was 6.3% per year, with 73.5% converting after 12-year follow-up (Postuma et al., 2019).

To date, there is a considerable amount of neuroimaging research showing structural (Campabadal et al., 2019b; De Marzi et al., 2016; Ehrminger et al., 2016; Ellmore et al., 2010; Hanyu et al., 2012; Ohlhauser et al., 2019; Park et al., 2018; Pereira et al., 2019;

<sup>☆</sup> Under a Creative Commons license: <https://creativecommons.org/licenses/by-nc-nd/4.0/>

\* Corresponding author at: Medical Psychology Unit, Department of Medicine, University of Barcelona, Casanova 143 (08036), Barcelona, Spain.  
E-mail address: [cjunque@ub.edu](mailto:cjunque@ub.edu) (C. Junque).

<sup>1</sup> A. Campabadal and A. Inganzo contributed equally to the manuscript.

Pyatigorskaya et al., 2017; Rahayel et al., 2015; 2018a; 2018b; Scherfler et al., 2011; Unger et al., 2010) and functional (Byun et al., 2020; Campabadal et al., 2020; Dayan and Browner, 2017; Ellmore et al., 2013; Park et al., 2018; Rolinski et al., 2016) abnormalities in IRBD patients using MRI. Most importantly, owing to all these works, there is strong evidence that brain changes relate to cognitive impairment (Byun et al., 2020; Campabadal et al., 2020; Pereira et al., 2019; Rahayel et al., 2018b; Vendette et al., 2012) and olfactory loss (Campabadal et al., 2019a; Pereira et al., 2019; Rahayel et al., 2018b; Vendette et al., 2011). Nevertheless, few researchers have investigated how the disease progression affects brain structure and function, and how these changes are associated with cognitive decline. Previous longitudinal investigations have focused on metabolic prognostic biomarkers in IRBD. In this sense, reduced dopamine transporter binding in the striatum (Iranzo et al., 2017), increased hippocampal perfusion (Dang-Vu et al., 2012), abnormalities in PD related pattern expression (Holtbernd et al., 2014; Yoon et al., 2019), and hyperechogenicity of the substantia nigra (Iranzo et al., 2010) were found to be able to predict phenoconversion in IRBD patients. As for studies focused on structural progression, a recent work reported that IRBD patients that eventually convert to Lewy body disease had widespread thinning in the left superior frontal, right precentral and lateral occipital gyri compared to non-converters (Pereira et al., 2019). This study found that converters had widespread cortical loss in frontal, precentral and occipital regions compared to healthy controls (HC) (Pereira et al., 2019). However, the lack of MRI follow-up for the control group precludes to discard the aging effects on brain changes.

Within this framework, the objectives of the current work were (1) to address differential progressive cortical and subcortical degeneration between IRBD and normal aging, (2) to study the changes over time in cognitive functions in IRBD and their relationship with progressive cortical thinning. We hypothesized that both healthy individuals and IRBD patients would show an aging-related progressive decline, with larger degeneration in IRBD given that this parasomnia is considered part of the prodromal phase of the Synucleinopathies PD and DLB.

## 2. Material and methods

### 2.1. Participants

The study sample included 14 patients with IRBD and 18 healthy subjects who were evaluated at two different time-points by the same neuropsychologist using the same neuropsychological battery and MRI scanning protocol. Subjects were evaluated at baseline and after  $1.6 \pm 0.3$  years for patients and  $1.6 \pm 0.2$  years for controls of follow-up ( $U = 127$ ;  $p = 0.97$ ). All participants are part of a longitudinal cohort recruited between 2015 and 2017 (Campabadal et al., 2019b). IRBD patients were recruited from our sleep disorders center and none of them developed parkinsonism during the follow-up. Diagnosis of REM sleep behavior disorder (RBD) required a history of dream-enacting behaviors, video-polysomnographic demonstration of REM sleep without atonia, associated with abnormal behaviors, absence of motor complaints at the time of the recruitment, unremarkable neurological examination, normal brain magnetic resonance imaging and no temporal association between the estimated onset of RBD and the introduction or withdrawal of a medication (Boeve, 2010; Iranzo et al., 2006). At the time of the current study, eight patients were taking benzodiazepines to reduce RBD symptomatology. Healthy subjects did not show sleep disorders, cognitive or motor impairment and were recruited from the *Institut de l'Enveliment* (Barcelona, Spain).

Exclusion criteria for all participants were: [1] clinical evidence of movement disorder; [2] presence of psychiatric and/or neurologic comorbidity; [3] low global IQ score estimated by the Vocabulary subtest of the Wechsler Adult Intelligence Scale, 3rd edition (scalar score  $\leq 7$  points); [4] global cognitive impairment, Mini-Mental State Examination (MMSE) score  $< 25$ , [5] claustrophobia; and [6] MRI

movement artifacts.

The study was approved by the Ethics Committee of the University of Barcelona (IRB00003099) and Hospital Clinic (HCB/2014/0224). All subjects provided written informed consent to participate after full explanation of the procedures involved.

### 2.2. Neuropsychological assessment

Participants were evaluated with the same neuropsychological battery at both time points. One IRBD patient and one healthy control did not complete the neuropsychological assessment, and thus they were excluded from the analyses that concern these measures. Attention and working memory were assessed with the Trail Making Test (TMT, parts A and B) (in seconds), Digit Span Forward and Backward, the Stroop Color-word Test, and the Symbol Digits Modalities Test (SDMT)-Oral version. Executive functions were evaluated with phonemic (words beginning with the letter "p" in 1 min) and semantic (animals in 1 min) fluencies. Language was assessed by the total number of correct responses in the short version of the Boston Naming Test (BNT). In the memory domain, we assessed the Rey Auditory Verbal Learning Test total learning recall (sum of correct responses from trial I to trial V) (RAVLT). Visuospatial and visuo-perceptual (VS/VP) functions were assessed with Benton's Judgement of Line Orientation (BJLO), Visual Form Discrimination (VFD) and Facial Recognition (FRT) tests (Lezak, 2012).

Expected z scores adjusted for age, sex, and education for each test and each subject were calculated based on a multiple regression analysis performed in the HC group (Aarsland et al., 2009). As in a previous study (Segura et al., 2014), the presence of mild cognitive impairment (MCI) was established if the z-score for a given test was at least 1.5 lower than the expected score in at least two tests in one domain, or in at least one test per domain in at least two domains. Mild cognitive impairment was excluded only for the healthy individuals, but not for the patients since one of our aims was to study changes over time in cognitive functions in IRBD, as well as its relationship with cortical thinning. Furthermore, the presence of dementia was determined if MMSE score was below 25, or if there was cognitive impairment in more than one domain and impaired instrumental activities of daily living (IADL), as recommended by Dubois et al. (Dubois et al., 2007).

Neuropsychiatric symptomatology and instrumental activities of daily living were measured by means of Beck Depression Inventory II (BDI) (Beck and Steer1996), Starkstein's Apathy Scale (AS) (Starkstein et al., 1992), and the IADL scale.

### 2.3. MRI acquisition and preprocessing

MRI data were acquired with a 3T scanner (MAGNETOM Trio, Siemens, Germany) at both times. The scanning protocol included high-resolution 3-dimensional T1-weighted images acquired in the sagittal plane (TR = 2300 ms, TE = 2.98 ms, TI = 900 ms, 240 slices, FOV = 256 mm, 1-mm isotropic voxel) and an axial FLAIR sequence (TR = 9000 ms, TE = 96 ms).

Cross-sectional preprocessing was performed using the automated FreeSurfer stream (version 5.1; available at: <http://surfer.nmr.harvard.edu>). After processing each subject cross-sectionally, in order to perform the longitudinal analyses of the data, within-subject templates (Reuter and Fischl, 2011) and the corresponding longitudinal files were created for each time point and subject. Briefly, a template volume for each subject, using information from all of their time points, and an average image were created using robust, inverse, consistent registration (Reuter et al., 2010). All time points were constructed through unbiased mean images and later aligned. After registration and creation of the templates, images from all time points were mapped to the template location and averaged and processed with the default cross-sectional stream. The symmetrized percent change (SPC) was used for longitudinal analyses of cortical thickness. Cortical thickness SPC is the

rate in mm/year with respect to the average thickness [(Thickness at time point 1 – Thickness at time point 2)/Interval between assessments]/[0.5\*(Thickness at time point 1 + Thickness at time point 2)]. In aging or disease, SPC is expected to be negative in most regions (<https://surfer.nmr.mgh.harvard.edu/fswiki/LongitudinalTwoStageModel>).

Automated subcortical segmentation performed with FreeSurfer was used to estimate subcortical volumetry. The SPC of subcortical volumes was computed. Estimated Total Intracranial Volume (eTIV) was obtained to correct volumetric data for inter-individual differences in brain sizes. Between group differences were assessed in SPC volumetric data controlled by sex and eTIV.

#### 2.4. Olfactory assessment

Olfactory identification was assessed using the Spanish version of the University of Pennsylvania Smell Identification Test (UPSIT) (Doty et al., 1995). Specific exclusion criteria for the olfaction test were: [1] history of nasal bone fracture, [2] diagnosis of rhinitis or nasal polyps, and [3] upper respiratory tract infections in the two weeks prior to testing.

#### 2.5. Motor assessment

Presence of motor symptoms was evaluated using the International Parkinson and Movement Disorders Society Unified Parkinson's Disease Rating Scale motor section (MDS-UPDRS-III).

#### 2.6. Statistical analyses

Group differences between HC and IRBD at baseline were analyzed using Mann-Whitney's *U* test and chi-squared test. For longitudinal neuropsychological and olfactory variables, repeated measures general linear model was used to assess group differences over time in quantitative variables with sex as a covariate. Spearman's Rho correlations were used to investigate the relationship between cognitive, clinical and volumetric data.

Comparisons between groups in the cortical thickness SPC were performed using a vertex-by-vertex general linear model. Time effects in both groups and group-by-time interaction effects were computed, SPC was included as a dependent factor and group as an independent factor. Regression models included SPC as an independent factor and clinical or cognitive scores as dependent factors. Sex was introduced as a covariate in all analyses. Maps were smoothed using a circularly symmetric Gaussian kernel across the surface with a full width at half maximum of 15 mm. The vertex-wise cluster threshold was set at  $< 0.05$ . In order to avoid clusters appearing significant purely by chance (i.e., false positives), Monte Carlo null-Z simulation with 10,000 iterations was applied to cortical thickness maps to provide clusterwise correction for multiple comparisons. Simulation was applied for negative time effects (time 2 < time 1) in each group, on all other models, simulation was applied for absolute results. Results were thresholded at a corrected *p* value of 0.05.

### 3. Results

#### 3.1. Sociodemographic and clinical data

Sociodemographic and clinical data of participants are summarized in Table 1. No significant differences between groups were found in age, education and, the interval between assessments. Groups differed significantly in sex ( $X^2 = 5.039$ ;  $p = 0.025$ ), as men were more common in the IRBD group, and for this reason this variable was entered as a covariate in all analyses.

Regarding functional and emotional tests, groups did not differ in the BDI scale, whereas the IRBD patients had higher scores at baseline

**Table 1**  
Demographic and clinical data of the participants.

	IRBD (n = 14)	HC (n = 18)	Test stat/p
Age at baseline, years	70.1 (6.9)	68.3 (7.5)	147/0.44
Education, years	10.1 (5.1)	10.9 (4.2)	101.5/0.36
Sex (male/female)	11/3	7/11	<b>5.039/0.03</b>
IADL scale	6.7 (1.1)	7.5 (1.1)	<b>57.5/0.01</b>
AS scale	13 (5.8)	8 (3.6)	<b>188.5/0.02</b>
BDI scale	5.6 (5.3)	3.8 (3.5)	138.5/0.64
Disease duration	4.5 (3.4)	–	–
Age of onset	65.6 (7.5)	–	–
MDS-UPDRS-III	2.9 (3.4)	–	–

Abbreviations: AS, Starkstein's Apathy Scale; BDI, Beck Depression Inventory II; HC, healthy controls; IADL, Lawton and Brody instrumental activities of daily living scale; IRBD, idiopathic rapid eye movement sleep behavior disorder; MDS-UPDRS-III, Movement Disorder Society Unified Parkinson's Disease Rating Scale motor section. Measures are presented as mean (standard deviation) for continuous variables. Group differences between HC and IRBD were analyzed using Mann-Whitney's *U* test. Differences in categorical variables were analyzed with chi-squared test.

in the AS ( $U = 188.5$ ;  $p = 0.02$ ) and lower in the IADL ( $U = 57.5$ ;  $p = 0.01$ ) scales. One IRBD patient reported visual, auditory and tactile hallucinations. None of the aforementioned scales correlated with neuropsychological data.

#### 3.2. Neuropsychological, olfactory and motor changes

The longitudinal evolution of cognitive and olfactory performance is summarized in Table 2. Significant group differences between patients and HC were found in several measures, namely MMSE, VFD, BJLO, semantic fluency, RAVLT, Stroop measures, SDMT, TMTA, TMTB and BNT (see Table 2, for detailed statistical data). Significant group-by-time interaction was seen in VFD test with worse progression in the IRBD group relative to HC ( $F = 12.76$ ;  $p < 0.001$ ; Hedge's *g* effect size = 1.05 [CI = 0.295–1.845]). Only this test evidenced the clinically relevant cognitive decline in IRBD. Specifically, 69.2% of the IRBD patients presented a worsening greater than 1.5 standard deviation in VFD performance in comparison to baseline scores, while none healthy individual had such a loss in this test ( $X^2 = 6.036$ ;  $p = 0.014$ ). Only one HC, but also one IRBD patient, has worsened greater than –1.5 standard deviation in BNT performance in comparison to baseline scores ( $X^2 = 0.039$ ;  $p = 0.687$ ). At follow up, MCI criteria were fulfilled by 6 (46.2%) patients, from whom 5 were already MCI at baseline, and one (7.7%) had converted to MCI at follow-up. Olfactory identification was impaired in IRBD relative to HC ( $F = 29.4$ ;  $p < 0.001$ ), but we did not find decline across time. No significant time effect was found for the MDS-UPDRS-III for the IRBD group [baseline  $2.9 \pm 3.4$ ; follow-up  $3.7 \pm 3.3$  ( $t = 1.941$ ;  $p = 0.191$ )].

#### 3.3. Cortical thickness and subcortical gray matter evolution

Cortical thickness analysis revealed that both groups had significant progressive GM decline over time (Fig. 1A and Table 3 show the time effect for each group). In IRBD, cortical thinning was found in both hemispheres involving mainly the parietal cortices, but also frontal and occipital regions. Specifically, cortical GM loss was found in the superior and inferior parietal lobes, cuneus, precuneus, precentral and postcentral gyri, the left lateral occipital and orbitofrontal cortices and the right rostral middle frontal gyrus (FWE corrected,  $p$ -value  $< 0.05$ ). In controls, changes were seen in the left pars triangularis, supramarginal gyrus and precuneus. As illustrated in Fig. 1B and Table 3, significant group-by-time interactions were found between groups; in comparison with HC, IRBD patients exhibited significantly greater progressive cortical thinning encompassing the bilateral superior parietal and precuneus, the right cuneus, the left occipital pole and lateral

**Table 2**  
Neuropsychological decline over time in IRBD and HC.

	IRBD (n = 13)		HC (n = 17)		F (Group)	F (Time)	F (Group by time)
	Baseline	Follow-up	Baseline	Follow-up			
MMSE	27.9 (1.7)	28.2 (1.4)	29.4 (1.0)	29.4 (0.6)	<b>10.9/0.003</b>	0.6/0.44	0.3/0.62
VFD	29.3 (2.8)	26.5 (2.3)	29.6 (2.5)	29.5 (2.8)	<b>5.2/0.03</b>	3.9/0.06	<b>12.8/ &lt; 0.001</b>
BJLO	22.4 (4.9)	22.5 (4.5)	24.1 (3.9)	24.6 (3.8)	<b>4.9/0.04</b>	0.1/0.82	0.1/0.88
FRT Short	21.4 (2.4)	22.1 (3.7)	22.9 (1.9)	23.3 (2.3)	2.3/0.14	0.7/0.42	0.1/0.79
Phonemic fluency	12.9 (5.7)	12.5 (5.1)	16.1 (4.3)	16.3 (4.1)	3.9/0.06	0.3/0.61	0.5/0.49
Semantic fluency	15.0 (5.1)	16.2 (4.9)	19.1 (3.2)	19.1 (2.6)	<b>7.2/0.01</b>	0.8/0.38	0.4/0.54
RAVLT	39.8 (7.2)	41.1 (9.3)	48.7 (7.7)	47.2 (8.2)	<b>6.6/0.02</b>	0.3/0.58	0.6/0.44
Direct Digits	5.3 (1.8)	4.9 (1.1)	5.4 (1.2)	5.3 (0.3)	0.6/0.45	1.2/0.28	0.3/0.64
Indirect Digits	4.2 (0.9)	3.4 (1.1)	4.1 (1.2)	3.9 (1.2)	0.1/0.34	1.0/0.33	3.4/0.08
Stroop W	84.6 (17.6)	81.5 (17.8)	96.3 (14.7)	93.4 (15.7)	<b>8.9/0.01</b>	0.1/0.92	0.6/0.45
Stroop C	54.7 (12.0)	56.2 (13.3)	65.6 (9.5)	60.8 (7.4)	<b>5.2/0.03</b>	0.1/0.81	1.9/0.18
Stroop WC	30.0 (11.3)	29.8 (11.9)	36.5 (9.9)	35.1 (9.6)	<b>4.3/0.05</b>	0.8/0.39	0.4/0.53
SDMT	35.5 (12.6)	35.5 (13.1)	48.1 (9.6)	48.3 (9.8)	<b>11.0/0.003</b>	0.1/0.77	0.1/0.80
TMTA	52.6 (14.1)	54.2 (16.8)	39.4 (17.9)	43.1 (19.3)	<b>15.5/ &lt; 0.001</b>	2.9/0.09	2.2/0.15
TMTB	161.3 (76.6)	202.2 (102.5)	94.8 (43.2)	126.7 (64.7)	<b>13.8/0.001</b>	<b>4.7/0.04</b>	0.7/0.40
BNT	13.2 (0.9)	13.8 (0.4)	14.1 (0.8)	13.8 (1.2)	<b>4.7/0.04</b>	0.4/0.56	<b>4.7/0.04</b>
UPSIT	17.7 (6.2)	19.2 (6.6)	30.1 (5.6)	30.1 (2.9)	<b>29.4/ &lt; 0.001</b>	1.2/0.29	0.4/0.53

Abbreviations: BJLO, Benton's Judgment of Line Orientation test; BNT, Boston Naming Test; FRT Short, Facial Recognition test short form; HC, healthy controls; IRBD, idiopathic rapid eye movement sleep behavior disorder; MMSE, Mini-mental state examination; RAVLT, Rey's Auditory Verbal Learning Test sum of correct responses from trial I to trial V; SDMT, Symbol Digits Modalities Test; Stroop W, Stroop Word; Stroop C, Stroop Color; Stroop WC, Stroop Word-Color; TMTA, Trail Making Test part A; TMTB, Trail Making Test part B; UPSIT, The University of Pennsylvania Smell Identification Test; VFD, Visual Form Discrimination. Repeated measures general linear model was used to assess group differences over time with sex as a covariate. Measures are presented as mean (standard deviation).

orbitofrontal gyri (FWE corrected,  $p$ -value < 0.05). Our results did not show differences over time between groups in any subcortical volume.

### 3.4. Clinical and cognitive correlates

To assess the clinical relevance of VFD decline in IRBD patients, we investigated its structural correlates. Whole-brain analyses showed significant correlations between changes in VFD over time and cortical thinning in the right superior parietal and the left precuneus (FWE corrected,  $p$ -value < 0.05) (see Fig. 2 and Table 3). No significant correlations between VFD changes and cortical thinning was obtained for the control group.

Changes in the MDS-UPDRS-III over time were associated with cortical degeneration bilaterally in the superior parietal, the left superior frontal, and right rostral middle frontal (see Fig. 3A and Table 3). Furthermore, our results highlighted cortical loss in bilateral precuneus and lateral occipital gyri after 1.6 years in those patients with late onset of the disease (FWE corrected,  $p$ -value < 0.05) (see Fig. 3B and Table 3).

## 4. Discussion

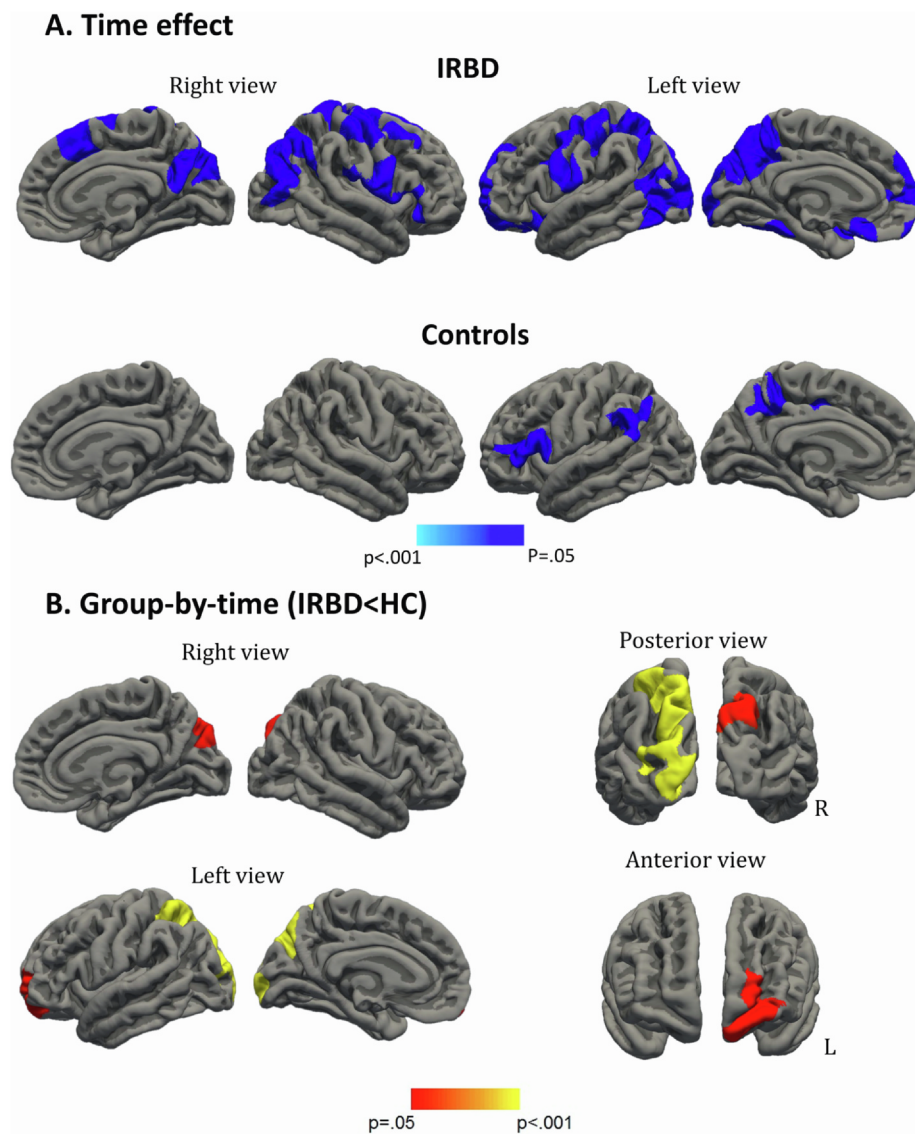
In the present study, we aimed to investigate the progression of cortical and subcortical changes in IRBD relative to healthy individuals, and how these changes relate to cognitive decline. As far as we know, this is the first longitudinal work reporting gray matter loss and progressive worsening in visual discrimination performance in IRBD compared to normal aging. It is worth noting that structural and cognitive changes are identified even in a short interval of less than two years.

We found significant group effect in several neuropsychological tests. Similar to previous studies we identified deficits in verbal learning (Gagnon et al., 2009; Massicotte-Marquez et al., 2008), semantic fluency (Gagnon et al., 2009; Massicotte-Marquez et al., 2008), mental processing speed (Pereira et al., 2019), attention and executive functions (Delazer et al., 2012; Ferini-Strambi et al., 2004; Gagnon et al., 2009; Massicotte-Marquez et al., 2008; Terzaghi et al., 2013). We also observed impaired VS/VP functions, similarly to the findings in PD and DLB (Garcia-Diaz et al., 2018a; Mori et al., 2000; Pereira et al., 2009; Ramirez-Ruiz et al., 2006; Segura et al., 2014; Tiraboschi et al., 2006).

As for the cognitive decline over IRBD, there is still considerable uncertainty. Previous longitudinal studies including follow-up data for IRBD and healthy individuals, did not report an interaction between group and time, so the aging effect could not be ruled out (Fantini et al., 2011; Terzaghi et al., 2013; Youn et al., 2016). In the current work, after a short period of time, we found cognitive decline in IRBD relative to normal aging. Particularly, we identified VFD progressive worsening with a large effect size, again in agreement with VS/VP findings in PD and DLB (Garcia-Diaz et al., 2018a; Mori et al., 2000; Pereira et al., 2009; Ramirez-Ruiz et al., 2006; Segura et al., 2014; Tiraboschi et al., 2006). Finally, although we found group-by-time interaction for the BNT, the fact that one HC, but also one IRBD patient, has worsened greater than  $-1.5$  standard deviation in BNT performance in comparison to baseline scores, calls into question the clinical relevance of this finding.

MRI data evidenced aging-related structural changes in both groups with common thinning in the left precuneus and inferior parietal regions but with a larger widespread frontal and parieto-occipital progression in IRBD. Cortical thickness is a sensitive measure to detect time effect in normal aging and PD (Uribe et al., 2019), and likewise, it seems to be useful to track gray matter loss in IRBD patients even in a short interval of less than two years. Indeed, when we compared both groups' cortical thinning pattern across time, we confirmed the larger degeneration in IRBD relative to healthy individuals bilaterally in the superior parietal and precuneus, the right cuneus, the left occipital pole and a cluster involving the left lateral orbitofrontal and frontopolar cortices. As stated in the introduction, there is no previous research investigating brain changes in IRBD over time compared to normal aging. It is interesting noting that already in our cross-sectional study superior parietal thinning was identified in these patients (Campabadal et al., 2019b), with our current results, we highlight the involvement of parietal regions in the progression of IRBD. This predominantly posterior cortical pattern is similar to previous findings in PD and DLB (Delli Pizzi et al., 2014; Ramirez-Ruiz et al., 2007; Segura et al., 2014; Uribe et al., 2016).

Cortical degeneration was also observed in left lateral orbitofrontal and frontopolar cortex. These regions have an important role in complex cognitive processes, namely planning, introspection and problem solving. In PD, orbitofrontal cortex is associated with decision-making and recognition of emotions (Ibarratxe-Bilbao et al., 2009). Despite we



**Fig. 1.** Vertex-wise symmetrized percent change (SPC) in cortical thickness. **A.** Time effect for IRBD and HC group, cold colors represent negative SPC (GM loss across time); **B.** Group-by-time interaction, warm colors depict those regions were IRBD present reduced SPC in comparison with HC over the course of the study. Results were obtained using Monte Carlo simulation with 10,000 iterations applied to cortical thickness maps to provide cluster-wise correction for multiple comparisons (FWE corrected,  $p$ -value  $< 0.05$ ). Simulation was applied for negative time effects (time 2  $<$  time 1), whereas, on group-by-time contrast, simulation was applied for absolute results. Sex was used as a covariate. Abbreviations: HC, healthy controls; IRBD, idiopathic REM sleep behavior disorder; L, left; R, right.

found executive dysfunction compared to HC, no decline was found across time, which might be explained by the fact that the current neuropsychological assessment did not evaluate specifically orbitofrontal functions. On the other hand, orbitofrontal regions have also been associated with olfactory dysfunction in IRBD (Campabadal et al., 2019a; Pereira et al., 2019) and PD (Ibarretxe-Bilbao et al., 2010). Nonetheless, despite finding olfactory identification deficits in IRBD relative to healthy controls, our results did not show decline over the disease course. In the same line, after a 4-year follow-up, olfactory decline in IRBD (Iranzo et al., 2013) and PD patients (Campabadal et al., 2017) was similar to that observed in healthy elder controls. Iranzo et al. (2013) hypothesized that the absence of longitudinal changes in IRBD might be explained by a floor effect in olfactory loss reached at early stages of the disease, suggesting that the smell function is already compromised in IRBD.

Our study provides new evidence for neuroanatomical substrate of progressive worsening in IRBD cognition. In particular, we established that visual discrimination changes over time are related to progressive reductions in bilateral superior parietal cortical regions. As far as we are aware, the neuroanatomical basis of cognitive dysfunction in IRBD has only been studied cross-sectionally (Pereira et al., 2019; Rahayel et al., 2018b). Specifically, structural mechanisms underpinning VS/VP impairment in IRBD are related with cortical thinning in posterior regions

(Pereira et al., 2019; Rahayel et al., 2018b), but also anterior (Pereira et al., 2019; Rahayel et al., 2018b) frontal, insular cortices and with right hippocampal regions (Rahayel et al., 2018b). The involvement of frontal regions in Rahayel et al.'s work, might be explained by the use of copy drawing and block design to compute VS domain, tasks that also demand motor and executive functions. It is worth noting that when assessing specifically VS/VP functions in PD, structural substrates encompass cortical thinning in lateral temporoparietal regions (Garcia-Diaz et al., 2018a; 2014). Moreover, as PD progresses, VS/VP impairment is accompanied by bilateral posterior degeneration (Garcia-Diaz et al., 2018b). Although further longitudinal data with larger samples are needed to confirm our results, the decline in VS/VP performance might help to identify those patients presenting progressive neurodegeneration in posterior cortices.

Our results evidenced that in the IRBD group changes in the MDS-UPDRS-III over time were associated with bilateral cortical degeneration in the superior parietal, and in the left superior frontal, and right rostral middle frontal. This finding concurs with a previous work where increasing motor disease severity, measured with the same scale, was related to cortical thinning in the left superior frontal and fusiform and the right precentral gyri (Pereira et al., 2019). Interestingly, when motor output was assessed more thoroughly, slower finger tapping of the right hand was associated with cortical thinning in the right

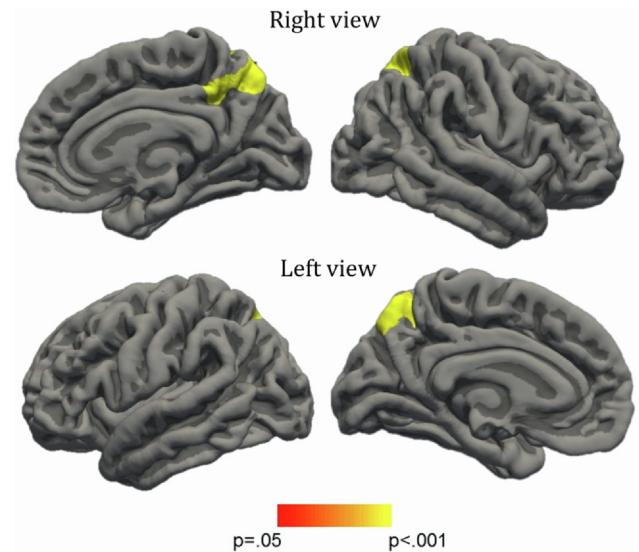
**Table 3**  
Significant clusters showing cortical thickness differences between groups and correlations with cognitive and clinical measures

	Cluster size (mm <sup>2</sup> )	MNI305 space			Clusterwise p value	Cluster anatomical annotation
		X	Y	Z		
<b>IRBD effect Time</b>						
<b>LH Clusters</b>						
1	17560.6	-17.5	-87.9	19.9	< 0.001	Superior parietal
2	5351.7	-10.7	55.5	-18.7	< 0.001	Lateral orbitofrontal
3	2248.5	-41.5	-0.3	28.7	0.001	Precentral
<b>RH Clusters</b>						
1	1606.7	23.1	60.7	2.2	0.021	Rostral middle frontal
2	10258.7	7.1	25.7	56.2	< 0.001	Superior frontal
3	7201.8	41.6	-63.6	45.7	< 0.001	Inferior parietal
<b>HC effect Time</b>						
<b>LH Clusters</b>						
1	1803.3	-47.7	27.9	3.3	0.009	Pars triangularis
2	1615.2	-57.7	-50.2	30.5	0.019	Supramarginal
3	1684.3	-15.0	-44.5	46.5	0.014	Precuneus
<b>Group by Time (IRBD &lt; HC)</b>						
<b>LH Clusters</b>						
1	5609.7	-17.5	-87.9	19.9	< 0.001	Superior parietal
2	1043.3	-13.4	55.8	-16.7	0.035	Lateral orbitofrontal
<b>RH Clusters</b>						
1	1259.1	20.4	-79.6	43.1	0.012	Superior parietal
<b>Correlation with decline in VFD in IRBD</b>						
<b>LH Clusters</b>						
1	921.2	-8	-72.6	48.7	0.044	Precuneus
<b>RH Clusters</b>						
1	1870.46	21.1	-59.3	58.9	< 0.001	Superior parietal
<b>Correlation with MDS-UPDRS-III changes in IRBD</b>						
<b>LH Clusters</b>						
1	894.4	-18.9	-3.5	66.3	0.029	Superior frontal
2	999.2	-17.4	-67.5	43.5	0.014	Superior parietal
<b>RH Clusters</b>						
1	1494.9	23.6	43.6	31.8	< 0.001	Rostral middle frontal
2	1770.9	23.4	-61.6	49.3	< 0.001	Superior parietal
<b>Correlation with age of onset in IRBD</b>						
<b>LH Clusters</b>						
1	4205.8	-42.8	-77.9	2.5	< 0.001	Lateral occipital
2	1658.6	-6.0	-71.3	40.9	< 0.001	Precuneus
3	929.5	-7.8	-98.5	9.4	0.041	Lateral occipital
<b>RH Clusters</b>						
1	1676.1	6.8	-44.8	44.1	0.001	Precuneus

Abbreviations: HC, healthy controls; IRBD, idiopathic rapid eye movement sleep behavior disorder; LH, left hemisphere; MDS-UPDRS-III, Movement Disorder Society Unified Parkinson's Disease Rating Scale motor section; RH, right hemisphere; VFD, Visual Form Discrimination. All analyses are covaried by sex. Results after FWE correction with Monte Carlo simulation and threshold at  $p \leq 0.05$ .

paracentral and superior parietal lobule cortices, and bilaterally with the pallidum; whereas in the left hand it correlated with cortical thinning in the right postcentral and superior parietal lobule cortices (Rahayel et al., 2018b). Furthermore, our results highlighted that cortical loss in posterior regions after 1.6 years follow-up was associated with late-onset IRBD. It is worth noting that in PD, older age at onset is associated with worse prognosis (Hely et al., 1995), with more severe motor and nonmotor PD phenotype, and greater impairment of dopaminergic dysfunction in the putamen and caudate as measured by DaTSCAN (Pagano et al., 2016). If we add this to the fact that posterior cortical degeneration is a well-documented finding of PD and DLB (Delli Pizzi et al., 2014; Ramírez-Ruiz et al., 2007; Segura et al., 2014; Uribe et al., 2016), we could speculate that those IRBD with late onset might presumably present a worse prognosis.

The strengths of our study are that all participants were evaluated by the same neuropsychologist at both time points, using the same



**Fig. 2.** Correlates of VFD changes. Vertex-wise symmetrized percent change (SPC) in cortical thickness correlations with SPC Visual form Discrimination (VFD) scores in IRBD group. Sex was used as a covariate. The scale bar shows  $P$  values (FWE corrected,  $p$ -value < 0.05).

neuropsychological battery and MRI scanning protocol, thus avoiding the variability of multicentric data. Moreover, we used a case control-design to identify different gray matter degeneration in IRBD in comparison to normal aging. However, the reduced sample size limits the generalization of the results, as well as the possibility to further investigate the sex effect and differences between IRBD with and without mild cognitive impairment. Another possible limitation of our work is that some patients were evaluated under the influence of benzodiazepines. Unfortunately, our sample does not allow us to study differences between medicated and non-medicated patients. On the other hand, the short time between evaluations may have limited the longitudinal findings of our work. A longer interval between time points would allow detecting a decline in other functions. Prospective studies will help to identify structural and cognitive markers of phenoconversion, with a particular focus on those able to identify whether a patient will eventually convert to PD or DLB.

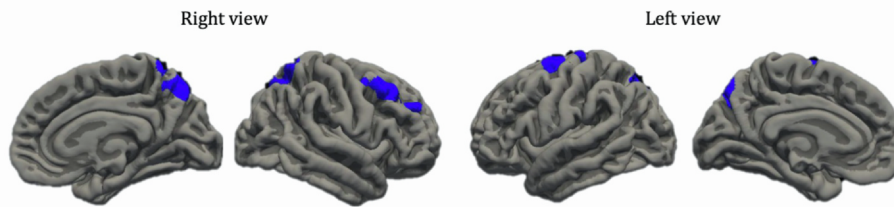
## 5. Conclusion

The current study gives evidence of progressive cortical degeneration in IRBD mainly encompassing parieto-occipital and orbitofrontal regions. Additionally, we identified visual discrimination decline over the course of the disease, and we established its structural substrates, highlighting the involvement of bilateral parietal cortices in IRBD's evolution. Overall, these findings widen our knowledge of how IRBD's progression affects brain structure and cognition mainly involving posterior and orbitofrontal regions, similarly to previous findings in PD and DLB.

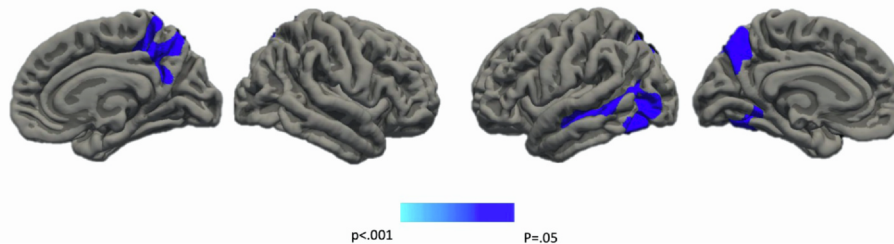
## Author contributions

CJ contributed in the design of the study. AA, AC and CU contributed to the data collection. AC, AI, BS and CJ contributed to the analysis of the data and AA, AC, AI, BS, CG, CJ, CU, JS, MS and YC contributed to the interpretation of the data. AC, AI, BS and CJ contributed to the draft of the article. All the authors revised the manuscript critically for important intellectual content and approved the final version of the manuscript.

## A. MDS-UPDRS-III



## B. Age of IRBD onset



**Fig. 3.** A. Vertex-wise symmetrized percent change (SPC) in cortical thickness correlations with SPC MDS-UPDRS-III (Movement Disorder Society Unified Parkinson's Disease Rating Scale motor section.); B. Vertex-wise SPC in cortical thickness correlations with age of IRBD onset. Sex was used as a covariate. The scale bar shows *P* values (FWE corrected, *p*-value < 0.05).

## Funding

This study was sponsored by the Spanish Ministry of Economy and Competitiveness ([PSI2017-86930-P] cofinanced by Agencia Estatal de Investigación (AEI) and the European Regional Development Fund), Generalitat de Catalunya [2017SGR 748], Fundació La Marató de TV3 in Spain [20142310], and supported by María de Maeztu Unit of Excellence (Institute of Neurosciences, University of Barcelona) MDM-2017-0729, Ministry of Science, Innovation and Universities. AC and AI were supported by APIF predoctoral fellowship from the University of Barcelona [2017–2018], AA was supported by a 2016–2019 fellowship from the Departament d'Empresa i Coneixement de la Generalitat de Catalunya, AGAUR [2016FI\_B 00360; 2017FI\_B1 00013; 2018FI\_B2 00001], and CU was supported by a fellowship from 2014, Spanish Ministry of Economy and Competitiveness [BES-2014-068173] and cofinanced by the European Social Fund (ESF).

## Declaration of Competing Interest

The authors report no conflicts of interest relevant to this study.

## Acknowledgments

We thank the cooperation of the patients, their families and control subjects. We are also indebted to the Magnetic Resonance Imaging core facility of the IDIBAPS for the technical support, especially to C. Garrido, G. Lasso, V. Sanchez and A. Albaladejo; and we would also like to acknowledge the CERCA Programme/Generalitat de Catalunya.

## References

- Aarsland, D., Bronnick, K., Larsen, J.P., Tysnes, O.B., Alves, G., 2009. Cognitive impairment in incident, untreated Parkinson disease: The Norwegian ParkWest Study. *Neurology* 72, 1121–1126. <https://doi.org/10.1212/01.wnl.0000338632.00552.cb>.
- Beck A, Steer R, B.G., 1996. Manual for the Beck Depression Inventory-II. Psychological Corporation, San Antonio, Texas.
- Boeve, B.F., 2010. REM sleep behavior disorder: updated review of the core features, the RBD-neurodegenerative disease association, evolving concepts, controversies, and future directions. *Ann. N. Y. Acad. Sci.* 15–54. <https://doi.org/10.1111/j.1749-6632.2009.05115.x.REM>.
- Byun, J.-I., Kim, H.-W., Kang, H., Cha, K.S., Sunwoo, J.-S., Shin, J.-W., Moon, J., Lee, S.-T., Jung, K.-H., Chu, K., Kim, M.-H., Shin, W.C., Lee, D.S., Schenck, C.H., Lee, S.K., Jung, K.-Y., 2020. Altered resting-state thalamo-occipital functional connectivity is associated with cognition in isolated rapid eye movement sleep behavior disorder. *Sleep Med.* 69, 198–203. <https://doi.org/10.1016/j.sleep.2020.01.010>.
- Campabadal, A., Abos, A., Segura, B., Serradell, M., Uribe, C., Baggio, H.C., Gaig, C.,

- Santamaria, J., Compta, Y., Bargallo, N., Junque, C., Iranzo, A., 2020. Disruption of posterior brain functional connectivity and its relation to cognitive impairment in idiopathic REM sleep behavior disorder. *NeuroImage Clin.* 25, 102138. <https://doi.org/10.1016/j.nicl.2019.102138>.
- Campabadal, A., Segura, B., Junque, C., Serradell, M., Abos, A., Uribe, C., Baggio, H., Gaig, C., Santamaria, J., Bargallo, N., Iranzo, A., 2019a. Comparing the accuracy and neuroanatomical correlates of the UPSIT-40 and the Sniffin' Sticks test in REM sleep behavior disorder. *Park. Relat. Disord.* 65, 197–202. <https://doi.org/10.1016/j.parkreldis.2019.06.013>.
- Campabadal, A., Segura, B., Junque, C., Serradell, M., Abos, A., Uribe, C., Baggio, H., Gaig, C., Santamaria, J., Compta, Y., Bargallo, N., Iranzo, A., 2019b. Cortical gray matter and hippocampal atrophy in idiopathic rapid eye movement sleep behavior disorder. *Front. Neurol.* 10, 1–9. <https://doi.org/10.3389/fneur.2019.00312>.
- Campabadal, A., Uribe, C., Segura, B., Baggio, H.C., Abos, A., Garcia-Diaz, A.L., Marti, M.J., Valldorriola, F., Compta, Y., Bargallo, N., Junque, C., 2017. Brain correlates of progressive olfactory loss in Parkinson's disease. *Parkinsonism Relat. Disord.* 41, 44–50. <https://doi.org/10.1016/j.parkreldis.2017.05.005>.
- Dang-Vu, T.T., Gagnon, J.F., Vendette, M., Soucy, J.P., Postuma, R.B., Montplaisir, J., 2014. Hippocampal perfusion predicts impending neurodegeneration in REM sleep behavior disorder. *Neurology* 79, 2302–2306. <https://doi.org/10.1212/WNL.0b013e318278b658>.
- Dayan, E., Browner, N., 2017. Alterations in striato-thalamo-pallidal intrinsic functional connectivity as a prodrome of Parkinson's disease. *NeuroImage Clin.* 16, 313–318. <https://doi.org/10.1016/j.nicl.2017.08.003>.
- De Marzi, R., Seppi, K., Högl, B., Müller, C., Scherfler, C., Stefani, A., Iranzo, A., Tolosa, E., Santamaria, J., Gizewski, E., Schocke, M., Skalla, E., Kremser, C., Poewe, W., 2016. Loss of dorsolateral nigral hyperintensity on 3.0 tesla susceptibility-weighted imaging in idiopathic rapid eye movement sleep behavior disorder. *Ann. Neurol.* 79, 1026–1030. <https://doi.org/10.1002/ana.24646>.
- Delazer, M., Högl, B., Zamarian, L., Wenter, J., Ehrmann, L., Gschliesser, V., Brandauer, E., Poewe, W., Feraucher, B., 2012. Decision Making and Executive Functions in REM Sleep Behavior Disorder 35, 667–673. doi: 10.5665/sleep.1828.
- Delli Pizzi, S., Franciotti, R., Tartaro, A., Caulo, M., Thomas, A., Onofri, M., Bonanni, L., 2014. Structural alteration of the dorsal visual network in DLB patients with visual hallucinations: a cortical thickness MRI study. *PLoS One* 9, e86624. <https://doi.org/10.1371/journal.pone.0086624>.
- Doty, R.L., Bromley, S.M., Stern, M.B., 1995. Olfactory testing as an aid in the diagnosis of Parkinson's disease: development of optimal discrimination criteria. *Neurodegeneration* 4, 93–97.
- Dubois, B., Burn, D., Goetz, C., Aarsland, D., Brown, R.G., Broe, G.A., Dickson, D., Duyckaerts, C., Cummings, J., Gauthier, S., Korczyn, A., Lees, A., Levy, R., Litvan, I., Mizuno, Y., McKeith, I.G., Olanow, C.W., Poewe, W., Sampaio, C., Tolosa, E., Emre, M., 2007. Diagnostic procedures for Parkinson's disease dementia: recommendations from the movement disorder society task force. *Mov. Disord.* 22, 2314–2324. <https://doi.org/10.1002/mds.21844>.
- Ehringer, M., Latimier, A., Pyatigorskaya, N., Garcia-Lorenzo, D., Leu-Semenescu, S., Vidailhet, M., Lehericy, S., Arnulf, I., 2016. The coeruleus/subcoeruleus complex in idiopathic rapid eye movement sleep behaviour disorder. *Brain* 139, 1180–1188. <https://doi.org/10.1093/brain/aww006>.
- Ellmore, T.M., Castriotta, R.J., Hendley, K.L., Aalbers, B.M., Furr-Stimming, E., Hood, A.J., Suescun, J., Beurlet, M.R., Hendley, R.T., Schiess, M.C., 2013. Altered nigrostriatal and nigrocortical functional connectivity in rapid eye movement sleep behavior disorder. *Sleep* 36, 1885–1892. <https://doi.org/10.5665/sleep.3222>.
- Ellmore, T.M., Hood, A.J., Castriotta, R.J., Stimming, E.F., Bick, R.J., Schiess, M.C., 2010. Reduced volume of the putamen in REM sleep behavior disorder patients. *Park. Relat. Disord.* 16, 645–649. <https://doi.org/10.1016/j.parkreldis.2010.08.014>.

- Fantini, M.L., Farini, E., Ortelli, P., Zucconi, M., Manconi, M., Cappa, S., Ferini-Strambi, L., 2011. Longitudinal study of cognitive function in idiopathic REM sleep behavior disorder. *Sleep* 34, 619–625. <https://doi.org/10.1093/sleep/34.5.619>.
- Ferini-Strambi, L., Di Gioia, M.R., Castronovo, V., Oldani, A., Zucconi, M., Cappa, S.F., 2004. Neuropsychological assessment in idiopathic REM sleep behavior disorder (RBD): does the idiopathic form of RBD really exist? *Neurology* 62, 41–45.
- Gagnon, J.-F., Vendette, M., Postuma, R.B., Desjardins, C., Massicotte-Marquez, Jessica, Panisset, M., Montplaisir, J., 2009. Mild cognitive impairment in rapid eye movement sleep behavior disorder and Parkinson's disease. *Ann. Neurol.* 66, 39–47. <https://doi.org/10.1002/ana.21680>.
- García-Díaz, A.I., Segura, B., Baggio, H.C., Martí, M.J., Valldeoriola, F., Compta, Y., Bargallo, N., Uribe, C., Campabadal, A., Abos, A., Junque, C., 2018a. Structural brain correlations of visuospatial and visuoperceptual tests in Parkinson's disease. *J. Int. Neuropsychol. Soc.* 24. <https://doi.org/10.1017/S1355617717000583>.
- García-Díaz, A.I., Segura, B., Baggio, H.C., Martí, M.J., Valldeoriola, F., Compta, Y., Vendrell, P., Bargallo, N., Tolosa, E., Junque, C., 2014. Structural MRI correlates of the MMSE and pentagon copying test in Parkinson's disease. *Park. Relat. Disord.* 20, 1405–1410. <https://doi.org/10.1016/j.parkreldis.2014.10.014>.
- García-Díaz, A.I., Segura, B., Baggio, H.C., Uribe, C., Campabadal, A., Abos, A., Martí, M.J., Valldeoriola, F., Compta, Y., Bargallo, N., Junque, C., 2018b. Cortical thinning correlates of changes in visuospatial and visuoperceptual performance in Parkinson's disease: a 4-year follow-up. *Parkinsonism Relat. Disord.* 46, 62–68. <https://doi.org/10.1016/j.parkreldis.2017.11.003>.
- Hanyu, H., Inoue, Y., Sakurai, H., Kanetaka, H., Nakamura, M., Miyamoto, T., Sasai, T., Iwamoto, T., 2012. Voxel-based magnetic resonance imaging study of structural brain changes in patients with idiopathic REM sleep behavior disorder. *Parkinsonism Relat. Disord.* 18, 136–139. <https://doi.org/10.1016/j.parkreldis.2011.08.023>.
- Hely, M.A., Morris, J.G., Reid, W.G., O'Sullivan, D.J., Williamson, P.M., Broe, G.A., Adena, M.A., 1995. Age at onset: the major determinant of outcome in Parkinson's disease. *Acta Neurol. Scand.* 92, 455–463. <https://doi.org/10.1111/j.1600-0404.1995.tb00480.x>.
- Holtbrunn, F., Gagnon, J.-F., Postuma, R.B., Ma, Y., Tang, C.C., Feigin, A., Dhawan, V., Vendette, M., Soucy, J.-P., Eidelberg, D., Montplaisir, J., 2014. Abnormal metabolic network activity in REM sleep behavior disorder. *Neurology* 82, 620–627. <https://doi.org/10.1212/WNL.0000000000000130>.
- Ibarretxe-Bilbao, N., Junque, C., Martí, M.J., Valldeoriola, F., Vendrell, P., Bargallo, N., Zarei, M., Tolosa, E., 2010. Olfactory impairment in Parkinson's disease and white matter abnormalities in central olfactory areas: A voxel-based diffusion tensor imaging study. *Mov. Disord.* 25, 1888–1894. <https://doi.org/10.1002/mds.23208>.
- Ibarretxe-Bilbao, N., Junque, C., Tolosa, E., Martí, M.-J., Valldeoriola, F., Bargallo, N., Zarei, M., 2009. Neuroanatomical correlates of impaired decision-making and facial emotion recognition in early Parkinson's disease. *Eur. J. Neurosci.* 30, 1162–1171. <https://doi.org/10.1111/j.1460-9568.2009.06892.x>.
- Iranzo, A., Lomeña, F., Stockner, H., Valldeoriola, F., Vilaseca, I., Salamero, M., Molinuevo, J.L., Serradell, M., Duch, J., Pavia, J., Gallego, J., Seppi, K., Högl, B., Tolosa, E., Poewe, W., Santamaría, J., 2010. Decreased striatal dopamine transporter uptake and substantia nigra hyperchogenicity as risk markers of synucleinopathy in patients with idiopathic rapid-eye-movement sleep behaviour disorder: a prospective study. *Lancet Neurol.* 9, 1070–1077. [https://doi.org/10.1016/S1474-4422\(10\)70216-7](https://doi.org/10.1016/S1474-4422(10)70216-7).
- Iranzo, A., Molinuevo, J.L., Santamaría, J., Serradell, M., Martí, M.J., Valldeoriola, F., Tolosa, E., 2006. Rapid-eye-movement sleep behaviour disorder as an early marker for a neurodegenerative disorder: a descriptive study. *Lancet Neurol.* 5, 572–577. [https://doi.org/10.1016/S1474-4422\(06\)70476-8](https://doi.org/10.1016/S1474-4422(06)70476-8).
- Iranzo, A., Santamaría, J., Valldeoriola, F., Serradell, M., Salamero, M., Gaig, C., Niñerola-Baizán, A., Sánchez-Valle, R., Lladó, A., De Marzi, R., Stefani, A., Seppi, K., Pavia, J., Högl, B., Poewe, W., Tolosa, E., Lomeña, F., 2017. Dopamine transporter imaging deficit predicts early transition to synucleinopathy in idiopathic rapid eye movement sleep behavior disorder. *Ann. Neurol.* 82, 419–428. <https://doi.org/10.1002/ana.25026>.
- Iranzo, A., Serradell, M., Vilaseca, I., Valldeoriola, F., Salamero, M., Molina, C., Santamaría, J., Tolosa, E., 2013. Longitudinal assessment of olfactory function in idiopathic REM sleep behavior disorder. *Park. Relat. Disord.* 19, 600–604. <https://doi.org/10.1016/j.parkreldis.2013.02.009>.
- Lezak, M.D., 2012. *Neuropsychological Assessment*. Oxford University Press.
- Massicotte-Marquez, J., Décary, A., Gagnon, J.-F., Vendette, M., Mathieu, A., Postuma, R.B., Carrier, J., Montplaisir, J., Petersen, R.C., 2008. Executive dysfunction and memory impairment in idiopathic REM sleep behavior disorder. *Neurology* 70, 1250–1257. <https://doi.org/10.1212/01.wnl.0000286943.79593.a6>.
- Mori, E., Shimomura, T., Fujimori, M., Hirono, N., Imamura, T., Hashimoto, M., Tanimukai, S., Kazui, H., Hanihara, T., 2000. Visuoperceptual Impairment in Dementia With Lewy Bodies 57, 489–493.
- Ohlhauser, L., Smart, C.M., Gawryluk, J.R., 2019. Tract-based spatial statistics reveal lower white matter integrity specific to idiopathic rapid eye movement sleep behavior disorder as a proxy for prodromal Parkinson's disease. *J. Parkinsons. Dis.* 9, 723–731. <https://doi.org/10.3233/JPD-191688>.
- Pagano, G., Ferrara, N., Brooks, D.J., Pavese, N., 2016. Age at onset and Parkinson disease phenotype. *Neurology* 86, 1400–1407. <https://doi.org/10.1212/WNL.0000000000002461>.
- Park, K.M., Lee, H.J., Lee, B.I., Kim, S.E., 2018. Alterations of the brain network in idiopathic rapid eye movement sleep behavior disorder: structural connectivity analysis. *Sleep Breath.* 23, 587–593. <https://doi.org/10.1007/s11325-018-1737-0>.
- Pereira, J.B., Junqué, C., Martí, M.J., Ramírez-Ruiz, B., Bargallo, N., Tolosa, E., 2009. Neuroanatomical substrate of visuospatial and visuoperceptual impairment in Parkinson's disease. *Mov. Disord.* 24, 1193–1199. <https://doi.org/10.1002/mds.22560>.
- Pereira, J.B., Weintraub, D., Chahine, L., Aarsland, D., Hansson, O., Westman, E., 2019. Cortical thinning in patients with REM sleep behavior disorder is associated with clinical progression. *npj Park. Dis.* 3, 5:7. <https://doi.org/10.1038/s41531-019-0079-3>.
- Postuma, R.B., Iranzo, A., Hu, M., Högl, B., Boeve, B.F., Manni, R., Oertel, W.H., Arnulf, I., Ferini-Strambi, L., Puligheddu, M., Antelmi, E., Cochen De Cock, V., Arnaldi, D., Mollenhauer, B., Videnovic, A., Sonka, K., Jung, K.Y., Kunz, D., Dauvilliers, Y., Provini, F., Lewis, S.J., Buskova, J., Pavlova, M., Heidebreder, A., Montplaisir, J.Y., Santamaría, J., Barber, T.R., Stefani, A., Louis, S.E.K., Terzaghi, M., Janzen, A., Leu-Semenescu, S., Plazzi, G., Nobili, F., Sixel-Doering, F., Dusek, P., Bes, F., Cortelli, P., Ehgoetz Martens, K., Gagnon, J.F., Gaig, C., Zucconi, M., Trenkwalder, C., Gan-Or, Z., Lo, C., Rolinski, M., Mahlknecht, P., Holzknecht, E., Boeve, A.R., Teigen, L.N., Toscano, G., Mayer, G., Morbelli, S., Dawson, B., Pelletier, A., 2019. Risk and predictors of dementia and parkinsonism in idiopathic REM sleep behaviour disorder: a multicentre study. *Brain* 142, 744–759. <https://doi.org/10.1093/brain/awz030>.
- Pyatigorskaya, N., Gaurav, R., Arnaldi, D., Leu-Semenescu, S., Yahia-Cherif, L., Valabregue, R., Vidailhet, M., Arnulf, I., LeHéricy, S., 2017. Magnetic resonance imaging biomarkers to assess Substantia nigra damage in idiopathic rapid eye movement sleep behavior disorder. *Sleep* 40. <https://doi.org/10.1093/sleep/zsx149>.
- Rahayel, S., Montplaisir, J., Monchi, O., Bedetti, C., Postuma, R.B., Brambati, S., Carrier, J., Joubert, S., Latreille, V., Jubault, T., Gagnon, J.F., 2015. Patterns of cortical thinning in idiopathic rapid eye movement sleep behavior disorder. *Mov. Disord.* 30, 680–687. <https://doi.org/10.1002/mds.25820>.
- Rahayel, S., Postuma, R.B., Montplaisir, J., Bedetti, C., Brambati, S., Carrier, J., Monchi, O., Bourgouin, P.A., Gaubert, M., Gagnon, J.F., 2018a. Abnormal gray matter shape, thickness, and volume in the motor cortico-subcortical loop in idiopathic rapid eye movement sleep behavior disorder: association with clinical and motor features. *Cereb. Cortex* 28, 658–671. <https://doi.org/10.1093/cercor/bhx137>.
- Rahayel, S., Postuma, R.B., Montplaisir, J., Génier Marchand, D., Escudier, F., Gaubert, M., Bourgouin, P.-A., Carrier, J., Monchi, O., Joubert, S., Blanc, F., Gagnon, J.-F., 2018b. Cortical and subcortical gray matter bases of cognitive deficits in REM sleep behavior disorder. *Neurology* 90, e1759–e1770. [https://doi.org/10.1016/S0306-4522\(99\)00316-4](https://doi.org/10.1016/S0306-4522(99)00316-4).
- Ramírez-Ruiz, B., Junqué, C., Martí, M.-J., Valldeoriola, F., Tolosa, E., 2006. Neuro-psychological deficits in Parkinson's disease patients with visual hallucinations. *Mov. Disord.* 21, 1483–1487. <https://doi.org/10.1002/mds.20965>.
- Ramírez-Ruiz, B., Martí, M.J., Tolosa, E., Giménez, M., Bargallo, N., Valldeoriola, F., Junqué, C., 2007. Cerebral atrophy in Parkinson's disease patients with visual hallucinations. *Eur. J. Neurol.* 14, 750–756. <https://doi.org/10.1111/j.1468-1331.2007.01768.x>.
- Reuter, M., Fischl, B., 2011. Avoiding asymmetry-induced bias in longitudinal image processing. *Neuroimage* 57, 19–21. <https://doi.org/10.1016/j.neuroimage.2011.02.076>.
- Reuter, M., Rosas, H.D., Fischl, B., 2010. Highly accurate inverse consistent registration: a robust approach. *Neuroimage* 53, 1181–1196. <https://doi.org/10.1016/j.neuroimage.2010.07.020>.
- Rolinski, M., Griffanti, L., Piccini, P., Roussakis, A.A., Szewczyk-krolikowski, K., Menke, R.A., Quinnell, T., Zaiwalla, Z., Klein, J.C., Mackay, C.E., Hu, M.T.M., 2016. Basal ganglia dysfunction in idiopathic REM sleep behaviour disorder parallels that in early Parkinson's disease. *Brain* 224, 2224–2234. <https://doi.org/10.1093/aww131>.
- Scherfler, C., Frauscher, B., Schocke, M., Iranzo, A., Gschliesser, V., Seppi, K., Santamaría, J., Tolosa, E., Högl, B., Poewe, W., 2011. White and gray matter abnormalities in idiopathic rapid eye movement sleep behavior disorder: a diffusion-tensor imaging and voxel-based morphometry study. *Ann. Neurol.* 69, 400–407. <https://doi.org/10.1002/ana.22245>.
- Segura, B., Baggio, H.C., Martí, M.J., Valldeoriola, F., Compta, Y., García-Díaz, A.I., Vendrell, P., Bargallo, N., Tolosa, E., Junque, C., 2014. Cortical thinning associated with mild cognitive impairment in Parkinson's disease. *Mov. Disord.* 29, 1495–1503. <https://doi.org/10.1002/mds.25982>.
- Starkstein, S.E., Mayberg, H.S., Preziosi, T.J., Andrezejewski, P., Leiguarda, R., Robinson, R.G., 1992. Reliability, validity, and clinical correlates of apathy in Parkinson's disease. *J. Neuropsychiatry Clin. Neurosci.* 4, 134–139. <https://doi.org/10.1176/jnp.4.2.134>.
- Terzaghi, M., Zucchella, C., Rustioni, V., Sinfiorani, E., Manni, R., 2013. Cognitive performances and mild cognitive impairment in idiopathic rapid eye movement sleep behavior disorder: results of a longitudinal follow-up study. *Sleep* 36, 1527–1532. <https://doi.org/10.5665/sleep.3050>.
- Tiraboschi, P., Salmon, D.P., Hansen, L.A., Hofstetter, R.C., Thal, L.J., Corey-Bloom, J., 2006. What best differentiates Lewy body from Alzheimer's disease in early-stage dementia? *Brain* 129, 729–735. <https://doi.org/10.1093/brain/awh725>.
- Unger, M.M., Belke, M., Menzler, K., Heverhagen, J.T., Keil, B., Stiasny-Kolster, K., Rosenow, F., Diederich, N.J., Mayer, G., Möller, J.C., Oertel, W.H., Knake, S., 2010. Diffusion tensor imaging in idiopathic REM sleep behavior disorder reveals microstructural changes in the brainstem, substantia nigra, olfactory region, and other brain regions. *Sleep* 33, 767–773. <https://doi.org/10.1093/sleep/33.6.767>.
- Uribe, C., Segura, B., Baggio, H.C., Abos, A., García-Díaz, A.I., Campabadal, A., Martí, M.J., Valldeoriola, F., Compta, Y., Bargallo, N., Junque, C., 2019. Progression of Parkinson's disease patients' subtypes based on cortical thinning: 4-year follow-up. *Parkinsonism Relat. Disord.* 64, 286–292. <https://doi.org/10.1016/j.parkreldis.2019.05.012>.
- Uribe, C., Segura, B., Baggio, H.C., Abos, A., Martí, M.J., Valldeoriola, F., Compta, Y., Bargallo, N., Junque, C., 2016. Patterns of cortical thinning in nondemented Parkinson's disease patients. *Mov. Disord.* 31, 699–708. <https://doi.org/10.1002/mds.26590>.
- Vendette, M., Gagnon, J.-F., Soucy, J.-P., Gosselin, N., Postuma, R.B., Tuineag, M., Godin, I., Montplaisir, J., 2011. Brain perfusion and markers of neurodegeneration in rapid



- eye movement sleep behavior disorder. *Mov. Disord.* 26, 1717–1724. <https://doi.org/10.1002/mds.23721>.
- Vendette, M., Montplaisir, J., Gosselin, N., Soucy, J.-P., Postuma, R.B., Dang-Vu, T.T., Gagnon, J.-F., 2012. Brain perfusion anomalies in rapid eye movement sleep behavior disorder with mild cognitive impairment. *Mov. Disord.* 27, 1255–1261. <https://doi.org/10.1002/mds.25034>.
- Yoon, E.J., Lee, J.Y., Nam, H., Kim, H.J., Jeon, B., Jeong, J.M., Kim, Y.K., 2019. A new metabolic network correlated with olfactory and executive dysfunctions in idiopathic rapid eye movement sleep behavior disorder. *J. Clin. Neurol.* 15, 175–183. <https://doi.org/10.3988/jcn.2019.15.2.175>.
- Youn, S., Kim, T., Yoon, I.Y., Jeong, J., Kim, H.Y., Han, J.W., Kim, J.M., Kim, K.W., 2016. Progression of cognitive impairments in idiopathic REM sleep behaviour disorder. *J. Neurol. Neurosurg. Psychiatry* 87, 890–896. <https://doi.org/10.1136/jnnp-2015-311437>.