



## Atypical acute presentation of an optic nerve sheath meningioma

Cole Holan<sup>a</sup>, Natalie A. Homer<sup>b,\*</sup>, Aliza Epstein<sup>c</sup>, Vikram D. Durairaj<sup>a,c</sup>

<sup>a</sup> Dell Medical School, University of Texas at Austin, 1501 Red River St, Austin, TX, 78712, USA

<sup>b</sup> UC Davis, Department of Ophthalmology, 4860 Y St, #2400, Sacramento, CA, 95817, USA

<sup>c</sup> TOC Eye and Face, 3705 Medical Parkway, Suite 120, Austin, TX, 78705, USA

### ARTICLE INFO

#### Keywords:

Optic nerve tumor  
Optic nerve sheath meningioma  
Optic nerve edema  
Retrolbulbar tumor

### ABSTRACT

**Purpose:** Primary optic nerve sheath meningiomas (ONSM) are benign lesions that typically present with findings of painless proptosis (59%), optic nerve pallor (55%), and decreased peripheral vision (35%). Herein we share an atypical case of a patient who presented acutely with periorbital pain and optic nerve head edema, and was ultimately determined to have a low-grade optic nerve meningioma.

**Observations:** A 36-year-old healthy woman presented with acute onset of left periorbital discomfort. She was found to have intact visual acuity, full peripheral vision, and ipsilateral optic nerve edema. MRI imaging revealed a large intraconal mass partially encircling the left optic nerve. Incisional biopsy revealed a diagnosis of meningioma, WHO grade 1.

**Conclusions:** Low-grade optic nerve sheath meningiomas may uncommonly present with acute pain and optic nerve head swelling, and absence of classic disease features.

### 1. Introduction

Primary optic nerve sheath meningiomas (ONSM) account for 33% of optic nerve tumors.<sup>1</sup> Primary ONSMs arise from the cap cells of the arachnoid layer and can form at any location along the optic nerve, typically occurring in the intraorbital region.<sup>2</sup> These benign tumors tend to progress slowly and thus present with subtle findings of painless proptosis (59%), optic nerve pallor (55%), and decreased peripheral vision (35%) in a majority of patients.<sup>3</sup> Herein we share an atypical case of a patient who presented acutely with periorbital pain and optic nerve head edema, with normal central acuity and peripheral vision, and was ultimately found to have a low-grade optic nerve meningioma.

The collection and evaluation of protected patient health information were compliant with Health Insurance Portability and Accountability Act of 1996 and adhered to the ethical principles outlined in the Declaration of Helsinki as amended in 2013. Patient consent was obtained for photography publication.

### 2. Case presentation

A 36-year-old healthy woman presented to optometry with acute onset of left periorbital “pressure” sensation. She was found to have ipsilateral globe proptosis and optic nerve head swelling, and was

referred to oculoplastic surgery for further evaluation. She confirmed rapid development of left periorbital discomfort and denied blurry vision or diplopia. Examination revealed 20/20 visual acuity, normal pupillary response and intact color vision. There was trace limitation of left supraduction, with otherwise full motility. She had 3 mm of relative left globe proptosis without significant resistance to retropulsion (Fig. 1). Dilated fundus examination revealed left optic nerve head edema without hemorrhage (Fig. 2). Humphrey visual field testing of the left eye showed non-specific defects centrally, with intact field peripherally (Fig. 3). Contrast-enhanced MRI imaging revealed a large intraconal mass wrapping around the inferior half of the left optic nerve (Fig. 4), abutting the posterior globe and medial rectus muscle. Imaging characteristics of low T2 signal-restricted diffusion were believed to correlate with a cellular high-grade tumor, such as a lymphoma or sarcoma.

Incisional biopsy was pursued given the acute presentation of symptoms and radiographic findings, atypical for benign optic nerve disease. A lateral orbitotomy via a swinging eyelid approach was performed. Intraoperatively the patient was found to have an ill-defined gray-colored friable retrolbulbar lesion with infiltration of the optic nerve sheath. Microscopic evaluation revealed syncytial proliferation of neoplastic meningotheelial cells with uniform oval nuclei arranged in nests and whorls, consistent with a diagnosis of meningioma, WHO

\* Corresponding author.

E-mail address: [nahomer@ucdavis.edu](mailto:nahomer@ucdavis.edu) (N.A. Homer).

<https://doi.org/10.1016/j.ajoc.2020.100951>

Received 29 April 2020; Received in revised form 15 September 2020; Accepted 27 September 2020

Available online 29 September 2020

2451-9936/© 2020 Published by Elsevier Inc. This is an open access article under the CC BY-NC-ND license (<http://creativecommons.org/licenses/by-nc-nd/4.0/>).

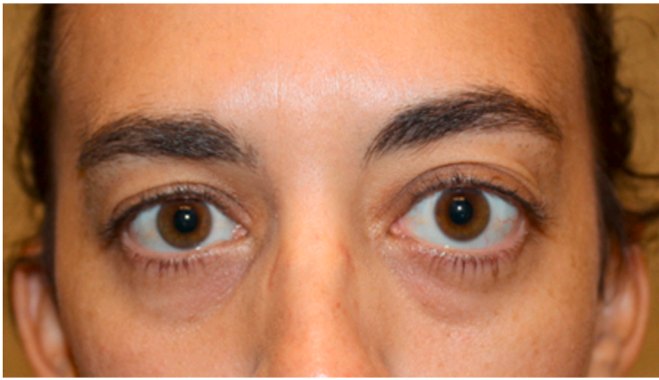


Fig. 1. Clinical photo showing significant left globe proptosis.

grade 1. (Fig. 5).

Post-operatively the patient developed transient abduction deficit, which fully resolved over two months. She maintained 20/20 visual acuity and intact afferent pupillary response over this same time. The patient was evaluated for targeted proton beam therapy, with plan to pursue treatment if objective vision compromise ensued.

### 3. Discussion

Optic nerve sheath meningiomas are a primary tumor derived from meningotheelial cells. ONSMs occur more commonly in females with a 5:1 female predilection.<sup>4</sup> They typically are limited to intraorbital optic nerve involvement but may extend toward the optic canal and chiasm in some cases (50%).<sup>4</sup> Central vision is usually maintained early in ONSMs which often masks the progressive loss of peripheral vision and may preclude early diagnosis. Most patients also present with painless proptosis (59%), optic nerve pallor (55%), strabismus (47%), and peripheral vision decline (35%).<sup>3</sup> Less common symptoms may include transient visual obscurations (15%), pain (7%), and diplopia (4%).<sup>4</sup> Optociliary shunt vessels may be seen in up to 25% of patients upon exam.<sup>4</sup> Clinical findings suggestive of a compressive optic nerve lesion should be followed by prompt evaluation with orbital contrast-enhanced MRI imaging.<sup>5</sup> Our patient had none of the four most common presenting complaints, and instead presented acutely with periorbital discomfort and optic nerve edema, findings more suggestive of an acutely expanding or malignant lesion. She had normal pupillary response and color vision, and visual field testing showing only non-specific defects in the cecentral region, likely correlating to her mild optic disc edema. No peripheral deficits were detected, despite a large circumferential optic nerve tumor. Interestingly the superior aspect of the patient's optic nerve was asymmetrically spared from compression, which may have allowed for maintained superior nerve vascular health and preserved nerve viability. The patient's discomfort

was likely due to the unusually large size of this lesion confined to the apical space. The authors believe it is unlikely that there was an acute significant change in lesion size or intralesional hemorrhage inciting her sudden symptoms, given the benign lesion histology and absence of organized hemorrhage on intraoperative inspection.

Only rare case reports of documented acute symptomatology from an optic nerve meningioma exist.<sup>6,7</sup> Alroughani et al. reported a case of a 47-year-old woman with subjective report of sudden vision change and movement-evoked eye pain four years preceding her meningioma diagnosis, erroneously attributed to optic neuritis.<sup>6</sup> An additional report of sudden vision change in setting of ONSM was ascribed to "pseudo-acute" awareness of visual decline, rather than rapid change.<sup>7</sup>

Hormones are postulated to affect meningioma activity, as receptors to progesterone, estrogen, glucocorticoid and androgen hormones have been detected in meningioma tissue.<sup>8</sup> Anecdotal reports of vision fluctuations with menstrual cycle and pregnancy have been reported in patients with optic nerve sheath meningiomas, further suggesting a correlation.<sup>9</sup> However, the use of hormone antagonists to halt disease progression has yielded mixed results.<sup>10,11</sup> There is no circumstantial evidence that hormone fluctuations played a role in our patient's symptomatology.

Diagnosis of optic pathway meningiomas is commonly made based on characteristic clinical and radiologic findings alone. Classically, CT scan reveals a "tram-track sign" of parallel calcifications along the length of the nerve, which can be used to differentiate these lesions from optic nerve gliomas, which display a uniform enhancement of the optic nerve proper.<sup>12,13</sup> Gadolinium-enhanced MRI with high spatial resolution typically reveals a segmental or diffuse thickening of the optic nerve sheath.<sup>14,15</sup> Shaggy borders and meningeal projections into the surrounding fat can also be seen. Our patient's MRI imaging displayed an atypically large nodular lesion with incomplete encasement of the optic nerve, believed to more likely reflect an external compressive lesion, rather than a tumor intrinsic to the optic nerve sheath. Additionally, the T2-restricted diffusion pattern resembled that seen in cellular high-grade tumors, such as lymphoma or sarcoma. In rare atypical cases requiring diagnostic confirmation, as in the one presented here, incisional biopsy is advised.<sup>12</sup>

Treatment of ONSMs most commonly is with observation in minimally-symptomatic cases. While progressive functional vision decline has been reported in up to 85% of non-treated patients, cases of longstanding stability over multiple decades do exist.<sup>3,16</sup> Surgical debulking of ONSMs may be warranted when there is intracanalicular extension, given the potential of optic chiasm involvement and risk of contralateral vision loss.<sup>12</sup> Surgical intervention is often performed via a craniotomy with extradural sphenoid ridge drilling, posterior orbitotomy, decompression of the superior orbital fissure, and unroofing of the optic canal.<sup>17</sup> Endoscopic transnasal ONSM excision has also been described.<sup>18</sup> Surgical excision of ONSMs is a technical challenge and associated with a significant risk of postoperative blindness.<sup>12</sup> Progression to complete vision loss has been reported in 78–100% of patients

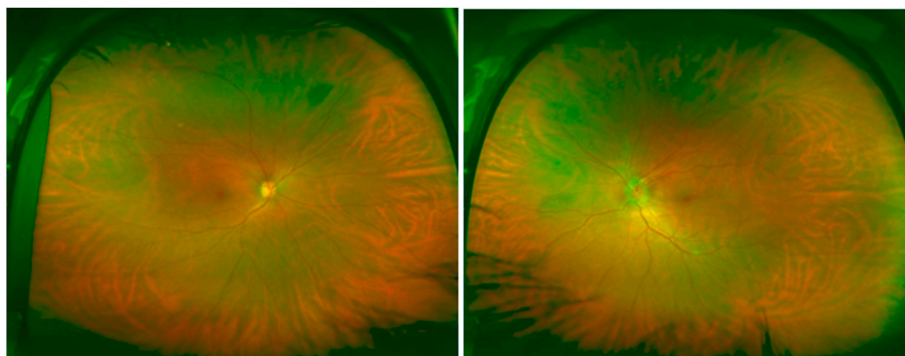


Fig. 2. Optos photos showing (a) normal right fundus and (b) left optic nerve edema without pallor.

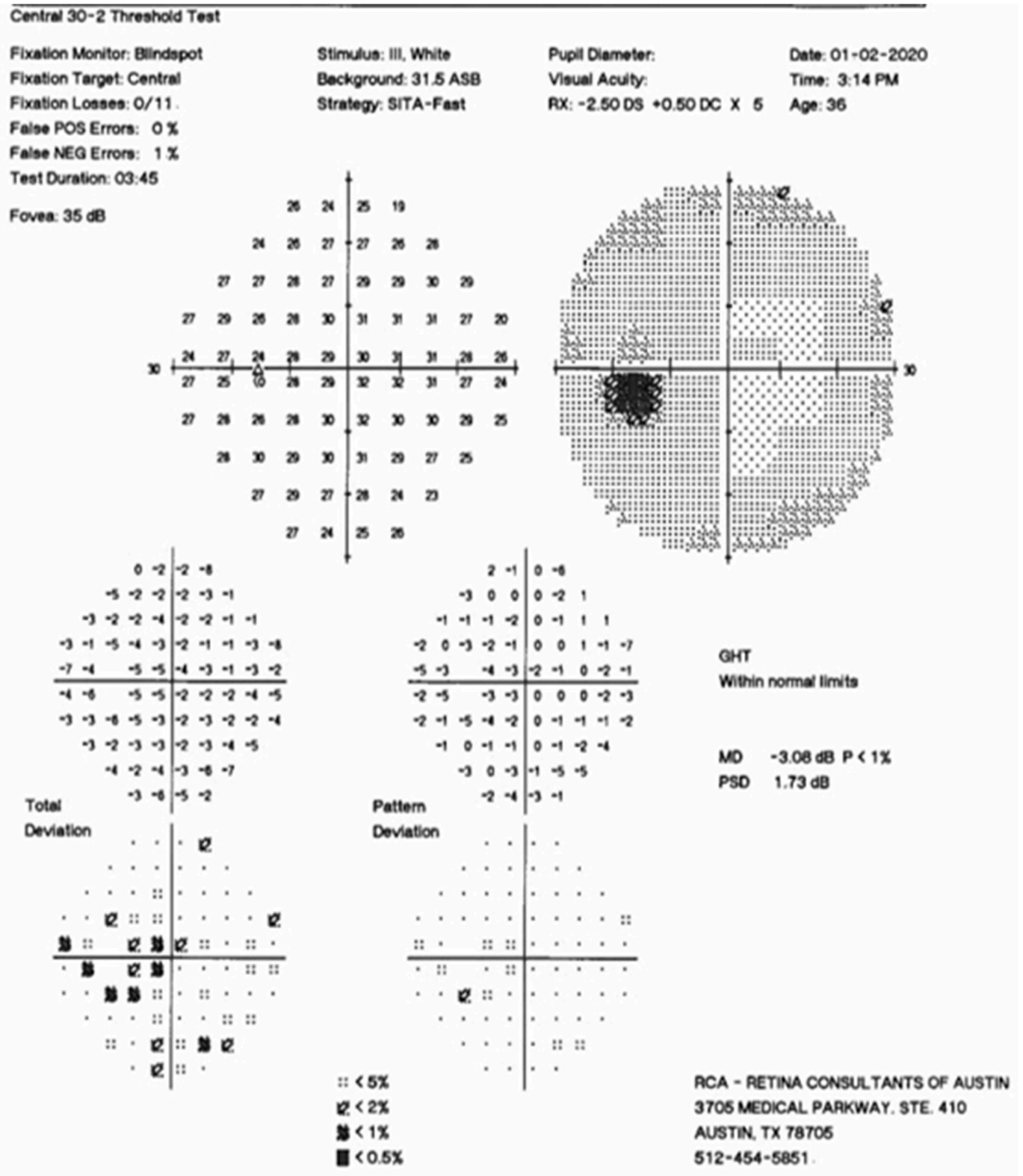


Fig. 3. 30-2 Humphrey visual field testing showing non-specific defects without a peripheral field deficit.

who undergo surgical excision, attributed to the disruption of normal optic nerve vascular supply.<sup>4,19</sup> Thus, surgical as a primary treatment modality is limited to cases with intracranial extension. Conventional radiation can also be used to treat ONSMs as primary therapy.<sup>12</sup> External beam, conformal and intensity-modulated radiotherapy have shown comparable success in stabilizing disease, though at the cost of

non-insignificant retinal and optic nerve toxicity.<sup>20,21</sup> In a comparison study of 64 patients, complication rates of surgical, radiation, and combined intervention were 66.7%, 33.3%, and 62.5%, respectively.<sup>12</sup> Fractionated radiotherapy has been used with reported local 5-year control rates nearing 100%, and decreased side-effect profile. Thus fractionated radiotherapy now serves as the gold standard for primary

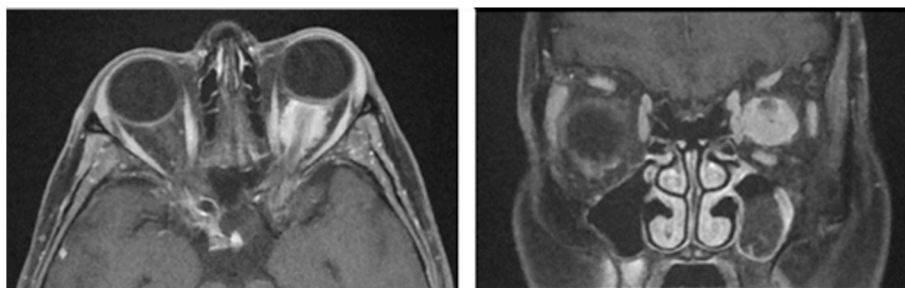


Fig. 4. MRI post-contrast T1 weighted (a) axial and (b) coronal image showing a large left intraconal lesion encompassing the optic nerve with nerve sheath invasion.

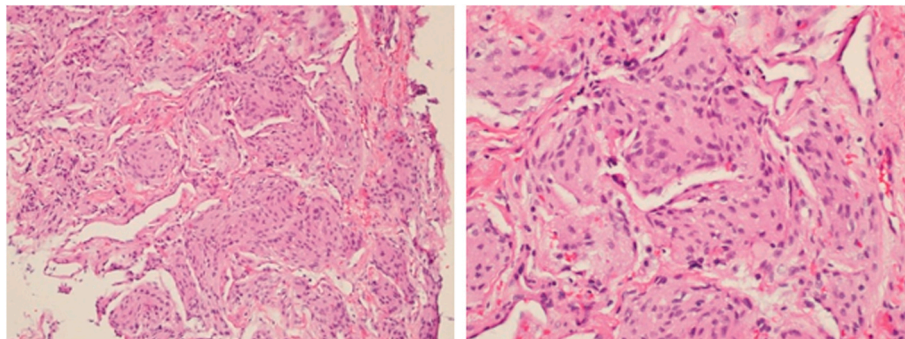


Fig. 5. Pathology images of (a) medium and (b) high-magnification displaying syncytial proliferation of neoplastic meningothelial cells with uniform oval nuclei arranged in nests and whorls, without increase in mitosis, hypercellularity or necrosis.

treatment of extracranial ONSMs.<sup>20,21</sup> Fractionated targeted proton beam radiation has also been used with moderate success, and a clinical trial utilizing a multisession radiosurgery protocol is ongoing, with initial results promising.<sup>22,23</sup> The decision of when to initiate treatment is controversial, and must weigh the threat of vision compromise and risks of treatment-related toxicity. Most currently advocate initiation of treatment upon detection of early objective visual decline.<sup>20,21</sup>

#### 4. Conclusions

We present herein a unique presentation of a benign optic nerve sheath meningioma. Optic nerve sheath meningiomas may uncommonly present with acute findings of pain and optic nerve swelling, and absence of classic disease features.

#### Patient consent

Consent to publish this case report has been obtained from the patient in writing.

#### Funding

No funding or grant support.

#### Authorship

All authors attest that they meet the current ICMJE criteria for Authorship.

#### Declaration of competing interest

Dr. Vikram D. Durairaj serves as a consultant for Stryker and Horizon Therapeutics. There are no direct conflicts of interest with this case report. The remaining authors have no financial disclosures.

#### Acknowledgments

The authors would like to acknowledge Dr. Suzanne Ledet for kindly providing the surgical pathology photographs.

#### References

1. Turbin RE, Pokorny K. Diagnosis and treatment of orbital optic nerve sheath meningioma. *Cancer Control*. 2004;11(5):334–341.
2. Wright J, Call N, Liaricos S. Primary optic nerve meningioma. *Br J Ophthalmol*. 1980;64(8):553–558.
3. Dutton JJ. Optic nerve sheath meningiomas. *Surv Ophthalmol*. 1992;37(3):167–183.
4. Saeed P, Rootman J, Nugent RA, White VA, Mackenzie IR, Koornneef L. Optic nerve sheath meningiomas. *Ophthalmology*. 2003;110(10):2019–2030.
5. Mao J-F, Xia X-B, Tang X-B, Zhang X-Y, Wen D. Analyses on the misdiagnoses of 25 patients with unilateral optic nerve sheath meningioma. *Int J Ophthalmol*. 2016;9(9):1315.
6. Alroughani R, Behbehani R. Optic nerve sheath meningioma masquerading as optic neuritis. *Case Rep Neurol Med*. 2016;2016.
7. Moster ML. Detection and treatment of optic nerve sheath meningioma. *Curr Neurol Neurosci Rep*. 2005;5(5):367–375.
8. Poisson M. Sex steroid receptors in human meningiomas. *Clin Neuropharmacol*. 1984;7(4):320–324.
9. Bickerstaff ER, Small JM, Guest IA. The relapsing course of certain meningiomas in relation to pregnancy and menstruation. *J Neural Neurosurg Psych*. 1958;21:89–91.
10. Jääskeläinen J, Laasonen E, Kärkkäinen J, Haltia M, Troupp H. Hormone treatment of meningiomas: lack of response to medroxyprogesterone acetate (MPA). *Acta Neurochir*. 1986;80(1-2):35–41.
11. Grunberg SM, Weiss MH, Spitz IM, et al. Treatment of unresectable meningiomas with the antiprogestone agent mifepristone. *J Neurosurg*. 1991 Jun;74(6):861–866.
12. Turbin RE, Thompson CR, Kennerdell JS, Cockerham KP, Kupersmith MJ. A long-term visual outcome comparison in patients with optic nerve sheath meningioma managed with observation, surgery, radiotherapy, or surgery and radiotherapy. *Ophthalmology*. 2002;109(5):890–899.
13. Dutton JJ. Optic nerve gliomas and meningiomas. *Neurol Clin*. 1991;9(1):163–177.
14. Mafee MF, Goodwin J, Dorodi S. Optic nerve sheath meningiomas: role of MR imaging. *Radiol Clin*. 1999;37(1):37–58.
15. Jakobiec FA, Depot MJ, Kennerdell JS, et al. Combined clinical and computed tomographic diagnosis of orbital glioma and meningioma. *Ophthalmology*. 1984;91(2):137–155.
16. Parker RT, Owens CA, Fraser CL, Samarawickrama C. Optic nerve sheath meningiomas: prevalence, impact, and management strategies. *Eye Brain*. 2018;10:85–99.
17. Schick U, Dutt U, Hassler W. Surgical management of meningiomas involving the optic nerve sheath. *J Neurosurg*. 2004;101(6):951–959.

18. Zoia C, Bongetta D, Pagella F, Antoniazzi ER, Gaetani P. New surgical option for optic nerve sheath meningiomas: fully endoscopic transnasal approach. *Can J Ophthalmol*. 2018;53(4):e142–e144.
19. Wright JE, Call NB, Liaricos S. Primary optic nerve meningioma. *Br J Ophthalmol*. 1980 Aug;64(8):553–558.
20. Bloch O, Sun M, Kaur G, Barani LJ, Parsa AT. Fractionated radiotherapy for optic nerve sheath meningiomas. *J Clin Neurosci*. 2012;19(9):1210–1215.
21. Hamilton SN, Nichol A, Truong P, et al. Visual outcomes and local control after fractionated stereotactic radiotherapy for optic nerve sheath meningioma. *Ophthalmic Plast Reconstr Surg*. 2018;34(3):217–221.
22. Moyal L, Vignal-Clermont C, Boissonnet H, Alapetite C. Résultats de la protonthérapie ciblée fractionnée dans le traitement des méningiomes primitifs de la gaine du nerf optique [Results of fractionated targeted proton beam therapy in the treatment of primary optic nerve sheath meningioma]. *J Fr Ophtalmol*. 2014;37(4):288–295.
23. Multisession radiosurgery for optic nerve sheath meningiomas (ONSMsmSRS). 2013 november. Accessed at: <https://clinicaltrials.gov/ct2/show/NCT02594709>.