

Pregnancy luteoma: A rare case report

Vaishali Verma, Surinder Paul, KS Chahal, Jaspreet Singh

Department of Pathology, Government Medical College, Amritsar, Punjab, India

ABSTRACT

Pregnancy luteomas are rare, nonneoplastic lesions of the ovary thought to be caused by the hormonal effects of pregnancy. Most of these patients are asymptomatic with the ovarian enlargement being incidentally discovered during imaging or surgery. Some patients develop hirsutism or virilization during late pregnancy. Luteomas spontaneously regress postpartum. It may be a diagnostic and management challenge as it can mimic the presentation of malignant ovarian tumors. We present a 33-year-old female with an enlarged ovary discovered incidentally at the time of cesarean section.

Key words: Cesarean section, postpartum, pregnancy luteoma

Submission: 23-01-2016 **Accepted:** 18-05-2016

INTRODUCTION

Pregnancy luteoma is a rare nonneoplastic tumor-like lesion of the ovary that was first described by Sternberg and Barclay in 1966, and to date, fewer than 200 cases have been reported in literature.^[1] It is usually discovered incidentally at the time of a cesarean section or during postpartum tubal ligation. Most cases resolve completely postpartum.^[2] An accurate diagnosis is important for both mother and fetus since it can be confused with ovarian malignancy leading to unnecessary oophorectomy, with concomitant risk to both mother and fetus.^[3]

CASE REPORT

The present case report is about a 33-year-old full-term pregnant woman, a known case of Type I diabetes mellitus who was admitted in obstetrics ward. The patient underwent cesarean section. A female baby was delivered uneventfully. Intraoperatively, surgeons found right-sided ovarian mass. Suspecting it to be an ovarian neoplasm, unilateral

oophorectomy was performed. The specimen was submitted for histopathological examination in 10% formalin.

Macroscopic examination showed an enlarged ovary measuring 6 cm × 5 cm × 3.5 cm. Cut surface of the ovary was circumscribed, soft, fleshy, and gray-brown [Figure 1]. Microscopically, sections from right ovarian mass revealed a lesion composed of diffuse masses of cells arranged in sheets, nests, and cords [Figure 2]. The cells were polygonal in shape and had abundant amount of finely granular eosinophilic cytoplasm. Nuclei were small, round, vesicular with prominent nucleoli. Occasional mitotic figures, areas of necrosis, and focal areas of hemorrhage were noted. Based on the clinical and histopathological findings, a diagnosis of pregnancy luteoma was made. Reinke crystals were not found in the sections studied; therefore, Leydig cell tumor and steroid cell tumor were ruled out and final diagnosis of pregnancy luteoma was made.

DISCUSSION

Pregnancy luteomas are benign tumors of lutein-like cells and are variable in size, ranging from microscopic to over 20 cm in diameter.^[4] Large luteomas rarely can cause torsion, resulting

Address for correspondence: Dr. Vaishali Verma,
Government Medical College, Room No. 61, G Block Girls Hostel,
Amritsar, Punjab, India.
E-mail: vmbbs@gmail.com

Access this article online

Quick Response Code:



Website:

www.ijabmr.org

DOI:

10.4103/2229-516X.192600

This is an open access article distributed under the terms of the Creative Commons Attribution-NonCommercial-ShareAlike 3.0 License, which allows others to remix, tweak, and build upon the work non-commercially, as long as the author is credited and the new creations are licensed under the identical terms.

For reprints contact: reprints@medknow.com

How to cite this article: Verma V, Paul S, Chahal KS, Singh J. Pregnancy luteoma: A rare case report. *Int J App Basic Med Res* 2016;6:282-3.

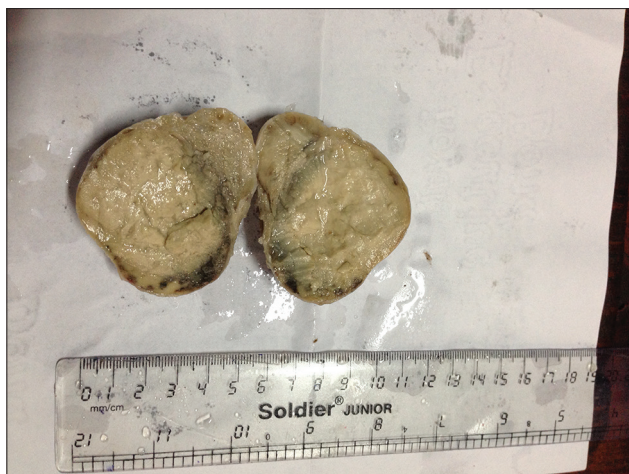

Figure 1: Gross examination

in acute abdominal pain. On gross examination, cut surfaces of luteomas are solid, soft, tan, or flesh colored, with hemorrhagic foci. Microscopically, luteomas are sharply circumscribed nodules composed of polygonal cells arranged in sheets, cords, or small clusters or form follicles containing colloid-like material. The cytoplasm is abundant eosinophilic and finely granular. The nuclei may be slightly pleiomorphic. In 25% of the cases, luteomas are hormonally active leading to secretion of androgens causing maternal hirsutism and virilization.^[5] Virilization of the female fetus occurs in half of the patients with maternal hirsutism, which results in clitoral enlargement and ambiguous genitalia. Male fetuses are not affected by this condition. The index case did not show any signs of virilization in either mother or baby; hence, hormonal studies were not done in our case.

There are some conditions that predispose a woman to form a luteoma during pregnancy. Polycystic ovary syndrome is one such condition.^[3] The high levels of hormones in polycystic ovary syndrome seem to be the predisposing factor for pregnancy luteoma. Other risk factors associated with luteomas are multiple pregnancies and advanced maternal age. Women who have already had a luteoma during a previous pregnancy have a higher risk of having another luteoma.

The differential diagnosis for pregnancy luteomas includes granulosa cell tumors, thecomas, Sertoli-Leydig cell tumors, pure Leydig (hilar) cell tumors, stromal hyperthecosis, stromal luteomas, and hyperreactio luteinalis. Because of the solid nature of the mass, it is impossible to differentiate luteomas from other solid ovarian neoplasms such as luteinized thecoma, granulosa cell tumor, or Leydig cell tumor based on imaging characteristics alone.

Malignant ovarian neoplasms are rare in pregnant women. Since luteomas regress spontaneously following drop in chorionic gonadotropin after delivery, observation of an adnexal lesion compatible with luteoma in the short-term

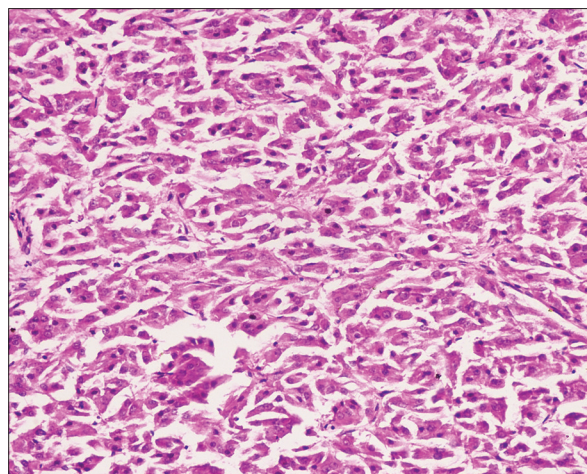


Figure 2: Microscopic examination

postpartum period could be considered in the proper clinical setting. Ovaries and serum testosterone usually return to normal size and levels at 2–3 weeks postpartum.^[6]

CONCLUSION

Pregnancy luteoma is a rare condition which probably represents an unusual response to the altered hormonal environment in pregnancy. These present a diagnostic and management challenge in that they can simulate the presentation of malignant ovarian tumors. When there is a high clinical suspicion for pregnancy luteoma, conservative management is appropriate since these tumors will usually regress spontaneously.

Acknowledgment

This case report is dedicated to beloved father of first author, Late Dr. Rana Verma.

Financial support and sponsorship

Nil.

Conflicts of interest

There are no conflicts of interest.

REFERENCES

1. Spitzer RF, Wherrett D, Chitayat D, Colgan T, Dodge JE, Salle JL, *et al.* Maternal luteoma of pregnancy presenting with virilization of the female infant. *J Obstet Gynaecol Can* 2007;29:835-40.
2. Garcia-Bunuel R, Berek JS, Woodruff JD. Luteomas of pregnancy. *Obstet Gynecol* 1975;45:407-14.
3. Phelan N, Conway GS. Management of ovarian disease in pregnancy. *Best Pract Res Clin Endocrinol Metab* 2011;25:985-92.
4. Clement PB. Tumor-like lesions of the ovary associated with pregnancy. *Int J Gynecol Pathol* 1993;12:108-15.
5. Zander J, Mickan H, Holzmann K, Lohe KJ. Androluteoma syndrome of pregnancy. *Am J Obstet Gynecol* 1978;130:170-7.
6. Joshi R, Dunaif A. Ovarian disorders of pregnancy. *Endocrinol Metab Clin North Am* 1995;24:153-69.