

Streptococcus group C meningitis with cavernous sinus thrombosis

Matthew Clarke¹
Hilary Enuh¹
Jessie Saverimuttu²
Jay Nfonoyim³

¹Department of Medicine, ²Division of Infectious Disease, ³Critical Care Unit, Richmond University Medical Center, Staten Island, NY, USA

Abstract: Group C Streptococcus (GCS) is a rare cause of bacteremia in humans. It is mostly associated with zoonological infections. Although GCS can be part of the normal oral, skin, and genitourinary flora, an infection with this pathogen can be highly virulent, causing rapid, disseminating disease. With a mortality of about 25%, the poor prognosis is linked to the severity of illness and the high level of virulence of the organism. Only a few cases of GCS meningitis have been reported. We present the first case of GCS meningitis with cavernous sinus thrombosis.

Keyword: streptococcus group C, cavernous sinus thrombosis, meningitis

Case report

An eighteen year old African American male presented to the emergency room with a 1-week history of sore throat, muscle aches, fever, headache, and photophobia. He also complained of nausea, one episode of vomiting, and abdominal pain. He was a college student and lived in a dormitory. He denied any recent travel or contact with ill people. Past medical history was significant for sickle cell trait and Osgood Schlatter's disease. He was up to date on vaccinations.

Physical examination revealed a tall, thinly built young man, in mild pain with an oral temperature of 97.5°F, blood pressure of 114/69 mmHg, heart rate of 89 beats per minute (BPM) and respirations of 18/minute. He had injected conjunctiva of the right eye, and pharyngeal and tonsillar exudates. The examination of the central nervous system revealed neck stiffness; Kernig's and Brudzinski's signs were not elicited. Cranial nerves were intact. The power and deep tendon reflexes were essentially normal. The rest of the systemic examinations were unremarkable.

Hemoglobin was 17.5 g/dL, hematocrit 50.8 g/dL, and white count $20.3 \times 10^9/L$ with 89% granulocytosis, and platelet count of $35 \times 10^9/L$. Basic metabolic profile was within normal limits, except for a potassium level of 3.2 meq/L, blood urea nitrogen of 44.9 mg/dL, and creatinine of 2.3 mg/dL. Chest X-ray revealed bilateral infiltrates in the middle and lower lung fields. Computed tomography (CT) of the head was unremarkable. The patient declined lumbar puncture. The blood culture grew penicillin sensitive Group C Streptococcus (GCS) within 24 hours of incubation. A few hours into the admission, he developed third and sixth nerve palsy. Further work-up revealed right cavernous and ophthalmic vein thrombosis on magnetic resonance imaging (Figures 1 and 2). Multiple patchy cavitary lesions on both lungs were seen in the chest CT. There was no vegetation on transesophageal echocardiogram. The oculomotor and abducens palsies resolved after medical management for 16 days.

Correspondence: Jessie Saverimuttu
Division of Infectious Disease,
Department of Medicine, Richmond
University Medical Center, Staten Island
NY 10310, USA
Email jsaverimuttu@rumcsi.org

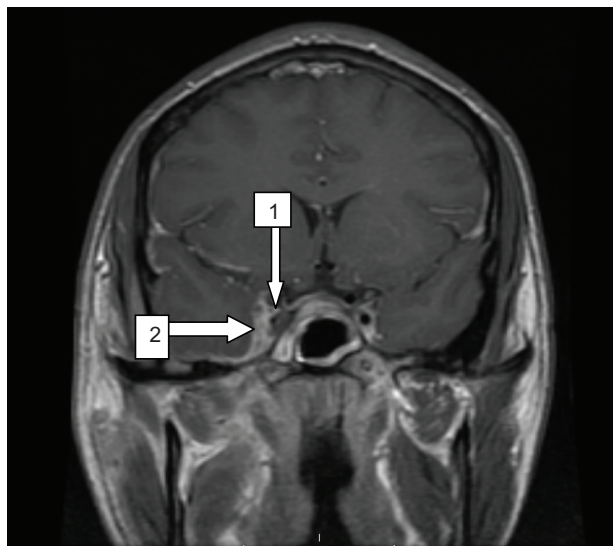


Figure 1 A band of enhancement measuring 6 mm in thickness is seen along the medial margin of the right temporal convexity (arrow #2). Increased T2 Signal in the region of the right cavernous sinus with diminished enhancement is suggestive of cavernous sinus thrombosis (arrow #1).

Discussion

GCS is a rare cause of bacteremia, mostly associated with zoonological infections.¹⁻⁸ It can cause a mucopurulent pulmonary disease in horses and mastitis in cattle.^{2,3} In humans, GCS can be part of the normal oral, skin, and genitourinary flora but, GCS infection can be highly virulent, causing rapid, disseminating disease²⁻⁴ carrying with it a mortality of

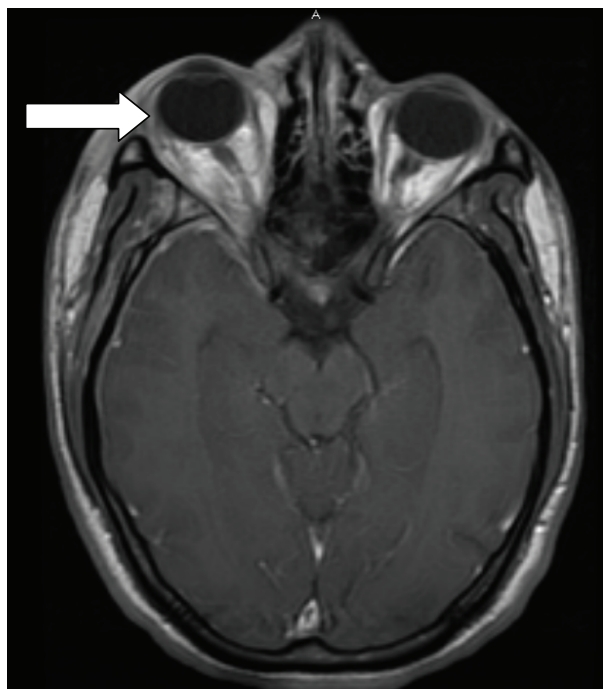


Figure 2 Right eye proptosis (arrow).

about 25%.^{4,5} The dismal prognosis is linked to the severity of illness and the high level of virulence of the organism.²

This group of Streptococci can be differentiated from other species by their hemolysis pattern and their ability to ferment sorbitol and trehalose.⁴ Examples of major species include *Streptococcus equisimilis*, *S. zooepidemicus*, *S. equi*, *S. dysgalactiae*, with the most common type isolated from the human throat being *S. milleri*.^{1-4,6,7} Unfortunately, one of our limitations was our laboratory was unable to identify the species of GCS. One study, which was based on the throat swabs of 1,016 college patients, showed that GCS was associated with pharyngitis.³ This is significant concerning our patient as he had complained of symptoms of sore throat and had a tonsillar exudate.

Cases of virulent GCS infections are rare. GCS meningitis, though rare, has a strong association with patients who were in close contact with infected animals or consumed unpasteurized milk.^{1,2,6-9} Huang et al reported 13 cases of GCS meningitis;² of these cases, five died, four suffered permanent neurological sequelae of some kind, and four recovered without lasting sequelae.² To the best of our knowledge, ours is the first case of GCS meningitis with cavernous sinus thrombosis. Adverse outcomes can still occur despite timely initiation of appropriate antimicrobial treatment.^{2,4,5} Blood cultures taken 24 hours after starting treatment would be negative, as well as cerebrospinal-fluid analysis. This exceptionally rapid eradication rate of the pathogen exists in the presence of continued fever spikes and a worsening clinical picture,² as was the case for our patient. He continued to have symptoms of fever and chills for at least 7–10 days after starting treatment.

A classic presentation of meningitis includes nuchal rigidity, fever, headache, and photophobia. However, without aggressive treatment, patients can rapidly develop more severe signs such as tetraparesis,⁹ aortic aneurysms, osteomyelitis and lymphadenitis,⁵ hearing loss, and blindness.^{2,4,5}

A possible complication of meningitis can be the development of a thrombosis in the cavernous sinus. Cavernous sinus thrombosis is the formation of a blood clot within the cavernous sinus. This is a cavity at the base of the brain which drains deoxygenated blood from the brain back to the heart. The cause is usually from a spreading infection in the nose, sinuses, ears, or teeth. *S. aureus* and *Streptococcus* are often the culpable bacteria. Cavernous sinus thrombosis symptoms include: decrease or loss of vision, chemosis, exophthalmos, headaches, and paralysis of the cranial nerves that course through the cavernous sinus, features which were observed in our patient. This infection is life-threatening and requires

immediate treatment, which usually includes antibiotics and sometimes surgical drainage.

When the patient originally entered the hospital he was started on extended coverage antibiotics: ceftriaxone and vancomycin. Once the diagnosis was established, and given the history of a penicillin allergy, we decided to begin treatment with chloramphenicol, one gram intravenously, every 6 hours. He was started on dexamethasone every 4 hours for the orbital edema. Twelve to 24 hours later, the sensitivity profile showed that the pathogen was susceptible to only penicillin G. At this juncture, it was decided to desensitize the patient to penicillin. He did not suffer any ill effects of the desensitization and his antibiotic regimen was switched to intravenous penicillin G, four million units every 4 hours. Due to risk of bleeding, considering patient's low platelet count, the decision was made to not fully anticoagulate our patient, but to manage him with 5000 units of subcutaneous heparin three times daily. Some advocate for the use of gentamicin, an aminoglycoside, with penicillin G to create a synergistic effect in severely ill patients or those who are immunocompromised.¹⁰ Our patient continued this treatment regimen for 6 weeks. During these 6 weeks he developed an empyema, which had to be drained with a chest tube, likely secondary to septic emboli. After drainage, the patient did well and was discharged.

GCS infection is a rare cause of meningitis in humans. It has a high virulence and affected patients may suffer permanent neurologic sequela. Prior pharyngitis from this organism is an important risk factor. Oculomotor or abducens palsy in patients with meningitis further indicates thrombosis of the cavernous sinus since these nerves pass through the sinus.

To our knowledge we have presented the first case of GCS meningitis with cavernous sinus thrombosis.

Disclosure

The authors report no conflicts of interest in this work.

References

1. Turner JC, Fox A, Fox K, et al. Role of group C beta-hemolytic streptococci in pharyngitis: epidemiologic study of clinical features associated with isolation of group C streptococci. *J Clin Microbiol.* 1993;31(4):808–811.
2. Huang AR, Briedis DJ. Group C streptococcal endocarditis presenting as clinical meningitis: report of a case and review of the literature. *Can J Infect Dis.* 1992;3(5):247–252.
3. Turner JC, Hayden FG, Lobo MC, Ramirez CE, Murren D. Epidemiologic evidence for Lancefield group C beta-hemolytic streptococci as a cause of exudative pharyngitis in college students. *J Clin Microbiol.* 1997;35(1):1–4.
4. Carmeli Y, Ruoff KL. Report of cases of and taxonomic considerations for large-colony-forming Lancefield group C streptococcal bacteremia. *J Clin Microbiol.* 1995;33(8):2114–2117.
5. Poulin MF, Boivin G. A case of disseminated infection caused by *Streptococcus equi* subspecies *zooepidemicus*. *Can J Infect Dis Med Microbiol.* 2009;20(2):59–61.
6. Rajasekhar A, Clancy CJ. Meningitis due to group C *Streptococcus*: a case report and review of the literature. *Scand J Infect Dis.* 2010;42(8):571–578.
7. Minces LR, Brown PJ, Veldkamp PJ. Human meningitis from *Streptococcus equi* subsp *zooepidemicus* acquired as zoonoses. *Epidemiol Infect.* 2011;139(3):406–410.
8. Mori N, Guevara JM, Tilley DH, Briceno JA, Zunt JR, Montano SM. *Streptococcus equi* subsp *zooepidemicus* meningitis in Peru. *J Med Microbiol.* 2013;62(Pt 2):335–337.
9. Rivas MT, Pascual J, Sesar A. Group C streptococcus meningitis: a very uncommon condition. *Neurologia.* 2008;23(9):604–606. Spanish.
10. <http://www.uptodate.com> [homepage on the Internet]. Group C and Group G streptococcal infection. Weinberg AN; 2013 [updated May 25, 2010]. Available from: <http://www.uptodate.com/contents/group-c-and-group-g-streptococcal-infection>. Accessed July 8, 2013.

Infection and Drug Resistance

Publish your work in this journal

Infection and Drug Resistance is an international, peer-reviewed open-access journal that focuses on the optimal treatment of infection (bacterial, fungal and viral) and the development and institution of preventive strategies to minimize the development and spread of resistance. The journal is specifically concerned with the epidemiology of antibiotic

Submit your manuscript here: <http://www.dovepress.com/infection-and-drug-resistance-journal>

Dovepress

resistance and the mechanisms of resistance development and diffusion in both hospitals and the community. The manuscript management system is completely online and includes a very quick and fair peer-review system, which is all easy to use. Visit <http://www.dovepress.com/testimonials.php> to read real quotes from published authors.