

# The use of noninvasive electrocardiographic mapping in an exercise-induced and nonsustained atrial tachycardia ablation



Francesco Peruzza, MD, Massimiliano Maines, MD, Carlo Angheben, MD, Paolo Moggio, MD, Domenico Catanzariti, MD, Maurizio Del Greco, MD, FHRS

From Santa Maria del Carmine Hospital, Rovereto, Italy.

## Introduction

Focal atrial tachycardia (FAT) is a relatively uncommon form of supraventricular tachycardia. Radiofrequency catheter ablation (CA) is the gold standard treatment, with a high long-term success rate. However, it is clinically challenging to map and ablate nonsustained FAT. We report an unusual case of exercise-induced and nonsustained FAT approached with the aid of noninvasive electrocardiographic mapping.

## Case report

A 17-year-old male basketball player was referred to our institution for several episodes of palpitations and presyncope during strenuous exercise, especially if practiced in warm places. He had no family history suggestive for cardiac disease or sudden death. An electrocardiogram (ECG) showed ectopic atrial rhythm and early repolarization pattern (Figure 1A). A 2-dimensional echocardiography was completely normal. A cardiac MRI showed no pathological findings. A 24-hour ambulatory ECG recorded during basketball training showed more than 60 episodes of narrow-QRS tachycardia and more than 40 episodes of wide-QRS tachycardia (various degrees of aberrant ventricular conduction), with a maximum rate of 250 beats/min (Figure 1B).

An electrophysiological study was performed introducing through the femoral vein a decapolar steerable catheter (Dynamic XT; Bard, Lowell, MA) in the coronary sinus and a quadripolar catheter in the His bundle region (Bard) and right ventricular apex (Bard). During intravenous administration of isoproterenol (up to 10 µg/min) and pacing maneuvers, we were able to induce nonsustained FAT (max 4 beats), suggestive of a right atrium intracardiac activation earliest site.

**KEYWORDS** Catheter ablation; Electroanatomical mapping systems; Electro physiological study; Focal atrial tachycardia; Noninvasive electrocardiographic mapping (Heart Rhythm Case Reports 2021;7:278–282)

Conflict of Interest: The authors report no conflicts of interest. **Address reprint requests and correspondence:** Dr Francesco Peruzza, Department of Cardiology, Santa Maria del Carmine Hospital, Corso Verona 4, 38068, Rovereto (TN), Italy. E-mail address: [peruzza.francesco@gmail.com](mailto:peruzza.francesco@gmail.com).

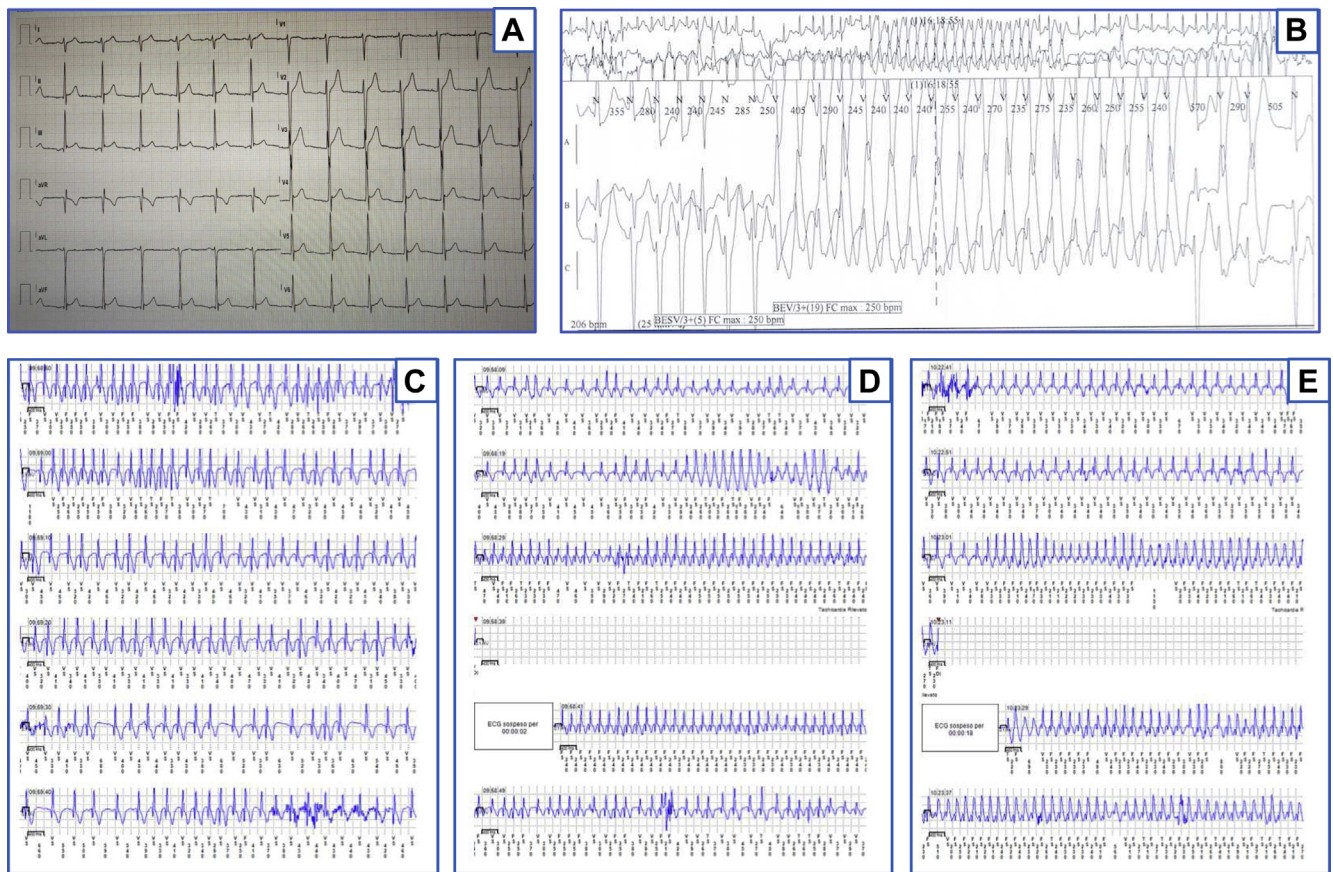
## KEY TEACHING POINTS

- Focal atrial tachycardia (FAT) arising from the superior vena cava is an uncommon form of supraventricular tachycardia.
- Exercise-induced and nonsustained FAT is a form of arrhythmia clinically challenging to map and ablate.
- Noninvasive electrocardiographic mapping can provide useful information about FAT mechanism, guiding catheter ablation.

Because of the limited reproducibility and nonsustainability of tachycardia, we decided to discontinue the procedure and to follow the patient with an implantable cardiac monitor (Medtronic Reveal LINQ; Medtronic, Minneapolis, MN).

During a strict monitoring we observed further arrhythmic relapses with the same characteristics as the previous ones (during strenuous exercise such as basketball training, bike ride, and gym session, Figure 1C–1E). Therefore it was decided that the patient undergo noninvasive electrocardiographic mapping (ECM) (CardioInsight; Medtronic), a system that collects chest ECG signals and combines them with computed tomography scan data. We performed ECM during exercise testing in a hot room, in order to reproduce the environmental conditions in which the FAT was triggered. We induced clinical atrial tachycardia and through repeated “single beat” analysis we created a potential map suggestive for anterior wall of superior vena cava (SVC) origin (Figure 2A–2D, online video).

We performed an ablation procedure with the CARTO 3 mapping system (Biosense Webster, Inc, Diamond Bar, CA). A PentaRay multipolar catheter (Biosense Webster, Inc) was advanced into the SVC, showing sharp vein potentials (Figure 3A). After phrenic nerve course identification through high-energy pacing, we performed segmental SVC isolation (SmartTouch; Biosense Webster, Inc) (Figure 3B and 3C, and online video) guided by circular mapping



**Figure 1** A: Basal electrocardiogram (ECG) showing an ectopic atrial rhythm, early repolarization pattern. B: Strip of a 24-hour ambulatory ECG recorded during basketball training showing an episode of large-QRS tachycardia (various degrees of aberrant ventricular conduction like right bundle branch block) with a maximum rate of 250 beats/min. C–E: Samples of LINQ (Medtronic, Minneapolis, MN) arrhythmic events recorded during basketball training, bike ride, and gym session.

catheter (LASSO; Biosense Webster, Inc), which then also allowed us to check entrance/exit block during intravenous adenosine administration.

During more than 1.5 years of follow-up with a loop recorder, the patient did not show new arrhythmic events.

## Discussion

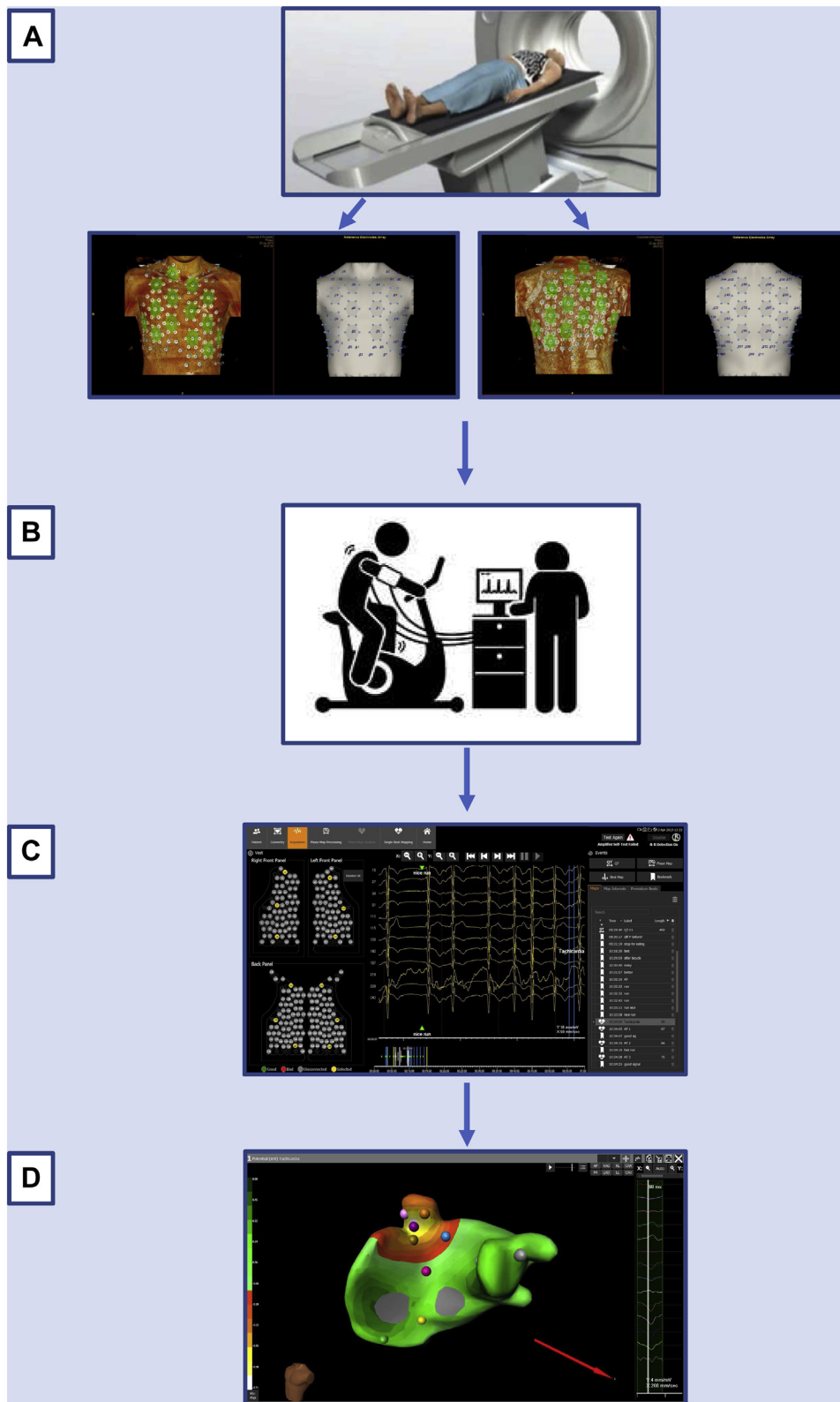
FAT is a relatively uncommon arrhythmia, accounting for up to 10% of supraventricular tachycardia.<sup>1</sup> It is generally characterized by a poor/unsatisfying response to drug therapy; CA represents the gold-standard treatment with high long-term success.<sup>2</sup> The use of 3-dimensional electroanatomical mapping systems combined with conventional techniques has remarkably helped the research of the earliest site of the intracardiac activation, reducing procedural and X-ray exposure time.<sup>3</sup> Nevertheless it is clinically challenging to map and ablate nonsustained FAT, mostly if inducible only in particular contexts such as during exercise, difficult to reproduce in the electrophysiology laboratory.

Strenuous exercise was the recognized trigger for FAT in our patient. This can be explained by the imbalance between the vagal and adrenergic elements in the left atrial ganglionated plexi, known to exist nearby the SVC. This mechanism

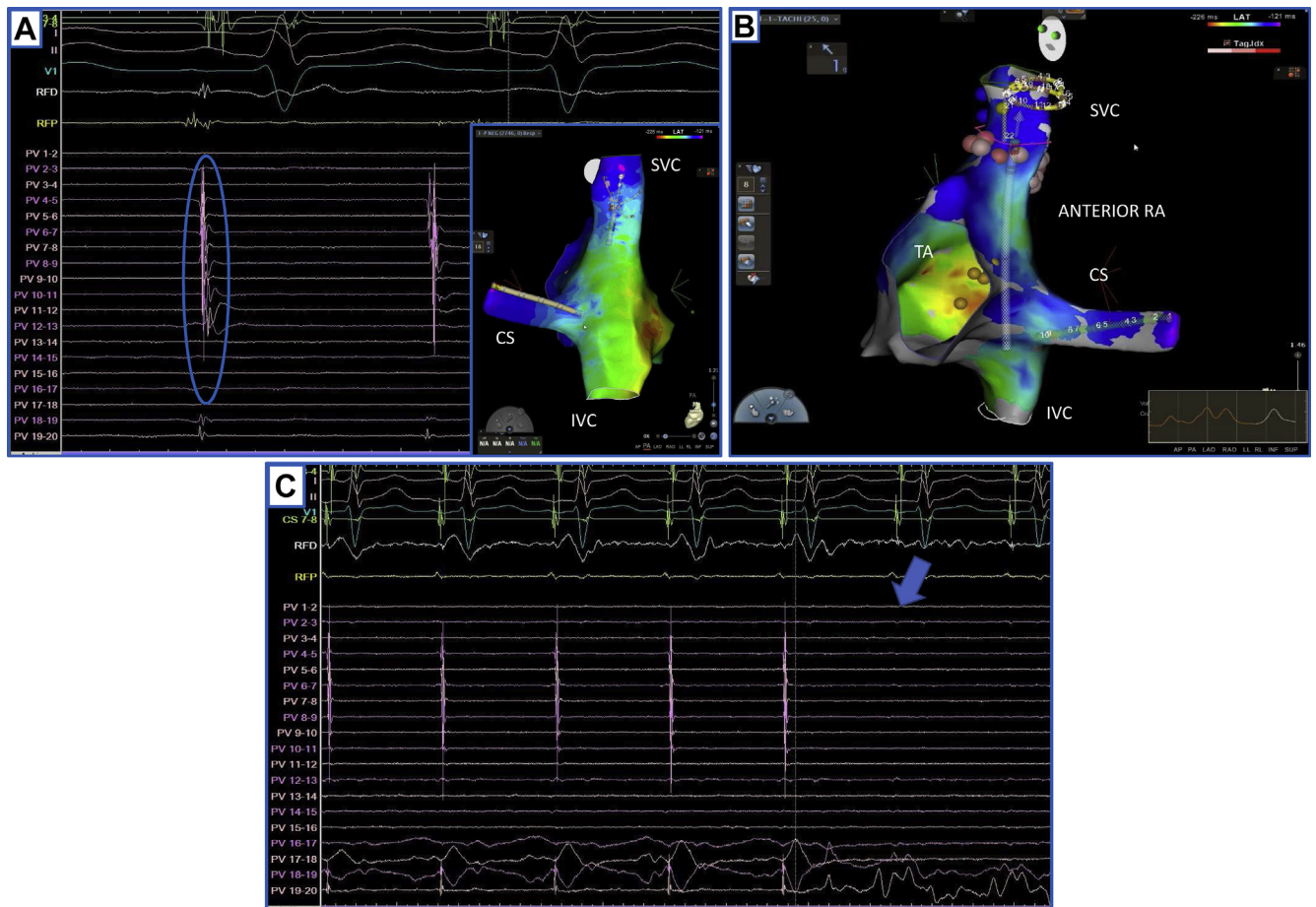
has been shown to induce triggered activity and subsequent atrial arrhythmogenic foci by the abbreviation of the local action potential duration and increased intracellular calcium transient currents via the ganglionated plexi, as previously reported. In our case FAT appeared after exercise was started and it ceased when the efforts terminated. This finding suggests the role of central modulation via the vagus nerve and the sympathetic nervous system, which can promote the formation of abnormal triggered activity, and subsequently lead to exercise-triggered FAT onset.<sup>4</sup>

The utility of exercise testing in reproducing supraventricular arrhythmias is not fully investigated in literature. Podrid and colleagues<sup>5</sup> recommended its use in arrhythmia management, even if a sustained supraventricular tachyarrhythmia is observed in only 1%–2% of patients undergoing an exercise testing; nevertheless, the frequency is higher in those with a history of such arrhythmia. We were able to induce the clinical atrial tachycardia only reproducing the environmental condition in which the FAT was triggered.

This case report describes an uncommon FAT induced only by efforts and arising from the SVC. Right atrium FAT is generally located in the crista terminals, near the tricuspid and mitral annulus, at the ostium of the coronary sinus, at the apex of the triangle of Koch, and at the right atrial



**Figure 2** Summary of noninvasive electrocardiographic mapping. **A:** A 252-electrode vest is applied to the patient's torso. It is followed by a noncontrast thoracic computed tomography scan to obtain high-resolution images of the heart and the vest electrodes. The electrodes' position and 3D epicardial biatrial geometry are obtained via segmentation from the computed tomography images. **B:** Vest is connected to the electrocardiographic mapping system and surface potentials are recorded. The patient starts exercise testing. **C:** During the exam focal atrial tachycardia (FAT) is triggered. **D:** The system reconstructs epicardial potentials and unipolar electrograms from torso potentials with "single beat analysis" using mathematical reconstruction algorithms. The platform creates a potential map, suggestive for FAT originating from the superior vena cava (SVC) or right atrium - SVC (Supplementary material online, [video 1](#)).



**Figure 3** Ablation procedure with CARTO 3 system (Biosense Webster, Inc, Diamond Bar, CA). **A:** After right atrium (RA) anatomical reconstruction, a PentaRay multipolar catheter (Biosense Webster, Inc) is advanced into the superior vena cava (SVC), showing rapid potentials (*blue circle*). **B:** After phrenic nerve course identification through high-energy pacing (*blue tags*) and replacing the PentaRay with a LASSO catheter (Biosense Webster, Inc), we perform SVC isolation (*red/rose tags*). **C:** Evidence of SVC isolation occurring during radiofrequency ablation; note the loss of signals on LASSO catheter (*blue arrow*). We confirm the isolation through circular mapping catheter and check entrance/exit block also during intravenous adenosine administration. CS = coronary sinus; IVC = inferior vena cava; TA = tricuspid annulus. (See supplementary material online, [video 2](#)).

appendage.<sup>6–8</sup> There are few isolated reports of FAT originating from the SVC.<sup>9,10</sup> Zhao and colleagues<sup>11</sup> reported a prevalence of 1.7% in a large series of FAT successfully ablated.

Because of the nonsustained nature of tachycardia, we could not precisely localize the origin of FAT during the first electrophysiological study, despite a high dosage of isoproterenol. ECM is a mapping technique that aims to noninvasively characterize cardiac electrical activity. The system reconstructs epicardial potentials as unipolar electrograms from torso potentials during each beat (“single beat analysis”) per cycle using mathematical reconstruction algorithms. Its efficacy has been demonstrated in a variety of arrhythmic scenarios, ranging from the mapping of premature ventricular complex and accessory pathways to the mapping of complex arrhythmias such as atrial fibrillation and ventricular tachycardia.<sup>12,13</sup>

To our knowledge, this is the first report that describes the use of CardioInsight during exercise testing for mapping an exercise-induced arrhythmia, opening up the possibility to use ECM in this distinctive arrhythmic scenario.

## Conclusion

Exercise-induced and nonsustained FAT is a challenging arrhythmia to map and ablate, and SVC is an unusual site of origin. Noninvasive ECM can accurately identify the mechanism of FAT in order to guide CA, allowing the mapping even during physical effort.

## Appendix Supplementary data

Supplementary data associated with this article can be found in the online version at <https://doi.org/10.1016/j.hrcr.2021.01.019>.

## References

- Porter MJ, Morton JB, Denman R, et al. Influence of age and gender on the mechanism of supraventricular tachycardia. *Heart Rhythm* 2004;1:393–396.
- Blomström-Lundqvist C, Scheinman MM, Aliot EM, et al. European Society of Cardiology Committee, NASPE-Heart Rhythm Society. ACC/AHA/ESC guidelines for the management of patients with supraventricular arrhythmias—executive summary. a report of the American College of Cardiology/American Heart Association Task Force on Practice Guidelines and the European Society of Cardiology Committee for Practice Guidelines (writing committee to develop guidelines for the

- management of patients with supraventricular arrhythmias) developed in collaboration with NASPE-Heart Rhythm Society. *J Am Coll Cardiol* 2003;42:1493–1531.
3. Casella M, Pelargonio G, Dello Russo A, et al. "Near-zero" fluoroscopic exposure in supraventricular arrhythmia ablation using the EnSite NavX™ mapping system: personal experience and review of the literature. *J Interv Card Electrophysiol* 2011;31:109–118.
  4. Lu Z, Scherlag BJ, Niu G, et al. Functional properties of the superior vena cava (SVC)-aorta ganglionated plexus: evidence suggesting an autonomic basis for rapid SVC firing. *J Cardiovasc Electrophysiol* 2010;21:1392–1399.
  5. Podrid PJ, Venditti FJ, Levine PA, Klein MD. The role of exercise testing in evaluation of arrhythmias. *Am J Cardiol* 1988;62:24H–33H.
  6. Kalman JM, Olgin JE, Karch MR, Hamdan M, Lee RJ, Lesh MD. "Cristal tachycardias": origin of right atrial tachycardias from the crista terminalis identified by intracardiac echocardiography. *J Am Coll Cardiol* 1998;31:451–459.
  7. Morton JB, Sanders P, Das A, Vohra JK, Sparks PB, Kalman JM. Focal atrial tachycardia arising from the tricuspid annulus: electrophysiologic and electrocardiographic characteristics. *J Cardiovasc Electrophysiol* 2001;12:653–659.
  8. Kistler PM, Fynn SP, Haqqani H, et al. Focal atrial tachycardia from the ostium of the coronary sinus: electrocardiographic and electrophysiological characterization and radiofrequency ablation. *J Am Coll Cardiol* 2005;45:1488–1493.
  9. Shah DC, Haïssaguerre M, Jaïs P, Clémenty J. High-resolution mapping of tachycardia originating from the superior vena cava: evidence of electrical heterogeneity, slow conduction, and possible circus movement reentry. *J Cardiovasc Electrophysiol* 2002;13:388–392.
  10. Tokutake K, Yamashita S, Yoshimura M, Yamane T. Focal atrial tachycardia from extremely high level of superior vena cava. *J Cardiovasc Electrophysiol* 2017;28:1355–1356.
  11. Zhao Z, Li X, Guo J. Electrophysiologic characteristics of atrial tachycardia originating from the superior vena cava. *J Interv Card Electrophysiol* 2009;24:89–94.
  12. Shah A, Hocini M, Haïssaguerre M, Jaïs P. Non-invasive mapping of cardiac arrhythmias. *Curr Cardiol Rep* 2015;17:60.
  13. Jamil-Copley S, Bokan R, Kojodjojo P, et al. Noninvasive electrocardiographic mapping to guide ablation of outflow tract ventricular arrhythmias. *Heart Rhythm* 2014;11:587–594.