

## CASE REPORT

# Clozapine-induced myocarditis

Tanuka Datta<sup>1,\*</sup> and Allen J. Solomon<sup>2</sup><sup>1</sup>Department of Internal Medicine, The George Washington University, Washington DC 20037, USA, and<sup>2</sup>Division of Cardiology, Department of Internal Medicine, The George Washington University, Washington, DC 20037, USA

\*Correspondence address. Department of Internal Medicine, The George Washington University, 2150 Pennsylvania Avenue NW, Washington, DC 20037, USA. Tel: +202-741-2222; Fax: +202-741-2427; E-mail: tdatta@email.gwu.edu

## Abstract

Approved in 1989 for the management of treatment-resistant schizophrenia, Clozapine is a last-line atypical antipsychotic drug used with increasing frequency. In addition to its well-known side effect of agranulocytosis, this drug also carries with it rare but serious adverse cardiovascular risk of myocarditis. We present a patient on Clozapine who was admitted to the cardiology service with chest pain, ST segment elevations and elevated troponin concerning for acute myocardial infarction. Evaluation with imaging revealed decreased left ventricular function, however, no coronary artery disease was present on catheterization; findings consistent with a diagnosis of myocarditis. Subsequent discontinuation of the patient's Clozapine and initiation of brief supportive medical therapy resulted in full recovery of systolic left ventricular function. Given the potential cardiovascular mortality risk, it is important for physicians on cardiology services caring for psychiatric patients to be aware of the presentation of symptoms, diagnostic findings and management of Clozapine induced myocarditis.

## INTRODUCTION

Clozapine is a last-line atypical antipsychotic agent used to treat patients with difficult to treat schizophrenia. It is classically known for its potential serious side effects of agranulocytosis, however also carries a boxed warning for an uncommon, but important association with adverse cardiovascular effects, namely myocarditis [1, 2]. In recent reviews, the incidence of myocarditis associated with Clozapine exposure is 3% [3, 4]. We report a case of a 40-year-old female started on Clozapine with subsequent development of myocarditis potentially relating to this agent. We focus in this vignette on the clinical management in a cardiac service as well as provide a brief literature review to understand the possible pathophysiology of Clozapine induced cardiotoxicity.

## CASE REPORT

A 40-year-old transgender male to female with history of schizophrenia initially presenting for suicidal ideation was admitted to the inpatient psychiatric unit. She was enrolled in the Clozapine risk evaluation and modification strategy program and started on the drug 7 days after admission. The medication was up-titrated to 50 mg in the morning and 150 mg at night. On Day 9, she reported chest pain. An EKG demonstrated new marked ST segment elevations in leads I, avL, II, and V4-V6 (see Figs 1 and 2). Laboratory results revealed elevated troponin of 12 ng/ml (normal range 0.000–0.034) and creatine kinase MB (CKMB) of 48 ng/ml (normal range 0.00–2.30). Given the EKG findings suggestive of acute ST segment elevation myocardial infarction (STEMI), she was transferred to our cardiac service.

Received: July 24, 2017. Revised: October 6, 2017. Accepted: October 26, 2017

© The Author 2018. Published by Oxford University Press.

This is an Open Access article distributed under the terms of the Creative Commons Attribution Non-Commercial License (<http://creativecommons.org/licenses/by-nc/4.0/>), which permits non-commercial re-use, distribution, and reproduction in any medium, provided the original work is properly cited. For commercial re-use, please contact journals.permissions@oup.com

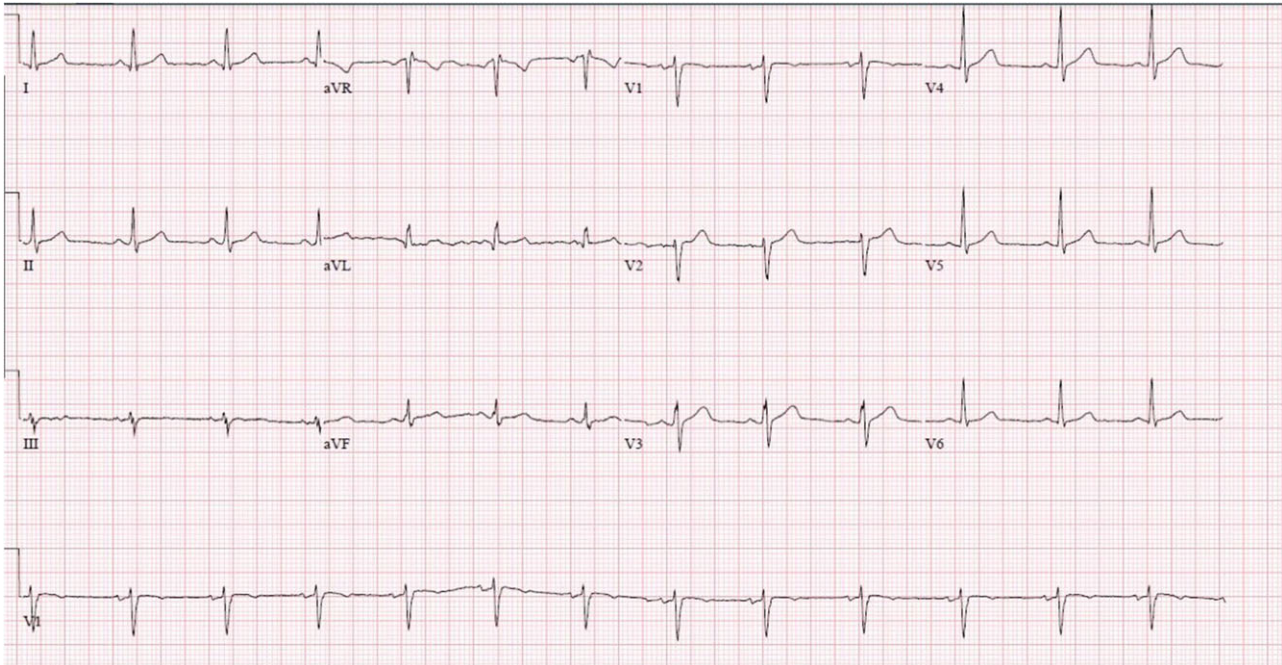

Figure 1: EKG prior to Clozapine initiation.

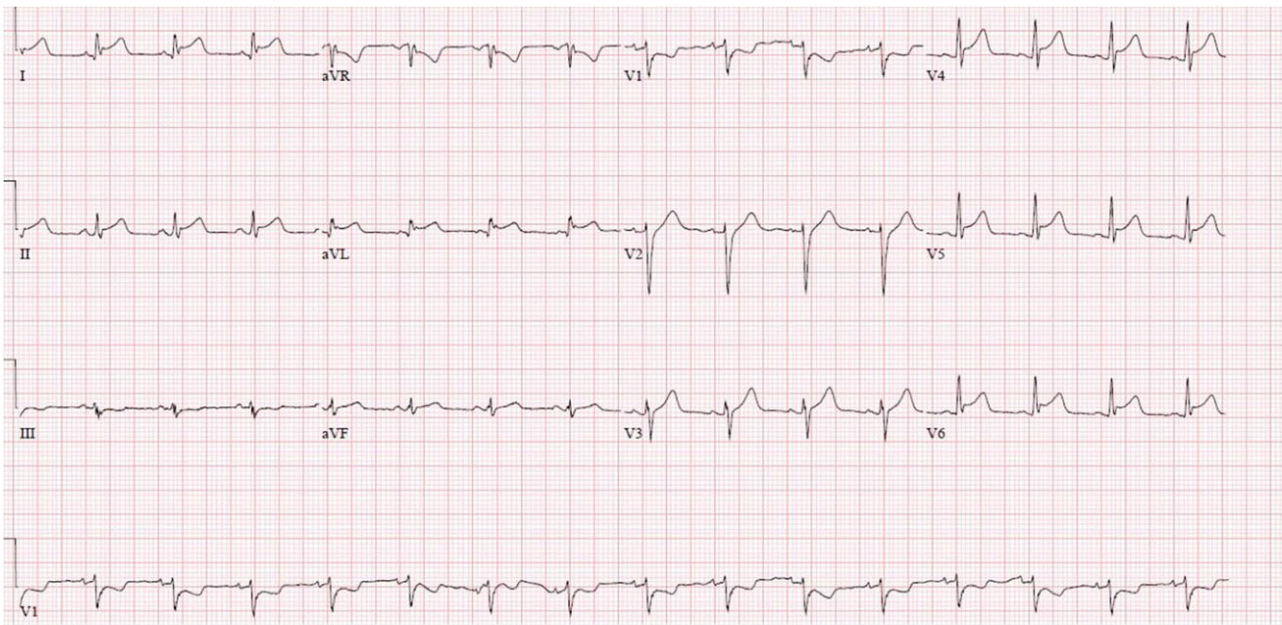


Figure 2: EKG during chest pain event after Clozapine therapy.

On initial evaluation, the patient described substernal chest pressure. Her past medical history revealed no cardiovascular disease risk factors. She denied having fevers, chills or upper respiratory symptoms. Her medication list included Clozapine, and prior single doses of Hydroxyzine, Haloperidol and Lorazepam. She took no medications at home. Her vital signs were stable, cardiac examination was normal. In addition to elevated troponin and CKMB, labs showed elevated brain natriuretic peptide (BNP) of 3070 pg/ml, erythrocyte sedimentation

rate (ESR) of 30 mm/h and C-reactive protein (CRP) of 36 mg/dl. An upper respiratory PCR panel was negative for influenza A/B and other viruses. A urine analysis revealed no signs of infection. A chest x-ray was unremarkable.

The patient was taken immediately to the catheterization lab and no occlusive coronary artery disease was seen. A transthoracic echocardiogram revealed ejection fraction of 30–35% with moderate global hypokinesis. Given high suspicion for drug induced myocarditis, Clozapine was stopped. The patient

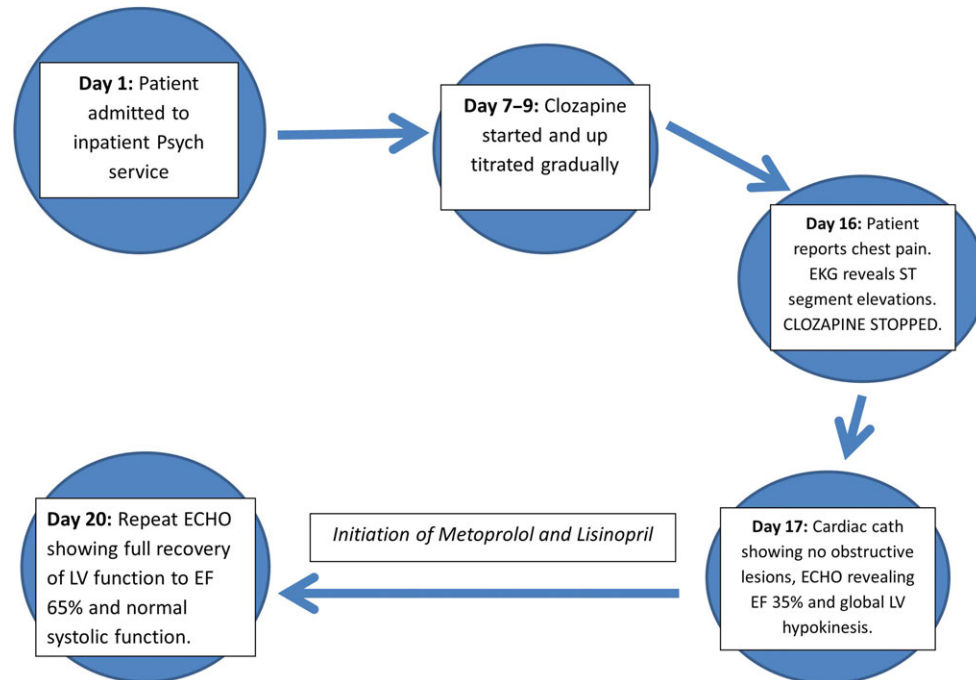


Figure 3: Timeline of events.

was monitored on telemetry and started on cardiac medical management with low doses of Metoprolol (12.5 mg twice a day) and Lisinopril (2.5 mg daily).

She remained chest pain free through the remainder of her course without development of shortness of breath, orthopnea or lower extremity swelling. On hospital Day 20 (4 days after discontinuation of Clozapine) a repeat transthoracic echocardiogram showed fully recovered left ventricular function with an ejection fraction of 65% and no wall motion abnormalities. Timeline of Events is shown in Fig. 3. Cardiac medications were discontinued and ventricular function remained recovered. The patient was transferred back to the psychiatry inpatient team in stable condition for further management of her schizophrenia.

## DISCUSSION

Development of myocarditis as a result of Clozapine therapy generally occurs within the first 2–8 weeks of therapy [5]. At time of diagnosis, the mean age of patients has been reported as 33.5 years with mean dose of Clozapine 360 mg [6]. Rule out of other etiologies of myocarditis/inflammatory cardiomyopathy with testing for viral respiratory infection, autoimmune diseases and giant cell myocarditis is imperative [7–9]. Laboratory testing to look for myocardial damage with elevated cardiac enzymes as well as evaluation of electrocardiogram and chest x-ray are standard measures. In our case, the diffuse ST segment elevations on electrocardiogram are seen with pericarditis however taking the entire clinical picture into context, myocarditis remained the leading diagnosis. Supportive evidence additionally includes elevated BNP and absence of hypertension or history of valvular disease. Echocardiogram to assess ventricular function and provide confirmation of developing ventricular failure is also helpful [5]. In the presence of reduced systolic function, a cardiac catheterization to confirm lack of obstructive or ischemic coronary disease further confirms a diagnosis of myocarditis. The role of re-challenging a

patient with Clozapine after myocarditis is controversial. While there have been mixed results, there are not enough cases with rechallenge reported to draw definitive conclusions. The decision depends upon patient discussion to weigh quality of life without Clozapine therapy versus risk of myocarditis on rechallenge. We did not rechallenge our patient. A major limitation in our diagnosis was the inability to obtain cardiac magnetic resonance imaging. In the absence of endomyocardial biopsy, this modality is important. Lastly, we could not confirm that the patient was not abusing any other substances no longer available once admitted, contributing to functional recovery.

Management of clozapine myocarditis is supportive and empiric [6]. Once the diagnosis is established, if drug induced myocarditis is suspected, the inciting agent should be discontinued immediately. Administration of diuretics, beta blockers and angiotensin converting enzyme inhibitors have been shown to support myocardial function during the acute myocardial insult [5]. Trending levels of inflammatory markers such as ESR and CRP have been suggested as ways to document recovery [10].

Discontinuation of Clozapine leads to cardiac functional recovery with a direct correlation in degree of compromised systolic function to degree of recovery, however mortality is still 12.5–24% [4, 6, 11]. The timeline of onset of cardiac functional recovery from the time of discontinuation of drug is variable. Discontinuation of Clozapine should be done with close liaison with Psychiatry colleagues as relapse of Schizophrenia may ensue leading to significant patient harm.

The mechanism of Clozapine induced myocarditis has not been well established. Links with geographical region based on ozone concentrations, genetic predisposition, Ig E mediated hypersensitivity and elemental deficiencies have been proposed. In a review conducted of 47 cases of Clozapine induced myocarditis, the development of eosinophilia suggesting IgE mediated hypersensitivity reaction has been documented in ~66% of cases [10]. The highest rates of Clozapine induced cardiomyopathy have been reported in New Zealand and Australia

possibly due to possibly increased blockade of M2 receptors and cholinergic receptor dysfunction in these areas of higher ozone concentrations [12]. Genetic predisposition is thought to be mediated by mutations in pharmacokinetic enzymes CYP450-1A2 and CY450-1A3 [6].

To further consider is inherent alpha-adrenergic blocking effects of antipsychotics [4]. This is supported by the fact that patients prescribed Clozapine are those exposed to many antipsychotics before initiation of this last line agent suggesting some degree of cumulative effect.

The role of sophisticated monitoring systems dedicated to detecting cardiovascular complications associated with clozapine has been established. Protocols focus mainly on keeping a high index of suspicion for early recognition of symptoms [13]. Ongoing discussions remain to include cardiac markers in weekly blood work along with markers of inflammation in these protocols.

In summary, our case highlights a rare yet potentially fatal cardiovascular complication potentially relating to Clozapine use. Recent cohort studies have shown that myocarditis and sudden cardiac death are uncommon in patients maintained on clozapine however given the fatal clinical significance, preventive measures need to be further studied [14]. Given lethal risk and boxed warning for cardiovascular toxicity, chest discomfort in a patient commencing Clozapine should be investigated for a symptom of myocarditis.

## ACKNOWLEDGEMENTS

All residents and medical staff that assisted in the care of this patient during her hospital stay.

## CONFLICT OF INTEREST STATEMENT

None declared.

## FUNDING

No funding was required.

## ETHICAL APPROVAL

No ethical approval was required.

## CONSENT

We obtained written signed patient consent for the presentation of this case.

## GUARANTOR

Tanuka Datta is the guarantor of this manuscript.

## REFERENCES

1. De Berardis D, Serroni N, Campanella D, Olivieri L, Ferri F, Carano A, et al. Update on the adverse effects of clozapine: focus on myocarditis. *Current drug safety* 2012;7: 55–62.
2. Annamraju S, Sheitman B, Saik S, Stephenson A. Early recognition of clozapine-induced myocarditis. *J Clin Psychopharmacol* 2007;27:479–83.
3. Ronaldson KJ, Fitzgerald PB, McNeil JJ. Clozapine-induced myocarditis, a widely overlooked adverse reaction. *Acta Psychiatr Scand* 2015;132:231–40.
4. Kilian JG, Kerr K, Lawrence C, Celermajer DS. Myocarditis and cardiomyopathy associated with clozapine. *Lancet* 1999; 354:1841–5.
5. Curto M, Girardi N, Lionetto L, Ciavarella GM, Ferracuti S, Baldessarini RJ. Systematic review of clozapine cardiotoxicity. *Curr Psychiatry Rep* 2016;18:68.
6. Alawami M, Wasywich C, Cicovic A, Kenedi C. A systematic review of clozapine induced cardiomyopathy. *Int J Cardiol* 2014;176:315–20.
7. Dennert R, Crijns HJ, Heymans S. Acute viral myocarditis. *Eur Heart J* 2008;29:2073–82.
8. Caforio AL, Pankuweit S, Arbustini E, Basso C, Gimeno-Blanes J, Felix SB, et al. Current state of knowledge on aetiology, diagnosis, management, and therapy of myocarditis: a position statement of the European Society of Cardiology Working Group on Myocardial and Pericardial Diseases. *Eur Heart J* 2013;34:2636–48, 48a–48d.
9. Heymans S, Eriksson U, Lehtonen J, Cooper LT Jr. The quest for new approaches in myocarditis and inflammatory cardiomyopathy. *J Am Coll Cardiol* 2016;68:2348–64.
10. Ronaldson KJ, Taylor AJ, Fitzgerald PB, Topliss DJ, Elsik M, McNeil JJ. Diagnostic characteristics of clozapine-induced myocarditis identified by an analysis of 38 cases and 47 controls. *J Clin Psychiatry* 2010;71:976–81.
11. La Grenade L, Graham D, Trontell A. Myocarditis and cardiomyopathy associated with clozapine use in the United States. *N Engl J Med* 2001;345:224–5.
12. Yost BL, Gleich GJ, Fryer AD. Ozone-induced hyperresponsiveness and blockade of M2 muscarinic receptors by eosinophil major basic protein. *J Appl Physiol* 1999;87: 1272–8.
13. Munshi TA, Volochniouk D, Hassan T, Mazhar N. Clozapine-induced myocarditis: Is mandatory monitoring warranted for its early recognition? *Case reports in psychiatry* 2014;2014:513108.
14. Khan AA, Ashraf A, Baker D, Al-Omary MS, Savage L, Ekmejian A, et al. Clozapine and incidence of myocarditis and sudden death—Long term Australian experience. *Int J Cardiol* 2017;238:136–9.