



Case Report

Recurrent Tolosa–Hunt syndrome

Phyo-Wai Thu^{a#}, Yu-Ming Chen^a, Weng-Ming Liu^{a,b,*}

^aDepartment of Neurology,
Hualien Tzu Chi Hospital,
Buddhist Tzu Chi Medical
Foundation, Hualien, Taiwan,

^bDoctoral Degree Program in
Translational Medicine, Tzu Chi
University and Academia Sinica,
Hualien, Taiwan

[#]Author has two names -
Phyo-Wai Thu @ Jun-Ming Zhao

Submission : 03-Jun-2020
Revision : 29-Jun-2020
Acceptance : 15-Jul-2020
Web Publication : 15-Oct-2020

ABSTRACT

The Tolosa–Hunt syndrome (THS) is caused by granulomatous inflammation in the cavernous sinus, superior orbital fissure, or orbit characterized by painful ophthalmoplegia. Here, we report a case of recurrent THS in a 48-year-old female, who initially showed a poor response to low-dose steroids. Each episode involved different cranial nerves and painful ophthalmoplegia. Neuroimaging showed enhancement in the right cavernous sinus. The patient was treated with glucocorticoid pulse therapy and azathioprine. THS was previously considered to be responsive to glucocorticoids. This report demonstrates a case of THS with poor response to steroids and unique presentation of frequent recurrence with different cranial nerve involvement.

KEYWORDS: *Cranial neuropathy, Differential diagnosis, Painful ophthalmoplegia, Tolosa–Hunt syndrome, Treatment*

INTRODUCTION

Tolosa–Hunt syndrome (THS), presenting as painful ophthalmoplegia, is rare, with an estimated incidence of one to two cases per million/year [1]. Half of the patients experience recurrent attacks at intervals of months or years [2]. These recurrences may be ipsilateral, contralateral, or rarely bilateral. Glucocorticoids are the mainstay of treatment, and symptoms usually resolve quickly with treatment [2]. Because several etiologies cause painful ophthalmoplegia, THS should be diagnosed after excluding other possible diagnoses.

CASE REPORT

A 48-year-old female with a history of steroid-responsive right-sided Bell's palsy at 43 and 47 years of age presented with acute diplopia and right retro-orbital pain for 3 days. Neurological examination showed right-sided horizontal binocular diplopia caused by right abducens palsy. Non-contrast-enhanced brain magnetic resonance imaging (MRI) was unremarkable. Vital signs and laboratory data, including random blood sugar, were within normal ranges.

We prescribed oral prednisolone 60 mg daily, but her symptoms progressed with oculomotor nerve involvement after 1 week [Figure 1]. Extensive screening for infectious, autoimmune, metabolic, and endocrine abnormalities revealed newly diagnosed diabetic mellitus (HbA1C: 7.8%). Contrast-enhanced brain MRI showed enhancement in the right cavernous sinus [Figure 2].

Cerebrospinal fluid (CSF) examination revealed mildly elevated CSF protein (47.2 mg/dL) and glucose (101 mg/dL)

with a normal cell count. Other CSF parameters, including cytology and infection screenings, were normal. We suspected THS according to clinical and radiologic findings.

We started methylprednisolone 500 mg daily. However, symptoms progressed to total ophthalmoplegia with impaired visual acuity and color vision, indicating optic nerve involvement and impaired sensations in the ophthalmic (V1) and maxillary (V2) divisions of the right trigeminal area. Anticipating an occult infection flare-up, we switched intravenous steroids to low-dose oral prednisolone and added empirical antibiotics. Intravenous heparin was administered until angiography excluded cavernous sinus thrombosis and other vascular problems. After CSF and blood cultures were negative, we restarted intravenous high-dose steroids. Her visual acuity, color vision, eye movements, and pupillary reflexes gradually recovered after 1 week. Follow-up brain MRI showed resolving enhancement of the right cavernous sinus. The patient was discharged with low-dose oral prednisolone.

The patient experienced two more attacks at an interval of 2 months, coincidentally after tapering steroids. At each recurrence, MRI showed contrast enhancement in the right cavernous sinus. Her symptoms resolved with high-dose methylprednisolone at each episode. The second attack showed vertical and horizontal diplopia, retro-orbital pain, ptosis, and impaired facial sensation resulting from trochlear, oculomotor,

*Address for correspondence:

Dr. Weng-Ming Liu,
Doctoral Degree Program in Translational Medicine, Tzu Chi University
and Academia Sinica, 701, Section 3, Zhongyang Road, Hualien, Taiwan.
E-mail: wengming111@hotmail.com

Access this article online

Quick Response Code:



Website: www.tcmjmed.com

DOI: 10.4103/tcmj.tcmj_137_20

This is an open access journal, and articles are distributed under the terms of the Creative Commons Attribution-NonCommercial-ShareAlike 4.0 license, which allows others to remix, tweak, and build upon the work non-commercially, as long as appropriate credit is given and the new creations are licensed under the identical terms.

For reprints contact: WKHLRPMedknow_reprints@wolterskluwer.com

How to cite this article: Thu PW, Chen YM, Liu WM. Recurrent Tolosa–Hunt syndrome. Tzu Chi Med J 2021;33:314-6.

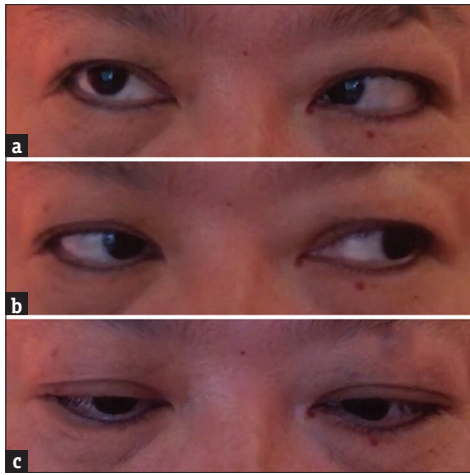


Figure 1: (a) The limitation of abduction of the right eye when looking to the right, (b) subtle limitation of adduction of the right eye when looking to the left, (c) convergence difficulty due to limitation of adduction of the right eye

and trigeminal involvements. The third attack involved the right abducens and trigeminal nerves. We administered azathioprine after the second attack to avoid a hyperglycemic response to high-dose steroids. Subsequently, we decided to maintain a low dose of steroids. Two months after the last episode, follow-up MRI revealed resolving contrast enhancement. No recurrent episodes occurred after we used combined azathioprine and low-dose prednisolone.

DISCUSSION

We presented a unique case of recurrent THS involving different ipsilateral cranial nerves that initially showed a poor response to low-dose glucocorticoids and later required combined glucocorticoid and azathioprine to prevent recurrence. Our case indicated that combination of immunosuppressants might be necessary for recurrent THS.

Based on the third edition of the International Classification of Headache Disorders, THS is diagnosed when the patient has one or more of the ipsilateral third, fourth, and sixth cranial nerves palsies with MRI or biopsy findings of granulomatous inflammation of the cavernous sinus, superior orbital fissure or orbit, without other causes explaining ophthalmoplegia. It is preceded or accompanied by orbital or periorbital headache [3]. Symptoms are similar to recurrent painful ophthalmoplegic neuropathy, which typically begins in childhood, involving ocular motor nerves [4]. Moreover, the lesion can extend beyond the cavernous sinus and orbit, involving the optic nerve and cranial nerves other than the ocular motor nerves [5]. Our patient had two previous episodes of ipsilateral Bell’s palsy. Although the facial nerve is the most frequently involved cranial nerve that runs outside the cavernous sinus in THS [6], without painful ophthalmoplegia or neuroimaging evidence at her previous Bell’s palsy episodes, we could not attribute those episodes to THS.

THS is the diagnosis of exclusion and a rare cause of multiple cranial neuropathies in which brainstem and extramedullary peripheral lesions should be considered first [7]. In cases of ophthalmoplegia, involvement of the ophthalmic and maxillary divisions of the trigeminal nerve helps localize the

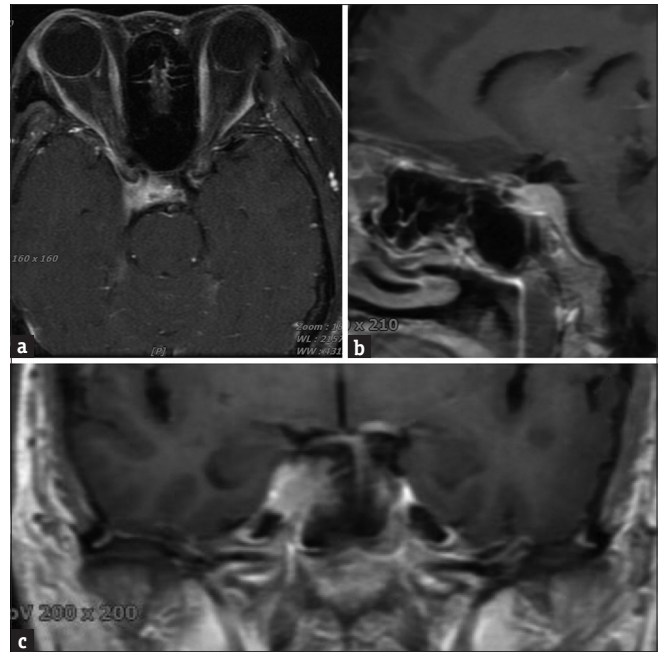


Figure 2: Postgadolinium T1 weighted magnetic resonance image showing (a) axial view: Contrast-enhanced lesion in right cavernous sinus extending to the superior orbital fissure and orbital apex. There was no mass effect nor peripheral edema around the lesion. (b) sagittal view: Contrast-enhanced at the skull base without invasion of brain tissue. (c) coronal view: Enhanced lesion prominently involved right cavernous sinus

Table 1: Notable causes of cavernous sinus and parasellar lesions producing ophthalmoplegia

Type of origin	Disease
Vascular	Cavernous sinus thrombosis
	Carotid-cavernous fistula
	Carotid artery aneurysm
	Intracavernous aneurysm
Neoplasm	Pituitary adenoma
	Craniopharyngioma
	Meningioma
	Nasopharyngeal carcinoma
	Pituitary adenoma or craniopharyngioma
Trauma Inflammatory disorders	Metastasis
	Mucormycosis
	Mycobacterium tuberculosis
	Sarcoidosis
	Wegener’s granulomatosis
	Polyarteritis nodosa
	Tolosa-Hunt syndrome

cavernous sinus. Impaired visual acuity suggests optic nerve involvement. The cavernous sinus is the most common site of multiple cranial nerve involvements, representing 25% of cases. Common causes are vascular, neoplastic, and inflammatory disorders [Table 1] [2,7]. Some cases of multiple isolated cranial nerves palsy with anti-GD1 antibody positivity have been described before [8].

The mainstay of treatment for THS is a short course of steroid therapy [2]. It needs to be cautioned that other

Table 2: Summary of previously reported treatments

	Classification	Medication	Dosage	References
First line	Steroid	Prednisolone	Variable	Kline LB <i>et al.</i> , 2001
		Methylprednisolone	500-1000 mg/day	Zhang X <i>et al.</i> , 2014
Second line	Immunosuppressant	Azathioprine	2 mg/kg/day	Mazzotta G <i>et al.</i> , 2004
		Cyclosporine	2-5 mg/kg/day	Bielory L <i>et al.</i> , 1991
		Methotrexate	7.5-25 mg/week	Kwon HS <i>et al.</i> , 2020
		Mycophenolate mofetil	1-2 g/day	Hatton MP <i>et al.</i> , 2005
	Monoclonal antibody	Infliximab	3-5 mg/kg/infusion	Halabi T <i>et al.</i> , 2018
		Adalimumab	40 mg/week	Wiener J <i>et al.</i> , 2019
	Radiotherapy		Total 30-60 Gy	Mormont E <i>et al.</i> , 2000

parasellar neoplasms that present as multiple cranial nerve palsies are also responsive to steroids. Recurrent and refractory THS can be treated with azathioprine, cyclosporine, methotrexate, mycophenolate mofetil, infliximab, and radiotherapy [Table 2] [9,10]. The same treatment regimen can be applied for other recurrent cranial neuropathies. Infectious causes should be excluded before empirical corticosteroids are administered. In the absence of a clear etiology, a meningeal biopsy before steroids may be considered. Although THS is generally thought to be quickly responsive to steroids, specific recommendations regarding the dosing of steroids vary. One recommendation for clinically severe cases is to start with high-dose intravenous methylprednisolone 1000 mg daily for 3–5 days followed by high-dose oral prednisone with further dose tapering based on the clinical response [7].

In conclusion, THS should be carefully diagnosed by excluding the possible differential diagnoses, particularly infections and neoplasms. Glucocorticoids remain the first-line treatment, while azathioprine and other immunomodulating drugs can be considered as steroid-sparing or second-line therapy.

Declaration of patient consent

Authors certify that the patient has provided signed informed consent. In the consent form, the patient has given her consent for her images and other clinical information to be reported in the journal. The patient understands that her name and initials will not be published, and due efforts will be made to conceal her identity, but anonymity cannot be guaranteed.

Acknowledgment

We acknowledge Dr. Raymond Y. Lo and Dr. Sheng-Huang Lin's clinical advice during treatment for the patient.

Financial support and sponsorship

Nil.

Conflicts of interest

There are no conflicts of interest.

REFERENCES

- Iaconetta G, Stella L, Esposito M, Cappabianca P. Tolosa-Hunt syndrome extending in the cerebello-pontine angle. *Cephalalgia* 2005;25:746-50.
- Kline LB, Hoyt WF. The Tolosa-Hunt syndrome. *J Neurol Neurosurg Psychiatry* 2001;71:577-82.
- Parisi P, Belcastro V, Verrotti A, Striano P, Kasteleijn-Nolst Trenitè DGA. "Ictal epileptic headache" and the revised International Headache Classification (ICHD-3) published in *Cephalalgia* 2018, vol. 38 (1) 1-211: Not just a matter of definition! *Epilepsy Behav* 2018;87:243-5.
- Smith SV, Schuster NM. Relapsing Painful Ophthalmoplegic Neuropathy: No longer a "Migraine," but Still a Headache. *Curr Pain Headache Rep* 2018;22:50.
- Hao R, He Y, Zhang H, Zhang W, Li X, Ke Y. The evaluation of ICHD-3 beta diagnostic criteria for Tolosa-Hunt syndrome: A study of 22 cases of Tolosa-Hunt syndrome. *Neurol Sci* 2015;36:899-905.
- Kansu T, Us O, Sarpel G, Araç N. Recurrent multiple cranial nerve palsies (Tolosa-Hunt plus?). *J Clin Neuroophthalmol* 1983;3:263-6.
- Carroll CG, Campbell WW. Multiple cranial neuropathies. *Semin Neurol* 2009;29:53-65.
- Simon O, Lacour A, Delval A, Beaume A, Vermersch P. Recurrent multiple cranial nerve palsy and anti-GD1a antibodies. *Muscle Nerve* 2011;43:447-8.
- Hannerz J. Recurrent Tolosa-Hunt syndrome. *Cephalalgia* 1992;12:45-51.
- Kwon HS, Kim TY, Kim JH, Bae JH, Koh SH, Choi H, et al. Use of methotrexate in the management of recurrent Tolosa-Hunt syndrome: Two case reports. *Medicine (Baltimore)* 2020;99:e19882.