



Open Access

ORIGINAL ARTICLE

Male Fertility

# Vitamin B<sub>12</sub>-induced spermatogenesis recovery in cimetidine-treated rats: effect on the spermatogonia number and sperm concentration

Flávia L Beltrame<sup>1</sup>, Estela Sasso-Cerri<sup>2</sup>

The H<sub>2</sub>-receptor antagonist cimetidine is an antiulcer drug also used for the treatment of cancer due to its antiangiogenic effect. However, this drug has caused structural changes in the seminiferous tubules. Vitamin B<sub>12</sub> has been used as a therapeutic agent for the treatment of male infertility. The supplementation of rats with vitamin B<sub>12</sub> during cimetidine treatment has recovered the damaged seminiferous tubules, but how this vitamin restores the seminiferous epithelium has not been clarified. In this study, we evaluated whether vitamin B<sub>12</sub> improves the number of spermatogonia, spermatocytes, and sperm concentration in cimetidine-treated rats. Adult male rats were treated for 50 days as follows: cimetidine group received 100 mg kg<sup>-1</sup> b.w. of cimetidine, cimetidine-B<sub>12</sub> group received cimetidine and 3 µg of vitamin B<sub>12</sub>-hydroxocobalamin, B<sub>12</sub> group received only 3 µg of vitamin, and control group received saline. Sperm concentration was calculated and historesin-embedded testes sections were used for the quantitative analyses of spermatogonia (A; In/B) and spermatocytes. TUNEL method and PCNA immunofluorescence were performed. Cimetidine caused a significant reduction in sperm concentration. TUNEL-positive spermatogonia and spermatocytes were correlated to a significant reduction in the number of these cells. In cimetidine-B<sub>12</sub> group, sperm concentration was higher than cimetidine group and a significant increase in the number of spermatogonia (stages II–VI) was correlated to a high incidence of PCNA-immunolabeled spermatogonia and spermatocytes. The results show that the supplementation of rats with vitamin B<sub>12</sub> during cimetidine treatment increases sperm concentration and exerts a potential effect in the recovery of spermatogonia and spermatocytes.

*Asian Journal of Andrology* (2017) 19, 567–572; doi: 10.4103/1008-682X.182397; published online: 26 August 2016

**Keywords:** cimetidine; fertility; spermatogenesis; testis; vitamin B<sub>12</sub>

## INTRODUCTION

Numerous studies have been focused on the infertility causative factors in attempt to find modes of stimulating sperm concentration and quality.<sup>1</sup> A lot of attention has been paid to the therapeutic properties of plant extracts, antioxidants, amino acids, and vitamins, including the effects of these agents on fertility.<sup>2</sup> Vitamin B<sub>12</sub> has been widely used in traditional medicine for the treatment of male infertility, especially when the cause is oligozoospermia or asthenozoospermia.<sup>3,4</sup> This vitamin, also known as cobalamin, is a water-soluble vitamin, essential in the nutrition, found in foods of animal origin, including dairy products. This vitamin plays an important role in DNA synthesis and cell division<sup>5</sup> and is an essential cofactor for methionine synthase during the production of purines and pyrimidines.<sup>6</sup> Thus, it is essential for the processes that require high cell renewal rate as the seminiferous epithelium. Studies on the relationship between vitamin B<sub>12</sub> and male reproductive performance have demonstrated that this vitamin is essential for the maintenance of testicular function.<sup>7</sup> Testicular changes, including atrophy of seminiferous tubules, have been demonstrated in vitamin B<sub>12</sub> deficient rodents;<sup>8,9</sup> however, the supplementation with vitamin B<sub>12</sub> can restore the altered testicular parameters. Reduction in the diameter of seminiferous tubules and in

sperm count caused by the treatment with the antineoplastic doxorubicin has been softened by the treatment with vitamin B<sub>12</sub>.<sup>10,11</sup> Studies performed in our laboratory have also demonstrated that the supplementation of rats with vitamin B<sub>12</sub> during the treatment with cimetidine can restore the seminiferous epithelium damaged by this drug.<sup>12</sup>

Cimetidine is clinically used as an antiulcer, competing for histamine H<sub>2</sub> receptors in the gastric parietal cells.<sup>13</sup> This drug also exerts an antioxidant effect due to its inhibitory activity of cytochrome P450 in several biological systems, especially in liver,<sup>14,15</sup> and has also been used as an adjuvant therapy in some types of cancer due to its antiangiogenic effect.<sup>16,17</sup> However, in male patients, cimetidine has been reported to cause some adverse effects, such as loss of libido, impotence, and gynecomastia,<sup>18–20</sup> which has been related to an antiandrogenic effect.<sup>21,22</sup> Reduction of testis, prostate, and seminal vesicles weight and changes in the hormonal levels have been observed,<sup>21,23–26</sup> confirming the antiandrogenic effect of this drug.

In testes, this drug has caused significant histopathological disorders in the seminiferous tubules, including reduction of the tubular diameter and epithelial area due to detachment<sup>27,28</sup> and loss of germ cells by apoptosis.<sup>28</sup> This tubular alteration seems to be a consequence of the

<sup>1</sup>Department of Morphology and Genetics, Federal University of São Paulo (UNIFESP/EPM), São Paulo, Brazil; <sup>2</sup>Department of Morphology, Laboratory of Histology and Embryology, Dental School – São Paulo State University (UNESP/FOAR), Araraquara, São Paulo, Brazil.

Correspondence: Dr. E Sasso-Cerri (esasso@foar.unesp.br)

Received: 09 October 2015; Revised: 08 December 2015; Accepted: 29 January 2016

interference of cimetidine on the peritubular tissue<sup>28–30</sup> and Sertoli cell death.<sup>28,30</sup> Recently, studies have demonstrated that cimetidine causes testicular microvasculature atrophy,<sup>31</sup> reduction in the number of Leydig cells due to apoptosis, and decrease in the testosterone serum levels.<sup>32</sup> These vascular and hormonal changes seem to be the main causative effects of the seminiferous tubules structural disruption.<sup>31,32</sup>

Independently, of the effect of cimetidine on the seminiferous tubules, the supplementation of the cimetidine-treated rats with vitamin B<sub>12</sub> has demonstrated to recover the number of Sertoli cells and the seminiferous epithelium area;<sup>12</sup> however, the way by which these testicular parameters are recovered by this vitamin is not yet clarified.

A correlation between vitamin B<sub>12</sub> and sperm parameters in human semen from both fertile and infertile males has indicated that this vitamin is essential for spermatogenesis and maintenance of normal sperm function.<sup>33</sup> Furthermore, the vitamin B<sub>12</sub> supplementation reduces the oxidative stress provoked by freezing-thawing and improves bovine semen quality.<sup>34,35</sup> Thus, vitamin B<sub>12</sub> seems to be a useful therapeutic strategy to improve sperm quality. However, since 1970, scarce studies have focused on the effect of this vitamin on spermatogenesis and/or sperm parameters. In this study, we investigated the role of vitamin B<sub>12</sub> on the cimetidine-induced germ cell loss, focusing on the number of spermatogonial germ cells, spermatocytes, and sperm concentration in adult rats.

## MATERIALS AND METHODS

### Animal treatment

The animal care and the experimental procedures were conducted following the National Law on Animal Use. The protocol of this study was approved by the Ethics Committee for Animal Research of São Paulo Federal University - UNIFESP/EPM, Brazil (CEUA n° 7950060514) and by the Ethics Committee/Institutional Review Board of Dental School – São Paulo State University (UNESP), Araraquara, São Paulo, Brazil (CEUA n° 28/2014).

Twenty Holtzman male rats (*Rattus norvegicus albinus*) aged 100 days were maintained in polypropylene cages under 12-h light/12-h dark cycle at a controlled temperature (23 ± 2°C), with water and food provided *ad libitum*. The animals were distributed into four groups, containing five animals each: cimetidine (CMTG), cimetidine/vitamin B<sub>12</sub> (CMT/B<sub>12</sub>G), vitamin B<sub>12</sub> (B<sub>12</sub>G), and control group (CG).

The animals from CMTG received daily intraperitoneal (i.p.) injections of 100 mg of cimetidine (Hycimet®, 300 mg - Hypofarma, MG, Brazil) per kg b.w.<sup>32</sup> This dosage was based on the therapeutic dose range of cimetidine usually administered in humans which is 800–1200 mg day<sup>-1</sup> (~=17 mg kg<sup>-1</sup> day<sup>-1</sup>) for gastric or ulcer treatment, and 2000 mg day<sup>-1</sup> (~=28.5 mg kg<sup>-1</sup> day<sup>-1</sup>) for the treatment of Zollinger–Ellison syndrome.<sup>36</sup> Applying the BW<sup>3/4</sup> scaling for the calculation of dosage to be applied to animal model (rats),<sup>37</sup> the dosage used in the present study (100 mg kg<sup>-1</sup>) is equivalent, in humans, to 27.5 mg kg<sup>-1</sup> (1920 mg day<sup>-1</sup>). According to Brodgen *et al.*,<sup>36</sup> doses of cimetidine below 2400 mg day<sup>-1</sup> do not cause systemic toxicity. Thus, the dosage used approaches the human therapeutic range. It is important to emphasize that this protocol of treatment with cimetidine was used in attempt to induce seminiferous epithelium damage and verify whether vitamin B<sub>12</sub> can improve the cimetidine-induced changes.

The animals from CMT/B<sub>12</sub>G received i.p. injections containing a solution of 100 mg kg<sup>-1</sup> b.w. of cimetidine and 3 µg of vitamin B<sub>12</sub>-hydroxocobalamin (Rubranova®, 5000 µg – Bristol-Myers Squibb, São Paulo, Brazil). This dosage of vitamin was determined from a preliminary evaluation of the quantity of daily food intake by the animals at this age.<sup>12</sup> The animals from B<sub>12</sub>G received only vitamin (3 µg day<sup>-1</sup>) and the control animals received saline solution,

corresponding to the volume of CMTG. All animals received the treatment for 50 consecutive days, period that corresponds to the duration of spermatogenesis in adult rats.<sup>38</sup>

### Sperm concentration

The animals were anesthetized with 80 mg kg<sup>-1</sup> b.w. of xylazine hydrochloride (Francotar; Virbac Brazil Ind. Com. Ltda., São Paulo, Brazil) and 8 mg kg<sup>-1</sup> b.w. of xylazine hydrochloride (Virbaxyl; Virbac Brazil Ind. Com. Ltda., São Paulo, Brazil). The sperm concentration was determined using caudal epididymal sperm of five animals per group. The epididymis was dissected and a small cut was made in the epididymal cauda with a razor blade. An aliquot (3 µl) of sperm was placed in 4 ml of distilled water to immobilize sperms. Sperm count was performed in a hemocytometer (Neubauer chamber).

After the experimental procedures, the animals were euthanized by overdose of anesthesia.

### Histological procedures

The testes were removed and fixed for 48 h at room temperature in 4% formaldehyde freshly prepared from paraformaldehyde (MERK, Germany) buffered at pH 7.4 with 0.1 mol l<sup>-1</sup> sodium phosphate. Subsequently, the testes were dehydrated in graded ethanol and embedded in glycol methacrylate (Historesin Embedding Kit, Jung, Germany) or paraffin. The historesin sections (3 µm) were stained with Gill's Hematoxylin and Eosin (H.E),<sup>39</sup> for morphological and morphometric analyses. The paraffin sections, 6 µm thick, were adhered to silanized slides and subjected to the TUNEL (Terminal deoxynucleotidyl-transferase mediated dUTP Nick End Labeling) method for detection of cell death and to the immunofluorescence reaction for detection of PCNA (Proliferating Cell Nuclear Antigen).

### Number of spermatogonia and spermatocytes

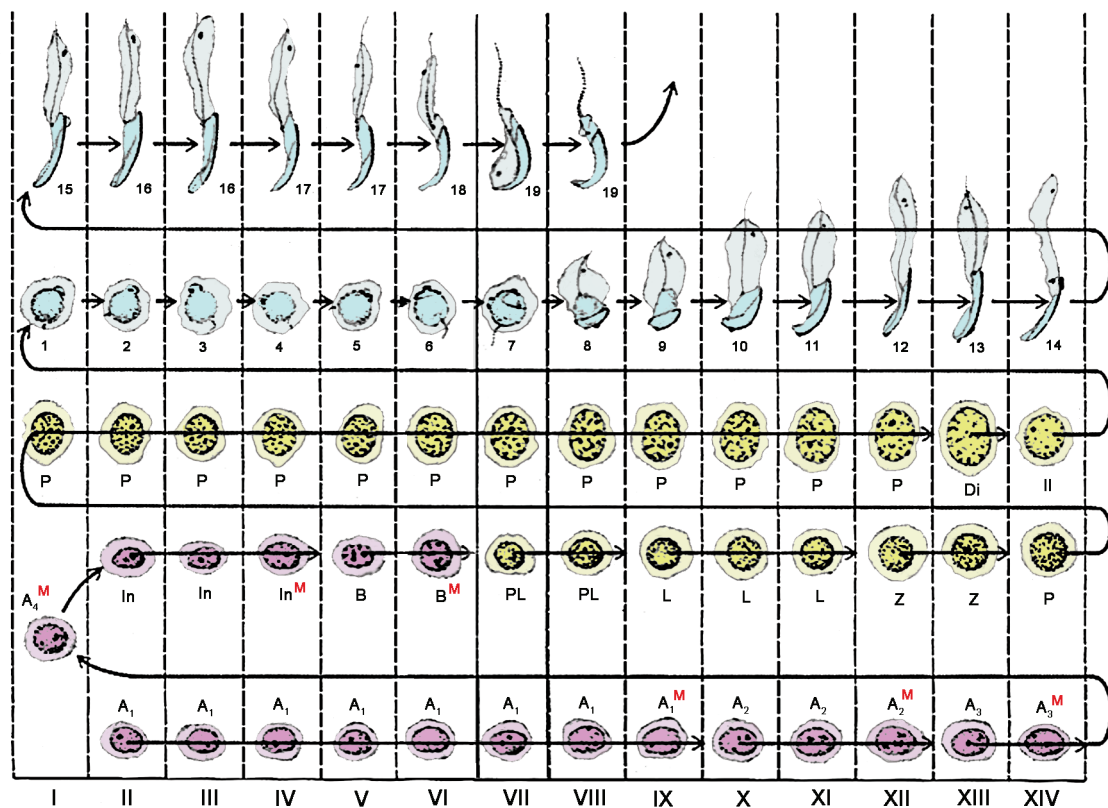
The images were captured using a DP-71 Olympus camera attached to an Olympus BX-51 light microscope. Four nonserial H.E.-stained testicular sections per animal were used, and in each section, 10 seminiferous tubules were captured at x345, totaling 40 tubules per animal. As the number of spermatogonia and spermatocytes varies according to the stages of the seminiferous epithelium cycle (Figure 1), 10 cross sections of seminiferous tubules were selected in each interval of cycle (stage I, stages II–VI, stages VII–VIII, and stages IX–XIV), according to Dym and Clermont,<sup>40</sup> for a standardized quantification. In each tubular section, spermatogonia and spermatocytes were quantified. Types A and Intermediate/B (In/B) spermatogonia were morphologically identified according to Chiarini-Garcia *et al.*<sup>41</sup> The quantification was performed by two calibrated and blinded examiners.

### TUNEL method

The protocol of TUNEL method was performed as previously described<sup>28,30–32</sup> and according to the ApopTag® Plus Peroxidase *In Situ* Apoptosis Detection Kit (Millipore; Temecula, CA, USA).

### Immunofluorescence reaction for detection of PCNA

Paraffin testicular sections adhered to silanized slides were immersed in 0.001 M sodium citrate buffer pH 6.0 and maintained at 90°C in a microwave oven for antigen recovery. After the inactivation of endogenous peroxidase in 9% hydrogen peroxide, the slides were washed in 50 mmol l<sup>-1</sup> phosphate-buffered saline containing 200 mmol l<sup>-1</sup> of sodium chloride (PBS) pH 7.3 and, then, incubated with 2% BSA. The testicular sections were incubated overnight with mouse anti-PCNA monoclonal primary antibody (Biocare Medical; Concord, CA, USA), diluted 1:100, in a humidified chamber at 4°C. Subsequently, the sections were incubated with Alexa Fluor 488® secondary antibody (Molecular Probes® by Life



**Figure 1:** Classification of the XIV different stages of the seminiferous epithelium cycle characterized in the rat. The vertical columns, designated by roman numerals, depict the cell associations. The letters designate specific germ cell types: type A (A<sub>1</sub>–A<sub>4</sub>), intermediate (In) and type B (B) spermatogonia; preleptotene (Pl), leptotene (L), zygotene (Z), pachytene (P), and diplotene (Di) primary spermatocytes and secondary spermatocytes (II). Mitotic divisions (M). The Arabic numbers (1–19) designate the steps of spermiogenesis (Modified from Dym and Clermont<sup>40</sup>).

Technologies, Carlsbad, CA, USA) for 1 h. DAPI (Molecular Probes® by Life Technologies, Carlsbad, CA, USA) was used for nuclear staining. Sections used as negative controls were incubated in nonimmunized serum instead of primary antibodies. The analysis was performed using a fluorescent microscope DM400 B LED, a camera DFC-550, and an Image Analysis System LAS4 (Leica, Germany).

**Statistical analysis**

Statistical analysis of data was performed using the GraphPad Prism® 4.0 software (GraphPad Software, CA, USA). The results were submitted to the one-way ANOVA followed by Tukey’s post-test. *P* < 0.05 was considered statistically significant.

**RESULTS**

**Sperm concentration**

The animals from CMTG showed reduction (*P* < 0.05) in sperm concentration in comparison to CG. Although sperm concentration in cimetidine/vitamin B<sub>12</sub>-treated rats was higher than that of cimetidine group, it was still reduced when compared to sperm concentration of rats from CG and B<sub>12</sub>G (Figure 2).

**Morphological results**

The seminiferous tubules of animals from CG and B<sub>12</sub>G showed seminiferous epithelium with normal aspect (Figures 3a and 3b, 4d). In the tubules at stages I–VI, types A and In/B spermatogonia were observed (Figure 3b).

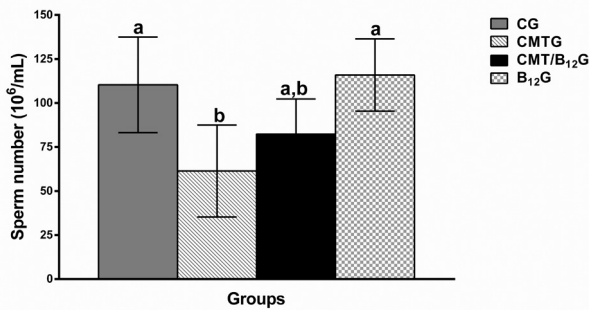
The seminiferous tubules of animals from CMTG showed reduction in the frequency of spermatogonia and spermatocytes (Figure 3c and 3d, Table 1). Moreover, these cells were also positive to the TUNEL method (Figure 3e). On the other hand, the seminiferous epithelium of animals from CMT/B<sub>12</sub>G showed an apparent increase in the incidence of spermatogonia and spermatocytes in comparison to CMTG (Figure 4a and 4c). In addition, spermatogonia in mitosis were also found (Figure 4b). In both groups treated with vitamin B<sub>12</sub> (CMT/B<sub>12</sub>G and B<sub>12</sub>G), germ cells in the basal portion of epithelium (spermatogonia and spermatocytes) were positive to the TUNEL method (Figure 4e and 4f).

In the sections subjected to immunofluorescence reaction for detection of PCNA, a low incidence of PCNA-immunolabeled spermatogonia and spermatocytes was observed in CMTG (Figure 5d–5f) while a high incidence of these immunolabeled cells (Figure 5g–5i) was observed in the vitamin B<sub>12</sub>-supplemented groups (CMT/B<sub>12</sub>G and B<sub>12</sub>G) in comparison to CG (Figure 5a–5c).

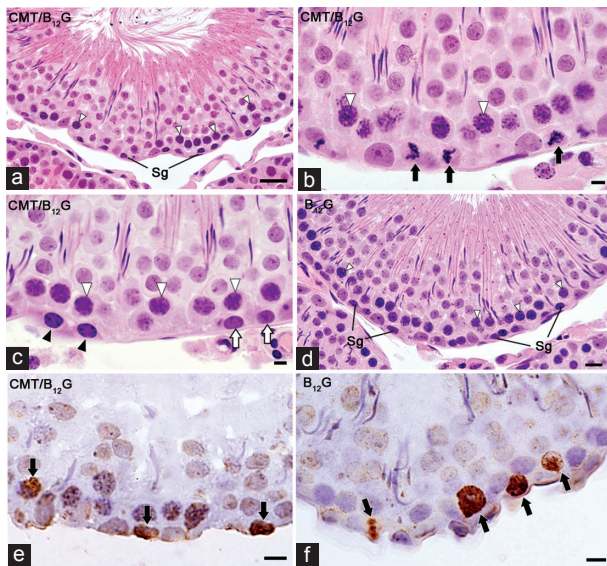
**Morphometric results**

In CMTG, a numerical reduction in type A spermatogonia (*P* < 0.05) and spermatocytes (*P* < 0.05) was observed in all stage intervals in comparison to CG. Otherwise, the seminiferous tubules of CMT/B<sub>12</sub>G showed an increase in the number of type A spermatogonia (stages I–VI; *P* < 0.05) and spermatocytes (all stages; *P* < 0.05) in comparison to CMTG (Tables 1 and 2). In this case, vitamin B<sub>12</sub> restored the number of spermatogonia and spermatocytes.





**Figure 2:** Sperm concentration of animals from CG, CMTG, CMT/B<sub>12</sub>G, and B<sub>12</sub>G.  $a \neq b$  ( $P < 0.05$ ). Data presented as mean  $\pm$  s.d. CG: control group; CMTG: cimetidine group; CMT/B<sub>12</sub>G: cimetidine/vitamin B<sub>12</sub> group; B<sub>12</sub>G: vitamin B<sub>12</sub> group.



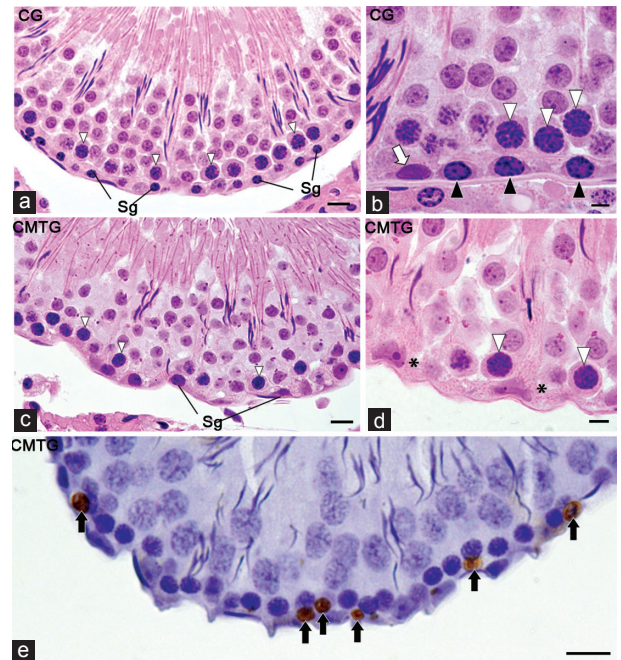
**Figure 4:** Photomicrographs of seminiferous tubules of animals from CMT/B<sub>12</sub>G and B<sub>12</sub>G, at stages I–VI, stained by H.E. (a–d) and subjected to TUNEL method (e and f). In 4a and 4d, numerous spermatogonia (Sg) and spermatocytes (white arrowheads) are observed. Some spermatogonia are in mitosis (4b; arrows). In 4c, types A (white arrows) and In/B (black arrowheads) spermatogonia and spermatocytes (white arrowheads). In 4e and 4f, TUNEL-positive spermatogonia and spermatocytes (arrows). Bars: 30  $\mu$ m (4a); 15  $\mu$ m (4d); 6  $\mu$ m (b, c, e, f). CMT/B<sub>12</sub>G: cimetidine/vitamin B<sub>12</sub> group; B<sub>12</sub>G: vitamin B<sub>12</sub> group; TUNEL: terminal deoxynucleotidyl-transferase mediated dUTP nick end labeling.

The number of spermatogonia and spermatocytes did not differ between CG and B<sub>12</sub>G groups.

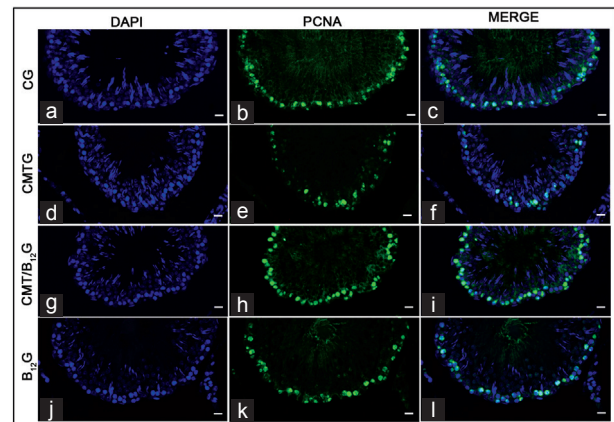
### DISCUSSION

The present findings show that cimetidine treatment causes significant reduction in the number of spermatogonia and spermatocytes and decreases epididymal sperm concentration. However, the supplementation of rats with vitamin B<sub>12</sub> during cimetidine treatment recovered the number of spermatogonia and spermatocytes and increased the sperm concentration.

The reduction in the number of spermatogonia and spermatocytes caused by cimetidine is due to cell death since TUNEL labeling was observed in these cells as also demonstrated in the previous study.<sup>28</sup> Moreover, the low incidence of PCNA-immunolabeled spermatogonia reinforces the interference of the treatment on these cells, leading to failure of spermatogenic process as a whole.



**Figure 3:** Photomicrographs of seminiferous tubules of animals from CG and CMTG at stages I–VI stained by H and E. (a–d) and subjected to TUNEL method (e). In 3a, the seminiferous epithelium with normal aspect shows numerous spermatogonia (Sg) and spermatocytes (white arrowheads). In 3b, type A (white arrow) and type In/B (black arrowheads) spermatogonia and spermatocytes (white arrowheads) are observed. In 3c and 3d, scarce spermatogonia (Sg) and spermatocytes (white arrowheads) are found. In 3d, note absence of spermatogonia in a portion of tubule (asterisks). In 3e, TUNEL-positive spermatogonia and spermatocytes (arrows) are observed. Bars: 15  $\mu$ m (a, c, e); 6  $\mu$ m (b, d). CG: control group; CMTG: cimetidine group; TUNEL: terminal deoxynucleotidyl-transferase mediated dUTP nick end labeling.



**Figure 5:** Photomicrographs of seminiferous tubules subjected to immunofluorescence for detection of PCNA. In CMTG (d–f), a low incidence of PCNA-positive spermatogonia and spermatocytes in comparison to the other groups. A high incidence of immunolabeled cells is observed in the control (a–c) and vitamin B<sub>12</sub>-supplemented groups (g–i). Bars: 15  $\mu$ m. PCNA: proliferating cell nuclear antigen; CMTG: cimetidine group.

Studies have demonstrated that the mitotic activity of spermatogonia is dependent on the synthesis of stem cell factor (SCF) by Sertoli cells and the expression of its receptor, c-kit protein.<sup>42</sup> The interaction between SCF and c-kit protein seems to modulate spermatogonial division.<sup>43</sup> Cimetidine treatment interferes in the peritubular tissue leading to Sertoli cell apoptosis and reduction in the number of these cells.<sup>12,28,30</sup> Thus, the reduction in the number of spermatogonia may be related to a

**Table 1: Number of types A and In/B spermatogonia, according to the stages of the seminiferous epithelium cycle, and total spermatogonia of rats from CG, B<sub>12</sub>G, CMTG, and CMT/B<sub>12</sub>G**

	I	II-VI		VII-VIII	IX-XIV	Total
	A	A	In/B	A	A	
CG	73±6.1 <sup>a</sup>	47±5.3 <sup>a</sup>	109±15.5 <sup>a</sup>	37±4.7 <sup>a</sup>	84±9.9 <sup>a</sup>	350±26.1 <sup>a</sup>
B <sub>12</sub> G	65±3.2 <sup>a</sup>	40±4.4 <sup>a</sup>	115±28.9 <sup>a</sup>	35±4.3 <sup>a</sup>	76±3.7 <sup>a</sup>	332±35.5 <sup>a</sup>
CMTG	52±10.5 <sup>b</sup>	25±4.7 <sup>b</sup>	90±21.3 <sup>a</sup>	19±4.0 <sup>b</sup>	50±5.5 <sup>b</sup>	236±24.1 <sup>b</sup>
CMT/B <sub>12</sub> G	70±18.1 <sup>a,b</sup>	42±5.3 <sup>a</sup>	111±19.7 <sup>a</sup>	23±2.5 <sup>b</sup>	60±8.7 <sup>b</sup>	306±36.6 <sup>a</sup>
P	0.0366	<0.0001	0.3257	<0.0001	<0.0001	0.0002

X±s.d.; a=b (P<0.05). CG: control group; B<sub>12</sub>G: vitamin B<sub>12</sub> group; CMTG: cimetidine group; s.d.: standard deviation

**Table 2: Number of spermatocytes according to the stages of the seminiferous epithelium cycle and total spermatocytes of rats from CG, B<sub>12</sub>G, CMTG, and CMT/B<sub>12</sub>G**

	I-VI	VII-VIII	IX-XIV	Total
	CG	602±14.5 <sup>a</sup>	1158±87.4 <sup>a</sup>	1228±51.7 <sup>a</sup>
B <sub>12</sub> G	598±22.4 <sup>a</sup>	1177±52.5 <sup>a</sup>	1257±69.7 <sup>a</sup>	3032±100.6 <sup>a</sup>
CMTG	481±68.2 <sup>b</sup>	986±88.3 <sup>b</sup>	1030±66.2 <sup>b</sup>	2497±208.2 <sup>b</sup>
CMT/B <sub>12</sub> G	556±67.0 <sup>a,b</sup>	1092±69.0 <sup>a,b</sup>	1144±83.7 <sup>a,b</sup>	2792±177.9 <sup>a</sup>
P	0.0048	0.0044	0.0004	0.0003

X±s.d.; a=b (P<0.05). CG: control group; B<sub>12</sub>G: vitamin B<sub>12</sub> group; CMTG: cimetidine group; s.d.: standard deviation

possible c-kit/SCF binding deficiency. It is also important to emphasize that cimetidine is an antiandrogenic drug<sup>21,22</sup> and induces testicular microvasculature atrophy,<sup>31</sup> Leydig cell death, and reduction in the serum testosterone levels.<sup>32</sup> Therefore, the cimetidine-induced germ cell loss by apoptosis is also a consequence of the interference of this drug on the vascular and/or androgenic supply of the seminiferous tubules.

The animals treated with cimetidine and vitamin B<sub>12</sub> (CMT/B<sub>12</sub>G) showed a significant increase in the number of type A spermatogonia and spermatocytes, corroborating a previous study, in which these animals showed a significant recovery in the total tubular and epithelial areas as well as in the number of Sertoli cells.<sup>12</sup> These results associated with the increase in the incidence of PCNA-positive germ cells confirm the efficient role of this vitamin in the seminiferous epithelium.

Vitamin B<sub>12</sub> is essential for the maintenance of testicular functions<sup>7</sup> since the deficiency of this vitamin may cause atrophy of seminiferous tubules and aplasia of spermatocytes, spermatids, and spermatozoa.<sup>8,9,44</sup> It is known that vitamin B<sub>12</sub> is an essential cofactor for methionine synthase during the production of purines and pyrimidines,<sup>6</sup> stimulating DNA synthesis and contributing to cell division.<sup>5,45</sup> Clermont and Leblond<sup>46</sup> demonstrated the existence of five peaks of spermatogonial divisions in rat located in stages IX, XII, XIV-I, IV, and VI of the cycle, respectively. The first three mitotic peaks were identified in the type A spermatogonia; the fourth mitotic peak corresponds to divisions of type In spermatogonia; and the fifth peak of mitosis corresponds to divisions of type B spermatogonia giving rise to preleptotene primary spermatocytes (Figure 1). Thus, the significant increase in the number of type A spermatogonia in the animals treated with cimetidine and vitamin B<sub>12</sub> (CMTG/B<sub>12</sub>G) indicates that this vitamin might have stimulated these spermatogonia during the mitotic peaks at stages I-VI, leading to the significant increase in the number of spermatocytes. Besides vitamin seems to recover spermatogenesis by stimulating spermatogonia, we cannot exclude the possibility that this vitamin can exert some protective effect on the seminiferous epithelium during cimetidine treatment. Further studies focusing on the initial effect of this vitamin on the cimetidine-damaged spermatogenesis would clarify this possibility.

It is known that the regulation of cell number is extremely important for the maintenance of size and function of tissues and organs. When tissues are injured, cell number increases to compensate the loss of functional tissue mass. In this context, some nutrients, such as vitamin B<sub>12</sub>, are essential for the cell cycle progression and tissue growth and maintenance.<sup>47</sup> Germ cell loss (apoptosis) plays an important role in the seminiferous epithelium homeostasis by limiting the number of produced sperm. This occurs mainly during meiosis, through the elimination of germ cells that are defective or carry DNA mutations, and during the spermatogonial phase in a process named cell-density regulation.<sup>48</sup> Our results showed that the number of spermatogonia and spermatocytes in vitamin B<sub>12</sub>-supplemented animals (B<sub>12</sub>G) was similar to control. In this case, a balance between apoptosis and cell proliferation might have occurred since the tissue was in homeostasis. Numerous PCNA-immunolabeled spermatogonia and early primary spermatocytes were observed in parallel to a high incidence of TUNEL-positive spermatogonia and spermatocytes in the vitamin-supplemented animals. As mitotic divisions of spermatogonia are synchronized to meiotic divisions of spermatocytes, the concomitant presence of apoptotic spermatogonia and apoptotic spermatocytes in the same tubule sections might also indicate that this synchronization is carried out through the synchronized control of mitotic and meiotic checkpoints.<sup>49</sup> It is known that there is a maximal number of germ cells to be supported by Sertoli cells, and this number is adjusted by cell death when proliferation of differentiating spermatogonia begins. Thus, cell death usually occurs at the same stages in which spermatogonia are committed to division.<sup>49</sup>

In CMTG and CMT/B<sub>12</sub>G, the number of spermatogonia was equivalent to the epididymal sperm concentration. Thus, while a low sperm concentration was correlated with a low number of spermatogonia in CMTG, an increased sperm concentration was correlated to a high number of spermatogonia in CMT/B<sub>12</sub>G. However, further studies are necessary to confirm whether the changes in the epididymal sperm concentration are consequent effects of cimetidine/vitamin treatments in testis or epididymis or both. Testis and epididymis provide a suitable and necessary environment for spermatogenesis, maturation, and storage of spermatozoa and their activities are regulated by testosterone.<sup>50</sup> In chromium-exposed rats, low sperm count has been associated with decreased activities of testicular steroidogenic enzymes such as 3β- and 17β-hydroxysteroid dehydrogenase,<sup>51</sup> indicating that decreased sperm count may be related to disruption in steroidogenesis and changes in testosterone levels.<sup>52,53</sup> As cimetidine treatment causes Leydig cell apoptosis and decrease in the testosterone serum levels,<sup>32</sup> the reduction in the sperm concentration may be related to deficient testosterone supply either in the testicular or epididymal microenvironment. Studies focusing on Leydig cell steroidogenesis would be useful to clarify if the increased sperm concentration induced by this vitamin in CMT/B<sub>12</sub> is related to hormonal status. Independently, of a possible role on hormonal control, vitamin B<sub>12</sub> administration in patients with pernicious anemia improves sperm parameters, mainly in cases of oligozoospermia.<sup>7</sup> Moreover, Watson<sup>54</sup> demonstrated that cobalamin also plays a role in the maturation of human spermatozoa. Since then, vitamin B<sub>12</sub> has been considered an important nutrient for the maintenance of normal fertility in men<sup>4,54,55</sup> and alleviates the changes in the testicular morphology, sperm number, and motility in doxorubicin-treated rats.<sup>10,11</sup>

## CONCLUSION

The supplementation of rats with vitamin B<sub>12</sub> during cimetidine treatment improves the epididymal sperm concentration and recovers the number of spermatogonia and spermatocytes, probably stimulating type A spermatogonia mitotic activity. These findings reinforce the potential effect of vitamin B<sub>12</sub> in the spermatogenic recovery.





## AUTHORS' CONTRIBUTION

ESC coordinated the study. FLB carried out the treatment of animals. FLB and ESC collected and carried out the histological processing. FLB carried out the morphological, morphometric and sperm analyses, TUNEL method, and the immunofluorescence reaction. FLB and ESC examined and selected the images, participated in the design, read and approved the final version of the manuscript.

## COMPETING FINANCIAL INTERESTS

None of the authors declared competing financial interests.

## ACKNOWLEDGMENTS

This work was supported by the FAPESP (2006/54776-6; 2010/02409-5; 2012/23845-3; 2013/25322-0) and CNPq.

## REFERENCES

- de Kretser DM. Determinants of male health: the interaction of biological and social factors. *Asian J Androl* 2010; 12: 291–7. [Doi: 10.1038/aja. 2010.15].
- Sinclair S. Male infertility: nutritional and environmental considerations. *Altern Med Ver* 2000; 5: 28–38.
- Iwasaki A, Hosaka M, Kinoshita Y, Saito K, Yumura Y, et al. Result of long-term methylcobalamin treatment for male infertility. *Jpn J Fertil Steril* 2003; 48: 119–24.
- Chatterjee S, Chowdhury RG, Khan B. Medical management of male infertility. *J Indian Med Assoc* 2006; 104: 74, 76–7.
- Oh RC, Brown DL. Vitamin B12 deficiency. *Am Fam Physician* 2003; 67: 979–86.
- O'Leary F, Samman S. Vitamin B12 in Health and Disease. *Nutrients* 2010; 2: 299–316. [Doi: 10.3390/nu2030299].
- Sharp AA, Witts LJ. Seminal Vitamin B12 and sterility. *Lancet* 1962; 2: 779.
- Kawata T, Tamiki A, Tashiro A, Suga K, Kamioka S, et al. Effect of Vitamin B12-deficiency on testicular tissue in rats fed by pair-feeding. *Int J Vitam Nutr Res* 1997; 67: 17–21.
- Watanabe T, Ebara S, Kimura S, Maeda K, Watanabe Y, et al. Maternal Vitamin B12 deficiency affects spermatogenesis at the embryonic and immature stages in rats. *Congenit Anom (Kyoto)* 2007; 47: 9–15.
- Ozaki S, Ohkawa I, Katoh Y, Tajima T, Kimura M, et al. Study on producing rats with experimental testicular dysfunction and effects of mecobalamin. *Nippon Yakurigaku Zasshi* 1988; 91: 197–207.
- Oshio S, Ozaki S, Tajima T, Kaneko S, Mohri H. Mecobalamin promotes mouse sperm maturation. *Andrologia* 1989; 21: 167–73.
- Beltrame FL, Caneguim BH, Miraglia SM, Cerri PS, Sasso-Cerri E. Vitamin B12 supplement exerts a beneficial effect on the seminiferous epithelium of cimetidine-treated rats. *Cells Tissues Organs* 2011; 193: 184–94.
- Clayman CB. Evaluation of cimetidine (Tagamet): an antagonist of hydrochloric acid secretion. *JAMA* 1977; 238: 1289–90.
- Ahmadi A, Ebrahimzadeh MA, Ahmad-Ashrafi S, Karami M, Mahdavi MR, et al. Hepatoprotective, antinociceptive and antioxidant activities of cimetidine, ranitidine and famotidine as histamine H2 receptor antagonists. *Fundam Clin Pharmacol* 2011; 25: 72–9. [Doi: 10.1111/j.1472-8206.2009.00810.x].
- Shaik IH, Mehvar R. Effects of cytochrome P450 inhibition by cimetidine on the warm hepatic ischemia-reperfusion injury in rats. *J Surg Res* 2010; 159: 680–8. [Doi: 10.1016/j.jss.2008.09.016].
- Kubecova M, Kolostova K, Pinterova D, Kacprzak G, Bobek V. Cimetidine: an anticancer drug? *Eur J Pharm Sci* 2011; 42: 439–44.
- Edrei Y, Gross E, Corchia N, Abramovitch R. Improved efficacy of a novel anti-angiogenic drug combination (TL-118) against colorectal-cancer liver metastases; MRI monitoring in mice. *Br J Cancer* 2012; 107: 658–66.
- Spence RW, Celestin LR. Gynecomastia associated with cimetidine. *Gut* 1979; 20: 154–7.
- Peden NR, Cargill JM, Browning MC, Saunders JH, Wormsley KG. Male sexual dysfunction during treatment with cimetidine. *Br Med J* 1979; 1: 659.
- Jensen RT, Collen MJ, Pandol SJ, Allende HD, Raufman JP, et al. Cimetidine-induced impotence and breast changes in patients with gastric hypersecretory states. *N Engl J Med* 1983; 308: 883–7.
- Winters SJ, Banks JL, Loriaux DL. Cimetidine is an antiandrogen in the rat. *Gastroenterology* 1979; 76: 504–8.
- Funder JW, Mercer JE. Cimetidine, a histamine H2 receptor antagonist, occupies androgen receptors. *J Clin Endocrinol Metab* 1979; 48: 189–91.
- Baba S, Paul HJ, Pollow K, Janetschek G, Jacobi GH. *In vivo* studies on the antiandrogenic effects of cimetidine versus cyproterone acetate in rats. *Prostate* 1981; 2: 163–74.
- Pereira OC. Some effects of cimetidine on the reproductive organs of rats. *Gen Pharmacol* 1987; 18: 197–9.
- Van Thiel DH, Gavalier JS, Smith WE, Paul G. Hypothalamic-pituitary-gonadal dysfunction in men using cimetidine. *N Engl J Med* 1979; 300: 1012–5.
- Wang C, Lai CL, Lam KC, Yeung KK. Effect of cimetidine on gonadal function in man. *Br J Clin Pharmacol* 1982; 13: 791–4.

- Sasso-Cerri E, Giovanoni M, Hayashi H, Miraglia SM. Morphological alterations and intratubular lipid inclusions as indicative of spermatogenic damage in cimetidine-treated rats. *Arch Androl* 2001; 46: 5–13.
- Sasso-Cerri E, Miraglia SM. *In situ* demonstration of both TUNEL-labeled germ cell and Sertoli cell in the cimetidine-treated rats. *Histol Histopathol* 2002; 17: 411–7.
- França LR, Leal MC, Sasso-Cerri E, Vasconcelos A, Debeljuk L, et al. Cimetidine (Tagamet) is a reproductive toxicant in male rats affecting peritubular cells. *Biol Reprod* 2000; 63: 1403–12.
- Sasso-Cerri E, Cerri PS. Morphological evidences indicate that the interference of cimetidine on the peritubular components is responsible for detachment and apoptosis of Sertoli cells. *Reprod Biol Endocrinol* 2008; 6: 18. [Doi: 10.1186/1477-7827-6-18].
- Beltrame FL, Yamauti CT, Caneguim BH, Cerri PS, Miraglia SM, et al. Cimetidine-induced vascular cell apoptosis impairs testicular microvasculature in adult rats. *Histol Histopathol* 2012; 27: 1343–51.
- Beltrame FL, Cerri PS, Sasso-Cerri E. Cimetidine-induced Leydig cell apoptosis and reduced EG-VEGF (PK-1) immunoeexpression in rats: evidence for the testicular vasculature atrophy. *Reprod Toxicol* 2015; 57: 50–8. [Doi: 10.1016/j.reprotox. 2015.05.009].
- Chen QX, Ng V, Mei J, Chia SE. Comparison of seminal Vitamin B12, folate, reactive oxygen species and various sperm parameters between fertile and infertile males. *Wei Sheng Yan Jiu=J Hyg Res* 2001; 30: 80–2. [Article in Chinese].
- Hu JH, Tian WQ, Zhao XL, Zan LS, Xin YP, et al. The cryoprotective effects of Vitamin B12 supplementation on bovine semen quality. *Reprod Domest Anim* 2011; 46: 66–73. [Doi: 10.1111/j. 1439-0531.2009.01575.x].
- Cai JG, Sun SQ, Wang LG, Gu HJ. The effect of adding Vitamin B12 in sperm diluter on quality of bull's straw frozen sperm. *J Liaoning Agric Coll* 2004; 6: 10–1.
- Brodgen RN, Heel RC, Speight TM, Avery GS. Cimetidine: a review of its pharmacological properties and therapeutic efficacy in peptic ulcer disease. *Drugs* 1978; 15: 93–131.
- U.S. EPA. Harmonization in interspecies extrapolation: Use of BW 3/4 as default method in derivation of the oral RfD (external review draft). Washington, D.C.: U.S. Environmental Protection Agency; 2006. [EPA/630/R-06/001].
- Clermont Y, Leblond CP, Messier B. Duration of the cycle of the seminal epithelium of the rat. *Arch Anat Microsc Morphol Exp* 1959; 48: 37–55.
- Cerri PS, Sasso-Cerri E. Staining methods applied to glycol methacrylate embedded tissue sections. *Micron* 2003; 34: 365–72.
- Dym M, Clermont Y. Role of spermatogonia in the repair of the seminiferous epithelium following x-irradiation of the rat testis. *Am J Anat* 1970; 128: 265–82.
- Chiariini-Garcia H, Raymer AM, Russell LD. Non-random distribution of spermatogonia in rats: evidence of niches in the seminiferous tubules. *Reproduction* 2003; 126: 669–80.
- Yoshinaga K, Nishikawa S, Ogawa M, Hayashi S, Kunisada T, et al. Role of c-kit in mouse spermatogenesis: identification of spermatogonia as a specific site of c-kit expression and function. *Development* 1991; 113: 689–99.
- de Kretser DM, Loveland KL, Meinhardt A, Simorangkir D, Wreford N. Spermatogenesis. *Hum Reprod* 1998; 13 Suppl 1: 1–8.
- Kawata T, Funada U, Wada M, Matsushita M, Sanai T, et al. Breeding severely Vitamin B12-deficient mice as model animals. *Int J Vitam Nutr Res* 2004; 74: 57–63.
- Beck WS, Goulian M, Kashket S. The role of Vitamin B12 in deoxyribonucleic acid synthesis: studies of a model megaloblast. *Trans Assoc Am Physicians* 1965; 128: 343–61.
- Clermont Y, Leblond CP. Renewal of spermatogonia in the rat. *Am J Anat* 1953; 93: 475–502.
- Bohnsack BL, Hirschi KK. Nutrient regulation of cell cycle progression. *Annu Rev Nutr* 2004; 24: 433–53. [Doi: 10.1146/annurev.nutr. 23.011702.073203].
- de Rooij DG, Russell LD. All you wanted to know about spermatogonia but were afraid to ask. *J Androl* 2000; 21: 776–98.
- Blanco-Rodríguez J, Martínez-García C, Porras A. Correlation between DNA synthesis in the second, third and fourth generations of spermatogonia and the occurrence of apoptosis in both spermatogonia and spermatocytes. *Reproduction* 2003; 126: 661–8.
- Turner TT, Miller DW, Avery EA. Protein synthesis and secretion by the rat caput epididymidis *in vivo*: influence of the luminal microenvironment. *Biol Reprod* 1995; 52: 1012–9.
- Chandra AK, Chatterjee A, Ghosh R, Sarkar M, Chaube SK. Chromium induced testicular impairment in relation to adrenocortical activities in adult albino rats. *Reprod Toxicol* 2007; 24: 388–96.
- Li H, Chen Q, Li S, Yao W, Li L, et al. Effect of Cr (VI) exposure on sperm quality: human and animal studies. *Ann Occup Hyg* 2001; 45: 505–11.
- Marouani N, Tebourbi O, Mahjoub S, Yacoubi MT, Sakly M, et al. Effects of hexavalent chromium on reproductive functions of male adult rats. *Reprod Biol* 2012; 12: 119–33.
- Watson AA. Seminal Vitamin B12 and sterility. *Lancet* 1962; 2: 644.
- Moriyama H, Nakamura K, Sanda N, Fujisawa E, Seko S, et al. Studies on the usefulness of methylcobalamin for patients with oligozoospermia. *Acta Urol Jpn* 1987; 33: 151–6.

This is an open access article distributed under the terms of the Creative Commons Attribution-NonCommercial-ShareAlike 3.0 License, which allows others to remix, tweak, and build upon the work non-commercially, as long as the author is credited and the new creations are licensed under the identical terms.

©The Author(s)(2017)

