

## Bilateral Sudden Hearing Loss in Waldenstrom's Macroglobulinemia: MR Appearance

Dean K. Shibata and S. Claiborne Johnston

A 46 year-old man with acquired immunodeficiency syndrome presented with sudden development of vertigo and tinnitus and then simultaneous, bilateral, profound, sudden hearing loss. Magnetic resonance imaging showed bilateral high signal within the cochlea, vestibule, and portions of the semicircular canals on the non-enhanced T1-weighted images, most consistent with recent hemorrhage into the otic labyrinth. Serum analysis and bone-marrow biopsy led to diagnosis of Waldenstrom's macroglobulinemia – a likely cause of the presumed hemorrhage.

### Introduction

Bilateral sudden hearing loss is much less common than unilateral loss and accounts for less than two percent of those with sudden hearing loss [1, 2]. Although often idiopathic, commonly suspected causes include viral infections, vascular occlusive events, metabolic disorders, toxicity, or labyrinthine membrane ruptures [1]. In the workup of unilateral hearing loss, imaging studies, particularly magnetic resonance imaging (MRI), are often performed to exclude the possibility of a tumor or other mass lesion, but in bilateral sudden hearing loss, hematological studies, or infectious serological assays (such as syphilis) are often felt more central to the workup.

In the setting of human immunodeficiency virus (HIV) infection, there have been reports of associated hearing loss related to lymphoma, suspected opportunistic infection, and antiretroviral therapy [3, 4]. In addition, there is the

possibility of direct involvement of the 8th cranial nerve [5] or hair cells [6] by the HIV infection itself, but these presentations are rarely sudden and bilateral [7].

Waldenstrom's macroglobulinemia is an uncommon disorder now felt to be a form of low-grade, small-cell lymphoma with immunoglobulin (Ig) M production [8]. It afflicts approximately 1,500 Americans each year and presents most often in the elderly. Like other B-cell lymphoplasmacytic neoplasms, Waldenstrom's macroglobulinemia can present with anemia and hemorrhage, but is particularly known for pronounced hyperviscosity. Neurologic disease exists in approximately 16% to 20% of Waldenstrom's macroglobulinemia patients. Involvement of the inner ear is relatively rare but there have been several case reports [9-11] of sudden unilateral deafness without pathologic or imaging correlates.

### Case Report

A 46 year old man with acquired immune deficiency syndrome (AIDS) and a CD4 count of 80 presented after the sudden development of vertigo, nausea, vomiting, gait unsteadiness, and right ear tinnitus. Initial exam revealed left-beating nystagmus on primary and leftward gaze. Weber's test lateralized to the left and Rinne's test was normal, but no obvious hearing impairment was found on informal testing. Laboratory testing revealed new thrombocytopenia with platelet count of 14 and serum globulin level of 8.7 g/dL with a profoundly elevated IgM of 6030 mg/dL (normal range, 56 - 352 mg/dl). Serum RPR was 1:1, reduced from 1:32 after treatment with doxycycline. Further work up for possible Waldenstrom's macroglobulinemia was refused, and lumbar puncture was also declined.

---

**Citation:** Shibata D, Johnston SC. Bilateral sudden hearing loss in waldenstrom's macroglobulinemia. *Radiology Case Reports*. [Online] 2006;1:25.

**Copyright:** © Dean K Shibata. This is an open-access article distributed under the terms of the Creative Commons Attribution-NonCommercial-NoDerivs 2.5 License, which permits reproduction and distribution, provided the original work is properly cited. Commercial use and derivative works are not permitted.

**Abbreviations:** MRI, magnetic resonance imaging, HIV, human immunodeficiency virus, AIDS, acquired immune deficiency syndrome, VDRL, venereal disease research laboratory test, CDL, cerebral spinal fluid

Dean K Shibata (E-mail: [shibatad@u.washington.edu](mailto:shibatad@u.washington.edu)) is in the Department of Radiology, University of Washington, Seattle, Washington, United States of America.

S. Claiborne Johnston is in the Department of Neurology, University of California at San Francisco, San Francisco, California, United States of America.

**DOI:** 10.2484/rcr.v1i3.25

## Bilateral Sudden Hearing Loss in Waldenstrom's Macroglobulinemia: MR Appearance

Vertigo and nystagmus slowly improved over the following 48 hours. However, 30 minutes after routine cerumen removal and otologic evaluation, the patient complained of sudden bilateral hearing loss. Initially he was able to understand loud speech, but hearing loss rapidly progressed over the next 24 hours. Audiology revealed profound bilateral sensorineural hearing loss with inability to recognize words at 105 dB. Gaze-evoked nystagmus was present bilaterally and gait was ataxic. Otoloscopic exam was unremarkable. Platelet count had fallen to nine and creatinine was 4.2 (up from baseline of 1.4). Waldenstrom's macroglobulinemia with hyperviscosity was suspected.

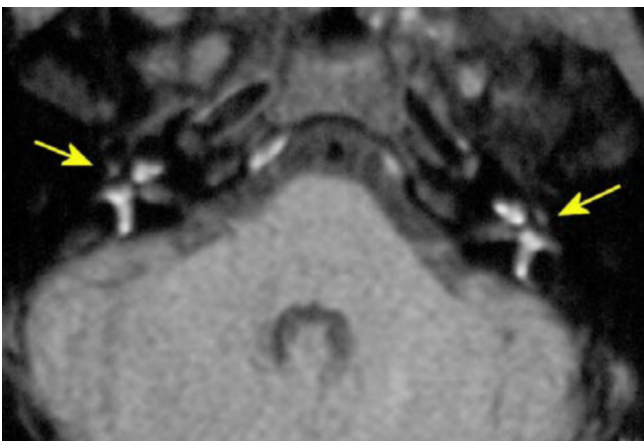
Emergent plasmapheresis was initiated and creatinine returned to baseline as viscosity was reduced to 2.4 g/dL. A bone marrow biopsy confirmed the diagnosis of Waldenstrom's macroglobulinemia. A lumbar puncture revealed a white blood cell count of 23 with 80% lymphocytes, protein 77, glucose 56, and non-reactive Venereal Disease Research Laboratory test (VDRL).

MRI was performed on a 1.5 Tesla scanner with and without contrast and thin 3mm coronal and axial sections obtained through the inner ear. The T2-weighted images were unremarkable, but the T1-weighted images axial (Fig 1) and coronal (Fig 2) demonstrated bilateral strikingly abnormal high signal material precisely outlining and filling in the cochlea, vestibule, and portions of the semicircular canals. The post-contrast T1-weighted images showed no evidence of associated abnormal enhancement.

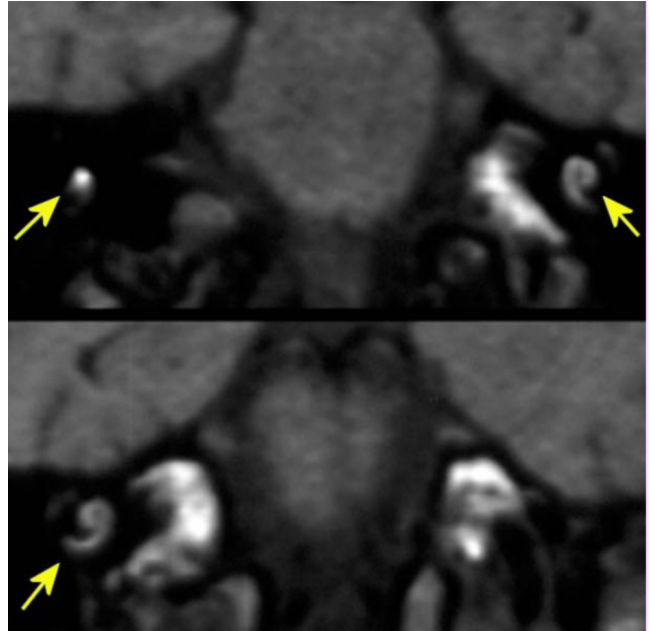
Profound sensorineural hearing loss persisted unchanged during a six-month follow-up period in spite of aggressive treatment for the Waldenstrom's macroglobulinemia with steroids and chlorambucil.

### Discussion

Magnetic resonance imaging can be highly sensitive in detecting subacute blood products since paramagnetic methemoglobin promotes T1 shortening and thus high signal on T1-weighted images. On routine T2-weighted images the otic labyrinth is well demonstrated because high-signal



**Figure 1.** Axial T1-weighted (TR 700, TE 30) 3mm noncontrast sections through the petrous bone. Arrows indicate T1 shortening within the labyrinth.



**Figure 2.** Coronal T1-weighted (TR 600, TE 30) 3mm noncontrast sections through the inner ear. Arrows indicate hemorrhage within the labyrinth.

endolymph and perilymph are contrasted against the signal void of the bony capsule. Enhancement of the labyrinth is usually attributed to inflammatory disease such as viral labyrinthitis, but in these instances the normal labyrinth is hypointense, similar to cerebral spinal fluid (CSF), on the precontrast T1-weighted images [12, 13]. There have been passing references to intrinsic vestibule and cochlea T1-shortening [12, 14] attributed to high-protein fluid or hemorrhage.

In the present case, there is good reason to believe that the MR finding represent hemorrhage into the labyrinth related to hypercoagulation. Nonhemorrhagic AIDS-related hearing loss must also be considered in the differential diagnosis, but the sudden onset and the labyrinthine T1 shortening are strongly suggestive of hemorrhage. Other entities in the differential diagnosis include nonspecific viral labyrinthitis with high protein fluid or other causes of hemorrhage such as trauma or other forms of coagulopathy. Although lipid material may show T1 shortening, the high signal on the post contrast T1 fat saturation images makes that unlikely. In the absence of pathological proof other these entities cannot be excluded, but the bilateral nature of the findings, and the abrupt clinical presentation in the setting of Waldenstrom's macroglobulinemia, make hemorrhage the most likely.

Labyrinthine hemorrhage has been suspected as the mechanism of sudden hearing loss in several hematologic diseases including multiple myeloma [15] and leukemia [16], as well as disseminated adenocarcinoma [17]. The blood products in the perilymph may render the cochlea

## Bilateral Sudden Hearing Loss in Waldenstrom's Macroglobulinemia: MR Appearance

nonfunctional due to either to "alterations in chemistry" or by interfering with the hydrodynamics of the wave kinetics [16].

Although there have been reports of inner ear disorders in patients with Waldenstrom's macroglobulinemia, the mechanism is uncertain do to lack of pathologic material [11]. Unlike other hematological diseases in which tumor cell infiltration and coagulopathy are the most likely factors, in Waldenstrom's the mechanism is more likely related to hyperviscosity and venous congestion. An animal study involving obstruction of the inferior cochlear vein and some of its collateral's in the guinea pig showed varying degrees of hemorrhage into the labyrinthine spaces as well as direct degeneration of the stria vascularis and sensory epithelium [18].

In the era of high resolution MR imaging, one can now directly assess the chemical composition of the labyrinth. This case illustrates the value of obtaining thin-section pre-contrast T1-weighted images in patients with acute symptoms attributable to inner ear disease. In some imaging protocols, only post-contrast T1-weighted images are obtained and the high signal is interpreted as enhancement, obscuring detection of high T1 signal that may indicate labyrinthine hemorrhage.

### References

1. Fetterman BL, Luxford WM, Saunders JE. Sudden bilateral sensorineural hearing loss. *Laryngoscope*. 1996;106:1347-1350. [[PubMed](#)]
2. Cadoni G, Agostino S, Scipione S, et al. Sudden sensorineural hearing loss: our experience in diagnosis, treatment, and outcome. *J Otolaryngol*. 2005 Dec;34(6):395-401. [[PubMed](#)]
3. Madriz JJ, Herrera G. Human immunodeficiency virus and acquired immune deficiency syndrome AIDS-related hearing disorders. *J Amer Acad Audiology*. 1995;6:358-64. [[PubMed](#)]
4. Marra CM, Wechkin HA, Longstreth WT, Jr., Rees TS, Syapin CL, Gates GA. Hearing loss and antiretroviral therapy in patients infected with HIV-1. *Arch Neurology*. 1997;54:407-10. [[PubMed](#)]
5. Grimaldi LM, Luzi L, Martino GV, et al. Bilateral eighth cranial nerve neuropathy in human immunodeficiency virus infection. *J. Neurology*. 1993;240:363-6. [[PubMed](#)]
6. Pappas DG, Jr., Roland JT, Jr., Lim J, Lai A, Hillman DE. Ultrastructural findings in the vestibular end-organs of AIDS cases. *Amer J. Otolaryngol*. 1995;16:140-5. [[PubMed](#)]
7. Solanellas SJ, Soldado PL, Lozano DF. Sudden hearing loss and HIV infection. *Acta Otorrinolaringologica Espanola*. 1996;47:311-3. [[PubMed](#)]
8. Gertz MA, Fonseca R, Rajkumar SV. Waldenstrom's macroglobulinemia. *Oncologist*. 2000;5(1):63-7. [[PubMed](#)]
9. Ruben RJ, Distenfeld A, Berg P, et al. Sudden sequential deafness as the presenting symptom of Macroglobulinemia. *JAMA* 1969;209:1264-1265. [[PubMed](#)]
10. Syms MJ, Arcila ME, Holtel MR. Waldenstrom's macroglobulinemia and sensorineural hearing loss. *Am J Otolaryngol*. 2001 Sep-Oct;22(5):349-53. [[PubMed](#)]
11. Platia EV, Saral R. Deafness and Waldenstrom's macroglobulinemia. *Southern Med J*. 1979;72:1495-1496. [[PubMed](#)]
12. Mark AS, Seltzer S, Harnsberger HR. Sensorineural hearing loss: more than meets the eye? *Amer J Neuroradiol*. 1993;14:37-45. [[PubMed](#)]
13. Casselman JW, Kuhweide R, Dehaene I, et al. Magnetic resonance examination of the inner ear and cerebellopontine angle in patients with vertigo and/or abnormal findings at vestibular testing. *Acta Otolaryngol (Stockh) Suppl*. 1994;513:15-27. [[PubMed](#)]
14. Weissman JL, Curtin HD, Hirsch BE, Hirsch WL. High signal from the otic labyrinth on unenhanced magnetic resonance imaging. *Amer J Neuroradiol*. 1992;13:1183-1187. [[PubMed](#)]
15. Keay D. Total bilateral hearing loss as a complication of myeloma. *J. Laryn Oto*. 1988;102:357-358. [[PubMed](#)]
16. Schuknecht HF, Igarashi M, Chasin WD. Inner ear hemorrhage in leukemia. *Laryngoscope*. 1965;75:662-668. [[PubMed](#)]
17. Johnson A, Hawke M, Berger G. Sudden deafness and vertigo due to inner ear hemorrhage- a temporal bone case report. *J. Otolaryngol*. 1984;13:201-488. [[PubMed](#)]
18. Kimura R, Perlman HB. Extensive venous obstruction of the labyrinth: A. Cochlear changes. *Ann Otol*. 1956;65:332-351. [[PubMed](#)]